

Anatomical Changes and Audiological Profile in Branchio-oto-renal Syndrome: A Literature Review

Tâmara Andrade Lindau¹ Ana Cláudia Vieira Cardoso¹ Natalia Freitas Rossi¹ Célia Maria Giacheti¹

¹Department of Speech Pathology, Universidade Estadual Paulista - UNESP, Marília, São Paulo, Brazil

Address for correspondence Célia Maria Giacheti, PhD, Department of Speech Pathology, Universidade Estadual Paulista UNESP, Av. Hygino Muzzi Filho, 737, Marília, São Paulo 14525-900, Brazil (e-mail: giacheti@uol.com.br).

Int Arch Otorhinolaryngol 2014;18:68–76.

Abstract

Introduction Branchio-oto-renal (BOR) syndrome is an autosomal-dominant genetic condition with high penetrance and variable expressivity, with an estimated prevalence of 1 in 40,000. Approximately 40% of the patients with the syndrome have mutations in the gene *EYA1*, located at chromosomal region 8q13.3, and 5% have mutations in the gene *SIX5* in chromosome region 19q13. The phenotype of this syndrome is characterized by preauricular fistulas; structural malformations of the external, middle, and inner ears; branchial fistulas; renal disorders; cleft palate; and variable type and degree of hearing loss.

Aim Hearing loss is part of BOR syndrome phenotype. The aim of this study was to present a literature review on the anatomical aspects and audiological profile of BOR syndrome.

Data Synthesis Thirty-four studies were selected for analysis. Some aspects when specifying the phenotype of BOR syndrome are controversial, especially those issues related to the audiological profile in which there was variability on auditory standard, hearing loss progression, and type and degree of the hearing loss. Mixed loss was the most common type of hearing loss among the studies; however, there was no consensus among studies regarding the degree of the hearing loss.

Keywords

- ▶ branchio-oto-renal syndrome
- ▶ BOR syndrome
- ▶ hearing
- ▶ review

Introduction

The etiology of hearing loss has been investigated in molecular and genetics medical centers.¹ Anatomical and physiological changes in the auditory system have been described as part of the phenotype of numerous genetic syndromes, including the previously studied branchio-oto-renal (BOR) syndrome.²

The features of this clinical condition were first described in 1864 when Heusinger presented the initial reports on the association between branchial fistulas, preauricular fistulas, and hearing loss.³ However, these features combined with auricular malformations and renal anomalies, thus comprising the phenotype of a specific condition, were described

almost 110 years after the first clinical reports, and it was called BOR syndrome.^{4–6}

Different classifications have been applied to this condition over the years, including Melnick-Fraser syndrome. This nomenclature originates from the first phenotype descriptions by these authors, “ear pits deafness syndrome”⁷ and “branchio-oto-ureteral syndrome.”⁸ However, contemporary studies have adopted the term “BOR syndrome” in a systematic way.

The clinical characteristics that compose the BOR syndrome phenotype can be classified according to the occurrence of larger and smaller anomalies. The larger or more frequent anomalies are: (1) hearing loss (sensorineural,

received
August 27, 2013
accepted
September 4, 2013

DOI <http://dx.doi.org/10.1055/s-0033-1358659>.
ISSN 1809-9777.

Copyright © 2014 by Thieme Publicações Ltda, Rio de Janeiro, Brazil

License terms



conductive, or mixed), (2) preauricular pits, (3) renal anomalies ranging from mild hypoplasia to agenesis, (4) brachial fistulae, and (5) stenosis of the external auditory canal. The smaller or less frequent anomalies are: (1) lacrimal duct aplasia, (2) short or cleft palate, (3) retrognathia, (4) congenital hip dysplasia, (5) facial nerve paralysis, (6) gustatory lacrimation, and (7) pancreatic cyst.⁹

Such anomalies are used as criteria to diagnose BOR syndrome. In other words, the presence of three major deficiencies, or the combination of two major and two smaller anomalies, or the presence of a major anomaly associated with presence of another first degree family member diagnosed with the syndrome.¹⁰

One of the most mentioned characteristics as part of the BOR syndrome phenotype is progressive hearing loss, which can be mixed, conductive, or sensorineural and can range from mild to profound.^{9,11} In some patients, the hearing loss has a fluctuating pattern.^{12–15} Studies have reported the occurrence of congenital cholesteatoma among the less common characteristics.^{16–18}

Genetic/Etiologic Bases of Branchio-Oto-Renal Syndrome

The estimated rate of BOR syndrome is 1:40,000.^{4–6,9,19} BOR syndrome presents a pattern of autosomal-dominant inheritance and is considered the most common syndromic hearing loss form of genetic etiology with high penetrance and variable expressivity.^{4,8,19–21} In addition to the autosomal-dominant, mitochondrial inheritance,²² some patients present with “new” mutations.^{7,23} Deletions of various sizes have been found in individuals with BOR syndrome.^{24–26}

The first chromosomal region associated with the syndrome was 8q12–22, identified from linkage studies in families that had multiple members affected.²⁷ Subsequently, the detailed genetic study of this region allowed researchers to determine the chromosomal region 8q13.3 was associated with the syndrome.²⁴ The *EYA1* gene, which is responsible for the development of the branchial arches, auditory system, and kidneys, is located in this region.^{25,28}

EYA1 gene mutations have been reported in most cases of BOR syndrome.^{2,29} However, studies described that in many cases of clinically diagnosed BOR syndrome, the screening for alterations in the *EYA1* gene was negative, which also showed that other genes are involved in the BOR syndrome etiology, indicating a condition with genetic heterogeneity.^{10,30,31}

Missense mutations and small deletions in the *SIX1* gene, located on chromosome region 14q23.1, were also reported by several studies that described families affected by BOR syndrome.^{28,32–36} However, intrafamilial phenotypic variability can be observed in all families studied that showed mutations in *SIX1*.²²

General Clinical Features of Branchio-Oto-Renal Syndrome

Based on the reviewed studies, the most common triad of BOR syndrome findings is: (1) hearing loss and preauricular fistulas located near the helix, (2) branchial fistulas typically found on the anterior border of the sternocleidomastoid

muscle, and (3) a variability of renal anomalies, which often present no symptoms. Branchial fistulas are usually located next to the first branchial arch. However, a rare case was described where the subject had four branchial fistulas located at the first and second branchial arches.^{37,38}

A retrospective analysis of seven individuals diagnosed with BOR syndrome has shown that besides the applicant phenotype, other clinical features were found in these individuals, such as gustatory lacrimation, imperforate anus, otosclerosis, and congenital vocal cord paresis.³⁹

The manifestations of BOR syndrome can also be composed of craniofacial abnormalities such as microcephaly,³⁹ hemifacial microsomia,⁴⁰ long face syndrome associated with lacrimal duct stenosis,^{5,7,14,17,41,42} overbite palate,¹⁷ and retrognathia.³⁹ The presence of micrognathia,⁴³ hypodontia,³⁹ and microdontia associated with malformations of permanent molars⁴⁴ were also reported. Lacrimal duct stenosis, although rare, has been described in some studies,^{6,7} and its occurrence is associated with gustatory lacrimation.^{39,41}

One study described the presence of cardiac manifestation—mitral valve prolapse—in a family diagnosed with BOR syndrome (one family member had tachycardia). These symptoms were not reported in previous studies. This manifestation was identified in five of seven patients with BOR syndrome in this family, whereas hearing loss was present in all of them. Other previously described features such as branchial fistula, preauricular appendices, external ear malformation, renal anomalies, and anomalies of the lacrimal duct were found in this family.⁴⁵

Limited kidney functions, bifid renal pelvis, hypoplasia, and renal cysts associated with urinary tract infections appeared in one study.²⁰ Another study reported that such infections and glomerulonephritis episodes may be associated with normal renal anatomy and physiology.¹⁶ However, a case with a bifid kidney, double ureter, and vesicoureteric reflux⁴⁶ as well as two patients who reported congenital hydronephrosis were described.⁴⁰ Only one case has been described with severe reduction in kidney volume without family history of this condition,⁴⁷ and there was another case with renal agenesis.⁴⁸

From 1975 to 2013, several authors have described specific phenotypes in individuals diagnosed with BOR syndrome: these articles are summarized in **Table 1**. Most of these studies describe isolated patients or a familial nucleus and show varied expressiveness.

Hearing loss is part of the BOR syndrome phenotype. The aim of this study was to present a literature review on the anatomical aspects and audiological profile in this condition.

Methods

This study review published studies describing BOR syndrome from 1975 to 2013. Research was performed on the following national and international databases: BIREME (Virtual Health Library—LILACS and IBICS) PubMed/MEDLINE (MEDlars onLINE), ProQuest, Web of Science (integrated into ISI Web of Knowledge), and OMIM (Online Mendelian Inheritance in Man).

Table 1 Description of general findings from BOR syndrome

Branchial anomalies
Branchial fistulae (first/second arches)
Other anomalies
Lacrimal duct aplasia/gustatory lacrimation
Palate abnormality (short/cleft)
Micrognathia/retrognathia
Facial asymmetry
Preauricular pits
Small ears and low implantation
Pinnae deformities
Facial nerve paresis
Microdontia/hypodontia
Congenital vocal cord paresis
Congenital hip dysplasia
Pancreatic duplication cyst
Mitral valve prolapse
Renal anomalies
Ureteral pelvic junction obstruction
Renal cyst
Renal agenesis
Renal hypoplasia
Renal aplasia
Double ureter

Abbreviation: BOR, branchio-oto-renal.

The following research descriptors were used according to the criteria of the MeSH:

1. "Branchio-Otorrenal Syndrome" and "Hearing Loss" or "Hearing Disorders"
2. "Branchio-Oto-Renal Syndrome" and ("Hearing" or "Hearing Disorders" or "Hearing Loss")
3. "Branchio-Oto-Renal Syndrome"

Exclusion Criteria

This review refers to the auditory aspects of BOR syndrome and used the following criteria for the exclusion of articles: the title and summary were not related to the purpose of the review; repeated articles and articles written in languages other than English, Portuguese, or Spanish; animal studies; editorial letters, review articles, and articles in which BOR syndrome was associated with other syndromes or genetic conditions with partial phenotype of BOR syndrome; articles that cited BOR syndrome as a cause of loss of hearing; and those that were focused only on general and genetic aspects of BOR syndrome.

From the BIREME database (LILACS and IBECs) and ProQuest, six articles were found using research descriptor 1, and five articles were excluded based on the exclusion criteria. When searching the MEDLINE database, via PubMed, using research descriptor 2, 37 articles were found, 27 of which were excluded by the criteria mentioned above, and thus 10 articles remained. The last search was performed on the Web of Science database using research descriptor 3. It resulted in 96 articles, 73 of which were excluded considering the exclusion criteria, leaving 23 remaining articles.

The results concerning literature review and discussion followed the chronological order of publication, and the issues were grouped by the descriptors used in the literature.

► **Fig. 1** shows the flow diagram that demonstrates the articles' selection criteria.

Literature Review

After the application of the exclusion criteria, 34 studies were selected and compiled on ► **Table 2**, which contains the year of publication, article title, author, and number of the study participants.

Results

Anatomical Changes and Audiological Profile

In the studies reviewed, a prevalence of mixed hearing loss was observed, followed by conductive and sensorineural hearing loss. Some studies reported that the presence of chronic or recurrent otitis media is an aggravating factor for hearing loss, which may be associated with ossicular chain malformations or alterations, or presence of cleft palate, increasing the number with conductive/mixed hearing loss.^{6,16,20,49–51} There was a higher recurrence of moderate and severe hearing loss among the studies' participants, probably due to the number of abnormalities found in the inner ear, which encompasses cochlear alterations to malformation of the vestibular system.

Some research verified that in addition to the auditory standards mentioned above, hearing loss could maintain a progressive and/or fluctuating pattern,^{6,13–15,19,46,52} which contradicts other studies that related their standard as stable.^{12,16,19,53} A retrospective study identified significant hearing loss progression in 10 patients. The results demonstrated that in seven patients, the hearing loss was fluctuating; however, this fluctuation was only significant in young patients.⁵² A study reported that patients with an enlarged endolymphatic sac or duct had hearing thresholds significantly higher than in those patients without such abnormalities,⁵² which corroborates the study of Kemperman et al, 2001.¹³

In the literature, a description was found of three patients with BOR syndrome who also had cholesteatoma. In one of them, the cholesteatoma was in the temporal bone cavity, bilaterally, and showed no association with the facial nerve alterations. However, the other patients showed facial nerve alterations. One subject had facial nerve paralysis on the left side and in the other subject had right-side paralysis.^{16–18,54}

Cochlear implant in BOR syndrome was first used in a 3-year-old with congenital profound hearing loss and impaired language and speech development. Radiologic evaluation of the temporal bone and the inner ear showed severe dysplasia of the vestibule, ossicles, and bilaterally malformed semicircular canals and facial nerve posteriorly positioned. Three weeks after implantation, initial mapping showed positive responses. After hearing habilitation, the patient was able to recognize speech stimuli in a closed set.⁵⁵

Radiologic studies and magnetic resonance imaging of the mastoid and middle ear showed several types of middle and inner ear pathology, among them: (1) hypoplasia,

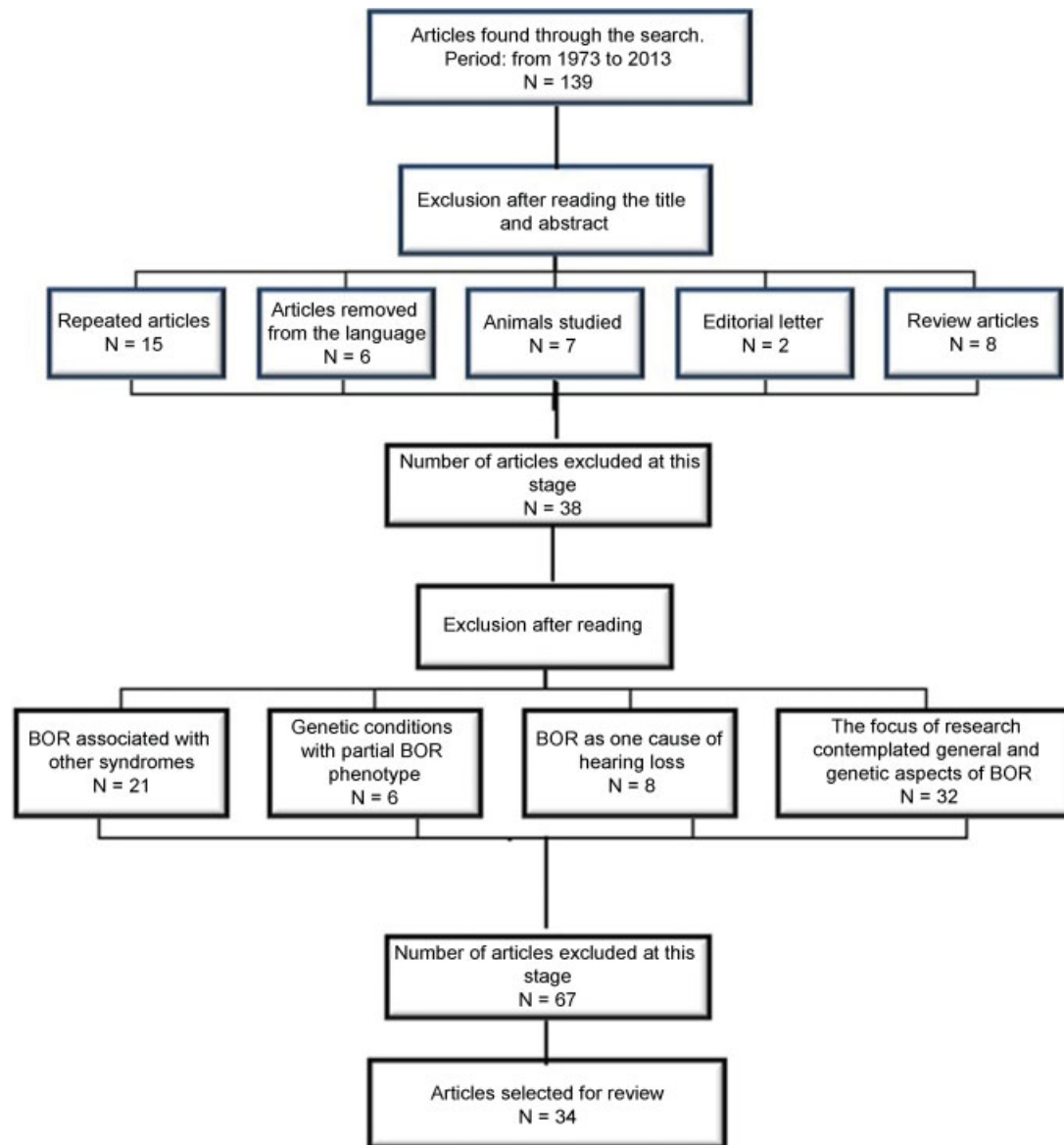


Fig. 1 Flowchart demonstrating the process of deleting articles. Abbreviation: BOR, branchio-oto-renal syndrome.

malformation and displacement of the ossicular chain, such as the junction of the hammer and anvil fixing the malleus in the tympanic membrane, and calcified oval window; (2) malformations—enlargement—and asymmetry of the semi-circular canals/ducts and endolymphatic sac; and (3) cochlear hypoplasia or dysplasia.^{6,7,14,49,50,53,56–58}

A study retrospectively assessed tomographic findings of 21 subjects (42 ears) with a clinical diagnosis of BOR syndrome, based on criteria derived from genotype and phenotype, and described the most common and easily identifiable features of BOR syndrome by visual inspection. The results of this assessment were: (1) apical cochlear hypoplasia was present in all individuals with BOR syndrome and no subject had normal hearing, (2) the facial nerve was diverted to the medial side of the cochlea in 38 of 42 ears, and (3) the inner ear channel was funnel-shaped in 36 of the 42 ears.⁵⁹

Discussion

The phenotypic features related to the most-mentioned anatomical ear alterations in BOR syndrome were: malformation; hyperplasia and low implantation of the ear; narrowing of the external acoustic meatus; ossicular chain abnormalities; reduced size of the middle ear cavity; otosclerosis; semicircular canal anomalies involving hypoplasia, dysplasia, and enlargement of the endolymphatic duct and sac; and cochlear hypoplasia.

The audiological profile, considering the type and degree of hearing loss and the association of the auditory system characteristics, is presented in ► **Table 3**.

The analysis of these studies showed that there was a high frequency of mixed hearing loss (33.72%) followed by sensorineural (10.98%) and conductive hearing loss (7.84%); however, in 47.45% of the articles, this information was not

Table 2 Summary of the reviewed articles' information

Article	Title	Author	Year	Sample
1	Familial branchio-oto-renal dysplasia: a new addition to the branchial arch syndromes.	Melnick et al ⁵	1976	<i>n</i> = 4 (two generations)
2	Genetic aspects of the BOR syndrome—branchial fistulas, ear pits, hearing loss, and renal anomalies	Fraser et al ⁶	1978	<i>n</i> = 8 (three generations)
3 ^a	The earpits-deafness syndrome. Clinical and genetic aspects	Creemers, Fikkers-Van Noord ⁷	1980	<i>n</i> = 19 (four families)
4	Temporal bone findings in a family with branchio-oto-renal syndrome (BOR)	Ostri et al ¹²	1991	<i>n</i> = 19 (four generations)
5	Branchio-oto-renal (BOR) syndrome: variable expressivity in a five-generation pedigree	König et al ²⁰	1994	<i>n</i> = 6 (four generations)
6	Phenotypic manifestations of branchio-oto-renal syndrome	Chen et al ¹⁹	1995	<i>n</i> = 32
7	Branchio-oto-renal syndrome	Millman et al ³⁸	1995	<i>n</i> = 1
8	Renal failure and deafness: branchio-oto-renal syndrome	Misra, Nolph ⁴³	1998	<i>n</i> = 1
9	Congenital cholesteatoma and malformations of the facial nerve: rare manifestations of the BOR syndrome	Graham et al ¹⁶	1999	<i>n</i> = 2
10	New' manifestations of BOR syndrome	Weber, Kousseff ³⁹	1999	<i>n</i> = 7
11	Bilateral congenital cholesteatoma in branchio-oto-renal syndrome	Worley et al ¹⁷	1999	<i>n</i> = 1
12	Branchio-oto-renal syndrome with generalized microdontia	Prabhu et al ⁴⁴	1999	<i>n</i> = 1
13	<i>EYA1</i> nonsense mutation in a Japanese branchio-oto-renal syndrome family	Usami et al ⁵⁴	1999	<i>n</i> = 3 (two generations)
14	Temporal bone computed tomography findings in bilateral sensorineural hearing loss	Bamiou et al ⁵⁵	2000	<i>n</i> = 3
15	Branchio-oto-renal syndrome: a report on nine family groups	Bellini et al ⁴²	2001	<i>n</i> = 10 (nine families)
16	The presence of a widened vestibular aqueduct and progressive sensorineural hearing loss in the branchio-oto-renal syndrome. A family study	Stinckens et al ¹⁴	2001	<i>n</i> = 12
17	Progressive fluctuant hearing loss, enlarged vestibular aqueduct, and cochlear hypoplasia in branchio-oto-renal syndrome	Kemperman et al ¹³	2001	<i>n</i> = 2 (two generations)
18	Visualization of inner ear dysplasias in patients with sensorineural hearing loss	Klingebl et al ⁵⁷	2001	<i>n</i> = 2
19	Inner ear anomalies are frequent but non-obligatory features of the branchio-oto-renal syndrome	Kemperman et al ⁵⁸	2002	<i>n</i> = 35 (six families)
20	A family with the branchio-oto-renal syndrome: clinical and genetic correlations	Pierides et al ⁴⁶	2002	<i>n</i> = 10 (two generations)
21	Temporal bone anomalies in the branchio-oto-renal syndrome: detailed computed tomographic and magnetic resonance imaging findings	Ceruti et al ¹⁵	2002	<i>n</i> = 8 (four generations)
22	Síndrome branquio-oto-renal y colesteatoma congénito	Adiego et al ¹⁸	2003	<i>n</i> = 1

Table 2 (Continued)

Article	Title	Author	Year	Sample
23	Evidence of progression and fluctuation of hearing impairment in branchio-oto-renal syndrome	Kemperman et al ⁵³	2004	<i>n</i> = 32 (six families)
24	Temporal bone findings on computed tomography imaging in branchio-oto-renal syndrome	Propst et al ⁵⁹	2005	<i>n</i> = 21
25 ^a	Non-inherited manifestation of bilateral branchial fistulae, bilateral pre-auricular sinuses and bilateral hearing loss: a variant of branchio-oto-renal syndrome	Rana et al ²³	2005	<i>n</i> = 1
26	Identification of a novel mutation in the <i>EYA1</i> gene in a Korean family with branchio-oto-renal (BOR) syndrome	Kim et al ⁴⁹	2005	<i>n</i> = 2 (two generations)
27	Cochlear implantation in branchio-oto-renal syndrome—a surgical challenge	Kameswaran et al ⁵⁶	2007	<i>n</i> = 1
28	Branchio-oto-renal syndrome	Garg et al ⁴⁷	2008	<i>n</i> = 1
29	Achados genéticos, audiológicos e da linguagem oral de um núcleo familiar com diagnóstico da síndrome Branquio-oto-renal (SBOR)	Furlan et al ⁵¹	2008	<i>n</i> = 7 (two generations)
30	From a branchial fistula to a branchiootorenal syndrome: a case report and review of the literature	Senel et al ⁵⁰	2009	<i>n</i> = 1
31	Mitral valve prolapse as a new finding in branchio-oto-renal syndrome	Ayçiçek et al ⁴⁵	2010	<i>n</i> = 1
32	Diagnostic and surgical challenge: middle ear dermoid cyst in 12 month old with branchio-oto-renal syndrome and multiple middle-ear congenital anomalies	Johnston et al ⁴⁰	2011	<i>n</i> = 1
33	Young woman with branchio-oto-renal syndrome and a novel mutation in the <i>EYA-1</i> gene	Nardi et al ⁴⁸	2011	<i>n</i> = 1
34	Congenital unilateral facial nerve palsy as an unusual presentation of BOR syndrome	Jankauskienė, Azukaitis ⁵²	2013	<i>n</i> = 1

^aSyndrome manifestation as a noninherited characteristic.

present. The degree of hearing loss was classified as moderate in 12.94% of the articles, mild in 6.66%, severe in 6.27%, and profound in 4.73%. This information was not present in 67.84% of the articles. Only 29.4% of the studies described the hearing loss pattern, which was classified as stable, progressive, or fluctuating.

Conclusion

Because hearing loss is mentioned in a great number of BOR syndrome studies. Deafness linked to preauricular fistula, branchial fistulae, and renal anomalies should be investigated and monitored by a multidisciplinary team, mainly otorhinolaryngologic professionals.

Due to the variable phenotypic expression described, many cases of BOR syndrome may have been underdiagnosed,

and sometimes the diagnosis is delayed, even in cases where the hearing impairment is severe and interferes with the development of language and speech.

This review shows that some aspects remain controversial due to syndrome variability and the difficulty of early diagnosis, especially in issues related to the audiological profile where there is a great variability in the auditory pattern and the hearing loss progression, type, and degree. Most studies described that mixed hearing loss is the most common type; however, there is no consensus about the degree.

In the 40 years of research on BOR syndrome, studies were aimed at characterization of the phenotype of this syndrome, and the hearing loss was mentioned as part of the phenotype; however, few specific studies characterize the hearing loss standard, type, and degree.

Table 3 Auditory system characteristics and description of hearing loss in BOR syndrome

Article	Type	Degree	Pattern	Anatomic changes: external, middle, and inner ear
Melnick et al ⁵	Mixed	–	–	Mondini-type cochlear malformation and stapes fixation
Fraser et al ⁶	Conductive/mixed	Mild to severe	Progressive	OC changes, ME fluid, otosclerosis
Cremers, Fikkers-Van Noord ⁷	Conductive/mixed/sensorineural	–	–	Cochlear hypoplasia/dysplasia, narrow or wide internal auditory canal, OC anomalies, horizontal SC with reduced size
Ostri et al ¹²	Mixed	Moderate to severe	Stable	Cochlear hypoplasia, SC hypoplasia and abnormal duct endolymphatic, massive OC and reduced size of ME
König et al ²⁰	Mixed	Severe	–	Malformation of OC
Chen et al ¹⁹	Conductive/mixed/sensorineural	Mild to profound	Progressive/stable	Stenosis of the EEC, malformation of OC, cochlear hypoplasia/dysplasia and enlargement of the endolymphatic duct
Millman et al ³⁸	–	Severe	–	–
Misra, Nolph ⁴³	Mixed	Moderate to severe	–	Changes in OC
Graham et al ¹⁶	Conductive	Moderate	Stable	Cholesteatoma, absence or abnormality of the ossicles and oval window, TM retraction
Weber, Kousseff ³⁹	Conductive/sensorineural	Mild to moderate	–	Otosclerosis
Worley et al ¹⁷	Mixed	Moderate	–	Cholesteatoma, OC anomalies, otitis media–ventilation tubes
Prabhu et al ⁴⁴	Mixed	–	–	Malformed and hyperplastic right pinna and a preauricular pit on the left ear
Usami et al ⁵⁴	Conductive/mixed	Mild to moderate	Stable	Cochlear hypoplasia of the lateral and posterior semicircular canal, abnormal OC, soft mass density in the epitympanic and mastoid cavity
Bamiou et al ⁵⁵	–	–	–	Mondini-type cochlear malformation
Bellini et al ⁴²	Conductive/mixed/sensorineural	–	–	–
Stinckens et al ¹⁴	Sensorineural	–	Progressive	Enlarged vestibular aqueduct, cochlear hypoplasia
Kemperman et al ¹³	Sensorineural	Profound	Progressive/fluctuant	Cochlear hypoplasia, enlarged vestibular aqueduct
Klingebiel et al ⁵⁷	–	–	–	Dysplasia of the SC superior, cochlear hypoplasia (1.5 turn)
Kemperman et al ⁵⁸	–	–	–	Enlarged vestibular aqueduct, hypoplastic cochleae and labyrinths, malformed auricles
Pierides et al ⁴⁶	–	–	Progressive	–
Ceruti et al ¹⁵	Sensorineural	–	Progressive	Cochlear hypoplasia/dysplasia, SC malformations, OC malformations
Adiego et al ¹⁸	Mixed	Moderate	–	EEC stenosis, cholesteatoma, OC malformation, cochlear hypoplasia, abnormal morphology of the SC
Kemperman et al ⁵³	–	–	Progressive/fluctuant	Enlarged vestibular aqueduct, medial deviation of facial nerve, cochlear hypoplasia
Propst et al ⁵⁹	–	–	–	Cochlear hypoplasia, narrowed internal auditory canal

Table 3 (Continued)

Article	Type	Degree	Pattern	Anatomic changes: external, middle, and inner ear
Rana et al ²³	–	–	–	Pneumatic temporal bone, partial agenesis of the EEC
Kim et al ⁴⁹	Mixed	Moderate to profound	–	EEC stenosis, dense mass in the mastoid and tympanic cavity, cochlear hypoplasia, enlarged vestibular aqueduct, OC malformation, otitis media
Kameswaran et al ⁵⁶	Sensorineural	Profound	–	Vestibular dysplasia, SC and ossicles malformation
Garg et al ⁴⁷	–	Moderate to profound	–	–
Furlan et al ⁵¹	Conductive/mixed	Mild to moderate to severe	–	–
Senel et al ⁵⁰	Conductive/mixed	Mild to moderate	–	EEC stenosis, auricular malformation, cochlear and SC hypoplasia, OC malformation
Ayçiçek et al ⁴⁵	–	–	–	EE and IE malformation
Johnston et al ⁴⁰	Mixed	Moderate to severe	–	Cochlear hypoplasia, OC malformation, enlarged vestibular aqueduct
Nardi et al ⁴⁸	–	–	–	Enlarged vestibular aqueduct
Jankauskienė, Azukaitis ⁵²	–	–	–	Uncertain results of otoacoustic emission and facial nerve paralysis at the RE

Abbreviations: EE, external ear; EEC, external ear canal; IE, inner ear; ME, middle ear; OC, ossicular chain; RE, right ear; SC, semicircular canals; TM, tympanic membrane.

References

- Ramos PZ, de Moraes VCS, Svidnicki MCM, Soki MN, Castilho AM, Sartorato EL. Etiologic and diagnostic evaluation: algorithm for severe to profound sensorineural hearing loss in Brazil. *Int J Audiol* 2013;1–7
- Kniffin CL. Branchiootorenal syndrome 1; BOR1. OMIM 2012. Available at: <http://omim.org/entry/113650>. Access date: 10/07/2013.
- Heusinger CF. Hals-Kiemen-Fisteln von noch nicht beobachteter form. *Virchows. Arch Path Anat* 1864;29:338–380
- Melnick M, Bixler D, Silk K, Yune H, Nance WE. Autosomal dominant branchiootorenal dysplasia. *Birth Defects Orig Artic Ser* 1975;11:121–128
- Melnick M, Bixler D, Nance WE, Silk K, Yune H. Familial branchio-oto-renal dysplasia: a new addition to the branchial arch syndromes. *Clin Genet* 1976;9:25–34
- Fraser FC, Ling D, Clogg D, Nogrady B. Genetic aspects of the BOR syndrome—branchial fistulas, ear pits, hearing loss, and renal anomalies. *Am J Med Genet* 1978;2:241–252
- Cremers CW, Flikkers-Van Noord M. The earpits-deafness syndrome. Clinical and genetic aspects. *Int J Pediatr Otorhinolaryngol* 1980;2:309–322
- Fraser FC, Aymé S, Halal F, Sproule J. Autosomal dominant duplication of the renal collecting system, hearing loss, and external ear anomalies: a new syndrome? *Am J Med Genet* 1983;14:473–478
- Smith RJH, Schwartz C. Branchio-oto-renal syndrome. *J Commun Disord* 1998;31:411–420, quiz 421
- Chang EH, Menezes M, Meyer NC, et al. Branchio-oto-renal syndrome: the mutation spectrum in *EYA1* and its phenotypic consequences. *Hum Mutat* 2004;23:582–589
- Fraser FC, Sproule JR, Halal F. Frequency of the branchio-oto-renal (BOR) syndrome in children with profound hearing loss. *Am J Med Genet* 1980;7:341–349
- Ostri B, Johnsen T, Bergmann I. Temporal bone findings in a family with branchio-oto-renal syndrome (BOR). *Clin Otolaryngol Allied Sci* 1991;16:163–167
- Kemperman MH, Stinckens C, Kumar S, Huygen PL, Joosten FB, Cremers CW. Progressive fluctuant hearing loss, enlarged vestibular aqueduct, and cochlear hypoplasia in branchio-oto-renal syndrome. *Otol Neurotol* 2001;22:637–643
- Stinckens C, Standaert L, Casselman JW, et al. The presence of a widened vestibular aqueduct and progressive sensorineural hearing loss in the branchio-oto-renal syndrome. A family study. *Int J Pediatr Otorhinolaryngol* 2001;59:163–172
- Ceruti S, Stinckens C, Cremers CW, Casselman JW. Temporal bone anomalies in the branchio-oto-renal syndrome: detailed computed tomographic and magnetic resonance imaging findings. *Otol Neurotol* 2002;23:200–207
- Graham GE, Allanson JE. Congenital cholesteatoma and malformations of the facial nerve: rare manifestations of the BOR syndrome. *Am J Med Genet* 1999;86:20–26
- Worley GA, Vats A, Harcourt J, Albert DM. Bilateral congenital cholesteatoma in branchio-oto-renal syndrome. *J Laryngol Otol* 1999;113:841–843
- Hernández Montero E, Adiego I, Clau F, Fraile J, Llorente E, Ortiz García A. Síndrome branquio-oto-renal y colesteatoma congénito. *O.R.L.-DIPS*. 2003;30:222–225
- Chen A, Francis M, Ni L, et al. Phenotypic manifestations of branchio-oto-renal syndrome. *Am J Med Genet* 1995;58:365–370
- König R, Fuchs S, Dukiet C. Branchio-oto-renal (BOR) syndrome: variable expressivity in a five-generation pedigree. *Eur J Pediatr* 1994;153:446–450

- 21 Stratakis CA, Lin J-P, Rennert OM. Description of a large kindred with autosomal dominant inheritance of branchial arch anomalies, hearing loss, and ear pits, and exclusion of the branchio-oto-renal (BOR) syndrome gene locus (chromosome 8q13.3). *Am J Med Genet* 1998;79:209–214
- 22 Mosrati MA, Hammami B, Rebeh IB, et al. A novel dominant mutation in *SIX1*, affecting a highly conserved residue, result in only auditory defects in humans. *Eur J Med Genet* 2011;54:e484–e488
- 23 Rana I, Dhawan R, Gudwani S, Bothra R, Mathur NN. Non-inherited manifestation of bilateral branchial fistulae, bilateral pre-auricular sinuses and bilateral hearing loss: a variant of branchio-oto-renal syndrome. *Indian J Otolaryngol Head Neck Surg* 2005;57:52–54
- 24 Ni L, Wagner MJ, Kimberling WJ, et al. Refined localization of the branchiootorenal syndrome gene by linkage and haplotype analysis. *Am J Med Genet* 1994;51:176–184
- 25 Abdelhak S, Kalatzis V, Heilig R, et al. A human homologue of the *Drosophila* eyes absent gene underlies branchio-oto-renal (BOR) syndrome and identifies a novel gene family. *Nat Genet* 1997;15:157–164
- 26 Vincent C, Kalatzis V, Abdelhak S, et al. BOR and BO syndromes are allelic defects of *EYA1*. *Eur J Hum Genet* 1997;5:242–246
- 27 Kumar S, Kimberling WJ, Kenyon JB, Smith RJH, Marres HA, Cremers CWRJ. Autosomal dominant branchio-oto-renal syndrome—localization of a disease gene to chromosome 8q by linkage in a Dutch family. *Hum Mol Genet* 1992;1:491–495
- 28 Ruf RG, Xu PX, Silvius D, et al. *SIX1* mutations cause branchio-oto-renal syndrome by disruption of *EYA1-SIX1*-DNA complexes. *Proc Natl Acad Sci U S A* 2004;101:8090–8095
- 29 Stockley TL, Mendoza-Londono R, Propst EJ, Sodhi S, Dupuis L, Papsin BC. A recurrent *EYA1* mutation causing alternative RNA splicing in branchio-oto-renal syndrome: implications for molecular diagnostics and disease mechanism. *Am J Med Genet A* 2009;149A:322–327
- 30 Rodríguez-Soriano J, Vallo A, Bilbao JR, Castaño L. Branchio-oto-renal syndrome: identification of a novel mutation in the *EYA1* gene. *Pediatr Nephrol* 2001;16:550–553
- 31 Vervoort VS, Smith RJH, O'Brien J, et al. Genomic rearrangements of *EYA1* account for a large fraction of families with BOR syndrome. *Eur J Hum Genet* 2002;10:757–766
- 32 Ito T, Noguchi Y, Yashima T, Kitamura K. *SIX1* mutation associated with enlargement of the vestibular aqueduct in a patient with branchio-oto syndrome. *Laryngoscope* 2006;116:796–799
- 33 Sanggaard KM, Rendtorff ND, Kjaer KW, et al. Branchio-oto-renal syndrome: detection of *EYA1* and *SIX1* mutations in five out of six Danish families by combining linkage, MLPA and sequencing analyses. *Eur J Hum Genet* 2007;15:1121–1131
- 34 Kochhar A, Orten DJ, Sorensen JL, et al. *SIX1* mutation screening in 247 branchio-oto-renal syndrome families: a recurrent missense mutation associated with BOR. *Hum Mutat* 2008;29:565
- 35 Krug P, Moriniere V, Marlin S, et al. Mutation screening of the *EYA1*, *SIX1* and *SIX5* genes in a large cohort of patients harboring branchio-oto-renal syndrome calls into question the pathogenic role of *SIX5* mutations. *Hum Mutat* 2011;32:183–190
- 36 Nie X, Sun J, Gordon RE, Cai CL, Xu PX. *SIX1* acts synergistically with *TBX18* in mediating ureteral smooth muscle formation. *Development* 2010;137:755–765
- 37 Gutierrez CB, Bardají C, Bento L, Martinez MA, Conde J. Branchio-oto-renal syndrome: incidence in three generations of a family. *J Pediatr Surg* 1993;28:1527–1529
- 38 Millman B, Gibson WS, Foster WP. Branchio-oto-renal syndrome. *Arch Otolaryngol Head Neck Surg* 1995;121:922–925
- 39 Weber KM, Kousseff BG. New manifestations of BOR syndrome. *Clin Genet* 1999;56:306–312
- 40 Johnston DR, Whittemore K, Poe D, Robson CD, Perez-Atayde AR. Diagnostic and surgical challenge: middle ear dermoid cyst in 12 month old with branchio-oto-renal syndrome and multiple middle-ear congenital anomalies. *Int J Pediatr Otorhinolaryngol* 2011;75:1341–1345
- 41 Preisch JW, Bixler D, Ellis FD. Gustatory lacrimation in association with the branchio-oto-renal syndrome. *Clin Genet* 1985;27:506–509
- 42 Bellini C, Piaggio G, Massocco D, et al. Branchio-oto-renal syndrome: a report on nine family groups. *Am J Kidney Dis* 2001;37:505–509
- 43 Misra M, Nolph KD. Renal failure and deafness: branchio-oto-renal syndrome. *Am J Kidney Dis* 1998;32:334–337
- 44 Prabhu NT, Alexander S, John R. Branchio-oto-renal syndrome with generalized microdontia: case report. *Oral Surg Oral Med Oral Pathol Oral Radiol Endod* 1999;87:180–183
- 45 Ayçiçek A, Sağlam H, Koçoğullari CU, Haktanir NT, Dereköy FS, Solak M. Mitral valve prolapse as a new finding in branchio-oto-renal syndrome. *Clin Dysmorphol* 2010;19:181–184
- 46 Pierides AM, Athanasiou Y, Demetriou K, Koptides M, Deltas CC. A family with the branchio-oto-renal syndrome: clinical and genetic correlations. *Nephrol Dial Transplant* 2002;17:1014–1018
- 47 Garg A, Wadhwa R, Gulati SP, Kumar A. Branchio-oto-renal syndrome. *J Assoc Physicians India* 2008;56:904–905
- 48 Nardi E, Palermo A, Cusimano P, Mulè G, Cerasola G. Young woman with branchio-oto-renal syndrome and a novel mutation in the *EYA1* gene. *Clin Nephrol* 2011;76:330–333
- 49 Kim SH, Shin JH, Yeo CK, et al. Identification of a novel mutation in the *EYA1* gene in a Korean family with branchio-oto-renal (BOR) syndrome. *Int J Pediatr Otorhinolaryngol* 2005;69:1123–1128
- 50 Senel E, Kocak H, Akbiyik F, Saylam G, Gulleroglu BN, Senel S. From a branchial fistula to a branchiootorenal syndrome: a case report and review of the literature. *J Pediatr Surg* 2009;44:623–625
- 51 Furlan RH, Rossi NF, Cardoso ACV, Richieri-Costa A, Motonaga SM, Giacheti CM. Achados genéticos, audiológicos e da linguagem oral de um núcleo familiar com diagnóstico da síndrome Branquio-oto-renal (SBOR). Paper presented at: XVI Congresso Brasileiro de Fonoaudiologia; September 24–27, 2008; Campos do Jordão, São Paulo, Brasil
- 52 Jankauskienė A, Azukaitis K. Congenital unilateral facial nerve palsy as an unusual presentation of BOR syndrome. *Eur J Pediatr* 2013;172:273–275
- 53 Kemperman MH, Koch SM, Kumar S, Huygen PL, Joosten FB, Cremers CW. Evidence of progression and fluctuation of hearing impairment in branchio-oto-renal syndrome. *Int J Audiol* 2004;43:523–532
- 54 Usami S, Abe S, Shinkawa H, Deffenbacher K, Kumar S, Kimberling WJ. *EYA1* nonsense mutation in a Japanese branchio-oto-renal syndrome family. *J Hum Genet* 1999;44:261–265
- 55 Bamiou DE, Phelps P, Sirimanna T. Temporal bone computed tomography findings in bilateral sensorineural hearing loss. *Arch Dis Child* 2000;82:257–260
- 56 Kameswaran M, Kumar RSA, Murali S, Raghunandhan S, Karthikeyan K. Cochlear implantation in branchio-oto-renal syndrome—a surgical challenge. *Indian J Otolaryngol Head Neck Surg* 2007;59:280–283
- 57 Klingebiel R, Bockmühl U, Werbs M, et al. Visualization of inner ear dysplasias in patients with sensorineural hearing loss. *Acta Radiol* 2001;42:574–581
- 58 Kemperman MH, Koch SM, Joosten FB, Kumar S, Huygen PL, Cremers CW. Inner ear anomalies are frequent but nonobligatory features of the branchio-oto-renal syndrome. *Arch Otolaryngol Head Neck Surg* 2002;128:1033–1038
- 59 Propst EJ, Blaser S, Gordon KA, Harrison RV, Papsin BC. Temporal bone findings on computed tomography imaging in branchio-oto-renal syndrome. *Laryngoscope* 2005;115:1855–1862