


# Treatment and Prevention of (Early) Osteoarthritis Using Articular Cartilage Repair—Fact or Fiction? A Systematic Review

Cartilage  
4(Suppl. 3) 5S–12S  
© The Author(s) 2013  
Reprints and permissions:  
sagepub.com/journalsPermissions.nav  
DOI: 10.1177/1947603513486560  
cart.sagepub.com  


Tommy S. de Windt<sup>1</sup>, Lucienne A. Vonk<sup>1</sup>, Mats Brittberg<sup>2</sup>  
and Daniel B.F. Saris<sup>1,3</sup>

## Abstract

Early osteoarthritis (OA) is increasingly being recognized in patients who wish to remain active while not accepting the limitations of conservative treatment or joint replacement. The aim of this systematic review was to evaluate the existing evidence for treatment of patients with early OA using articular cartilage repair techniques. A systematic search was performed in EMBASE, MEDLINE, and the Cochrane collaboration. Articles were screened for relevance and appraised for quality. Nine articles of generally low methodological quality (mean Coleman score 58) including a total of 502 patients (mean age range = 36–57 years) could be included. In the reports, both radiological and clinical criteria for early OA were applied. Of all patients included in this review, 75% were treated with autologous chondrocyte implantation. Good short-term clinical outcome up to 9 years was shown. Failure rates varied from 8% to 27.3%. The conversion to total knee arthroplasty rate was 2.5% to 6.5%. Although a (randomized controlled) trial in this patient category with long-term follow-up is needed, the literature suggests autologous chondrocyte implantation could provide good short- to mid-term clinical outcome and delay the need for total knee arthroplasty. The use of standardized criteria for early OA and implementation of (randomized) trials with long-term follow-up may allow for further expansion of the research field in articular cartilage repair to the challenging population with (early) OA.

## Keywords

early osteoarthritis, active patients, cartilage repair, autologous chondrocyte implantation

## Introduction

The general increase in sports-related injuries of the past decades and the high demands for fast and accurate treatment create one of the biggest challenges for the orthopedic surgeon of the 21st century. As such, early osteoarthritis (OA) is increasingly being recognized, creating an even bigger challenge for the field. Early OA is considered more difficult to diagnose than OA as signs and symptoms may still be limited, often becoming manifest after higher strains such as sport activities.<sup>1</sup> In contrast, the diagnosis of advanced OA is easily made based on the patient history and physical and X-ray examinations. Patients are typically over 50 years old and show symptoms of pain and decreased joint function, which in turn, reduces quality of life.<sup>2</sup> In early OA, the articular cartilage shows fibrillation and vertical fissures that extend into the mid-zone. The articular surface becomes discontinuous and there is progressive increase in subchondral bone plate and subarticular spongiosa.<sup>3</sup> The prevalence of (early) osteoarthritic defects in

patients with knee pain (mean age 39 years) has been approximated by Widuchowski *et al.*<sup>4</sup> Of 25,124 arthroscopies, 15,074 showed cartilage defects, 29% of which were osteoarthritic. Other structures such as the menisci and ligaments are frequently affected as well, thus disturbing the joint homeostasis.<sup>3,5</sup> As early OA generally presents in younger more active patients, traditional approaches for OA such as anti-inflammatory drugs and physical therapy may only provide temporary relief whereas joint

<sup>1</sup>Department of Orthopaedics University Medical Center Utrecht, Utrecht, Netherlands

<sup>2</sup>Cartilage Research Unit, University of Gothenburg, Region Halland Orthopaedics, Hallands Hospital Kungälv, Kungälv, Sweden

<sup>3</sup>MIRA Institute for Biotechnology and Technical Medicine, University of Twente, Enschede, Netherlands

### Corresponding Author:

Daniel B.F. Saris, Department of Orthopaedics, University Medical Center Utrecht, P.O. Box 85500, 3508 GA, Utrecht, Netherlands.  
Email: d.saris@umcutrecht.nl

replacement limits function and could be prone to future revision surgery.<sup>6-8</sup> Articular cartilage repair may be a promising treatment modality for early OA patients, potentially providing symptom relief and delaying or preventing disease progression. However, there is considerable debate whether cartilage repair is effective in this patient category as the disturbed homeostasis in early OA may create extra difficulty for local cellular regeneration. The aim of this systematic review was to evaluate the existing evidence for treatment of patients with early OA using articular cartilage repair techniques.

## Methods

### Systematic Search

A systematic review of the literature was conducted on treatment of early OA with articular cartilage repair. The search was performed on November 1, 2012 in the electronic databases of MEDLINE, EMBASE, and the Cochrane Collaboration using the following terms: (osteoarthritis) OR (early osteoarthritis) OR (moderate osteoarthritis) OR (early osteoarthrosis) OR (osteoarthritic) OR (early osteoarthritic changes) OR (early arthritis) OR (degenerative) OR (salvage) AND ((cartilage repair) OR (tissue engineering) OR (cartilage restoration) OR (autologous chondrocyte implantation) OR (autologous chondrocyte transplantation) OR (matrix-assisted autologous chondrocyte transplantation) OR (matrix-induced autologous chondrocyte implantation) OR (MACT) OR (MACI) OR (characterized chondrocyte implantation) OR (autologous osteochondral transplantation) OR (osteochondral autologous transplantation) OR (OATS) OR (osteochondral autograft transplantation) OR (OCT) OR (mosaicplasty) OR (allograft osteochondral transplantation) OR (scaffolds) OR (microfracture) OR (microfracturing).

### Literature

Inclusion criteria for relevant articles that were used during screening of titles and abstracts included: therapeutic studies of articular cartilage repair in patients with early osteoarthritis and/or degenerative changes with a minimal follow-up of 12 months. Languages that were included were English, German, and Dutch. Etiologic studies, reviews, case reports, animal and cadaver studies were excluded and also articles of which the full texts were not retrievable. The *Cochrane Handbook for Systematic Reviews*<sup>9</sup> and the guidelines for Transparent Reporting of Systematic Reviews and Meta-analysis (PRISMA)<sup>10</sup> were used. To assess the methodological quality, 2 independent observers (TdW and LV) appraised each study using the modified Coleman Methodology score.<sup>11</sup> A score of 100 represents a study with a solid design and no biases or

confounding factors. If there was a difference in scores, studies were discussed and a consensus was reached. Extracted data from the selected studies included patient demographics, grade of OA, surgical procedure(s), defect sizes, and clinical outcome scores.

## Results

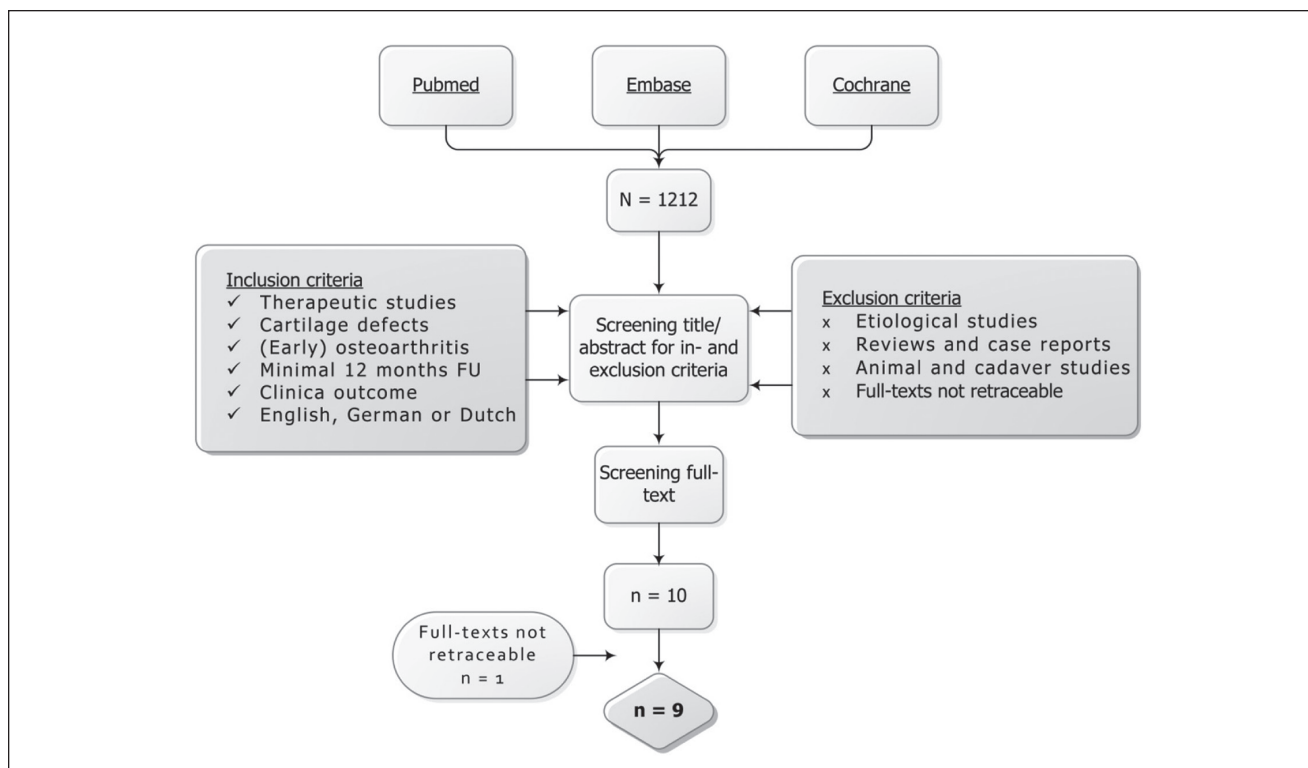
### Systematic Search and Study Appraisal

The literature search in MEDLINE resulted in 986 articles. The search in EMBASE and Cochrane resulted in 226 and 26 articles, respectively. After excluding duplicates, 1,212 articles remained for screening title and abstract. Application of inclusion and exclusion criteria resulted in 10 articles.<sup>12-21</sup> One full-text article<sup>22</sup> could not be retraced and was therefore excluded (**Fig. 1**). All included articles were case series reporting on a total of 502 patients (mean age range 36-57 years). One report presented the 4-year follow-up of a subset of patients from one of the included studies.<sup>18</sup> All studies were of level 4 evidence according to the Oxford Center for Evidence-Based Medicine and had a mean modified Coleman score of 58 (range = 36-73; **Table 1**).

### Literature

Minas *et al.*<sup>19</sup> performed a prospective study including 153 patients with early OA who were treated with first-generation ACI and followed for a mean of 64 months (range = 24-132 months). In this study, radiographic criteria for early OA were peripheral intra-articular osteophyte formation and/or 0% to 50% joint space narrowing as defined by Ahlbäck stage 0-I whereas the clinical criteria included evidence of bipolar (kissing) lesions or generalized chondromalacia. Concomitant procedures were performed in 103 (66.5%) patients (**Table 2**). At 5 years, 92% of patients experienced improvement in the WOMAC (Western Ontario and McMaster Universities Osteoarthritis Index) score ( $P < 0.001$ ) and were able to delay the need for joint replacement. Of the patients, 8% were considered treatment failures and were revised to partial ( $n = 2$ ) or total ( $n = 10$ ) joint arthroplasty (**Table 3**).

In 2 similar case series, Filardo *et al.*<sup>15,16</sup> evaluated 57 patients with degenerative grade III-IV ICRS (International Cartilage Repair Society) lesions (at least 6 months of symptoms not responding to conservative treatment) and 44 patients with cartilage lesions in OA knees (Kellgren-Lawrence grade 2-3) who had refused total knee arthroplasty (TKA). In the first study,<sup>15</sup> patients were treated with second-generation ACI and followed for a mean of 74 months. Concomitant procedures were performed in 23 patients (41%; **Table 2**). After 6 years, 85% of patients showed a significant improvement in the International Knee Documentation



**Figure 1.** Flowchart of the literature search.

**Table 1.** Study Design and Quality Assessment.

Authors	Design	Level of Evidence	Coleman
Minas <i>et al.</i> <sup>19</sup>	CS	4	73
Filardo <i>et al.</i> (2011) <sup>15</sup>	CS	4	60
Filardo <i>et al.</i> (2013) <sup>16</sup>	CS	4	60
Ossendorf <i>et al.</i> <sup>20</sup>	CS	4	64
Rosenberger <i>et al.</i> <sup>21</sup>	CS	4	72
Hollander <i>et al.</i> <sup>17</sup>	CS	4	36
Bae <i>et al.</i> <sup>12</sup>	CS	4	46
Brittberg <i>et al.</i> <sup>13</sup>	CS	4	54
De Windt <i>et al.</i> <sup>14</sup>	CS	4	60

Note: CS = case series; Coleman = modified Coleman score.

Committee (IKDC) score ( $P < 0.005$ ). Ten patients (18.5%) required reintervention because of symptoms related to the primary defect (**Table 3**). In the second study,<sup>16</sup> 44 patients received the same treatment (Hyalograft C) and were followed for up to 9 years. Of the patients, 55% received concomitant procedures. Although clinical improvement was shown (IKDC  $P < 0.0005$ ), the failure rate was higher than the previous study (27.3% vs. 18.5%; **Table 3**).

Ossendorf *et al.*<sup>20</sup> used second-generation ACI to treat 40 patients suffering from chronic posttraumatic and/or

degenerative cartilage lesions. Thirteen patients had early OA with a Jäger–Wirth<sup>23</sup> score of 3 whereas 27 patients had a Jäger–Wirth score of 1 to 2. The mean defect size was 5.0 cm<sup>2</sup> and the follow-up was 24 months (**Table 2**). Comparable clinical improvement (KOOS/IKDC  $P < 0.05$ ) in both the osteoarthritic and posttraumatic/mild degenerative groups was seen. Second-look biopsies of 4 patients showed hyaline-like and mixed repair tissues. At final follow-up, 22 patients had radiological OA (Kellgren–Lawrence<sup>24</sup> score  $\geq 2$ ) while still showing significant improvement ( $P < 0.0001$ ) in the Lysholm and Cincinnati Knee Rating Systems. The failure rate was 12.5%, and 2.5% required TKA (**Table 3**). Kreuz *et al.*<sup>18</sup> later presented the 4-year clinical improvement (Lysholm and KOOS  $P < 0.05$ ) of 19 patients of the cohort of Ossendorf *et al.*<sup>20</sup> who preoperatively had confirmed OA with a Kellgren–Lawrence score of  $\geq 2$ . MRI analysis showed defect filling in 16 out of these 19 patients.

In a case series of 56 patients aged  $\geq 45$  years, Rosenberger *et al.*<sup>21</sup> used first-generation ACI to treat 32 patients with large early osteoarthritic lesions (mean size 11.7 cm<sup>2</sup>). The same criteria for early OA as described by Minas *et al.*<sup>19</sup> were used. Thirty patients (53.6%) required a concomitant procedure (**Table 2**). Overall, patients rated their outcomes as excellent (72%) and comparable clinical improvement

**Table 2.** Study and Patient Characteristics.

Authors	Treatment	Previous Procedures <sup>a</sup> (%)	Concomitant Procedures	n	Mean Age (Years)	Mean Defect Size (cm <sup>2</sup> )	Follow-up (Months)	Lesion
Minas <i>et al.</i> <sup>19</sup>	ACI	90-100	Osteotomy (30.3%) Ligament reconstruction (2.6%) Patella realignment (28.3%) Meniscal allograft (4.6%)	153	38.3	4.9	64.2	Early OA
Filardo <i>et al.</i> (2011) <sup>15</sup>	ACI	78	Osteotomy (6.8%) Ligament reconstruction (15.5%) Meniscectomy (15.5%) Meniscal implants (6.9%)	58	34.7	2.3	74.4	Degenerative
Filardo <i>et al.</i> (2013) <sup>16</sup>	ACI	83%	Osteotomy (30%) Ligament reconstruction (6.8%) Patella realignment (4.5%) Meniscectomy (4.5%)	44	42	4.0	108	Early OA
Ossendorf <i>et al.</i> <sup>20</sup>	ACI	80-100	Osteotomy (25.0%) Ligament reconstruction (25.0%) Patella realignment (2.5%) Capsular shift (2.5%)	40	36.0	5.0	24	Early OA
Rosenberger <i>et al.</i> <sup>21</sup>	ACI	90-100	Osteotomy (21.4%) Ligament reconstruction (3.6%) Patella realignment (25.0%) Meniscal allograft (1.8%)	56	48.8	11.7	50.6	Degenerative
Hollander <i>et al.</i> <sup>17</sup> Bae <i>et al.</i> <sup>12</sup>	ACI MF	62 N/A	N/A Partial meniscectomy (75.0%) Bilateral MF (6.8%)	23 44	35.6 57.0	5.0 3.9	14.9 27.6	Early OA Early OA
Brittberg <i>et al.</i> <sup>13</sup> De Windt <i>et al.</i> <sup>14</sup>	CF CF	100 46-85	N/A Osteotomy (18.9%) Meniscectomy (38.3%)	37 47	39.0 47.0	5.6 2.7	48 32	Early OA Early OA

Note: ACI = autologous chondrocyte implantation; N/A = not applicable; MF = microfracture; CF = carbon fibers.

<sup>a</sup>Previous procedures: debridement, chondroplasty, marrow stimulation, ligament reconstruction, and meniscectomy.

**Table 3.** Outcomes of the Included Studies.

Authors	Procedure	Clinical Outcome	Failure rate (%)	Conversion to TKA (%)
Minas et al. <sup>19</sup>	ACI	WOMAC $P < 0.001$	8.0	6.5
Filardo et al. (2011) <sup>15</sup>	ACI	IKDC $P < 0.005$	18.5	N/A
Filardo et al. (2013) <sup>16</sup>	ACI	IKDC $P < 0.005$	27.3	N/A
Ossendorf et al. <sup>20</sup>	ACI	Lysholm/IKDC/KOOS $P < 0.05$	12.5	2.5
Rosenberger et al. <sup>21</sup>	ACI	WOMAC/Cincinnati $P < 0.001$	9.0	5.4
Hollander et al. <sup>17</sup>	ACI	IKDC improvement $\geq 90\%$	N/A	N/A
Bae et al. <sup>12</sup>	MF	Daily living and pain $P < 0.05$	0.0	N/A
Brittberg et al. <sup>13</sup>	CF	VAS/Tegner $P < 0.001$	N/A	N/A
De Windt et al. <sup>14</sup>	CF	VAS/KOOS/Lysholm $P < 0.005$	14.9	N/A

Note: TKA = total knee arthroplasty; ACI = autologous chondrocyte implantation; WOMAC = Western Ontario and McMaster Universities Osteoarthritis Index; IKDC = International Knee Documentation Committee Knee Examination Form; KOOS = Knee Injury and Osteoarthritis Outcome Score; Cincinnati = Cincinnati Knee Rating System; MF = Microfracture; CF = carbon fibers; VAS = Visual Analogue Scale; Tegner = Tegner Activity Scale; N/A = not applicable.

was seen for all defect categories, that is, simple, complex, and salvage. Both failure of treatment and conversion to TKA occurred in 3 patients (9%; **Table 3**).

Hollander et al.<sup>17</sup> compared second-look biopsies from 14 ACI patients with no X-ray signs of OA (Ahlbäck<sup>25</sup> score 0) and 9 patients with X-ray signs of OA (Ahlbäck score III-IV). After 1 year, the repair tissue showed hyaline cartilage in 67% of OA joints compared with 36% of non-OA joints. Two out of 3 biopsies from patients with advanced OA (Ahlbäck IV) showed hyaline cartilage.

Bae et al.<sup>12</sup> evaluated 44 patients with an average lesion size of 3.9 cm<sup>2</sup> (range = 1-6 cm<sup>2</sup>, Outerbridge grade IV) with moderate osteoarthritic changes who underwent microfracture (MF; **Table 2**). After a mean of 2.3 years, significant improvement ( $P < 0.05$ ) in pain and daily living was seen and 95% of patients were rated good to excellent (**Table 3**). In addition, using second-look arthroscopy, defect filling was determined which was confirmed with histologic evaluation and type II collagen staining.

Brittberg et al.<sup>13</sup> and de Windt et al.<sup>14</sup> used drilling and subsequent carbon fiber scaffold implantation for treatment of early osteoarthritic defects in 2 separate cohorts with a short-term success rate of more than 80% in terms of pain and clinical outcome (**Tables 2 and 3**). All patients had ICRS grade III-IV lesions and fulfilled the criteria for symptomatic OA by the Subcommittee of the American College of Rheumatology.

## Discussion

Early OA is increasingly being recognized in patients who wish to remain active while not accepting the limitations of conservative treatment or joint replacement. As such, the research field in articular cartilage repair is extending its grounds, aiming at early treatment and prevention of

disease progression. This review evaluated the literature that describes the use of cartilage repair procedures in patients with early OA. After application of inclusion and exclusion criteria, 9 articles of generally low methodological quality (mean Coleman score 58) could be included.<sup>12-17,19-21</sup> The low methodological quality and heterogeneity in patient populations is a known limitation of clinical research in cartilage repair.<sup>26,27</sup> This heterogeneity may even be more profound in early OA, as these patients frequently have been subjected to multiple previous and/or concomitant procedures.<sup>6</sup> In fact, in the included studies, 46% to 100% of patients received a previous treatment for to the index knee and up to 67% of patients underwent concomitant procedures (**Table 2**). The use of concomitant treatments in this patient category does not seem to have a negative effect on clinical outcome as no substantial differences in outcome were reported. This is surprising, as it is thought that concurrent injuries can disturb joint homeostasis.<sup>5,28</sup> For example, anterior cruciate ligament and meniscal tears are known to be a risk factor for OA.<sup>29-34</sup> Indeed, in one of the included studies by Filardo et al.,<sup>16</sup> inferior outcome in knees with previous or combined partial meniscectomy was found. Moreover, numerous studies have found correlation between time since symptom onset and clinical outcome, suggesting a disturbance in joint homeostasis could affect cartilage regeneration.<sup>35-39</sup>

The combined treatment of articular cartilage defects and malalignment is increasingly being applied and shows promising results.<sup>40</sup> Bauer et al.<sup>41</sup> demonstrated significant clinical improvement in 18 patients (mean age = 47 years) with medial knee OA receiving matrix-induced ACI and a high tibial osteotomy. Sterett et al.<sup>42</sup> found a 91% survivorship 7 years after combined high tibial osteotomy and MF in 106 patients. Twelve patients (11%) required TKA after a mean of 81 months. In our review, we found a conversion



to TKA rate of 2.5% to 6.5% for ACI (**Table 3**). This is encouraging, as the conversion rates for isolated osteotomy has been found to be higher (20% to 50%).<sup>43-45</sup> It should be acknowledged, however, that only a randomized controlled trial would be able to distinguish between the effect of cartilage repair and realignment osteotomy.

Of all patients included in this review, 75% were treated with ACI. This is not surprising, as in general, ACI is preferred in larger and complex lesions and clinical outcome after MF may have the tendency to deteriorate over time.<sup>46-49</sup> Indeed several *in vitro* studies<sup>50-52</sup> have shown good proliferation of OA chondrocytes and recently, ACI showed superior macroscopic and histological results compared to cell-free approaches in an early OA model *in vivo*.<sup>53</sup> While Bae *et al.*<sup>12</sup> used MF to treat cartilage defects in early OA, no patients underwent previous procedures and the mean defect size was smaller (3.9 cm<sup>2</sup>) than in most studies (**Table 2**). Kaul *et al.*<sup>54</sup> recently showed that tissue removed prior to TKA in failed MF patients with early OA consisted of fibrocartilaginous tissue. This could imply that the quality of the regenerative tissue is an important prognostic factor. However, as Brittberg *et al.*<sup>13</sup> and de Windt *et al.*<sup>14</sup> also demonstrated clinical improvement using marrow stimulation, long-term (comparative) research is needed to determine if regenerative tissue quality affects clinical outcome in early OA.

Although a study aiming specifically at osteochondral autograft or allograft transfer for early OA could not be included, these procedures may well be an option for future clinical trials in this patient category. Hangody *et al.*<sup>55</sup> performed osteochondral autograft transfer in 82 professional athletes including those with early signs of OA and found similar success rates compared with that of less athletic patients, although high motivation resulted in better subjective evaluation. Osteochondral allograft transfer has successfully been applied in young patients with steroid-induced osteonecrosis showing 90% graft survival at 6 years.<sup>56</sup> At their last follow-up, TKA was avoided in 27 out of 28 knees. In contrast, Beaver *et al.*<sup>57</sup> found a higher failure rate for posttraumatic osteoarticular bipolar lesions treated with fresh allografts. Furthermore, primary OA has been reported to reduce clinical outcome after allograft transfer.<sup>45</sup>

Limitations of this review are the low methodological quality, small sample sizes, and heterogeneity of patients. Although the inclusion criteria were strictly aimed at early OA, the variation in the definition of early OA may also limit the findings of this review. Minas *et al.*<sup>19</sup>, Rosenberger *et al.*,<sup>21</sup> and Hollander *et al.*<sup>17</sup> primarily used the radiographic Ahlbäck score whereas Ossendorf *et al.*<sup>20</sup> and Kreuz *et al.*<sup>18</sup> used the Jäger–Wirth scale. All others applied clinical and macroscopic grading only. In recognizing and defining early OA as a disease entity, the Osteoarthritis Research Society International histologic histochemical grading system was recently adapted aiming specifically at early OA.<sup>3</sup> The development and use of such a standardized

radiological and clinical grading system could especially be important for the comparability between (future) clinical trials in early OA.

The excellent clinical outcome (up to 4 years) in a small subset of patients with advanced OA as shown by Ossendorf *et al.*<sup>20</sup> and Kreuz *et al.*<sup>18</sup> as well as hyaline-like regeneration shown in biopsies by Hollander *et al.*<sup>17</sup> are promising findings, which could imply that cartilage repair can be an alternative for active patients with advanced OA. Furthermore, the comparable failure rates in early OA compared with the general population, that is, 8% to 27.3%<sup>12-17,19-21</sup> versus 1.5% to 33%,<sup>58</sup> respectively, underline the potential of cartilage repair as a salvage procedure. However, it is important to note that Filardo *et al.*<sup>15,16</sup> found a relatively high failure rate, which increased for the longer follow-up. Although they still consider ACI as an option to delay joint replacement, these findings stress the importance of careful treatment selection and patient counseling.

In considering TKA as an alternative for younger patients with OA, Keeney *et al.*<sup>59</sup> performed a systematic review and found surgeon-measured clinical improvement in patients younger than 55 years who had received TKA. In this study, a moderate increase in second decade implant failures (from 91% to 99% implant survival to 85% to 97%) was found. Unfortunately, a lack of patient-based and functional outcome measures as well as the difference in patient selection makes these results difficult to compare with the results of this review. Thus, a (randomized) comparison between TKA, cartilage repair, and/or conservative measures for early OA could be of great value. Nevertheless, revisions and the known limitations in activity following TKA emphasize the need for different treatment options in active patients with (early) OA.<sup>60,61</sup>

In conclusion, although not yet a fact, there is low-level evidence that suggests cartilage repair is a feasible treatment for (early) OA, which demonstrates preliminary effectiveness of up to 9 years. Although a (randomized controlled) trial in this patient category with long-term follow-up is needed, the literature suggests ACI could provide short- to mid-term clinical outcome and delay the need for TKA. The use of standardized criteria for early OA and implementation of (randomized) trials with long-term follow-up may allow for further expansion of the research field in articular cartilage repair to the challenging population with (early) OA.

### Acknowledgments and Funding

The author(s) received no financial support for the research, authorship, and/or publication of this article.

### Declaration of Conflicting Interests

The author(s) declared no potential conflicts of interest with respect to the research, authorship, and/or publication of this article.

## Ethical Approval

This study was approved by our institutional review board.

## References

- Luyten FP, Denti M, Filardo G, Kon E, Engebretsen L. Definition and classification of early osteoarthritis of the knee. *Knee Surg Sports Traumatol Arthrosc.* 2012;20(3):401-6.
- Woolf AD, Pfleger B. Burden of major musculoskeletal conditions. *Bull World Health Organ.* 2003;81(9):646-56.
- Madry H, Luyten FP, Facchini A. Biological aspects of early osteoarthritis. *Knee Surg Sports Traumatol Arthrosc.* 2012;20(3):407-22.
- Widuchowski W, Widuchowski J, Trzaska T. Articular cartilage defects: study of 25,124 knee arthroscopies. *Knee.* 2007;14(3):177-82.
- Saris DB, Dhert WJ, Verbout AJ. Joint homeostasis. The discrepancy between old and fresh defects in cartilage repair. *J Bone Joint Surg Br.* 2003;85(7):1067-76.
- Gomoll AH, Filardo G, de Girolamo L, Espregueira-Mendes J, Marcacci M, Rodkey WG, et al. Surgical treatment for early osteoarthritis. Part I: cartilage repair procedures. *Knee Surg Sports Traumatol Arthrosc.* 2012;20(3):450-66.
- Moseley JB, O'Malley K, Petersen NJ, Menke TJ, Brody BA, Kuykendall DH, et al. A controlled trial of arthroscopic surgery for osteoarthritis of the knee. *N Engl J Med.* 2002;347(2):81-8.
- Kirkley A, Birmingham TB, Litchfield RB, Giffin JR, Willits KR, Wong CJ, et al. A randomized trial of arthroscopic surgery for osteoarthritis of the knee. *N Engl J Med.* 2008;359(11):1097-107.
- Higgins JP, and Green S, editors. *Cochrane handbook for systematic reviews of interventions.* Version 5.1.0. Oxford, UK: The Cochrane Collaboration; 2011.
- Moher D, Liberati A, Tetzlaff J, Altman DG. Preferred reporting items for systematic reviews and meta-analyses: the PRISMA statement. *BMJ.* 2009;339:b2535.
- Coleman BD, Khan KM, Maffulli N, Cook JL, Wark JD. Studies of surgical outcome after patellar tendinopathy: clinical significance of methodological deficiencies and guidelines for future studies. *Victorian Institute of Sport Tendon Study Group. Scand J Med Sci Sports.* 2000;10(1):2-11.
- Bae DK, Yoon KH, Song SJ. Cartilage healing after microfracture in osteoarthritic knees. *Arthroscopy.* 2006;22(4):367-74.
- Brittberg M, Faxén E, Peterson L. Carbon fiber scaffolds in the treatment of early knee osteoarthritis. A prospective 4-year follow-up of 37 patients. *Clin Orthop Relat Res.* 1994;(307):155-64.
- de Windt TS, Concaro S, Lindahl A, Saris DB, Brittberg M. Strategies for patient profiling in articular cartilage repair of the knee: a prospective cohort of patients treated by one experienced cartilage surgeon. *Knee Surg Sports Traumatol Arthrosc.* 2012;20(11):2225-32.
- Filardo G, Kon E, Di Martino A, Patella S, Altadonna G, Balboni F, et al. Second-generation arthroscopic autologous chondrocyte implantation for the treatment of degenerative cartilage lesions. *Knee Surg Sports Traumatol Arthrosc.* 2011;20(9):1704-13.
- Filardo G, Vannini F, Marcacci M, Andriolo L, Ferruzzi A, Giannini S, et al. Matrix-assisted autologous chondrocyte transplantation for cartilage regeneration in osteoarthritic knees: results and failures at midterm follow-up. *Am J Sports Med.* 2013;41(1):95-100.
- Hollander AP, Dickinson SC, Sims TJ, Brun P, Cortivo R, Kon E, et al. Maturation of tissue engineered cartilage implanted in injured and osteoarthritic human knees. *Tissue Eng.* 2006;12(7):1787-98.
- Kreuz PC, Muller S, Ossendorf C, Kaps C, Erggelet C. Treatment of focal degenerative cartilage defects with polymer-based autologous chondrocyte grafts: four-year clinical results. *Arthritis Res Ther.* 2009;11(2):R33.
- Minas T, Gomoll AH, Solhpour S, Rosenberger R, Probst C, Bryant T. Autologous chondrocyte implantation for joint preservation in patients with early osteoarthritis. *Clin Orthop Relat Res.* 2010;468(1):147-57.
- Ossendorf C, Kaps C, Kreuz PC, Burmester GR, Sittinger M, Erggelet C. Treatment of posttraumatic and focal osteoarthritic cartilage defects of the knee with autologous polymer-based three-dimensional chondrocyte grafts: 2-year clinical results. *Arthritis Res Ther.* 2007;9(2):R41.
- Rosenberger RE, Gomoll AH, Bryant T, Minas T. Repair of large chondral defects of the knee with autologous chondrocyte implantation in patients 45 years or older. *Am J Sports Med.* 2008;36(12):2336-44.
- Andres BM, Mears SC, Somel DS, Klug R, Wenz JF. Treatment of osteoarthritic cartilage lesions with osteochondral autograft transplantation. *Orthopedics.* 2003;26(11):1121-6.
- Scheller G, Sobau C, Bulow JU. Arthroscopic partial lateral meniscectomy in an otherwise normal knee: Clinical, functional, and radiographic results of a long-term follow-up study. *Arthroscopy.* 2001;17(9):946-52.
- Kellgren JH, Lawrence JS. Radiological assessment of osteoarthritis. *Ann Rheum Dis.* 1957;16(4):494-502.
- Ahlbäck S. Osteoarthritis of the knee. A radiographic investigation. *Acta Radiol Diagn (Stockh).* 1968;Suppl 277:7-72.
- Jakobsen RB, Engebretsen L, Slauterbeck JR. An analysis of the quality of cartilage repair studies. *J Bone Joint Surg Am.* 2005;87(10):2232-9.
- Worthen J, Waterman BR, Davidson PA, Lubowitz JH. Limitations and sources of bias in clinical knee cartilage research. *Arthroscopy.* 2012;28(9):1315-25.
- Heijink A, Gomoll AH, Madry H, Drobnic M, Filardo G, Espregueira-Mendes J, et al. Biomechanical considerations in the pathogenesis of osteoarthritis of the knee. *Knee Surg Sports Traumatol Arthrosc.* 2012;20(3):423-35.
- Daniel DM, Stone ML, Dobson BE, Fithian DC, Rossman DJ, Kaufman KR. Fate of the ACL-injured patient. A prospective outcome study. *Am J Sports Med.* 1994;22(5):632-44.
- Kannus P, Jarvinen M. Posttraumatic anterior cruciate ligament insufficiency as a cause of osteoarthritis in a knee joint. *Clin Rheumatol.* 1989;8(2):251-60.
- Maletius W, Messner K. Eighteen- to twenty-four-year follow-up after complete rupture of the anterior cruciate ligament. *Am J Sports Med.* 1999;27(6):711-7.
- Papalia R, Del BA, Osti L, Denaro V, Maffulli N. Meniscectomy as a risk factor for knee osteoarthritis: a systematic review. *Br Med Bull.* 2011;99:89-106.
- Stein V, Li L, Lo G, Guermazi A, Zhang Y, Kent KC, et al. Pattern of joint damage in persons with knee osteoarthritis and concomitant ACL tears. *Rheumatol Int.* 2012;32(5):1197-208.

34. Von PA, Roos EM, Roos H. High prevalence of osteoarthritis 14 years after an anterior cruciate ligament tear in male soccer players: a study of radiographic and patient relevant outcomes. *Ann Rheum Dis.* 2004;63(3):269-73.
35. de Windt TS, Bekkers JE, Creemers LB, Dhert WJ, Saris DB. Patient profiling in cartilage regeneration: prognostic factors determining success of treatment for cartilage defects. *Am J Sports Med.* 2009;37(Suppl 1):58S-62S.
36. Krishnan SP, Skinner JA, Bartlett W, Carrington RW, Flanagan AM, Briggs TW, *et al.* Who is the ideal candidate for autologous chondrocyte implantation? *J Bone Joint Surg Br.* 2006;88(1):61-4.
37. Mithoefer K, Williams RJ III, Warren RF, Wickiewicz TL, Marx RG. High-impact athletics after knee articular cartilage repair: a prospective evaluation of the microfracture technique. *Am J Sports Med.* 2006;34(9):1413-8.
38. Saris DB, Vanlauwe J, Victor J, Almqvist KF, Verdonk R, Bellemans J, *et al.* Treatment of symptomatic cartilage defects of the knee: characterized chondrocyte implantation results in better clinical outcome at 36 months in a randomized trial compared to microfracture. *Am J Sports Med.* 2009;37(Suppl 1):10S-19S.
39. Vanlauwe J, Saris DB, Victor J, Almqvist KF, Bellemans J, Luyten FP. Five-year outcome of characterized chondrocyte implantation versus microfracture for symptomatic cartilage defects of the knee: early treatment matters. *Am J Sports Med.* 2011;39(12):2566-74.
40. Brouwer RW, van Raaij TM, Bierma-Zeinstra SM, Verhagen AP, Jakma TS, Verhaar JA. Osteotomy for treating knee osteoarthritis. *Cochrane Database Syst Rev.* 2007;(3):CD004019.
41. Bauer S, Khan RJ, Ebert JR, Robertson WB, Bredahl W, Ackland TR, *et al.* Knee joint preservation with combined neutralising high tibial osteotomy (HTO) and matrix-induced autologous chondrocyte implantation (MACI) in younger patients with medial knee osteoarthritis: a case series with prospective clinical and MRI follow-up over 5 years. *Knee.* 2012;19(4):431-9.
42. Sterett WI, Steadman JR, Huang MJ, Matheny LM, Briggs KK. Chondral resurfacing and high tibial osteotomy in the varus knee: survivorship analysis. *Am J Sports Med.* 2010;38(7):1420-4.
43. Billings A, Scott DF, Camargo MP, Hofmann AA. High tibial osteotomy with a calibrated osteotomy guide, rigid internal fixation, and early motion. Long-term follow-up. *J Bone Joint Surg Am.* 2000;82(1):70-9.
44. Coventry MB, Ilstrup DM, Wallrichs SL. Proximal tibial osteotomy. A critical long-term study of eighty-seven cases. *J Bone Joint Surg Am.* 1993;75(2):196-201.
45. Gomoll AH, Filardo G, Almqvist FK, Bugbee WD, Jelic M, Monllau JC, *et al.* Surgical treatment for early osteoarthritis. Part II: allografts and concurrent procedures. *Knee Surg Sports Traumatol Arthrosc.* 2012;20(3):468-86.
46. Harris JD, Siston RA, Pan X, Flanagan DC. Autologous chondrocyte implantation: a systematic review. *J Bone Joint Surg Am.* 2010;92(12):2220-33.
47. Kon E, Gobbi A, Filardo G, Delcogliano M, Zaffagnini S, Marcacci M. Arthroscopic second-generation autologous chondrocyte implantation compared with microfracture for chondral lesions of the knee: prospective nonrandomized study at 5 years. *Am J Sports Med.* 2009;37(1):33-41.
48. Ossendorf C, Steinwachs MR, Kreuz PC, Osterhoff G, Lahm A, Ducommun PP, *et al.* Autologous chondrocyte implantation (ACI) for the treatment of large and complex cartilage lesions of the knee. *Sports Med Arthrosc Rehabil Ther Technol.* 2011;3:11.
49. Zaslav K, Cole B, Brewster R, DeBerardino T, Farr J, Fowler P, *et al.* A prospective study of autologous chondrocyte implantation in patients with failed prior treatment for articular cartilage defect of the knee: results of the Study of the Treatment of Articular Repair (STAR) clinical trial. *Am J Sports Med.* 2009;37(1):42-55.
50. Cavallo C, Desando G, Facchini A, Grigolo B. Chondrocytes from patients with osteoarthritis express typical extracellular matrix molecules once grown onto a three-dimensional hyaluronan-based scaffold. *J Biomed Mater Res A.* 2010;93(1):86-95.
51. Dehne T, Karlsson C, Ringe J, Sittlinger M, Lindahl A. Chondrogenic differentiation potential of osteoarthritic chondrocytes and their possible use in matrix-associated autologous chondrocyte transplantation. *Arthritis Res Ther.* 2009;11(5):R133.
52. Tallheden T, Bengtsson C, Brantsing C, Sjögren-Jansson E, Carlsson L, Peterson L, *et al.* Proliferation and differentiation potential of chondrocytes from osteoarthritic patients. *Arthritis Res Ther.* 2005;7(3):R560-8.
53. Schinhan M, Gruber M, Dorotka R, Pilz M, Stelzeneder D, Chiari C, *et al.* Matrix-associated autologous chondrocyte transplantation in a compartmentalized early stage of osteoarthritis. *Osteoarthritis Cartilage* 2013;21(1):217-25.
54. Kaul G, Cucchiari M, Remberger K, Kohn D, Madry H. Failed cartilage repair for early osteoarthritis defects: a biochemical, histological and immunohistochemical analysis of the repair tissue after treatment with marrow-stimulation techniques. *Knee Surg Sports Traumatol Arthrosc.* 2012;20(11):2315-24.
55. Hangody L, Dobos J, Balo E, Panics G, Hangody LR, Berkes I. Clinical experiences with autologous osteochondral mosaicplasty in an athletic population: a 17-year prospective multicenter study. *Am J Sports Med.* 2010;38(6):1125-33.
56. Gortz S, De Young AJ, Bugbee WD. Fresh osteochondral allografting for steroid-associated osteonecrosis of the femoral condyles. *Clin Orthop Relat Res.* 2010;468(5):1269-78.
57. Beaver RJ, Mahomed M, Backstein D, Davis A, Zukor DJ, Gross AE. Fresh osteochondral allografts for post-traumatic defects in the knee. A survivorship analysis. *J Bone Joint Surg Br.* 1992;74(1):105-10.
58. Harris JD, Siston RA, Brophy RH, Lattermann C, Carey JL, Flanagan DC. Failures, re-operations, and complications after autologous chondrocyte implantation—a systematic review. *Osteoarthritis Cartilage.* 2011;19(7):779-91.
59. Keeney JA, Eunice S, Pashos G, Wright RW, Clohisy JC. What is the evidence for total knee arthroplasty in young patients? A systematic review of the literature. *Clin Orthop Relat Res.* 2011;469(2):574-83.
60. Bisschop R, Brouwer RW, van Raay JJ. Total knee arthroplasty in younger patients: a 13-year follow-up study. *Orthopedics.* 2010;33(12):876.
61. Odland AN, Callaghan JJ, Liu SS, Wells CW. Wear and lysis is the problem in modular TKA in the young OA patient at 10 years. *Clin Orthop Relat Res.* 2011;469(1):41-7.