

## SHORT REPORT

# An AP4B1 frameshift mutation in siblings with intellectual disability and spastic tetraplegia further delineates the AP-4 deficiency syndrome

Hengameh Abdollahpour<sup>1,7</sup>, Malik Alawi<sup>2,3,4</sup>, Fanny Kortüm<sup>1</sup>, Michael Beckstette<sup>3</sup>, Eva Seemanova<sup>5</sup>, Vladimír Komárek<sup>6</sup>, Georg Rosenberger<sup>1</sup> and Kerstin Kutsche<sup>\*,1</sup>

The recently proposed adaptor protein 4 (AP-4) deficiency syndrome comprises a group of congenital neurological disorders characterized by severe intellectual disability (ID), delayed or absent speech, hereditary spastic paraplegia, and growth retardation. AP-4 is a heterotetrameric protein complex with important functions in vesicle trafficking. Mutations in genes affecting different subunits of AP-4, including *AP4B1*, *AP4E1*, *AP4S1*, and *AP4M1*, have been reported in patients with the AP-4 deficiency phenotype. We describe two siblings from a non-consanguineous couple who presented with severe ID, absent speech, microcephaly, growth retardation, and progressive spastic tetraplegia. Whole-exome sequencing in the two patients identified the novel homozygous 2-bp deletion c.1160\_1161delCA (p.(Thr387Argfs\*30)) in *AP4B1*. Sanger sequencing confirmed the mutation in the siblings and revealed it in the heterozygous state in both parents. The *AP4B1*-associated phenotype has previously been assigned to spastic paraplegia-47. Identification of a novel *AP4B1* alteration in two patients with clinical manifestations highly similar to other individuals with mutations affecting one of the four AP-4 subunits further supports the observation that loss of AP-4 assembly or functionality underlies the common clinical features in these patients and underscores the existence of the clinically recognizable AP-4 deficiency syndrome.

*European Journal of Human Genetics* (2015) 23, 256–259; doi:10.1038/ejhg.2014.73; published online 30 April 2014

## INTRODUCTION

A group of congenital neurological diseases characterized by severe intellectual disability (ID), absence of speech, and early-onset progressive spasticity leading to spastic para- or tetraplegia has recently been associated with deficiency of different adaptor protein 4 (AP-4) complex subunits.<sup>1</sup> AP-4 belongs to a family of adaptor proteins consisting of the five heterotetramers AP-1 to AP-5, which have key functions in vesicle trafficking.<sup>2,3</sup> APs are composed of two large subunits ( $\beta$ 1–5, and either  $\alpha$ ,  $\gamma$ ,  $\delta$ ,  $\epsilon$ , or  $\zeta$ ), one medium subunit ( $\mu$ 1–5), and one small subunit ( $\sigma$ 1–5), and these mediate different cellular transport steps. The ubiquitously expressed AP-4 complex is composed of the four subunits *AP4B1* ( $\beta$ 1), *AP4E1* ( $\epsilon$ 1), *AP4M1* ( $\mu$ 1), and *AP4S1* ( $\sigma$ 1) and has a role in trafficking of proteins from the *trans* Golgi network to endosomes.<sup>4,5</sup> Mutations in genes encoding different subunits of the AP-4 complex have been associated with autosomal-recessive ID with spastic paraplegia: A homozygous splice site mutation in *AP4M1* was found in family members affected by early infantile hypotonia, delayed psychomotor development, inability to walk independently, absent speech, progressive spasticity, and severe ID (MIM 612936).<sup>6</sup> In two siblings with spastic paraplegia cerebral palsy with profound ID, microcephaly, epilepsy, and white matter loss, a homozygous microdeletion covering part of the *AP4E1*

gene has been identified (MIM 613744).<sup>7</sup> Abou Jamra *et al*<sup>1</sup> and Najmabadi *et al*<sup>8</sup> described homozygous mutations of *AP4B1* (MIM 614066), *AP4S1* (MIM 614067), *AP4E1*, and *AP4M1* in individuals with severe ID, growth retardation, stereotypic laughter, progressive spasticity, and inability to walk as the core phenotype. Two Arabic siblings with hereditary spastic paraplegia (HSP), ID, and seizures<sup>9</sup> were found to carry the homozygous c.664delC mutation in *AP4B1*.<sup>10</sup> Thinning of the corpus callosum has been proposed to be a key feature of the AP-4-associated HSP.<sup>6,7,10</sup> Identification of a homozygous *AP4E1* nonsense mutation in twins with HSP and mycobacterial disease suggests a role of the AP-4 complex not only in the neurological but also in the immunological system.<sup>11</sup> Taken together, the common clinical features in patients with mutations in different subunits of the AP-4 complex indicate that loss of one subunit results in severely impaired complex formation leading to the AP-4 deficiency syndrome.<sup>1,2</sup> The function of the AP-4 adaptor complex in endosomal trafficking highlights a novel biological mechanism underlying an HSP type associated with severe ID.<sup>12</sup>

Here we report a homozygous 2-bp deletion in *AP4B1* in two siblings with severe ID, microcephaly, growth retardation, inability to walk, and absent speech, confirming the common phenotype associated with AP-4 deficiency.

<sup>1</sup>Institute of Human Genetics, University Medical Center Hamburg-Eppendorf, Hamburg, Germany; <sup>2</sup>University Medical Center Hamburg-Eppendorf, Bioinformatics Service Facility, Hamburg, Germany; <sup>3</sup>Center for Bioinformatics, University of Hamburg, Hamburg, Germany; <sup>4</sup>Heinrich-Pette-Institute, Leibniz-Institute for Experimental Virology, Virus Genomics, Hamburg, Germany; <sup>5</sup>Department of Clinical Genetics, Institute of Biology and Medical Genetics, University Hospital Motol, Second Medical School, Charles University Prague, Prague, Czech Republic; <sup>6</sup>Department of Pediatric Neurology, Charles University, Second Faculty of Medicine, Motol Hospital, Prague, Czech Republic

<sup>7</sup>Current address: MVZ genteQ GmbH, Hamburg, Germany.

\*Correspondence: Professor K Kutsche, Institute of Human Genetics, University Medical Center Hamburg-Eppendorf, Martinstraße 52, 20246 Hamburg, Germany. Tel: +49 40 7410 54597; Fax: +49 40 7410 55138; Email: kkutsche@uke.de

Received 10 December 2013; revised 4 March 2014; accepted 7 March 2014; published online 30 April 2014

## SUBJECTS AND METHODS

### Case reports

The study was approved by the Ethics Committee of the Medical Chamber of Hamburg (No. PV3802). Written consent was obtained from the parents of patients 1 and 2, including consent to use the photographs in this report.

Patient 1 is a 14-year-old girl (Figure 1a and Table 1) born to non-consanguineous healthy parents. She was born by natural delivery after medical induction at 41 weeks of gestation; birth weight was 4000 g, length was 52 cm, and occipitofrontal circumference (OFC) was 34 cm. Apgar scores were 10–10–10; there were no perinatal complications. At the age of 3 months, psychomotor developmental delay was noticed. The girl was microcephalic (–2 s.d.) at the age of 1 year. At 18 months of age, she began to speak a few words. The propositus started to walk at the age of 20 months. At the age of 3.5 years, the patient was admitted to hospital because of duplicated ureter, urosepsis, pelvic duplex, and febrile seizure. Three years later she experienced another episode of febrile seizure, which was controlled by antiepileptic treatment. The patient was referred to one of us (ES) when she was almost 4 years old. She could walk only short distances and spoke short sentences. Microcephaly (–2 s.d.) and increased tonus of lower limbs were observed. Recent clinical examination at the age of 14 years revealed microcephaly (–2 s.d.), short stature (–2 s.d.), club foot, skin hyperpigmentation on the lumbar region, and low anterior and posterior hairline. The patient had spastic tetraplegia with contractures, particularly of the lower limbs, hyperreflexia, and positive Babinski sign; she had been wheelchair-bound since the age of 12 years. Pelvis X-ray revealed valgosity of the hips with bilateral subluxation and acetabular dysplasia. Otologic and ophthalmologic evaluations were normal, similar to conventional and molecular karyotyping as well as biochemical serum and urine tests. She had facial dysmorphism with tongue protrusion, open mouth, widely spaced teeth, gingival hyperplasia, prominent supraorbital ridges, and a broad nasal root. The patient had a shy and anxious character and had been communicating nonverbally since the age of 13 years; she never had stereotypic laughter. She was able to control urinary and anal sphincters and eat without assistance. Electroencephalography (EEG) evaluations revealed a generalized abnormality with a low-frequency brain activity, especially in the centroparietal region. Brain magnetic resonance imaging (MRI) did not show any abnormality.

Patient 2 (Figure 1b and Table 1) is the 12-year-old brother of patient 1. Birth was by cesarean section at 41 weeks of gestation because of suspected fetal stress. However, postpartal adaptation was normal with Apgar scores 9–10–10. Birth weight was 3500 g, length was 50 cm, and OFC was 34 cm. Apathetic behaviour was noticed at the age of 3 months. His psychomotor development was delayed: he could walk at the age of 18 months, spoke his first words at the age of 24 months, and had a very short attention span. Physical examination at the age of 2 years showed microcephaly and psychomotor developmental delay. Mild spasticity of lower extremities was noticed with hyperreflexia and Babinski sign. He was able to walk until the age of 7.5 years, after which he could walk only with assistance and had been wheelchair-dependent since the age of 12. At the age of 10 years, the Achilles

tendon on the right side was operated upon because of club foot. Shortly after, febrile convulsions occurred, which led to antiepileptic therapy. X-ray investigation of the hips revealed coxa valga with acetabular dysplasia. Facial dysmorphism was noted with large auricles, synophrys, open mouth, tongue protrusion, prominent nasal root, and mild convergent strabismus. He had a more severe ID than his sister, with very short attention span and inability to communicate. Additional clinical findings were spastic tetraplegia with contractures of the knees, thoracic dextroscoliosis, and lumbar levoscoliosis. He had hyperpigmentation on the right shoulder. He had a shy and anxious character and no history of stereotypic laughter. Latest examination at the age of 12 years revealed mild microcephaly (–2 s.d.) and short stature (–2 s.d.). EEG findings were identical to those of his sister. MRI of the brain revealed mild thinning of the corpus callosum in the dorsal region of the splenium.

### Whole exome sequencing (WES) and data analysis

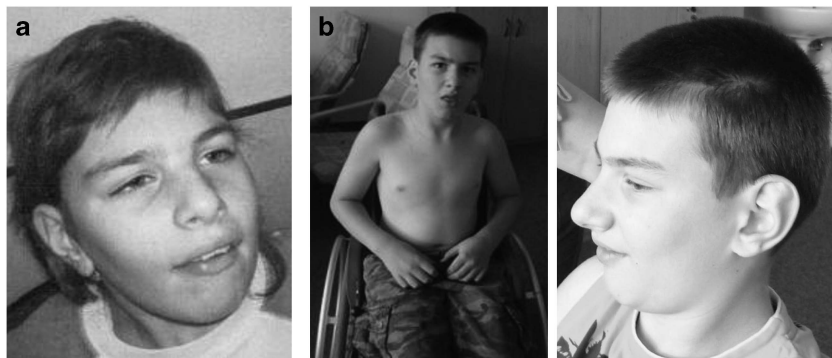
For detailed description of the WES and Sanger sequencing procedures, see Supplementary Methods.

## RESULTS

We performed WES on genomic DNA of patients 1 and 2 and on their mother and filtered for compound heterozygous and homozygous sequence variants in the siblings. No compound heterozygous mutation was identified; however, we detected a 2-bp deletion, c.1160\_1161delCA, in the *AP4B1* gene (RefSeq NM\_006594.2) in two patients in the homozygous state (Figure 2). Sanger sequencing confirmed the homozygous c.1160\_1161delCA mutation in exon 7 of *AP4B1* in the siblings, whereas both parents were heterozygous (Figure 2). This variant was not found in the databases dbSNP, 1000Genomes, and Exome Variant Server. The *AP4B1* variant c.1160\_1161delCA identified in this study was submitted to the ClinVar database with the accession number SCV000119895 (<http://www.ncbi.nlm.nih.gov/clinvar/?term=SCV000119895>). *AP4B1* mutations have already been linked to an autosomal recessive form of ID with spastic paraplegia (spastic paraplegia-47, MIM 614066), which fits well to the phenotype of the siblings. Thus, we concluded that the homozygous frameshift mutation in *AP4B1* underlies the neurological disorder in both patients.

## DISCUSSION

We performed WES in two siblings with severe ID, microcephaly, growth retardation, inability to walk, and absent speech, and detected the homozygous 2-bp deletion c.1160\_1161delCA in the *AP4B1* gene. This mutation results in a frameshift and in the introduction of a premature termination codon (p.(Thr387Argfs\*30)). Both parents were heterozygous for the *AP4B1* mutation. To date, two other mutations in the *AP4B1* gene have been identified in individuals with



**Figure 1** Photographs of the sister and brother with a homozygous *AP4B1* mutation. (a) The 14-year-old girl shows an open mouth, prominent supraorbital ridges, and a broad nasal root. (b) Her 12-year-old brother is wheelchair-bound. He has facial dysmorphism with large auricles, synophrys, open mouth, and a prominent nasal root.

**Table 1 Clinical features of patients with *AP4B1* mutations**

Patient	IV-2 <sup>a</sup>	IV-4 <sup>a</sup>	IV-5 <sup>a</sup>	P1 <sup>b</sup>	P2 <sup>b</sup>	P1 <sup>c</sup>	P2 <sup>c</sup>
<i>AP4B1</i> mutation	<i>c.487_488insTAT</i> ( <i>p.Glu163Valfs*2</i> )			<i>c.664delC</i> ( <i>p.Leu222Cysfs*31</i> )		<i>c.1160_1161delCA</i> ( <i>p.Thr387Argfs*30</i> )	
Age at last examination	23 y	15 y	11 y	5 y 6 m	4 y 10 m	14 y	12 y
Head circumference	-2 s.d.	-2.5 s.d.	-3 s.d.	2nd cen	< -2 s.d.	-2 s.d.	-2 s.d.
Short stature	+	+	+	nd	nd	+ (-2 s.d.)	+ (-2 s.d.)
Facial dysmorphism	+	+	+	-	-	+	+
Severe ID	+	+	+	+	+	+	+
Epilepsy/seizures	-	-	-	Febrile seizures	Febrile seizures	Febrile seizures	-
Shy character	+	+	-	nd	nd	+	+
Stereotypic laughter	+	+	+	nd	nd	-	-
Speech	Marked delay	Marked delay	Marked delay	Two-word utterances	No speech, but vocalization	Spoke short sentences, non-verbal communication since age 12 y	
Neonatal hypotonia	+	+	+	+	+	nd	nd
Progression to hypertonia	+	+	+	+	+	+	+
MRI findings	nd	nd	nd	Ventriculomegaly, thin and short corpus callosum	Loss of periventricular white matter, thin corpus callosum	-	thin corpus callosum
Hyperreflexia	+	+	+	+	+	+	+
Babinski sign	+	-	+	nd	nd	+	+
Spasticity	+	+	+	+	+	+	+
Foot deformity	Pes Planus	Pes Planus	Pes Planus	nd	nd	Club foot	Club foot
Walk independently	At 2.5 y	At 2.5 y	At 2.5 y	With walker at age 30 m	-	At 20 m	At 18 m
Ambulation	Wheelchair	+	Wheelchair	Walker	Wheelchair	Wheelchair	Wheelchair

Abbreviations: +, present; -, absent; cen, centile; ID, intellectual disability; m, months; nd, no data; s.d., standard deviation; y, years.

<sup>a</sup>Published in Abou Jamra *et al.*<sup>1</sup>

<sup>b</sup>Published in Blumkin *et al.*<sup>9</sup> and Bauer *et al.*<sup>10</sup>

<sup>c</sup>This report.

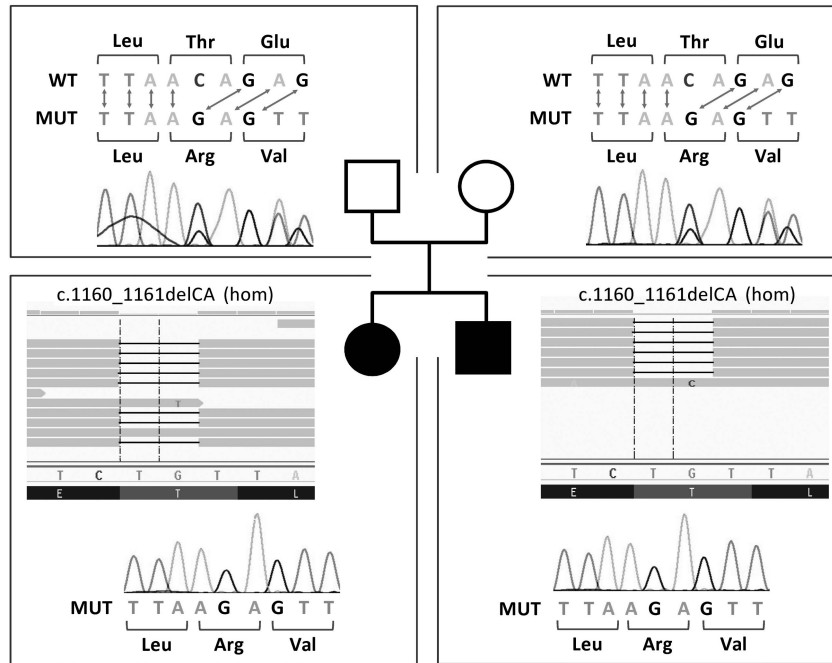
a congenital neurological disorder (Table 1): the homozygous 3-bp insertion *c.487\_488insTAT* (*p.(Glu163Valfs\*2)*) is the correct description of the mutation at the protein level<sup>1</sup> and the 1-bp deletion *c.664delC* (*p.(Leu222Cysfs\*31)*) is the correct description.<sup>10</sup> Remarkably, the three known sequence-level alterations in *AP4B1* are small rearrangements and most likely represent loss-of-function mutations. This is in agreement with drastically reduced *Ap4b1* transcript levels in fibroblast cells of a patient with the *c.487\_488insTAT* mutation indicating nonsense-mediated mRNA decay.<sup>1</sup> Thus, loss of one AP-4 subunit results in defective AP-4 complex formation leading to impaired endosomal trafficking, especially in the neuronal system.

*AP4B1* encodes the  $\beta 1$  subunit of the AP-4 complex, which together with AP-1, AP-2, AP-3, and AP-5 constitutes the adaptor protein family. AP complexes 1–5 are transiently transported onto membranes, where they function as coat proteins to select cargo and shape vesicles. These proteins are ubiquitously expressed in human tissues and have an essential role in vesicle trafficking.<sup>2</sup> Mutations in genes that code for different subunits of adaptor protein complexes have been described in human disorders. Mutations in *AP1S1* and *AP1S2* encoding  $\sigma$  subunits of the AP-1 complex have been found in patients with MEDNIK syndrome (mental retardation, enteropathy, deafness, neuropathy, ichthyosis, keratoderma) and an X-linked ID syndrome, respectively.<sup>13–17</sup> The autosomal recessive Hermansky–Pudlak syndrome 2, which is characterized by platelet defects and oculocutaneous albinism, is caused by mutations in the *AP3B1* gene encoding the  $\beta 1$  subunit of the AP-3 complex.<sup>18</sup> Remarkably, heterozygous missense mutations of *AP2S1* substituting arginine 15 underlie the familial hypocalcaemic hypercalcaemia type 3.<sup>19</sup> The severe neurological phenotype in patients with mutations affecting components of the AP-4 complex suggests that AP-4 has an important role in human brain development. Indeed, in *Ap4b1*-deficient mice the

somatodendritically localized low-density lipoprotein receptor, AMPA, and  $\delta 2$  glutamate receptors were mislocalized in axons, underscoring a function of the AP-4 complex in polarized sorting of these receptors to the somatodendritic domain of neurons.<sup>20</sup> However, *Ap4b1*-null mice have an almost normal brain and no neurological defects were seen in this mouse model,<sup>20</sup> indicating important and non-redundant functions of the AP-4 complex in the human brain.

The phenotype of *AP4B1*-mutation-positive individuals is quite similar (Table 1). Microcephaly became obvious at the age of 1 year and developed to -2 to -3 s.d. later in life. Where data were available, short stature was present. All individuals had significant psychomotor developmental delay that developed to severe ID; seizures can occur. Five of seven patients could walk independently, and one with assistance. Increased tonus of the lower limbs was noticed between the ages of 2 and 5 years. Spastic para- or tetraplegia with contractures and hyperreflexia was present between the ages of 10 and 14 years. Patients became wheelchair-dependent around the age of 12 years. Marked speech delay or absent speech was noticed in the patients. Brain imaging revealed periventricular white matter changes in two and thinning of the corpus callosum in three individuals; no MRI data were available for three siblings.<sup>1</sup> The phenotype associated with *AP4B1* mutations has been assigned the formal hereditary spastic paraplegia type 47 (SPG47) entry.<sup>10,12</sup> A thin corpus callosum could likely give a clue to SPG47 and has also been observed in patients harbouring mutations in *AP4M1* or *AP4E1*.<sup>6,7</sup>

In summary, the similar clinical features in patients with mutations affecting different AP-4 subunits underscore the existence of the recognizable AP-4 deficiency syndrome. The phenotype is characterized by microcephaly, severe ID with delayed or absent speech, progressive spasticity leading to wheelchair dependence in early adolescence, and growth retardation. Loss of AP-4 complex



**Figure 2** Whole-exome sequencing (WES) and Sanger sequencing revealed the homozygous *AP4B1* mutation c.1160\_1161delCA (p.(Thr387Argfs\*30)) in the two affected siblings. Pedigree of the family with two affected children is shown in the centre. WES identified the 2 bp deletion c.1160\_1161delCA in the *AP4B1* gene in both patients (lower boxes). Sequence data are visualized using the Integrated Genomics Viewer) showing the negative strand with complement nucleotides and reverse complement translations. Parts of the Sanger sequencing electropherograms showing the negative strand with complement nucleotides and reverse complement translations. Parts of the Sanger sequencing electropherograms showing the negative strand with complement nucleotides and reverse complement translations. The *AP4B1* mutation is present in both parents in the heterozygous state. Electropherograms show the Sanger sequencing results, and the sequences of wild-type (WT) and mutant (MUT) alleles are given (upper boxes). Encoded amino acids are indicated in the three-letter code. hom: homozygous.

assembly and functionality in patients with either *AP4M1*, *E1*, *S1*, or *B1* mutations is thus the common pathogenetic mechanism underlying the AP-4 deficiency phenotype.

### CONFLICT OF INTEREST

The authors declare no conflict of interest.

### ACKNOWLEDGEMENTS

We are grateful to the family for their interest and participation in this study. We thank Maja Hempel for critical reading of the manuscript. This work was supported by grants of the Deutsche Forschungsgemeinschaft (KU 1240/5-1 to KK, RO 3660/1-1 to GR and KO 4576/1-1 to FK).

- Najmabadi H, Hu H, Garshasbi M *et al*: Deep sequencing reveals 50 novel genes for recessive cognitive disorders. *Nature* 2011; **478**: 57–63.
- Blumkin L, Lerman-Sagie T, Lev D, Yosovich K, Leshinsky-Silver E: A new locus (SPG47) maps to 1p13.2-1p12 in an Arabic family with complicated autosomal recessive hereditary spastic paraplegia and thin corpus callosum. *J Neurol Sci* 2011; **305**: 67–70.
- Bauer P, Leshinsky-Silver E, Blumkin L *et al*: Mutation in the *AP4B1* gene cause hereditary spastic paraplegia type 47 (SPG47). *Neurogenetics* 2012; **13**: 73–76.
- Kong XF, Bousfiha A, Rouissi A *et al*: A novel homozygous p.R1105X mutation of the *AP4E1* gene in twins with hereditary spastic paraplegia and mycobacterial disease. *PLoS One* 2013; **8**: e58286.
- Fink JK: Hereditary spastic paraplegia: clinico-pathologic features and emerging molecular mechanisms. *Acta Neuropathol* 2013; **126**: 307–328.
- Borck G, Molla-Herman A, Boddaert N *et al*: Clinical, cellular, and neuropathological consequences of *AP1S2* mutations: further delineation of a recognizable X-linked mental retardation syndrome. *Hum Mutat* 2008; **29**: 966–974.
- Cacciagli P, Desvignes JP, Girard N *et al*: *AP1S2* is mutated in X-linked Dandy-Walker malformation with intellectual disability, basal ganglia disease and seizures (Pettigrew syndrome). *Eur J Hum Genet* 2013; **22**: 363–368.
- Montpetit A, Cote S, Brusteijn E *et al*: Disruption of *AP1S1*, causing a novel neurocutaneous syndrome, perturbs development of the skin and spinal cord. *PLoS Genet* 2008; **4**: e1000296.
- Saillour Y, Zanni G, Des Portes V *et al*: Mutations in the *AP1S2* gene encoding the sigma 2 subunit of the adaptor protein 1 complex are associated with syndromic X-linked mental retardation with hydrocephalus and calcifications in basal ganglia. *J Med Genet* 2007; **44**: 739–744.
- Tarpey PS, Stevens C, Teague J *et al*: Mutations in the gene encoding the Sigma 2 subunit of the adaptor protein 1 complex, *AP1S2*, cause X-linked mental retardation. *Am J Hum Genet* 2006; **79**: 1119–1124.
- Dell'Angelica EC, Shotelersuk V, Aguilar RC, Gahl WA, Bonifacino JS: Altered trafficking of lysosomal proteins in Hermansky-Pudlak syndrome due to mutations in the beta 3A subunit of the AP-3 adaptor. *Mol Cell* 1999; **3**: 11–21.
- Nesbit MA, Hannan FM, Howles SA *et al*: Mutations in *AP2S1* cause familial hypocalcaemic hypercalcaemia type 3. *Nat Genet* 2013; **45**: 93–97.
- Matsuda S, Miura E, Matsuda K *et al*: Accumulation of AMPA receptors in autophagosomes in neuronal axons lacking adaptor protein AP-4. *Neuron* 2008; **57**: 730–745.

- Abou Jamra R, Philippe O, Raas-Rothschild A *et al*: Adaptor protein complex 4 deficiency causes severe autosomal-recessive intellectual disability, progressive spastic paraplegia, shy character, and short stature. *Am J Hum Genet* 2011; **88**: 788–795.
- Hirst J, Irving C, Borner GH: Adaptor protein complexes AP-4 and AP-5: new players in endosomal trafficking and progressive spastic paraplegia. *Traffic* 2013; **14**: 153–164.
- McNiven MA, Thompson HM: Vesicle formation at the plasma membrane and trans-Golgi network: the same but different. *Science* 2006; **313**: 1591–1594.
- Dell'Angelica EC, Mullins C, Bonifacino JS: AP-4, a novel protein complex related to clathrin adaptors. *J Biol Chem* 1999; **274**: 7278–7285.
- Hirst J, Bright NA, Rous B, Robinson MS: Characterization of a fourth adaptor-related protein complex. *Mol Biol Cell* 1999; **10**: 2787–2802.
- Verkerk AJ, Schot R, Dumee B *et al*: Mutation in the *AP4M1* gene provides a model for neuroaxonal injury in cerebral palsy. *Am J Hum Genet* 2009; **85**: 40–52.
- Moreno-De-Luca A, Helmers SL, Mao H *et al*: Adaptor protein complex-4 (AP-4) deficiency causes a novel autosomal recessive cerebral palsy syndrome with microcephaly and intellectual disability. *J Med Genet* 2011; **48**: 141–144.

Supplementary Information accompanies this paper on European Journal of Human Genetics website (<http://www.nature.com/ejhg>)