

# Prosthetic Rehabilitation of Hypophosphatasia with Precision Attachment Retained Unconventional Partial Denture: A Case Report

GAYATRI SHEENA SUVARNA<sup>1</sup>, RAMESH KHANDURAO NADIGER<sup>2</sup>, SATYABODH SHESHARAJ GUTTAL<sup>3</sup>, OMKAR SHETTY<sup>4</sup>

## ABSTRACT

Deficiency of the alkaline phosphatase isoenzyme can lead to a rare hereditary disorder called Hypophosphatasia. It is characterized by defective mineralization of the skeletal and dental structures of the body. Hypophosphatasia is classified into six clinical forms namely, perinatal lethal, perinatal benign, infantile, childhood, adult and odontohypophosphatasia. This clinical report describes the prosthetic rehabilitation of an 18-year-old girl with Hypophosphatasia with partial anodontia and no occlusion. A precision attachment retained unconventional removable partial denture in the maxillary arch and conventional removable partial denture in the mandibular were fabricated to establish an acceptable masticatory function, speech, occlusion and aesthetics for the patient.

**Keywords:** Hypophosphatasia, Odontohypophosphatasia, Precision attachment, Removable partial denture

## CASE REPORT

An 18-year-old girl reported with a chief complaint of missing teeth, poor oral hygiene and inability to eat. She desired aesthetic replacement of the missing teeth [Table/Fig-1]. Patient gave a history of early exfoliation of deciduous teeth due to caries and mobility. The permanent dentition erupted normally but there was gradual loss due to caries and mobility of some of the permanent teeth in both upper and lower arches of the jaws. On recording medical history it was noted that the patient suffered from chronic and severe vomiting, poor feeding, anorexia and constipation. Family history revealed parents, siblings and grandparents were healthy and did not show any signs of unusual tooth exfoliation.

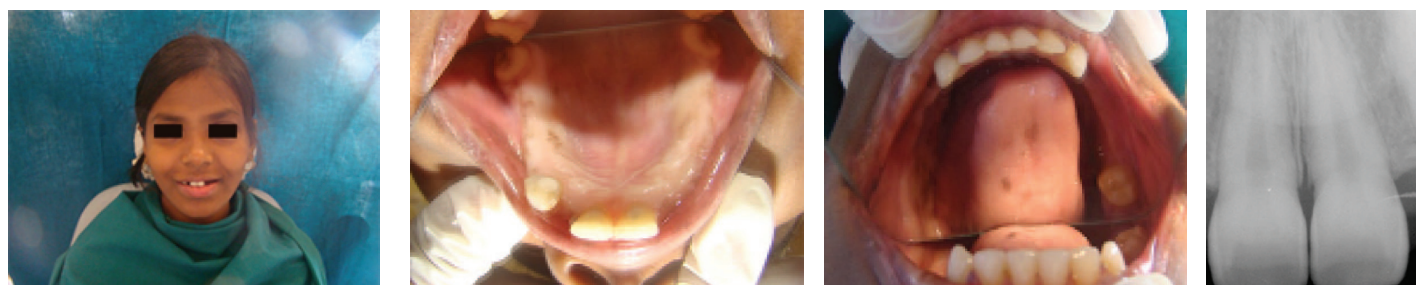Intra oral examination revealed the presence of 11, 21, 13 and 17 and 27 in the maxillary arch [Table/Fig-2] and 31, 32, 33, 41, 42, 43 and 47 in the mandibular arch [Table/Fig-3]. The maxillary and mandibular alveolar ridges appeared to be thin, sharp and resorbed with overlying mucosa appearing normal. Twenty Seven in maxillary arch showed poor prognosis due to grade 3 mobility and was extracted and sent for ground sectioning. The ground section report revealed absence of cementum in the apical 2/3rd with no Sharpey's fibres [1].

Intra-oral periapical radiograph of 11, 13 and 21 revealed enlarged pulp chambers and root canals [Table/Fig-4]. Patient was tested for complete blood count (CBC), serum calcium and alkaline phosphatase levels. The CBC report was normal. Serum calcium levels were 8.10 mg/dl (NR = 8.5 – 10.1). Alkaline phosphatase levels were 33.0 UL (NR = 50– 136). The report showed marked

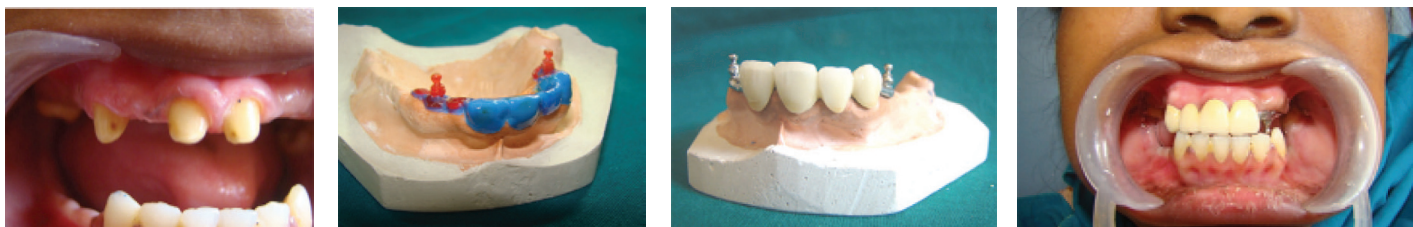
reduction in alkaline phosphatase levels with normal serum calcium, confirming the diagnosis of Hypophosphatasia [2,3].

Orthopantomogram (OPG) and a Lateral Cephalogram of the patient were taken. OPG revealed severe alveolar bone loss with enlarged pulp chambers of the teeth present. After studying the radiographs it was concluded that implant retained prosthesis could not be fabricated as bone height was inadequate due to severe resorption of the maxillary and mandibular alveolar ridges. Also, the distance between the bone crest and the occlusal plane would have led to an unfavourable crown: implant ratio, thus affecting the long term prognosis of the prosthesis [4].

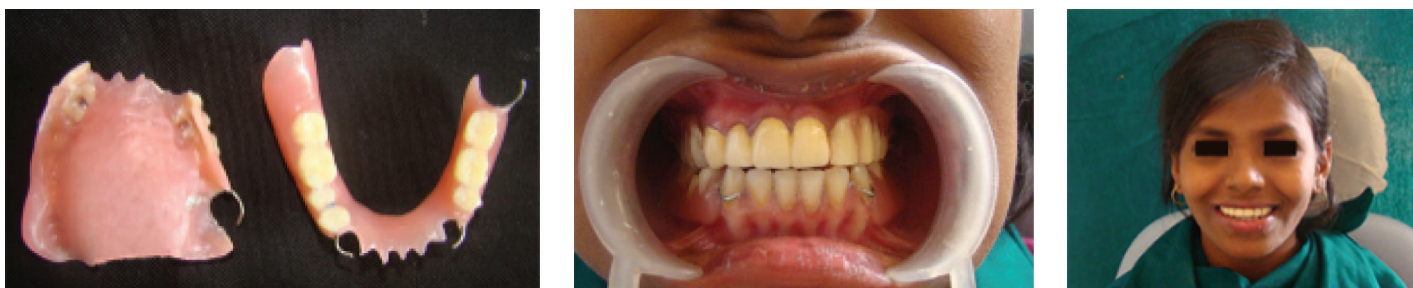The treatment planning for prosthetic rehabilitation for this patient was made after considering the age of the patient, multiple missing teeth and long standing partial edentulism. For the purpose of improved aesthetics and elevated psychological acceptance of the prosthesis by the patient, precision attachment retained interim removable partial denture was planned in the maxillary arch [5]. Due to poor periodontal condition of lower anterior teeth, a conventional clasp retained interim removable partial denture was planned for the mandibular arch [6]. The enlarged pulp chambers of the anterior teeth carried a risk of perforation during tooth preparation and hence 21, 11, 13 were root canal treated. Primary impressions of the upper and lower arch were made. Casts were prepared with type III dental stone. Temporary baseplates and wax occlusal rims were fabricated and a tentative jaw relation was carried out to confirm that adequate inter-arch space was available for fabrication of precision attachment retained prosthesis. Tooth preparation for porcelain fused to metal bridge was done on 21, 11, and 13 [Table/



[Table/Fig-1]: Pre-treatment extra-oral view [Table/Fig-2]: Pre-treatment intraoral view of maxillary arch [Table/Fig-3]: Pre-treatment intraoral view of mandibular arch [Table/Fig-4]: Intraoral periapical radiograph of maxillary central incisors showing enlarged pulp chambers



**[Table/Fig-5]:** Tooth preparation for a porcelain fused to metal bridge with 11, 13 and 21 **[Table/Fig-6]:** Wax pattern for fabrication of porcelain fused to metal bridge on abutments 11, 13 and 21 with extracoronal precision attachment **[Table/Fig-7]:** Finished porcelain fused to metal bridge with extracoronal precision attachment incorporated **[Table/Fig-8]:** Intraoral view of cemented porcelain fused to metal bridge with extracoronal precision attachment incorporated



**[Table/Fig-9]:** O-ring incorporated upper partial denture and lower conventional removable partial denture, **[Table/Fig-10]:** Post insertion Intra-oral view, **[Table/Fig-11]:** Post insertion Extra-oral view

Fig-5]. Anatomic impression of the upper arch was made in putty elastomeric impression material and light body. Anatomic cast was prepared in type 4 dental stone. Porcelain fused to metal bridge was fabricated on this anatomic cast on the prepared abutments of 11, 13 and 21 [Table/Fig-6]. The extra coronal precision attachment that is the O-ring posts (male matrix) were incorporated distal to 13 and 21 in the porcelain fused to metal bridge [Table/Fig-7]. Following trial, finishing and polishing, this porcelain fused to metal bridge with the extracoronal precision attachments was cemented permanently in the patient's mouth with Glass ionomer cement on the abutment teeth 11, 13 and 21 [Table/Fig-8]. Functional impressions of the upper and lower arch were made and master cast was poured in dental stone type IV [7]. Jaw relation, try in and fabrication of the removable partial dentures in the upper and lower arches were then carried out sequentially. The female matrix namely the O-rings were incorporated into the upper partial denture in correspondence to the male matrix that is the O-ring posts [Table/Fig-9]. The removable partial dentures were inserted in the patient's mouth after minor adjustments in the occlusion [Table/Fig-10,11]. The patient was educated about the usage and maintenance of the prosthesis. Follow-up appointment was scheduled after 3 months to study bone growth and plan for a definitive prosthesis.

## DISCUSSION

Hypophosphatasia is a rare metabolic bone disease that is characterized by deficient activity of tissue-nonspecific alkaline phosphatase (TNSALP) [8]. This deficient activity of TNSALP has been attributed to mutations in TNSALP gene which causes significant changes in the structure and functions of TNSALP [9]. It is characterized by defective bone and teeth mineralization. The severity of disease is not directly related to serum alkaline phosphate levels. Depending on the age at diagnosis, six clinical forms are currently recognized [10]:

- Perinatal
- Infantile
- Childhood
- Adult
- Odontohypophosphatasia and
- Pseudohypophosphatasia

Characteristic dental symptoms are premature deciduous teeth loss, premature exfoliation of fully rooted primary teeth, severe dental caries

and alveolar bone loss [11]. The diagnosis of Hypophosphatasia for this patient was on the basis early loss of deciduous teeth and most permanent teeth and elevated ALP levels.

The loss of teeth in young patients can cause both aesthetic-functional and psychological problems [12]. The long edentulous span predisposes the patient to mastication difficulties and development of poor habits. Functional deviations as well as the uneven distribution of functional loads may also occur [13]. The interim prosthesis would facilitate the patient's transition from debilitated to rehabilitated dentition following which a definitive prosthesis could be fabricated [14].

The use of a conventional removable partial denture would require the placement of a circumferential clasp on the upper anterior teeth which would hamper aesthetics. The upper anterior teeth showed good periodontal support and crown to root ratio, hence an extracoronal precision attachment retained removable partial denture was made for the upper teeth. The extracoronal resilient attachment system offers vertical resiliency and universal stress relief and easy replacement of worn attachments [15]. Since the periodontal condition of lower anterior teeth was compromised, a conventional removable partial denture was made for the mandibular arch. The advantages of this interim prosthesis is that the technique is non-invasive, tissue tolerant, aesthetic, comfortable to use, and easy to clean. The patient's functional and aesthetic expectations were successfully met with a significant improvement in appearance, speech and mastication.

## CONCLUSION

Precision attachments can be used to provide an aesthetic alternative to a conventional circumferential clasp in a removable partial denture. This interim removable partial denture serves as a suitable treatment option to transition young patients with long edentulous spans to a definitive prosthesis.

## REFERENCES

- Van den Bos T, Handoko G, Niehof A, Ryan LM, Coburn SP, Whyte MP, et al. Cementum and dentin in Hypophosphatasia. *J Dent Res.* 2005;84(11):1021-25.
- Whyte MP. Hypophosphatasia and the role of alkaline phosphatase in skeletal mineralization. *Endocrine Reviews.* 1994;15(4):439-61.
- Baab DA, Page RC, Ebersole JL, Williams BL, Scott CR. Laboratory studies of a family manifesting premature exfoliation of deciduous teeth. *J Clin Periodontol.* 1986;13(7):677-83.

- [4] Malchiodi L, Cucchi A, Ghensi P, Consonni D, Nocini PF. Influence of crown-implant ratio on implant success rates and crestal bone levels: a 36-month follow-up prospective study. *Clin Oral Implants Res.* 2014;25(2):240-51.
- [5] Probst L, Bachmann R, Weber H. Custom-made resin-bonded attachments supporting a removable partial denture using the spark erosion technique: a case report. *Quintessence Int.* 1991;22(5):349-54.
- [6] Chen MS, Eichhold WA, Welker WA, Chien CC. Simplicity in interim tooth-supported removable partial denture construction. *J Prosthet Dent.* 1985;54(5):740-44.
- [7] Blatterfein L, Klein IE, Miglino JC. A loading impression technique for semiprecision and precision removable partial dentures. *J Prosthet Dent.* 1980;43(1):9-14.
- [8] Olsson A, Matsson L, Blomquist HK, Larsson A, Sjodin B. Hypophosphatasia affecting the permanent dentition. *J Oral Pathol Med.* 1996;25:343-47.
- [9] Watanabe H, Goseki-Sone M, Iimura T, Oida S, Orimo H, Ishikawa I. Molecular diagnosis of Hypophosphatasia with severe periodontitis. *J Periodontol.* 1999;70(6):688-91.
- [10] Iqbal SJ, Plaha DS, Linforth GH, Dalgleish R. Hypophosphatasia: diagnostic application of linked DNA markers in the dominantly inherited adult form. *Clin Sci [Lond].* 1999;97(1):73-78.
- [11] Mornet E. Hypophosphatasia. *Orphanet J Rare Dis.* 2007;2:40.
- [12] Itró A, Difalco P, Urciuolo V, Diomajuta A, Corzo L. The aesthetic and functional restoration in the case of partial edentulism in young patients. *Minerva Stomatol.* 2005;54(5):281-92.
- [13] Kotsiomi E, Kolokitha OE, Lazaridis N. Interim Prosthodontic Management of Surgery-Induced Dental Agenesis: A Clinical Report of 8 Years of Treatment. *J Prosthodont.* 2013;22(5):408-12.
- [14] Pellizzer EP, Mazaro JV, Verri FR, Antenucci RM, Goiato MC. Removable partial denture in combination with a milled fixed partial prosthesis as interim restorations in long-term treatment. *J Prosthodont.* 2010;19(1):77-80.
- [15] Ku YC, Shen YF, Chan CP. Extracoronary resilient attachments in distal-extension removable partial dentures. *Quintessence Int.* 2000;31(5):311-17.

**PARTICULARS OF CONTRIBUTORS:**

1. Senior Lecturer, Department of Prosthodontics, Dr D.Y.Patil Dental College and Hospital, Navi Mumbai, Maharashtra, India.
2. Professor, Department of Prosthodontics and Implantology, S.D.M College of Dental Sciences and Hospital, Dharwad, Karnataka, India.
3. Professor, Department of Prosthodontics and Implantology, S.D.M College of Dental Sciences and Hospital, Dharwad, Karnataka, India.
4. Professor and Head, Department of Prosthodontics, Dr D.Y.Patil Dental College and Hospital, Navi Mumbai, Maharashtra, India.

**NAME, ADDRESS, E-MAIL ID OF THE CORRESPONDING AUTHOR:**

Dr. Gayatri Sheena Suvarna,  
Senior Lecturer, Department of Prosthodontics, Dr D. Y. Patil Dental College and Hospital,  
Dr D. Y. Patil Vidyapeeth, Sector 7, Nerul, Navi Mumbai, Maharashtra, India.  
Phone : 08976476738, E-mail : dr.gayatrisuvarna@gmail.com

**FINANCIAL OR OTHER COMPETING INTERESTS:** None.

Date of Submission: **Mar 27, 2014**

Date of Peer Review: **Aug 13, 2014**

Date of Acceptance: **Sep 04, 2014**

Date of Publishing: **Dec 05, 2014**