

Neurotensin: Immunohistochemical localization in rat central nervous system

(amygdala/substantia gelatinosa/pituitary/peptide/hypothalamus)

GEORGE R. UHL, MICHAEL J. KUCHAR, AND SOLOMON H. SNYDER*

Departments of Pharmacology and Experimental Therapeutics, and Psychiatry and Behavioral Sciences, Johns Hopkins University School of Medicine, Baltimore, Maryland 21205

Communicated by David Bodian, June 28, 1977

ABSTRACT Neurotensin immunofluorescence was examined in the rat central nervous system using a well-characterized antiserum directed against this tridecapeptide. Morphological characteristics of the fluorescence indicate its association with neuronal cell bodies and processes in the brain and with cells of the anterior pituitary. Fluorescence is seen in many brain areas, with notable densities in the substantia gelatinosa zones of the spinal cord and trigeminal nucleus, central amygdaloid nucleus, anterior pituitary, median eminence, and preoptic and basal hypothalamic areas.

Neurotensin is a tridecapeptide (<Glu-Leu-Tyr-Glu-Asn-Lys-Pro-Arg-Arg-Pro-Tyr-Ile-Leu-OH) isolated from bovine hypothalamus and characterized by Carraway and Leeman (1-3). This peptide elicits many biological activities affecting glucoregulatory, hemodynamic, smooth muscle, neuroendocrine, thermoregulatory, and gastric secretory systems (1, 2, 4, 5). Radioimmunoassay reveals high levels of neurotensin in specific regions of the central nervous system, pituitary, and the gastrointestinal tract (6-8). In the canine ileum, Orci *et al.* (9) and Sundler *et al.* (10) have observed apparently glandular cells that display neurotensin-like immunofluorescence.

Brain neurotensin is concentrated in synaptosomal subcellular fractions (6). ¹²⁵I-labeled neurotensin binds to brain membranes with high affinity and substrate specificity that are suggestive of interactions with physiological receptor sites (11-14). [³H]Neurotensin binding has also been demonstrated recently (15). This receptor binding, along with the localization of neurotensin to synaptosomal fractions and specific grey matter brain areas, is consistent with a neurotransmitter role for neurotensin in the brain (12), though other criteria must also be satisfied before full transmitter status can be imputed to this peptide (16). We now report the presence of neurotensin immunofluorescence in apparently neuronal brain structures and in cells of the anterior pituitary, as well as the mapping of the distribution of this fluorescence throughout the rat central nervous system.

MATERIALS AND METHODS

Antiserum Preparation and Characterization. Neurotensin (Bachem) was conjugated to keyhole limpet hemocyanin (Calbiochem) using ECDI [1-ethyl-3-(3-dimethylamino propyl)carbodiimide] (18) as described previously (6). Antisera for neurotensin were produced in guinea pigs (Hartley) following a series of injections of this conjugate in Freund's adjuvant; these antisera were characterized by radioimmunoassay (6). In radioimmunoassay, the antineurotensin serum selected for use in this study (no. 1-3) displayed sensitivity and specificity comparable to those of the serum (no. 0-2) used for our initial radioimmunoassay studies (6). Binding specificity was sup-

ported by the fact that the fragments containing residues 2-13, 4-13, 6-13, 8-13, and 9-13 of neurotensin, substance P, gonadotropin-releasing hormone, thyrotropin-releasing hormone, angiotensin II, and bradykinin were all less than 1/1000 as potent as neurotensin itself in reducing ¹²⁵I-labeled neurotensin binding from serum (no. 1-3). Additional evidence of radioimmunoassay specificity was provided by the fact that values for neurotensin immunoreactivity in acid/acetone extracts of several rat brain regions obtained using this serum agreed with those obtained using serum no. 0-2 and with values recently reported by Carraway and Leeman (7).

Tissue Preparation. Normal Sprague-Dawley rats (100 g) were used for most of these studies. For improved visualization of certain neurotensin-containing cell bodies, 50 μg colchicine (Sigma) in 25 μl of 0.9% NaCl was injected intracerebroventricularly 48 hr before sacrifice of some animals. Rats were perfused intracardially for 15 sec with ice-cold 0.9% NaCl followed by 10-min perfusion with ice-cold 4% depolymerized phosphate-buffered paraformaldehyde prepared according to Pease (17). Brains were cut into three or four slabs, postfixed in the same fixative for 3 hr, then soaked for at least 24 hr in 5% sucrose/0.06 M sodium phosphate buffer, pH 7.3. Brain slabs were rapidly frozen onto cryostat chucks using liquid nitrogen; sections were cut at 16 μm in a Harris cryostat and thaw-mounted onto gelatin-coated slides.

Staining. Neurotensin was stained by the indirect immunofluorescence method of Coons (19, 20). Sections were incubated for 30 min at 37° in a humid atmosphere with either anti-neurotensin serum (diluted 1:20), antineurotensin serum previously absorbed overnight at 4° with neurotensin or other substances, or guinea pig preimmune serum. Primary sera were diluted with phosphate-buffered saline containing 0.2% (wt/vol) Triton X-100 (21) as previously described (22). Triton concentrations were selected to maximize the ratio of specific to nonspecific fluorescence, with acceptable morphological preservation. Sections were washed for 15 min in three changes of phosphate-buffered saline/0.05% Triton, and then incubated for 15 min at 37° with fluorescein-conjugated goat anti-guinea pig IgG (IgG fraction, Cappel Laboratories) diluted 1:50 with phosphate-buffered saline/0.1% Triton. Sections were washed in phosphate-buffered saline/0.2% Triton, dipped in H₂O, mounted with 0.5 M Na bicarbonate buffer, pH 8.4, diluted 1:1 with glycerol, and examined under dark field conditions with a Zeiss Universal fluorescence microscope. Regions discussed in detail here were examined by two independent observers, and were studied in sections from at least two brains. Adjacent sections stained using both preimmune and neurotensin-adsorbed primary antisera served as control for nonspecific fluorescence at all levels discussed in detail. The anatomic drawings of König and Klippel (23), Palkovitz and Jacobowitz (24), and Steiner and Turner (25) were consulted; study of ad-

The costs of publication of this article were defrayed in part by the payment of page charges. This article must therefore be hereby marked "advertisement" in accordance with 18 U. S. C. §1734 solely to indicate this fact.

* To whom all correspondence should be addressed.

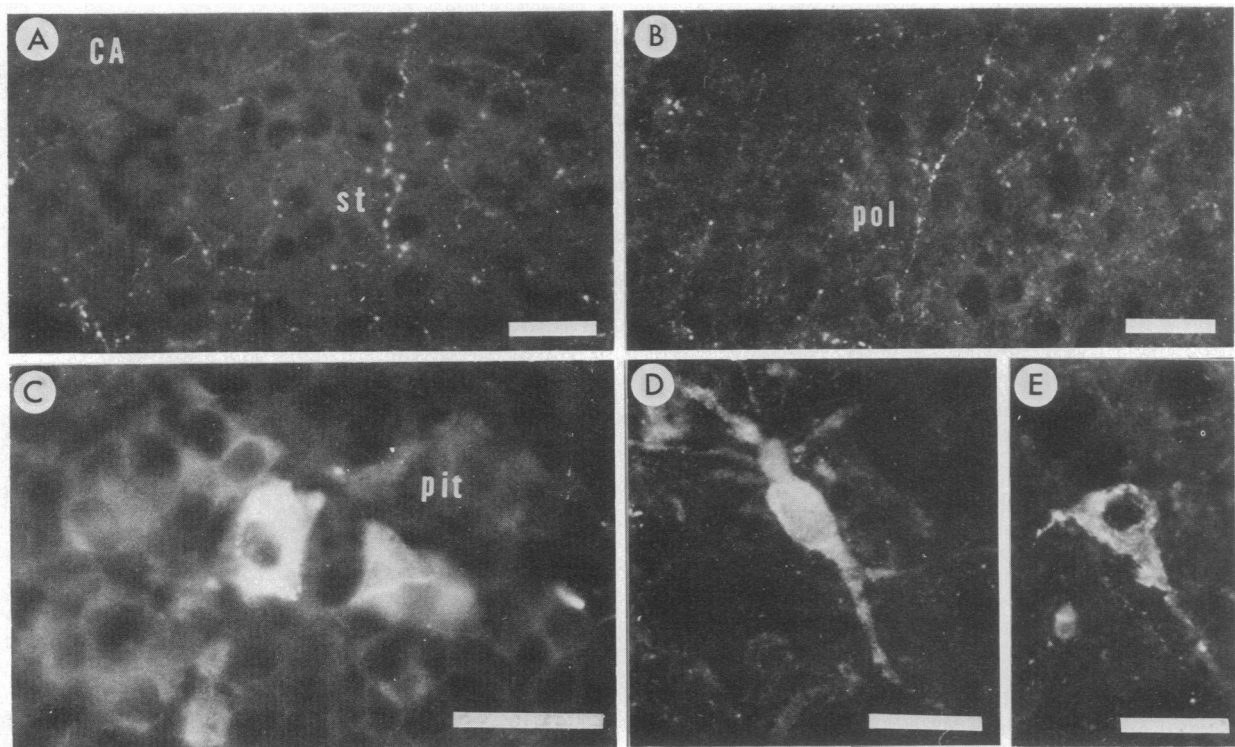


FIG. 1. Immunofluorescence micrographs of (A and E) the interstitial nucleus of the stria terminalis (st) and anterior commissure (CA), (B) the lateral preoptic nucleus (pol), (C) the anterior pituitary (pit), and (D) the amygdala. Sections A–C are from normal rats, D and E from rats pretreated with colchicine. Bars = 25 μ m.

jacent pyronin Y- or cresyl violet-stained sections aided anatomic localization.

RESULTS

Several characteristics of the observed immunohistofluorescence indicate that it is associated with the tridecapeptide neurotensin. Regional variations in neurotensin immunohistofluorescence generally parallel variations in endogenous levels of neurotensin and neurotensin receptor binding density (6–8, 11–14). Control experiments using preimmune serum or serum previously incubated with 10–1000 μ M neurotensin show negligible fluorescence, while adsorption with hemocyanin (20 mg/ml), substance P (10 μ M), thyrotropin-releasing hormone (10 μ M), prolylleucylglycinamide (100 μ M), angiotensin II (100 μ M), or bradykinin (100 μ M) failed to eliminate specific fluorescence.

Neurotensin immunohistofluorescence is localized throughout the rat central nervous system to fiber- and dot-like configurations resembling histofluorescence patterns associated with certain other brain peptides and biogenic amines (22, 26–28). These fluorescent patterns reflect the localization of neurotensin to axons and nerve terminals. Additionally, in several areas of the hypothalamus, a limited number of fluorescent cell bodies have been localized in normal rats that are not fluorescent in control sections. These perikarya display a dim, granular fluorescence superimposed on a lower intensity, more diffuse fluorescence that overlies their nonnuclear portions. In rats pretreated with colchicine, cell bodies with much more intense fluorescence occur in several hypothalamic areas, the interstitial nucleus of the stria terminalis, the amygdala, and the midbrain tegmentum (Fig. 1 D and E).

Numerous regions of the rat central nervous system and pituitary have been mapped for the detailed localization of immunoreactive neurotensin. In the discussion below, density of fiber- and terminal-like fluorescent patterns is described, unless indicated otherwise.

Spinal Cord. In the mid-cervical spinal cord, a dense band of fiber- and terminal-like fluorescence occurs in lamina II, with somewhat lower density in lamina I (Figs. 2 and 3). Fluorescent fiber- and terminal-like structures are seen scattered through the rest of the dorsal horn and, with somewhat lesser density, in the ventral horn and lateral to laminae I and II.

Medulla-Oblongata. In the caudal medulla, densest fluorescence occurs in the substantia gelatinosa of the spinal trigeminal nucleus (Figs. 2 and 3). More widely scattered fibers are seen through the remainder of the trigeminal nucleus. The lateral portion of the medullary reticular formation contains a limited number of fluorescent fibers and terminals; even fewer are seen in the medial reticular formation. Neurotensin fluorescence is also notable in the nucleus of the solitary tract, the nucleus of the vagus, and the commissural nucleus.

Mesencephalon. The most intense fluorescence at this level occurs in the midbrain tegmentum just dorsal to the interpeduncular nucleus (Fig. 4). As observed in the medulla-oblongata, low levels of fluorescence in the reticular formation are higher in lateral than in medial areas. The zona compacta of the substantia nigra displays limited fluorescence. A moderately low density of fluorescence is observed throughout the periaqueductal grey, merging ventrally with the higher densities of the more ventral tegmentum.

Diencephalon. Within the hypothalamus (and preoptic areas), anterior areas in general display more fluorescence than posterior areas (Figs. 1, 4, and 5). Densest fluorescence within the hypothalamus occurs in a band near the ventral surface, most pronounced in the more anterior portions of the hypothalamus, and apparently continuous with the dense fluorescence seen in the median eminence. Preoptic areas display fluorescence almost as great as that of this ventral band. Moderate fluorescence occurs in lateral hypothalamic areas with somewhat lower fluorescence densities in periventricular regions and least concentrated fluorescence in intermediate zones. Low levels of fluorescence occur in the mammillary bodies.

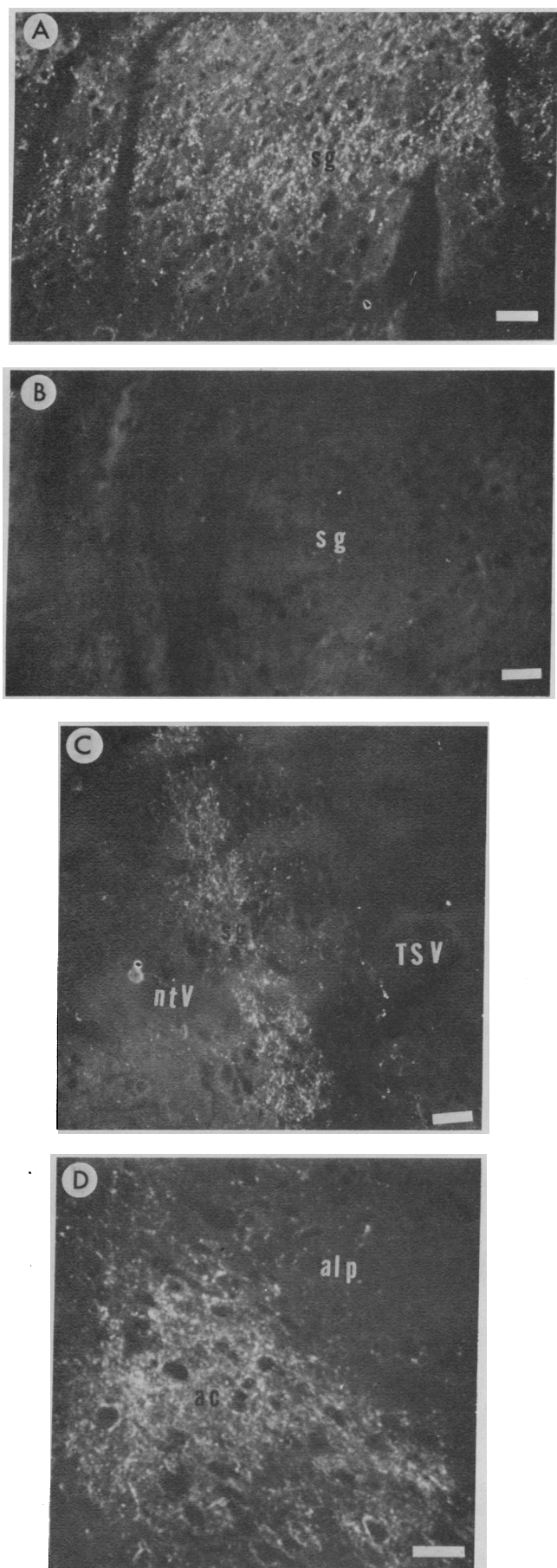


FIG. 2. Immunofluorescence micrographs of (A and B) the substantia gelatinosa (sg) of the cervical spinal cord, (C) the substantia

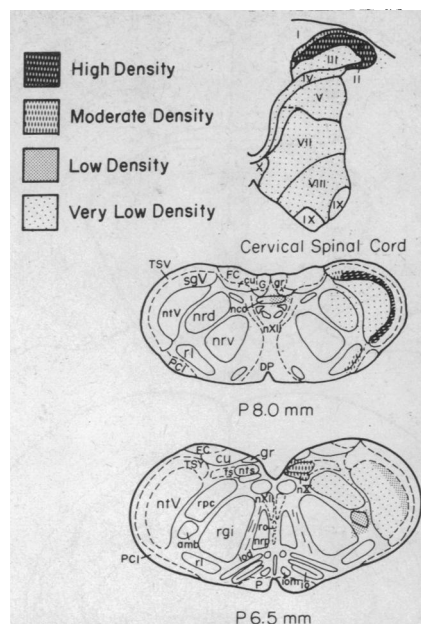


FIG. 3. Distribution of neurotensin immunohistofluorescence. Abbreviations are as follows: amb, ambiguus nucleus; cu, cuneate nucleus; DP, decussation of pyramids; FC, cuneate fasciculus; G, gracile fasciculus; gr, gracile nucleus; io, inferior olivary nucleus; iod, dorsal accessory olivary nucleus; iom, medial accessory olivary nucleus; nco, commissural nucleus; nrd, dorsal medullary reticular nucleus; nrp, paramedian reticular nucleus; nrv, ventral medullary reticular nucleus; nts, nucleus of the solitary tract; ntV, nucleus of the spinal tract of the trigeminal; nX, vagal nucleus; nXII, hypoglossal nucleus; P, pyramid; PCI, inferior cerebellar peduncle; rgi, gigantocellular reticular nucleus; rl, lateral reticular nucleus; ro, raphé obscurans nucleus; rpc, parvocellular reticular nucleus; sgV, "substantia gelatinosa" of the caudal trigeminal; ts, solitary tract; TSV, spinal tract of the trigeminal. Levels P 8.0 and P 6.5 are from ref. 24, cervical spinal cord from ref 25.

The densest fluorescence in the thalamus is observed in the periventricular nuclei (Figs. 4 and 5). Appreciable fluorescence in the medial thalamic nuclei is most enriched closer to the midline. Other medial thalamic regions with substantial densities of neurotensin fluorescence include the area of the rhomboid and reuniens nuclei. In contrast to the medial and periventricular nuclei, the lateral complex of thalamic nuclei is virtually devoid of fluorescence. At a more anterior level, the medial thalamic regions with the most concentrated neurotensin immunofluorescence include the areas of the parataenia and anterior medial nuclei; fluorescence is also seen in the nucleus reuniens and anterior ventral nuclei.

In the epithalamus, a moderately dense band of fluorescence occurs at the medial border of the lateral habenula at posterior levels of this structure. The remainder of the lateral habenula displays sparse fluorescence, while an extremely low density of immunoreactivity is seen in the medial habenula.

Telencephalon. The central nucleus of the amygdala is the most densely fluorescent area of the telencephalon (Figs. 2, 4, and 5). Fluorescence concentration decreases progressively in more ventral and more lateral portions of the amygdala.

In contrast to the amygdala, the hippocampus displays negligible fluorescence with only rare fibers and terminals observed in the area of the pyramidal cells.

gelatinosa of the caudal trigeminal nucleus (sgV), the nucleus of the spinal tract of the trigeminal (ntV), and the spinal tract of the trigeminal (TSV), and (D) the central (ac) and lateral posterior (alp) amygdaloid nuclei in normal rats. Micrographs A and B were taken from serial sections, but the primary serum used for staining in B was previously adsorbed overnight with 1 mM neurotensin to establish a control. Bars = 25 μ m.

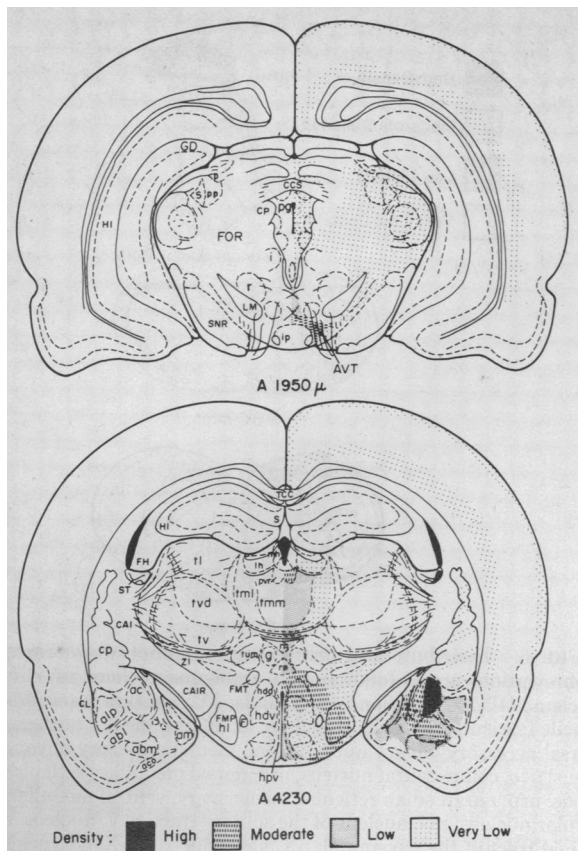


FIG. 4. Distribution of neurotensin immunofluorescence. Abbreviations are as follows: abl, lateral part of basal amygdaloid nucleus; abm, medial part of basal amygdaloid nucleus; ac, central amygdaloid nucleus; aco, cortical amygdaloid nucleus; alp, posterior part of lateral amygdaloid nucleus; am, medial amygdaloid nucleus; AVT, ventral tegmental area of Tsai; CAI, internal capsule; CAIR, retrolenticular internal capsule; CCS, commissure of the superior colliculus; CL, claustrum; CP, posterior commissure; cp, caudate/putamen nucleus; F, fornix; FH, fimbria of hippocampus; FMP, medial forebrain bundle; FMT, mammillothalamic tract; FOR, reticular formation; g, gelatinosa nucleus; GD, dentate gyrus; hdd, dorsal part of dorsomedial hypothalamic nucleus; hdv, ventral part of dorsomedial hypothalamic nucleus; HI, hippocampus; hl, lateral hypothalamic nucleus; hpv, periventricular hypothalamic nucleus; i, interstitial nucleus of Cajal; ip, interpeduncular nucleus; lh, lateral habenular nucleus; LM, medial lemniscus; mh, medial habenular nucleus; pp, profundus pretectal nucleus; pg, periaqueductal grey; pvr, rotundocellular part of periventricular thalamic nucleus; r, red nucleus; re, reuniens nucleus; rh, rhomboideus nucleus; S, suprageniculate nucleus; SNR, reticulata of substantia nigra; ST, stria terminalis, TCC, truncus of corpus callosum; tl, lateral thalamic nucleus; tml, lateral part of medial thalamic nucleus; tmm, medial part of medial thalamic nucleus; tvm, magnocellular part of ventral thalamic nucleus; tv, ventral thalamic nucleus; tvd, dorsomedial part of ventral thalamic nucleus; ZI, zona incerta. Levels are from ref. 23.

The ventrolateral portion of the stria terminalis is densely fluorescent, as is the interstitial nucleus of the stria terminalis (Figs. 1, 4, and 5). Fluorescence occurs throughout the septal area, with greater density in more lateral portions. The lateral part of the nucleus accumbens displays dense fluorescence, as does the nucleus of the diagonal band of Broca (not shown). Both the diagonal band itself and areas of cortex adjacent to the nucleus accumbens display moderate fluorescence densities. Low levels of neurotensin immunofluorescence are observed in the corpus striatum (Figs. 4 and 5). Within the caudate/putamen, sparse fluorescence occurs in patches. A more even distribution of fluorescence with similar intensity is observed throughout gray matter regions of the globus pallidus.

In several regions of the cerebral cortex (Figs. 4 and 5) a thin

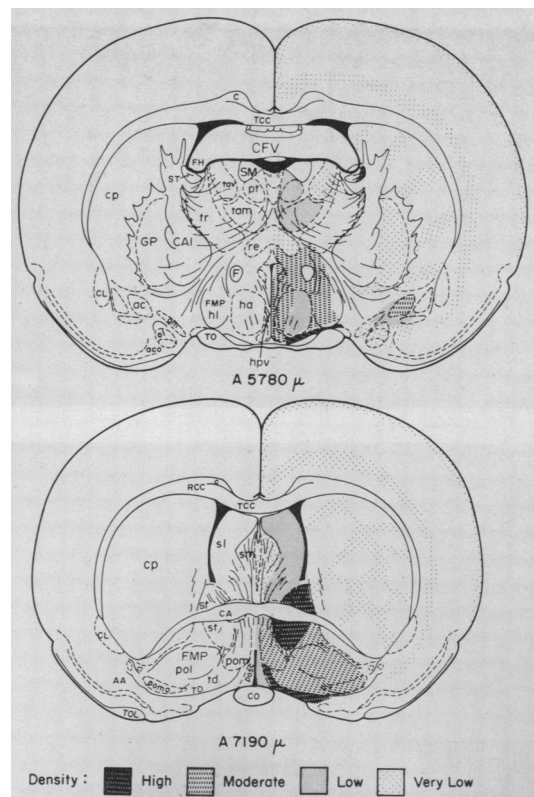


FIG. 5. Distribution of neurotensin immunofluorescence. Abbreviations are as follows: AA, anterior amygdaloid area; ac, central amygdaloid nucleus; aco, cortical amygdaloid nucleus; am, medial amygdaloid nucleus; C, cingulum; CA, anterior commissure; CAI, internal capsule; CFV, ventral commissure of the fornix; CL, claustrum; CO, optic chiasm; cp, caudate/putamen nucleus; F, fornix; FH, fimbria of hippocampus; FMP, median forebrain bundle; GP, globus pallidus; ha, anterior hypothalamic nucleus; hl, lateral hypothalamic nucleus; hpv, periventricular hypothalamic nucleus; ol, lateral nucleus of olfactory tract; pol, lateral preoptic nucleus; pom, medial preoptic nucleus; poma, magnocellular preoptic nucleus; pt, paratenial nucleus; re, reuniens nucleus; RCC, radiations of the corpus callosum; sl, lateral septal nucleus; sm, medial septal nucleus; SM, stria medullaris; ST, stria terminalis; st, interstitial nucleus of the stria terminalis; tam, anterior medial thalamic nucleus; tav, anterior ventral thalamic nucleus; TCC, truncus of corpus callosum; td, nucleus of the diagonal band of Broca; TD, diagonal band of Broca; TO, optic tract; TOL, lateral olfactory tract; tr, reticular thalamic nucleus. Levels are from ref. 23.

band of fairly sparse fluorescence occurs in apparently neuronal elements near the pial surface. A somewhat thicker band of fluorescence is observed in the deepest layers of the cortex, with no appreciable fluorescence in intermediate regions.

Pituitary. The lobes of the pituitary provide striking contrasts in the morphology of neurotensin immunofluorescence (Fig. 1). In the posterior and intermediate lobes, a low density of fiber- and terminal-like fluorescent patterns is noted; these patterns resemble the morphology of neurotensin fluorescence throughout the brain. In the anterior pituitary, however, a distinct population of pituitary cells exhibits brilliant neurotensin-like fluorescence over cytoplasmic regions. No fiber- and terminal-like patterns of fluorescence are seen in the anterior pituitary.

DISCUSSION

The immunohistofluorescence examined in the brain appears to represent authentic neurotensin tridecapeptide. The radioimmunoassay specificity of the serum for neurotensin both in brain extracts and in competition with related sequence fragments suggests that this serum may selectively recognize

neurotensin in immunohistochemical studies. The ability of preadsorption with neurotensin, but not with hemocyanin or other peptides, to block neurotensin fluorescence also weighs in favor of specificity. However, neither radioimmunoassay studies of the serum used nor immunohistofluorescent preadsorption controls totally rule out crossreactivity with a related antigen (26). Thus, it is conceivable that variants or precursors of neurotensin could be detected by this staining technique.

The distribution of neurotensin immunofluorescence throughout rat brain closely parallels neurotensin levels from microscopically dissected rat brain regions recently obtained by Kobayashi *et al.* (8). The microdissection data shows high levels of neurotensin immunoreactivity in the mediobasal, median eminence, and preoptic hypothalamic areas, where we find dense fluorescence. Elevated amounts of immunoreactive neurotensin occur in the nucleus accumbens, amygdala, interpeduncular nucleus, and mesencephalic grey (8). These results may correspond to the fluorescence densities we observe in the lateral accumbens and interstitial nucleus of the stria terminalis, in the central amygdala, and immediately dorsal to the interpeduncular nucleus, extending dorsally to the central mesencephalic grey. While neurotensin radioimmunoassay showed fairly high values in calf caudate (6), Kobayashi *et al.* (8) have found low levels of neurotensin immunoreactivity in the rat striatum (caudate/putamen), where fluorescence density is also relatively low.

Aspects of the localization of neurotensin-containing elements in the central nervous system resemble the distribution of other neuropeptides. For instance, enkephalin, substance P, and somatostatin are highly concentrated in the area of the substantia gelatinosa in the dorsal grey matter of the spinal cord as neurotensin is (22, 27). The central nucleus of the amygdala displays a high density of structures containing enkephalin, substance P, and neurotensin (22, 27). There are, however, major differences between the localization of neurotensin and that of other neuropeptides. Neurotensin fluorescence, for example, is found just dorsal to the interpeduncular nucleus, while substance P fluorescence is seen within this nucleus (27).

Some discrete localizations of neurotensin immunohistofluorescence suggest possible pathways of neurotensin-containing systems. For example, the existence of intense fluorescence in the amygdala, stria terminalis, and interstitial nucleus of the stria terminalis suggests that these anatomically connected structures may be part of a "neurotensinergic" pathway, a possibility that can be examined by lesion experiments.

The presence of neurotensin-containing cell bodies in colchicine-treated rats in areas where elevated fiber- and terminal-like fluorescence densities are found in normal rats suggests that many neurotensin neurons could be interneurons. Possible variability in the degree to which intracerebroventricularly administered colchicine penetrates to different brain regions limits the strength of this argument, however.

The localization of neurotensin fluorescence to neuronal perikarya, fibers, and terminals supports the notion that neurotensin may be a transmitter in the central nervous system. The functions of brain systems that might use this peptide as a transmitter, however, are currently largely unknown.

Immunoreactive neurotensin has been detected in the anterior pituitary and in the posterior pituitary/median eminence in high concentrations (7). The reported discrepant behavior of pituitary extracts in several different radioimmunoassay systems (7) suggests that especial caution should be given to interpretation of pituitary neurotensin immunofluorescence. Nevertheless, its striking cellular localization and elimination by neurotensin preadsorption of antiserum suggests that a

neurotensin-like antigen is contained in secretory cells here. Because neurotensin is also found in the gut (7, 9, 10) it is conceivable that neurotensin may fit into the emerging paradigm of peptides with gut and brain localizations, possessing neurotransmitter and hormonal activities (29).

We thank Drs. Carol LaMotte, Mark Molliver, and Reinhard Grzanna for valuable discussion; Naomi Taylor for expert technical assistance; and Susan Garonski and Carol Kenyon for assistance with the manuscript. Supported by U.S. Public Health Service Grant DA-00266, Research Scientist Development Award MH-33128 to S.H.S., Research Scientist Development Award MH-00053 to M.J.K., and Grant 5 T01 GM01183-13 to G.R.U.

1. Carraway, R. & Leeman, S. (1973) *J. Biol. Chem.* **248**, 6854-6861.
2. Carraway, R. & Leeman, S. (1975) *J. Biol. Chem.*, **250**, 1907-1911.
3. Carraway, R. & Leeman, S. (1975) *J. Biol. Chem.* **250**, 1912-1918.
4. Bissette, G., Nemeroff, C., Loosen, P., Prange, A. & Lipton, M. (1976) *Nature* **262**, 607-609.
5. Andersson, S., Chang, D., Folkers, K. & Rosell, S. (1976) *Life Sci.* **19**, 367-370.
6. Uhl, G. R. & Snyder, S. H. (1976) *Life Sci.* **19**, 1827-1832.
7. Carraway, R. & Leeman, S. (1976) *J. Biol. Chem.* **251**, 7045-7052.
8. Kobayashi, R., Brown, M. & Vale, W. (1977) *Brain Res.* **126**, 584-588.
9. Orci, L., Baetens, O., Refuner, C., Brown, M., Vale, W. & Guillemin, R. (1976) *Life Sci.* **19**, 559-562.
10. Sundler, F., Hakanson, R., Hammer, R., Alumets, J., Carraway, R., Leeman, S. & Zimmerman, E. (1977) *Cell Tissue Res.* **178**, 313-321.
11. Uhl, G., Bennett, J. P. & Snyder, S. H. (1976) *Neuroscience Abstracts: Society for Neuroscience Sixth Annual Meeting*, 803.
12. Uhl, G. R. & Snyder, S. H. (1977) *Eur. J. Pharmacol.* **41**, 89-91.
13. Uhl, G. R., Bennett, J. P. & Snyder, S. H. (1977) *Brain Res.* **130**, 299-313.
14. Lazarus, L., Brown, M. & Perrin, M. (1977) *Neuropharmacology*, in press.
15. Kitabgi, P., Carraway, R., Van Rietschoteu, J., Granier, C., Morgat, J., Menez, A., Leeman, S. & Freychet, P. (1977) *Proc. Natl. Acad. Sci. USA* **74**, 1846-1850.
16. Moore, K. (1971) in *An Introduction to Psychopharmacology*, eds. Rech, R. & Moore, K. (Raven Press, New York), pp. 79-136.
17. Pease, D. (1962) *Histologic Techniques for Electron Microscopy* (Academic Press, New York).
18. Goodfriend, T., Levine, L. & Fasman, G. (1964) *Science* **144**, 1344-1346.
19. Hökfelt, T., Fuxe, K. & Goldstein, M. (1975) *Ann N.Y. Acad. Sci.* **254**, 407-432.
20. Coons, A. (1958) in *General Cytochemical Methods*, ed. Danielli, J. (Academic Press, New York), pp. 399-422.
21. Hartman, B., Zide, D. & Udenfriend, S. (1972) *Proc. Natl. Acad. Sci. USA* **69**, 2722-2726.
22. Simantov, R., Kuhar, M. J., Uhl, G. R. & Snyder, S. H. (1977) *Proc. Natl. Acad. Sci. USA* **74**, 2167-2171.
23. Konig, J. & Klippel, R. (1963) *The Rat Brain* (Williams and Wilkins, Baltimore, MD).
24. Palkovitz, M. & Jacobowitz, L. (1974) *J. Comp. Neurol.* **157**, 29-42.
25. Steiner, T. & Turner, L. (1972) *J. Physiol. (London)* **222**, 123-125.
26. Petrusz, P., Sar, M., Ordronneau, P. & DiMeo, P. (1976) *J. Histochem. Cytochem.* **24**, 1110-1115.
27. Hökfelt, T., Kellerth, J., Nilsson, G. & Pernow, B. (1975) *Science* **190**, 889-890.
28. Fuxe, K. (1965) *Acta Physiol. Scand. Suppl.* **64** 247, 39-85.
29. Pearse, A. G. (1976) *Nature* **262**, 92-94.