

Heptadecapeptide gastrin in the vagal nerve

(gastrointestinal nerves/peptidergic nerves/gastrointestinal hormones/endocrine cells)

K. UVNÄS-WALLENSTEN*, J. F. REHFELD†, L.-I. LARSSON†, AND B. UVNÄS*

* Department of Pharmacology, Karolinska Institutet, Stockholm, Sweden; and † Institute of Medical Biochemistry, University of Aarhus, Aarhus, Denmark

Communicated by U. S. von Euler, September 12, 1977

ABSTRACT Immunoreactive gastrin was present in vagal nerves from cats, dogs, and human beings. The abdominal portion of the vagus contained gastrin in amounts ranging from 16 to 273 pmol/g of nerve tissue (wet weight). The thoracic and cervical portion of the vagi contained only minute amounts of gastrin. Gel chromatography of extracts of human, canine, and feline abdominal vagi monitored by region-specific antisera against heptadecapeptide gastrin and triacontatriapeptide cholecystokinin revealed that the vagal gastrin immunoreactivity predominantly consisted of heptadecapeptide gastrin. In addition, the vagi contained small amounts of the NH₂-terminal tridecapeptide gastrin fragment as well as of the putative biosynthetic gastrin precursors, components I and II. No cholecystokinin-like molecules were demonstrable. Immunocytochemical studies demonstrated gastrin-containing nerves in the intestinal wall. The nerves were found to be most numerous in the large and distal small intestine. These findings suggest that heptadecapeptide gastrin may represent a new vagal neurotransmitter.

In cats electrical vagal stimulation causes a release of gastrin heptadecapeptide, which is atropin resistant (1-4). Recently a large number of peptides have been found to possess a dual localization to endocrine cells and neurons. Such peptides include substance P, vasoactive intestinal polypeptide (VIP), somatostatin, neurotensin, and cholecystokinin (5-12). Previous findings of gastrin immunoreactivity in the central nervous system (13) have recently been shown to be due to a cross-reacting cholecystokinin octapeptide (14). Since no innervation of the G cells has been demonstrated, it occurred to us that vagal stimulation might cause a release of gastrin from gastrinergic nerves extending from the vagi. In the present communication we present evidence for the occurrence of heptadecapeptide gastrin in the trunk and branches of the vagal nerve.

MATERIALS AND METHODS

Specimens from the main trunks of the cervical, thoracic, and abdominal vagi were obtained from anesthetized cats and dogs. From human beings, specimens from the abdominal vagus were obtained at surgery. Immediately after sampling, the tissue was frozen on dry ice. While frozen the tissue was cut into pieces weighing a few milligrams, which were boiled for 20 min at pH 6.4 (10 ml of water per g of tissue) and homogenized. After centrifugation, the supernatant was assayed in dilutions from 1:10 to 1:10,000.

In addition, tissue specimens from the gastrointestinal tract, stomach to proximal colon, of cats were either immediately frozen in melting Freon-22, freeze-dried, vapor-fixed with diethylpyrocarbonate and embedded in paraffin or fixed in a 4% paraformaldehyde solution (pH 7.3) for 1-4 hr, washed in phosphate buffer (pH 7.3) containing 20% sucrose overnight,

The costs of publication of this article were defrayed in part by the payment of page charges. This article must therefore be hereby marked "advertisement" in accordance with 18 U. S. C. §1734 solely to indicate this fact.

and subsequently frozen in melting Freon-22 for cryostat sectioning.

Chromatography. Extracts (1.0-1.5 ml) were applied to Sephadex G-50 superfine columns (10 × 1000 mm) and eluted with 20 mM veronal (pH 8.4) containing 0.1% bovine serum albumin at 4° with a flow of 5 ml/hr. Fractions of 1.0 ml were collected and assayed with region-specific radioimmunoassays for gastrin and cholecystokinin. The columns were calibrated with ¹²⁵I-labeled albumin (to indicate the void volume, V₀) and ²²NaCl (to indicate the total volume, V_t). Moreover, the columns were calibrated with different molecular forms of gastrin and cholecystokinin: highly purified human triacontatriapeptide gastrin (component II or gastrin-34) (generous gift from R. A. Gregory, Liverpool, England), synthetic human heptadecapeptide gastrin (component III or gastrin-17), synthetic human NH₂-terminal tridecapeptide gastrin (generous gift from J. S. Morley, I. C. I., Alderley Park, Cheshire, England), highly purified porcine triacontatriapeptide cholecystokinin CCK-33, and the corresponding COOH-terminal octapeptide (generous gifts from V. Mutt, The Karolinska Institute, Stockholm).

Radioimmunoassays. The tissue extracts and the chromatography fractions were assayed radioimmunochemically with region-specific antisera against gastrin-17 and cholecystokinin-33: (i) antiserum 2604 raised against synthetic human gastrin-17 (15), which reacts with the COOH-terminal half of gastrin-17, binds gastrin-17 and the larger molecular forms of gastrin with equimolar potency (16), but reacts only poorly with cholecystokinin (ID₅₀ cholecystokinin/ID₅₀ gastrin <0.002); (ii) antiserum 1295 raised against synthetic human gastrin-17 (17), which reacts with the NH₂-terminal tridecapeptide fragment of gastrin-17; (iii) Antiserum L-6 raised against human gastrin-17 (18), which is entirely specific for heptadecapeptide gastrin and does not bind any larger or smaller molecular forms of gastrin; (iv) antiserum 2717 raised against synthetic human gastrin-17 (15), which reacts with the COOH-terminal pentapeptide region of gastrin-17 and hence reacts with both cholecystokinins and the larger molecular forms of gastrin; (v) antiserum 4698 raised against partially purified porcine CCK-33 (J. F. Rehfeld, unpublished), which binds amino acid sequence 25-30 of cholecystokinin-33; consequently it reacts with both the COOH-terminal octapeptide and the larger molecular forms of cholecystokinin, whereas it does not bind any gastrins; and (vi) antiserum 4478 raised against partially purified porcine cholecystokinin-33, (J. F. Rehfeld, unpublished), which binds amino acid sequence 19-25 of cholecystokinin-33 and hence binds neither the COOH-terminal cholecystokinin octapeptide nor any gastrins. Monoiodinated gastrin-17 (19) and cholecystokinin-33 labeled with iodinated *p*-hydroxyphenylpropionic acid and *N*-hydroxysuccinimide ester (20) were used as tracers; synthetic human gastrin-17 (I.C.I.) and highly purified (99% pure) porcine cholecystokinin-33 (V. Mutt, Stockholm) were used as standards.

Table 1. Concentration of gastrin, pmol/g of nerve tissue (wet weight), in different segments of the vagus

Species	Segment of vagal nerve		
	Cervical	Thoracic	Abdominal
Cat			
No. 1	0.2	0.0	54.5
No. 2	0.0	1.8	272.7
No. 3	0.0	1.6	61.4
No. 4	0.0	0.0	136.4
No. 5	2.3	0.0	136.4
Dog			
No. 1	—	—	15.9
No. 2	—	—	77.3
Human being			
No. 1	—	—	63.6
No. 2	—	—	107.1

Immunocytochemistry. Cryostat sections (5 μ m) of paraformaldehyde-fixed tissue samples were mounted on chrome alum-gelatin-coated slides which were immersed in Tris-buffered saline (pH 7.4). Paraffin sections (3 μ m) were de-waxed, hydrated, and placed in Tris-buffered saline. The sec-

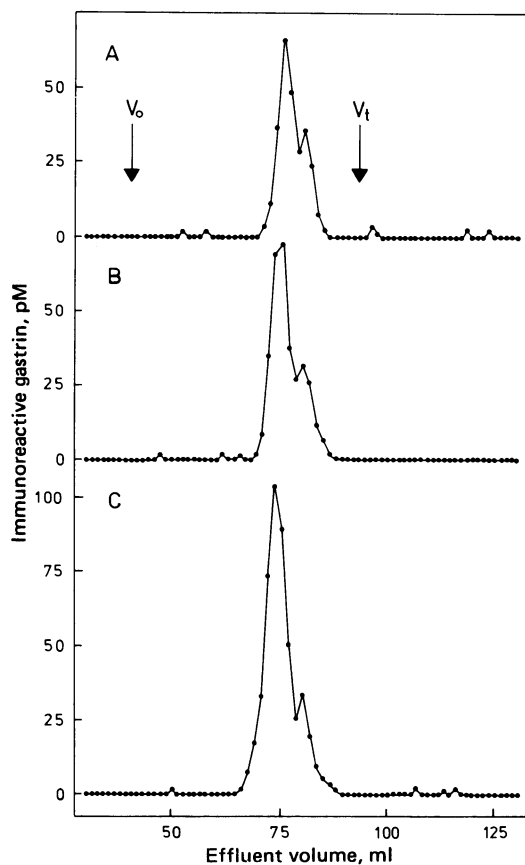


FIG. 1. Elution diagram of immunoreactive gastrin in extract from the abdominal portion of nervus vagus from human beings. The extract was applied to a Sephadex G-50 superfine column (10 \times 1000 mm) eluted at 4° with 20 mM veronal (pH 8.4) containing 0.1% bovine serum albumin. The gel chromatography was monitored radioimmunochemically with (A) antiserum 2604, which reacts with the COOH-terminal region of heptadecapeptide gastrin, and binds the larger molecular forms of gastrin with equimolar potency; (B) antiserum L-6, which binds only heptadecapeptide gastrin; and (C) antiserum 1295, which reacts with the NH₂-terminal region of heptadecapeptide gastrin.

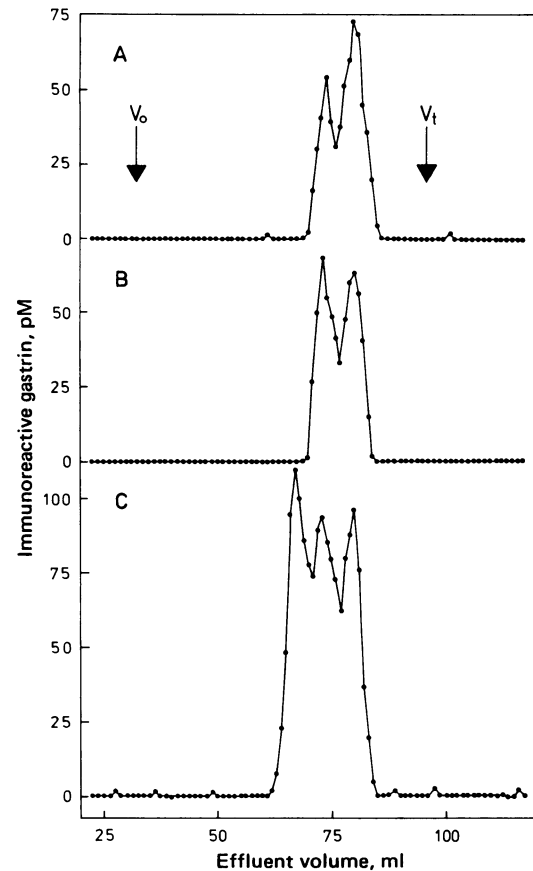


FIG. 2. Elution diagram of immunoreactive gastrin in extract from the abdominal portion of nervus vagus from cats. The extract was applied to a Sephadex G-50 superfine column (10 \times 1000 mm) eluted at 4° with 20 mM veronal (pH 8.4) containing 0.1% bovine serum albumin. The gel chromatography was monitored radioimmunochemically with (A) antiserum 2604, which reacts with the COOH-terminal region of heptadecapeptide gastrin, and binds the larger molecular forms of gastrin with equimolar potency; (B) antiserum L-6, which binds only heptadecapeptide gastrin; and (C) antiserum 1295, which reacts with the NH₂-terminal region of heptadecapeptide gastrin.

tions were allowed to react with gastrin antiserum 4562 at a 1:640 dilution for 24 hr at 4°, after which the site of antigen-antibody reaction was revealed with a 1:10 diluted solution of fluorescein isothiocyanate-labeled goat anti-rabbit IgG (SBL, Stockholm, Sweden) (21, 22). Controls were those recommended by Sternberger (23) and included the application of antigen-inactivated antiserum [10 μ g of synthetic human gastrin I (ICI, Alderley Park, Cheshire, England) was added per ml of antiserum 4562 in at a 1:640 dilution]. The sections were examined in a Zeiss standard 18 microscope equipped for epillumination with a Xenon XBO 75 lamp and selective filters for optimum excitation at 490 nm.

RESULTS

Radioimmunochemistry

All assays using antisera specific for different regions of heptadecapeptide gastrin showed large amounts of gastrin in the abdominal portion of the vagal nerve, whereas no or only minute amounts were demonstrable in cervical and thoracic portions of the vagus. The results with gastrin antiserum 2604 are shown in Table 1. The specific cholecystokinin assays did not detect significant amounts of this hormone. By gel chromatography the gastrin immunoreactivity was eluted in posi-

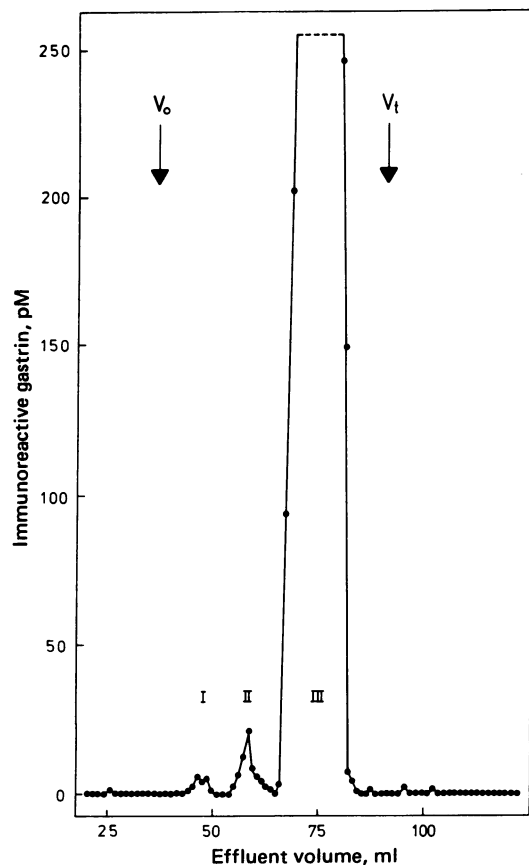


FIG. 3. Elution diagram of immunoreactive gastrin in a concentrated extract from the abdominal portion of nervus vagus from cats. The extract was applied to a Sephadex G-50 superfine column (10 × 1000 mm) eluted at 4° with 20 mM veronal (pH 8.4) containing 0.1% bovine serum albumin. The gel chromatography was monitored radioimmunochemically with gastrin antiserum 2717, which reacts with the COOH-terminal pentapeptide region of heptadecapeptide gastrin.

tions corresponding mainly to sulfated and nonsulfated heptadecapeptide gastrin (Figs. 1 and 2). In addition, gastrin immunoreactivity appeared in a position corresponding to the NH₂-terminal tridecapeptide fragment of heptadecapeptide gastrin (Fig. 2). This was particularly prominent in extracts from feline vagus. When a concentrated extract of the vagus was applied to gel chromatography monitored by an assay with optimized sensitivity (detection limit ≤0.5 pM heptadecapeptide gastrin), minor peaks of gastrin immunoreactivity were also apparent in positions corresponding to gastrin components I and II (gastrin-34) (Fig. 3).

Immunocytochemistry

In the proximal colon, numerous specifically immunoreactive nerves were detected (Fig. 4). The bulk of nerves occurred in the submucosa in close association with the submucous nervous plexus as well as with the muscularis mucosa. Occasional nerves were in addition detected in the lamina propria mucosa as well as in the external smooth muscle layer. In the small intestines the gastrin immunoreactive nerves predominated in the lamina propria mucosa, where they could be seen to extend up into the core of the intestinal villi (Fig. 5). The nerves were more abundant in the distal than in the proximal small intestine and were only occasionally detected in the proximal duodenum. Most specimens from the stomach wall (including both the antropyloric and the corpus portion) were devoid of immuno-

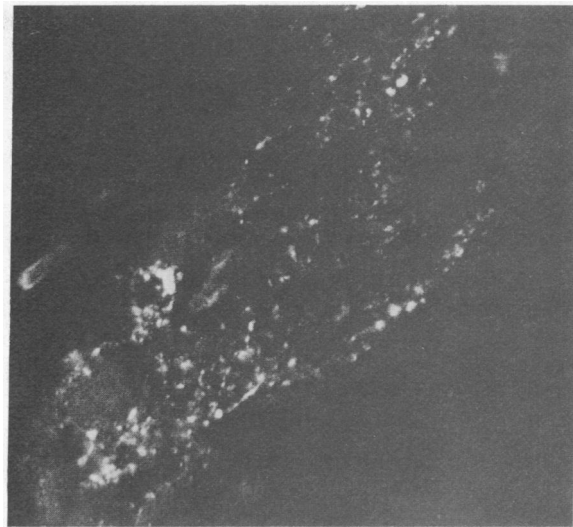


FIG. 4. Cat colonic mucosa. Paraformaldehyde-fixed cryostat section. Gastrin immunofluorescence. Numerous varicose immunoreactive fibers are seen in the submucosa. (×570.)

reactive nerves. In a few specimens, however, occasional nerves were detected in the external muscular lining of both the antrum and the corpus. Immunoreactive nerves were extremely rare in the myenteric plexus of the entire gastrointestinal tract.

The gastrin immunoreactive nerves were thin and often showed a beaded appearance. Although some nerves occurred in the vicinity of nerve cell somas of the submucous plexus, they were more frequently associated with smooth musculature of the colonic muscularis mucosa. In the small intestines, gastrin immunoreactive nerves were quite frequently associated with smooth muscle-like cells of the villous core. No gastrin immunoreactive nerve cell bodies were found.

Gastrin immunoreactive epithelial cells were detected in the antral and small intestinal mucosa in a pattern previously described in detail (22). Both types of tissue pretreatment were equally successful for demonstrating both nerves and endocrine cells. When sections were exposed to the gastrin antiserum for shorter time periods than usual (e.g., 30 min of exposure), gastrin cells still showed brilliant immunofluorescence whereas

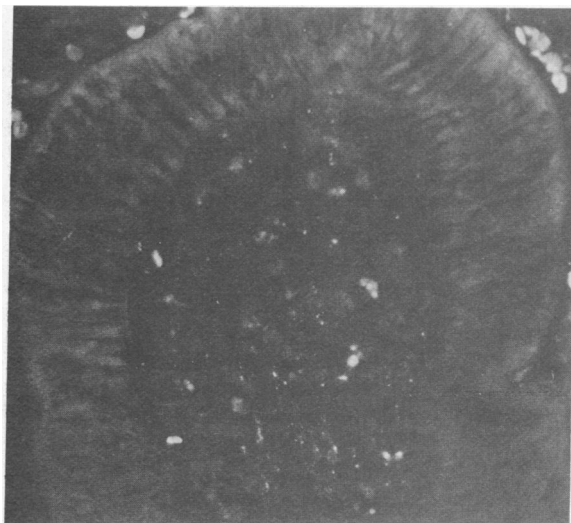


FIG. 5. Cat duodenal mucosa. Diethylpyrocarbonate-fixed paraffin section. Gastrin immunofluorescence. Scattered immunoreactive fibers are seen in the core of the villi. (×430.)

the nerves fluoresced only very faintly. Conceivably, this may be due to either a different storage form of gastrin in the nerves or to a lower content of gastrin in the latter. At any rate, the long exposure times necessary for demonstrating the nerves may explain why these nerves have not been detected in previous immunocytochemical studies.

DISCUSSION

Hitherto, gastrin has been considered to be stored exclusively in specialized endocrine (G) cells of the upper gastrointestinal mucosa. The present study shows that gastrin is present also in the vagal nerves of cats, dogs, and human beings. In addition gastrin-immunoreactive nerves are detectable in the gastrointestinal wall by immunocytochemistry.

The finding of a gastrointestinal hormone in both nerves and mucosal cells within the gastrointestinal tract is not unique. Other gastrointestinal peptides, such as substance P, somatostatin, neurotensin, and vasoactive intestinal polypeptide all occur in nerves as well as in endocrine-like cells (5–11).

The molecular forms of gastrin in vagal extracts are not similar to the brain "gastrin" originally described by Vanderhaeghen *et al.* (13). This brain "gastrin" has been shown mainly to be a small peptide resembling the COOH-terminal octapeptide of cholecystokinin (14). We could, however, not demonstrate such octapeptide-like cholecystokinin in the vagal extracts by specific cholecystokinin radioimmunoassays. Instead, vagal gastrin corresponds mainly to the molecular form of gastrin predominating in extracts of the antral mucosa, i.e., the heptadecapeptide form (component III). Thus, in mammals about 95% of the antral gastrin consists of heptadecapeptide gastrin, whereas components I and II account for the remaining 5% (3, 24, 25).

The presence of small amounts of larger gastrin components, conceivably representing biosynthetic precursors of heptadecapeptide gastrin (26), suggests that gastrin may be synthesized within the nerves.

The origin of the vagal gastrin immunoreactivity cannot be definitely established, but it is probably the vagal nucleus. The relatively low concentration of gastrin found in the medulla oblongata and in the proximal part of the vagi does not contradict such an assumption since neurotransmitter substances tend to be most concentrated in the distal parts of the neurons. Furthermore, low amounts of gastrin immunoreactivity corresponding to heptadecapeptide gastrin have been detected in the medulla oblongata (unpublished).

Our results, showing the presence of immunoreactive gastrin in the vagal nerves and in scattered nerve fibers of the gastrointestinal tract, indicate that gastrin, like several other gut peptides, is localized in both nerves and endocrine cells. The physiological functions of the neural gastrin are unknown.

- Uvnäs, B., Uvnäs-Wallensten, K. & Nilsson, G. (1975) "Release of gastrin on vagal stimulation in the cat," *Acta Physiol. Scand.* **94**, 167–176.
- Uvnäs-Wallensten, K., Uvnäs, B. & Nilsson, G. (1976) "Quantitative aspects of the vagal control of gastrin release in cats," *Acta Physiol. Scand.* **96**, 19–28.
- Uvnäs-Wallensten, K. & Rehfeld, J. F. (1976) "Molecular forms of gastrin in antral mucosa, serum and gastric juice during vagal stimulation in anaesthetized cats," *Acta Physiol. Scand.* **98**, 217–226.
- Uvnäs-Wallensten, K. & Andersson, H. (1977) "Effect of atropine and methiamide on vagally induced gastric acid secretion and gastrin release in anaesthetized cats," *Acta Physiol. Scand.* **99**, 496–502.
- Pearse, A. G. E. & Polak, J. M. (1975) "Immunocytochemical localization of substance P in mammalian intestine," *Histochemistry* **41**, 373–375.
- Nilsson, G., Larsson, L.-I., Håkanson, R., Brodin, E., Pernow, B. & Sundler, F. (1975) "Localization of substance P-like immunoreactivity in mouse gut," *Histochemistry* **43**, 97–99.
- Larsson, L.-I., Fahrenkrug, J., Schaffalitzky de Muckadell, O., Sundler, F., Håkanson, R. & Rehfeld, J. P. (1976) "Localization of vasoactive intestinal polypeptide (VIP) to central and peripheral neurons," *Proc. Natl. Acad. Sci. USA* **73**, 3197–3200.
- Hökfelt, T., Efendic, S., Hellerström, C., Johansson, O., Luft, R. & Arimura, A. (1974) "Cellular localization of somatostatin in endocrine-like cells and neurons of the rat with special reference to the cells of the pancreatic islets and the hypothalamus," *Acta Endocrinol. (Copenhagen) Suppl.* **80**, 200.
- Carraway, R. & Leeman, S. E. (1973) "The isolation of a new hypotensive peptide, neurotensin, from bovine hypothalamus," *J. Biol. Chem.* **248**, 6854–6861.
- Kitabgi, P., Carraway, R. & Leeman, S. E. (1976) "Isolation of a tridecapeptide from bovine intestinal tissue and its partial characterization as neurotensin," *J. Biol. Chem.* **251**, 7053–7058.
- Orci, L., Baetens, O., Rufener, C., Brown, M., Vale, W. & Guillemin, R. (1976) "Evidence for immunoreactive neurotensin in dog intestinal mucosa," *Life Sci.* **19**, 559–562.
- Larsson, L.-I. & Rehfeld, J. F. (1977) "Evidence for a common evolutionary origin of gastrin and cholecystokinin," *Nature*, in press.
- Vanderhaeghen, J. J., Signeau, J. C. & Gepts, W. (1975) "New peptide in the vertebrate CNS reacting with anti-gastrin antibodies," *Nature* **257**, 604–605.
- Dockray, G. J. (1976) "Immunochemical evidence of cholecystokinin-like peptides in brain," *Nature* **264**, 568–570.
- Rehfeld, J. F., Stadil, F. & Rubin, B. (1972) "Production and evaluation of antibodies for the radioimmunoassay of gastrin," *Scand. J. Clin. Lab. Invest.* **20**, 221–232.
- Rehfeld, J. F. (1976) "Distributed islet-cell function related to endogenous gastrin release," *J. Clin. Invest.* **58**, 41–49.
- Dockray, G. J. & Walsh, J. H. (1975) "Amino terminal gastrin fragment in serum of Zollinger-Ellison syndrome patients," *Gastroenterology* **68**, 222–230.
- Dockray, G. J. & Taylor, I. L. (1976) "Heptadecapeptide gastrin: Measurement in blood by specific radioimmunoassay," *Gastroenterology* **71**, 971–977.
- Stadil, F. & Rehfeld, J. F. (1972) "Preparation of ¹²⁵I-labelled synthetic human gastrin I for radioimmunoanalysis," *Scand. J. Clin. Invest.* **30**, 361–368.
- Bolton, A. E. & Hunter, W. M. (1973) "The labelling of proteins to high specific radioactivities by conjugation to a ¹²⁵I-containing acylating agent," *Biochem. J.* **133**, 529–539.
- Larsson, L.-I., Rehfeld, J. F., Håkanson, R. & Sundler, F. (1976) "Pancreatic gastrin in foetal and neonatal rats," *Nature* **262**, 609–610.
- Larsson, L.-I., Håkanson, R., Sjöberg, N.-O. & Sundler, F. (1975) "Fluorescence histochemistry of the gastrin cell in fetal and adult man," *Gastroenterology* **68**, 1152–1159.
- Sternberger, L. A. (1974) *Immunocytochemistry* (Prentice-Hall, Inc., Englewood Cliffs, NJ).
- Rehfeld, J. F. (1972) "Three components of gastrin in human serum," *Biochim. Biophys. Acta* **285**, 364–372.
- Malmström, J., Stadil, F. & Rehfeld, J. F. (1976) "Gastrins in tissue," *Gastroenterology* **70**, 697–704.
- Rehfeld, J. F. (1977) "Progastrin and the larger molecular forms of gastrin," in *Proceedings of the Vth International Congress of Endocrinology, Hamburg 1976*. ed. James, V. H. T. (Excerpta Medica, Amsterdam), pp. 57–60.