

Alternative Method for Creating Fine Hairs with Hair Removal Laser in Hair Transplantation for Hairline Correction

Hyun Sun Park, Jin Yong Kim, Yun Seon Choe, Wonseok Han¹, Jee Soo An², Kyle K. Seo²

Department of Dermatology, Seoul National University Boramae Hospital, ¹Hanhui Clinic, ²Modelo Clinic, Seoul, Korea

Background: Foremost fine hairs in the frontal hairline region are critical in hair transplantation for hairline correction (HTHC) in women. However, there are few studies on a nonsurgical revisionary method for improving an unnatural foremost hairline with thick donor hairs resulting from a previous HTHC. **Objective:** To investigate the efficacy and safety of using a hair removal laser (HRL) system to create fine hairs in Asian women with thick donor hairs. **Methods:** Through a retrospective chart review, the HRL parameters, hair diameter (measured with a micrometer before and after the procedures), subjective results after the procedures, adverse effects, and the number of procedures were investigated. The reduction rate of the hair diameter was calculated. **Results:** Twenty-four women who received long-pulse Neodymium-Doped:Yttrium Aluminum Garnet therapy after HTHC were included. The parameters were as follows: delivered laser energy, 35~36 J/cm²; pulse duration, 6 ms; and spot size, 10 mm. The mean number of laser sessions was 2.6. The mean hair diameter significantly decreased from 80.0±11.5 μm to 58.4±13.2 μm ($p=0.00$). The mean rate of hair diameter reduction was -25.7% (range, -44.6% to 5.7%). The number of laser sessions and the hair diameter after the procedures showed a negative correlation ($r=-0.410$, $p=0.046$). Most of the patients (87.5%) reported subjective improvement of their hairlines. Most

complications were transient and mild. **Conclusion:** HRL can be an alternative method for creating fine hairs and revising foremost hairline in Asian women with thick donor hairs. (*Ann Dermatol* 27(1) 21~25, 2015)

-Keywords-

Hair, Transplantation, Hair removal, Lasers, Nd:YAG

INTRODUCTION

The overall hairline shape differs between men and women. Men have a hairline with a pronounced fronto-temporal peak, whereas women tend to have a hairline with a round fronto-temporal angle. Because an oval hairline accentuates the beauty of the feminine face, the demand for hair transplantation for hairline correction (HTHC) has increased in women with an M-shaped, "masculine," forehead.

Hairs may be classified according to their diameter: thick hair, >80 μm; thin hair, between 60 μm and 80 μm; and fine hair, <60 μm¹. Swinehart² mentioned that a normal hairline is not a line but rather a zone in which hairs become finer and sparser. This diminution in diameter and density is most prominent in younger patients, along temporal hairlines, and in female patients. Therefore, fine single hairs at foremost zone of hairline are critical for a natural hairline design in HTHC in female patients. However, conventionally, hairs from the occipital scalp, which has the thickest diameters, are used in hair transplantation. Moreover, a large proportion of Asian patients tend to have hairs with substantially wider shaft diameters than those usually found in Caucasians, which results in a denser posttransplant appearance than ordinarily expected. Therefore, fewer grafts or sessions may

Received October 17, 2013, Revised February 28, 2014, Accepted for publication March 30, 2014

Corresponding author: Kyle K. Seo, Modelo Clinic, 459 Apgujeong-ro, Gangnam-gu, Seoul 135-955, Korea. Tel: 82-2-543-8855, Fax: 82-2-547-9009, E-mail: doctorseo@hotmail.com

This is an Open Access article distributed under the terms of the Creative Commons Attribution Non-Commercial License (<http://creativecommons.org/licenses/by-nc/3.0>) which permits unrestricted non-commercial use, distribution, and reproduction in any medium, provided the original work is properly cited.

produce satisfactory results, as with African American hairs (although not to the same degree). Additionally, special effort must be made to use the finest hairs for the most anterior rows³. To overcome this problem, a few methods have been suggested, including the grafting of bisected hair follicles² and follicular unit transplantation of body⁴ or leg⁵ hairs. However, their use is limited by many practical problems such as poor yield, a longer operation time, the need for a highly skilled specialist, variations in hair angulation or quality, and insufficient body hair. Recently, Jung et al.⁶ suggested a refined hairline correction technique involving the sorting of one-hair follicular units with a small diameter (60~70 μm thick) from the excision of an occipital hair strip, and then transplanting them onto the front-most hairline. Naturally thinner hairs from the postauricular zone or the nape of the neck can also be harvested and transplanted. However, there are few studies on a nonsurgical revisionary method for improving an unnatural foremost hairline with thick donor hairs resulting from a previous conventional HTHC. Therefore, on the basis of the idea that hairs surviving a hair removal laser (HRL) procedure becomes thinner, the authors investigated the efficacy and safety of using HRL to create fine hairs in Asian women with thick donor hairs.

MATERIALS AND METHODS

This retrospective study was approved by the internal institutional review board of Seoul National University Boramae Hospital (IRB No. 06-2012-68). A search of the medical record database revealed that 101 female adult patients received laser procedures at Modelo Clinic for creating fine hairs after HTHC between 2007 and 2010. Among them, 77 patients were excluded because of female pattern hair loss ($n=6$), receiving HRL treatment other than long-pulse Neodymium-Doped:Yttrium Aluminum Garnet (Nd:YAG) laser ($n=3$) (CoolGlide; Cutera, San Francisco, CA, USA), and insufficient data ($n=68$). Other exclusion criteria included pregnancy, menopause, regular medication, and chronic wasting disease ($n=0$). Therefore, we finally included 24 patients in the study. A retrospective chart review was done, and factors including age, HRL parameters, hair diameter (measured by a micrometer [Mitutoyo, Kawasaki, Japan] before and after the procedures), number of procedures, subjective results of treatment, and adverse effects were investigated. Foremost anterior hairs were divided into four segments along the hairline. One hair from each segment was randomly selected and measured by using a micrometer. The average of four values was calculated and considered the hair diameter. The rate of hair diameter reduction was

calculated by using the following equation:

$$\frac{\text{Hair diameter after the procedures} - \text{Hair diameter before the procedures}}{\text{Hair diameter before the procedures}} \times 100.$$

The data were statistically analyzed with IBM SPSS Statistics ver. 20.0 (IBM Co., Armonk, NY, USA) and a p -value of <0.05 was considered to be significant. The hair diameters measured before and after the procedures in one patient were analyzed with a paired t-test. The correlation between parameters was analyzed by using a bivariate correlation test.

RESULTS

Basic information

Twenty-four female patients with mean age of 28.8 ± 5.4 years (range, 22~45 years) were included in this study. In all patients, donor hairs for HTHC were acquired from strips of occipital scalp hair, and one-hair follicular units were transplanted onto the foremost hairline. The patients were generally satisfied with the previous HTHC but wanted to reduce the thickness of the hairs of the foremost hairline.

Laser procedure to create fine hairs

A long-pulse Nd:YAG laser was used to create fine hairs. The initial procedure was done at least 5 months after HTHC (mean, 15.7 months; range, 5~36 months). Foremost anterior two to three rows of hair were shaved and then irradiated with the laser. The parameters were as follows: energy, 35~36 J/cm^2 ; pulse duration, 6 ms; spot size, 10 mm. The mean number of laser sessions was 2.6 (range, 1~5). Laser treatment was repeated at 3-month intervals to check for hair regrowth.

Change of hair diameter

The mean hair diameter significantly decreased from $80.0 \pm 11.5 \mu\text{m}$ to $58.4 \pm 13.2 \mu\text{m}$ after the procedures ($p=0.00$; Fig. 1, 2).

The mean time of measurement of hair diameter after the procedures was 6.3 months (range, 3~14 months) after the last session. The mean rate of hair diameter reduction was -25.7% (range, -44.6% to 5.7%). The number of laser sessions and the hair diameter after the procedures showed a negative correlation ($r=-0.410$, $p=0.046$). Patients treated with a single session had a median postlaser hair diameter of $69.6 \mu\text{m}$ ($n=6$); two sessions, $55.8 \mu\text{m}$ ($n=14$); and more than three sessions, $50.8 \mu\text{m}$ ($n=4$). However, statistical analysis to compare these

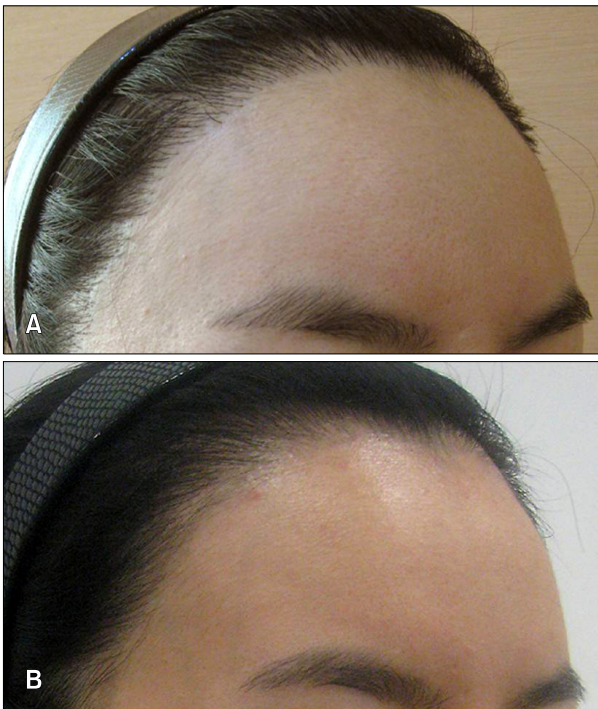


Fig. 1. (A) The resulting hairline after hair transplantation for hairline correction in an Asian woman with thick donor hairs. (B) A more natural hairline after revision, by creating fine hairs with hair removal laser (long-pulse Neodymium-Doped:Yttrium Aluminum Garnet).

groups could not be done because of the uneven and small number of cases. The median reduction rate of hair diameter according to the number of laser procedures showed the same tendency: 18.0%, 27.6%, and 30.5%.

Subjective assessment

Subjective assessment of the treatment result was done at the time of hair thickness measurement. More than 80% of the patients reported subjective improvement (Table 1).

Adverse effects

Acute adverse reactions, including erythema or swelling, were observed in most of the patients. However, they were tolerable and transient. Chronic adverse reactions at the time of hair thickness measurement included folliculitis (n=1) and focal alopecia (n=1). Twenty-two patients showed no HRL-associated chronic adverse effects.

DISCUSSION

The overall shape of the hairline and the proper ratio of the forehead to the entire face are important factors for a balanced and attractive face^{7,8}. A hairline with a prominent fronto-temporal recession is associated with a masculine facial appearance, whereas a round hairline is

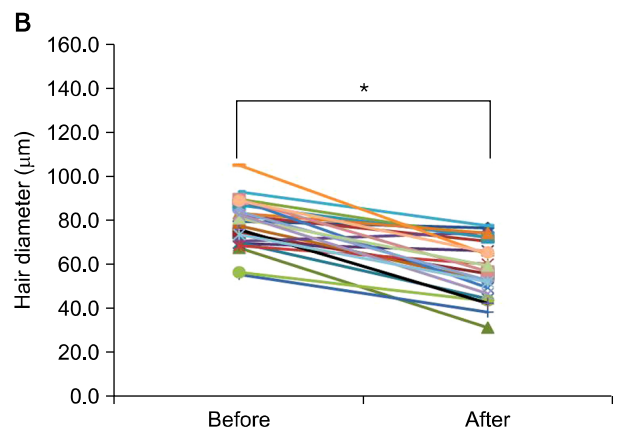


Fig. 2. (A) Comparison of hair diameter measurements before and after laser treatment under light microscopy. (B) Statistically significant reduction of hair diameter after the laser treatment. **p*<0.05, paired t-test.

Table 1. Patients’ subjective assessment of the results of the revisionary laser treatment

Criteria	Description	Patients No. (%)
Excellent	Unnatural foremost hairline from the previous HTHC is much improved after the laser treatment	4 (16.7)
Good	Unnatural foremost hairline from the previous HTHC is improved after the laser treatment	12 (50.0)
Fair	Unnatural foremost hairline from the previous HTHC is slightly improved after the laser treatment	5 (20.8)
Poor	Unnatural foremost hairline from the previous HTHC did not change after the laser treatment	3 (12.5)
Total		24 (100)

HTHC: hair transplantation for hairline correction.

associated with a feminine face. Scalp reduction surgery was first introduced to correct an M-shaped forehead⁸. It can allow a high density of hair growth. However, it often leaves a permanent linear scar along the hairline, results in an artificial-looking straight hairline, and causes numbness in the scalp⁷⁻⁹. On the other hand, hair transplantation can result in a more natural-looking hairline without scars. Therefore, hair transplantation surgery became the treatment of choice for hairline correction. However, hair transplantation also has some problems, including sparse hair density and unnaturally thick hairs at the foremost zone of hairline. Fine hairs at the foremost hairline are a unique feature in women; however, transplantation of hairs from the occipital area, where hairs are the thickest, create an unnatural hairline. In a recent study in Korea, normal women aged between 22 and 49 years had the thickest hairs on the occipital area ($84.2 \mu\text{m}$)¹⁰.

The creation of a natural-looking hairline thus must include a deliberate attempt to create finer-caliber hair in the most frontal part of the hairline⁵. A few methods, including transplantation of selected single hairs¹¹, creating fine hairs by using damaging hair bulbs^{2,12}, and follicular unit transplantation of fine leg hairs, were previously suggested. However, their uses are limited because they are time consuming, require high skills, and are troublesome processes that may have low reproducibility. Furthermore, in Asian women with thick donor hairs, the simple method of single-hair transplantation is not very useful. Recent methods such as the use of vellus-like one-hair follicular units approximately $60\sim 70 \mu\text{m}$ thick from the excision of an occipital hair strip, or the harvesting of naturally thinner hairs from the postauricular zone or the nape of the neck can be valuable options for HTHC in Asian women, resulting in a natural hairline⁶.

In some circumstances, a method with HRL can be an alternative. For example, HRL is useful when patients do not want an additional surgery to revise the unnatural hairline resulting from a previous conventional HTHC, or when naturally thin hairs are insufficient. HRL does not directly damage the follicular epithelium by targeting melanin as a chromophore. However, according to the extended theory of selective photothermolysis, laser heats the abundant melanins in the hair shaft and then the diffused heat from the shaft damages the surrounding follicular epithelium¹³. On the basis of this theory, we devised a new method for creating fine hairs that deliver partial damage to the surrounding follicular epithelium by applying laser irradiation with a short pulse width. That is why we selected the parameters of $35\sim 36 \text{ J/cm}^2$ energy and 6 ms pulse duration for a long-pulse Nd:YAG laser, instead of using the conventional parameters for thick hair

removal (i.e., $50\sim 60 \text{ J/cm}^2$ and $30\sim 40 \text{ ms}$).

On the basis of our data, the hair diameter (-25.7%) was effectively reduced after the HRL procedures. Furthermore, more HRL sessions led to a larger reduction of the hair diameter. Also, we observed foremost hairs partially damaged by HRL grew shorter (data not shown). Considering the reduction of hair diameter and hair length, a significant reduction of hair volume in foremost zone of hairline can be expected. The reduction of hair diameter seen in our study was stable and persistent at 6.3 months after the last session of HRL. However, considering that the growth cycle of human scalp anagen hair takes $2\sim 3$ years, and occasionally much longer, a long-term follow-up is required. We believe that any HRL can induce similar partial damage if the appropriate parameters are applied. It would be safe to try a small test area first, and then wait for 3 months to check if the hairs do regrow thinner before treating the whole area. This method can also be tried for other types of hair transplantation in which thin hairs are required, such as in the transplantation of eyebrows, sideburns, and eyelashes. A segment of the donor zone is irradiated with HRL, and hairs growing back thinner after a few months can be harvested and transplanted. However, further studies are required to prove the above hypotheses and to expand the indications.

Although there were no serious complications after creating fine hairs with a long-pulse Nd:YAG laser, careful setting of parameters is required because focal alopecia was observed in a few patients. However, adverse effects such as focal alopecia and folliculitis may be related not only to HRL but also to HTHC itself. Additionally, the thin hairs created by the laser procedure might have accentuated the sparsely transplanted areas.

In conclusion, HRL with long-pulse Nd:YAG can create fine hairs in Asian female patients with thick donor hairs. It can be a useful alternative method when patients do not want additional surgery to revise their hairline resulting from a previous conventional HTHC. It can reduce the diameter of foremost hairs and increase the patients' satisfaction with HTHC.

The limitation of this study is its retrospective and uncontrolled nature with no long-term follow-up data. Future prospective trials with a long-term follow-up and larger sample size are required.

REFERENCES

1. Zviak C, Bouillon C. Hair treatment and hair care products. In: Zviak C, editor. The science of hair care. New York: Marcel Dekker Inc., 1986:142.
2. Swinehart JM. "Cloned" hairlines: the use of bisected hair

- follicles to create finer hairlines. *Dermatol Surg* 2001;27:868-872.
3. Unger WP. Hair transplantation in Orientals. In: Unger WP, editor. *Hair transplantation*. 3rd ed. New York: Marcel Dekker Inc., 1995:285-286.
 4. Jones R. Body hair transplant into wide donor scar. *Dermatol Surg* 2008;34:857.
 5. Umar S. The transplanted hairline: leg room for improvement. *Arch Dermatol* 2012;148:239-242.
 6. Jung JH, Rah DK, Yun IS. Classification of the female hairline and refined hairline correction techniques for Asian women. *Dermatol Surg* 2011;37:495-500.
 7. Holcomb JD, McCollough EG. Trichophytic incisional approaches to upper facial rejuvenation. *Arch Facial Plast Surg* 2001;3:48-53.
 8. Ramirez AL, Ende KH, Kabaker SS. Correction of the high female hairline. *Arch Facial Plast Surg* 2009;11:84-90.
 9. Marten TJ. Hairline lowering during foreheadplasty. *Plast Reconstr Surg* 1999;103:224-236.
 10. Kang H, Kang TW, Lee SD, Park YM, Kim HO, Kim SY. The changing patterns of hair density and thickness in South Korean women with hair loss: clinical office-based phototrichogram analysis. *Int J Dermatol* 2009;48:14-21.
 11. Rassman WR, Bernstein RM, McClellan R, Jones R, Worton E, Uyttendaele H. Follicular unit extraction: minimally invasive surgery for hair transplantation. *Dermatol Surg* 2002;28:720-728.
 12. Kim JC, Choi YC. Regrowth of grafted human scalp hair after removal of the bulb. *Dermatol Surg* 1995;21:312-313.
 13. Altshuler GB, Anderson RR, Manstein D, Zenie HH, Smirnov MZ. Extended theory of selective photothermolysis. *Lasers Surg Med* 2001;29:416-432.