

Unilateral Agenesis of the Lung: A Rare Entity

Authors' Contribution:
Study Design A
Data Collection B
Statistical Analysis C
Data Interpretation D
Manuscript Preparation E
Literature Search F
Funds Collection G

AEF **Urvinderpal Singh**
EF **Daksh Jhim**
EF **Sunil Kumar**
EF **Vidhu Mittal**
F **Navdeep Singh**
F **Hitesh Gour**
F **Muralidharan Ramaraj**

Department of Pulmonary Medicine, Government Medical College, Patiala, Punjab, India

Corresponding Author: Urvinderpal Singh, e-mail: singhurvinderpal@hotmail.com
Conflict of interest: None declared

Patient: Female, 15
Final Diagnosis: Unilateral agenesis of the lung
Symptoms: Sore throat with dry cough
Medication: —
Clinical Procedure: Cect of the chest and bronchoscopy
Specialty: Pulmonology

Objective: Congenital defects/diseases





Background: Agenesis of the lung, a rare congenital anomaly, arises or develops when there is disruption of evolution of the primitive lung bud, leading to complete absence of the lung, bronchi, and the main pulmonary artery. With right-sided agenesis, a variety of cardiac and other congenital malformations are more commonly seen, leading to a poor prognosis.

Case Report: A young female, aged 15 years, presented with complaints of sore throat and cough. Her x-ray of the chest showed a homogeneous opacity in the middle and lower zones on the right side with marked shift of the mediastinum to the right side. Upon investigation, she was diagnosed with agenesis of the right lung with scoliosis, without any other congenital anomaly.

Conclusions: Especially in adults, it requires a high level of good clinical judgement to identify and diagnose this congenital aberration, as they are often wrongly diagnosed as more common diseases associated with unilateral opaque hemithorax on x-ray. Hence, when confronted with an opaque hemithorax with shift of the mediastinum to the affected side in a young person, "agenesis of the lung" should be an important differential diagnosis while investigating the case.

MeSH Keywords: Agenesis • Congenital Abnormalities • Lung Diseases • Scoliosis

Full-text PDF: <http://www.amjcaserep.com/abstract/index/idArt/892385>

 1294   5  16



Background

Agenesis of the lung, a rare congenital aberration, was first observed and described by De Pozze during the autopsy of an adult woman. It is a failure of development of the primitive lung bud, and has a prevalence of 34 per million live births [1]. Muhamed, while doing a medico-legal autopsy, is credited with describing the first case of agenesis from India [2]. Pulmonary agenesis may be diagnosed in isolation, but is frequently associated with other congenital abnormalities, particularly tracheal-esophageal fistula and VACTEL (vertebral, anal, cardiac, trachea-esophageal, and limb) syndrome [3–5]. Patients with left-sided agenesis, which is more common, have a longer life expectancy than those with right-sided agenesis [6]. For unknown reasons, pulmonary agenesis of the right side is associated with a higher frequency of other congenital anomalies than the left side [7]. It is usually diagnosed in childhood, but patients with no associated anomalies and minimal or no symptoms may survive into adulthood.

Case Report

A 15-year-old female presented with sore throat and cough that began 15 days previously. The cough was dry and hacking, mainly due to irritation in the throat. There was no history of fever, wheeze, chest pain, anorexia, or weight loss. On general physical examination, she was of average build and moderately nourished, with no pallor, icterus, clubbing, engorged neck veins, or lymphadenopathy. The examination of the abdominal, musculoskeletal, and neurological systems was unrevealing. Examination of the throat showed enlarged and inflamed tonsils with an inflamed pharynx. On examination her chest was asymmetrical with the right side smaller and moving less than the left side. The trachea was deviated to the right side and heart sounds were placed in the right axillary and inframammary area. On the left side, percussion note/sound was resonant and no cardiac dullness could be elicited. On the right side it was resonant in the clavicular area, but impaired from the 4th intercostal space downward anteriorly and in a scapular line posteriorly. On auscultation, vesicular breath sounds without any accompaniments were heard on the left side and in the clavicular area on the right side. In the rest of the right lung breath sounds were absent. No heart sounds could be appreciated in the left hemithorax, while normal rhythmic heart sounds were best heard in the right inframammary and axillary area on the right side without any murmurs or any other cardiovascular abnormality. Routine hematological tests, ECG, and ultrasonography of the abdomen were essentially normal. Echo color doppler study of the heart was essentially normal, but showed the cardiac activity in the right infra-axillary area.

A radiograph of the chest showed homogeneous opacity in the right middle and lower zone, obliterating both cardio-phrenic and costophrenic angle with marked shifting of the mediastinum

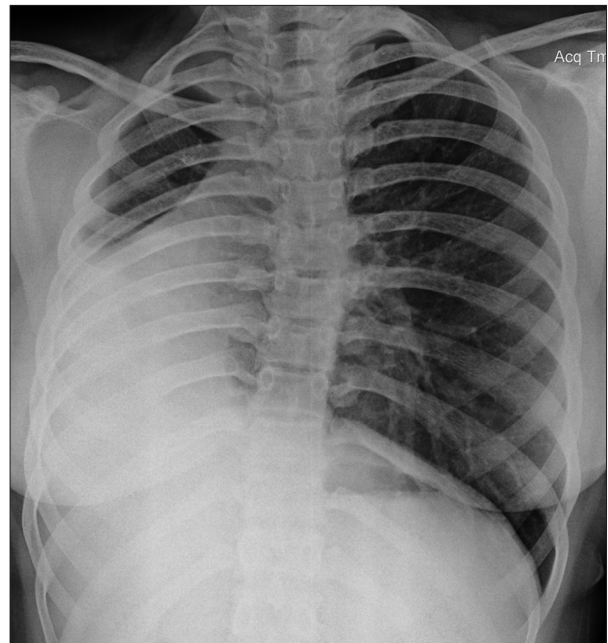


Figure 1. X-ray chest PA view. A homogeneous opacity in the right middle and lower zone with shift of the mediastinum to the right side along with scoliosis.

to the right and scoliosis with convexity to the left (Figure 1). Contrast-enhanced computed tomography (CECT) of the chest showed complete absence of the right lung with marked shift of the mediastinum to the right side, and the left lung was also seen herniating to the right side (Figures 2 and 3). The CECT also showed complete absence of the right pulmonary artery (Figure 4). Fibre-optic bronchoscopy, which was done to visually assess the right bronchus, showed an abrupt ending of the right main bronchus at the carina (Figure 5). Upon review of the results, she was diagnosed as agenesis of lung with scoliosis. She was treated for the upper respiratory tract infection (URI), which brought her to us, and eventually led to the diagnosis of agenesis of the lung. The patient and her parents have been informed about her congenital anomaly and advised to report to this institute immediately if she develops any symptoms related to the respiratory system. She is on regular follow-up visits.

Discussion

Pulmonary agenesis is a rare malformation usually seen alone or in association with other anomalies. Initially classified by Schneider and Schawatbe [8] and later modified by Boyden [9] depending upon the stage of development of the primitive bud, agenesis of the lung is divided into 3 variants.

Type 1 (Agenesis) is complete absence of pulmonary parenchyma and bronchus and absence of the pulmonary artery on the affected side.

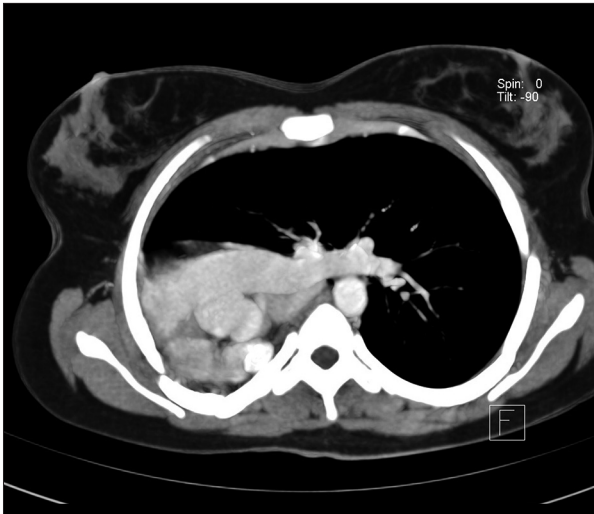

Figure 2. CECT of the chest showing gross shift of the mediastinum towards the right side.

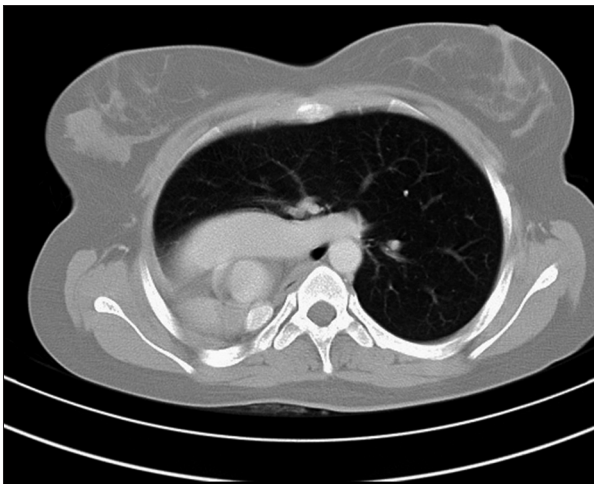


Figure 3. CECT of the chest showing herniation of the left lung in the right hemithorax.

Type 2 (Aplasia) is complete absence of pulmonary parenchyma but with a rudimentary bronchus.

Type 3 (Hypoplasia) is variable amounts of pulmonary parenchyma, bronchi, and supporting vessels are present.

Pulmonary agenesis can occur between the 4th and 5th week of gestation in the embryonic phase, before the pseudoglandular period, when the primitive lungs are forming as a diverticulum protruding from the foregut [10]. The exact etiology of this condition is unknown, but genetic factors, viral agents, and dietary deficiency of vitamin A during pregnancy are alleged to be responsible [11]. It is hypothesized that either a simple arrest of development occurs (bilateral agenesis) or there is failure to maintain the developmental balance of the 2 lung buds [12].

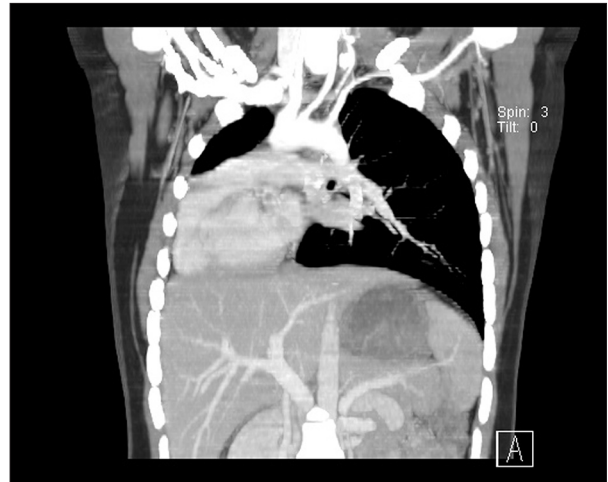


Figure 4. CECT of the chest showing complete absence of the right pulmonary artery.

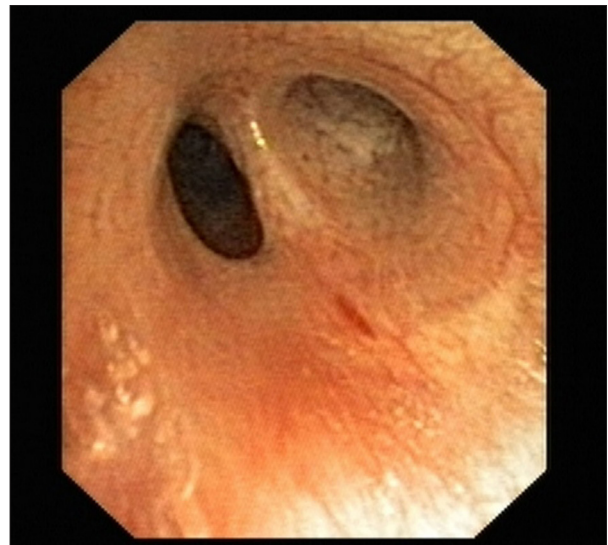


Figure 5. Bronchoscopic view at the carina showing the right main bronchus ending in a blind pouch.

Of the 2 lungs, the left lung is affected more often, with a male predominance [13]. Nonetheless, many reports have established that right-sided agenesis is usually associated with other congenital anomalies, mainly cardiac malformations, and because of these manifold anomalies most patients die within the first year of life [14]. Our patient had agenesis of the right side, but aside from scoliosis we could not find any other congenital anomaly.

Patients with agenesis may present with remarkably unpredictable symptoms. In infancy this anomaly is usually diagnosed because of recurrent chest infections and/or symptoms traceable to associated congenital anomalies. However, patients with 1 lung have been known to lead healthy lives into adulthood and the oldest patient was 72 years of age when

diagnosed with agenesis, as reported by Oyamada et al. [6]. Many patients are recognized incidentally in adulthood on the basis of abnormal chest X-rays ordered for other reasons [15]. Our patient presented with the complaint of sore throat and cough, which led to the diagnosis of agenesis of the lung.

The diagnosis of agenesis of the lung is usually suspected from the chest radiograph, which commonly reveals a homogeneous opacity occupying most of the affected hemithorax and displacement of the mediastinal contents into the empty hemithorax. In our patient the opacity occupied mainly the middle and lower zone on the right side, along with a shift of the mediastinal contents towards the affected side. Differential diagnosis on X-ray include collapse, destroyed lung, post-pneumonectomy, thickened pleura, and agenesis [16]. Currently, chest CECT, which renders comprehensive descriptions of parenchyma, bronchial tree, and vasculature, suffices to diagnose agenesis, and invasive procedures such as pulmonary angiography and bronchography are seldom attempted. CECT findings show an opaque hemithorax with a shift of the mediastinum to affected side and herniation of the healthy lung to the affected side, as in our patient. Although not necessary, bronchoscopy, if available, may be performed for visualization of the rudimentary or absent bronchus.

Regarding management, asymptomatic cases need no intervention, but prevention of infection in the solitary lung is of paramount importance. Chest infections of the solitary lung

can be life-threatening and should be treated promptly and aggressively with antibiotics, bronchodilators, and physiotherapy. Asymptomatic cases and patients with minimal symptoms have good prognosis.

Conclusions

Pulmonary agenesis of the right side, without any other congenital anomaly, as seen in the present case, is extremely rare. Diagnosing a developmental anomaly of the lungs in adults is challenging for clinicians. By reporting this case, we emphasize that in “young patients presenting with an opaque hemithorax”, an infrequent condition like agenesis of the lung should be considered in the differential diagnosis while investigating the case.

Acknowledgement

We would like to thank Dr Vishal Chopra, Associate Professor in our institute, for doing the bronchoscopy.

Conflict of interest

The authors declare that there is no conflict of interest, financial or otherwise, related to the publication of this study or its findings.

References:

1. Borja AR, Ransdell HT, Villa S: Congenital development arrest of the lung. *Ann Thorac Surg*, 1970; 10: 317–26
2. Muhamed KSN: Absence of left lung. *Ind Med Gaz*, 1923; 58: 262–64
3. Osborne J, Masel J, McCredie J: A spectrum of skeletal anomalies associated with pulmonary agenesis: possible neural crest injuries. *Pediatr Radiol*, 1989; 19: 425–32
4. Cunningham ML, Mann N: Pulmonary agenesis: a predictor of ipsilateral malformations. *Am J Med Genet*, 1997; 70: 391–98
5. Knowles S, Thomas RM, Lindenbaum RH et al: Pulmonary agenesis as part of the VACTERL sequence. *Arch Dis Child*, 1988; 63: 723–26
6. Oyamada A, Gasul BM, Holinger PM: Agenesis of the Lung. *Am J Dis Child*, 1953; 85: 182–87
7. Sharma R, Upadhyaya V, Attar N: Pulmonary agenesis – Group I with UPAA diagnosed in elderly geriatric age. *NUJHS*, 2012; 2(2): 63–67
8. Schneider P, Schawatbe E: Die Morphologie der Missbildungen Des Menschen Under Thiere. Jena: Gustav Fischer. 1912; 3 Part.2: 817–22 [in German]
9. Boyden E: Developmental anomalies. *Am J Surg*, 1955; 89: 79–88
10. Say B, Carpenter NJ, Giacoia G, Jegathesan S: Agenesis of the lung associated with a chromosome abnormality (46, XX, 2p+). *J Med Genet*, 1980; 17: 477–78
11. Sbokos CB, McMillan IRK: Agenesis of the lung. *Brit J Dis Chest*, 1977; 3: 183–97
12. Silverman FN, Kuhn JP (eds): Normal lung and anomalies. Caffey's Paediatric diagnosis; Can integrated Imaging approach, 9th Edition. St Louis: Mosby, 1993; 443–64
13. Booth JB, Berry CL: Unilateral pulmonary agenesis. *Arch Dis Childhood*; 1967; 42: 361–74
14. Roy PP, Datta S, Sarkar A et al: Unilateral pulmonary agenesis presenting in adulthood. *Respiratory Medicine Case Reports*, 2012; 5: 81–83
15. Savaş S, Hacıevliyagil, Gunen H et al: Asymptomatic Pulmonary Agenesis: Our Experience with Two Cases. *Turkish Respiratory Journal*, 2006; 7(1): 31–33
16. Dutta D, Karlekar A, Saxena R: Agenesis of the lung. *Ann Card Anaesthes*, 2013; 16(2): 151–52