

## Retrospective Study

**Results of the open surgery after endoscopic basket impaction during ERCP procedure**

Sezgin Yilmaz, Ogun Ersen, Taner Ozkececi, Kadir S Turel, Serdar Kokulu, Emre Kacar, Murat Akici, Murat Cilekar, Ozgur Kavak, Yuksel Arikan

Sezgin Yilmaz, Ogun Ersen, Taner Ozkececi, Yuksel Arikan, Department of General Surgery, Kocatepe University, 03020 Afyon, Turkey

Kadir S Turel, Murat Akici, Murat Cilekar, Ozgur Kavak, Department of General Surgery, State Hospital, 03020 Afyon, Turkey

Serdar Kokulu, Department of Anaesthesiology, Kocatepe University, 03020 Afyon, Turkey

Emre Kacar, Department of Radiology, Kocatepe University, 03020 Afyon, Turkey

**Author contributions:** Yilmaz S contributed to conception and design of the study, acquisition of data, drafting the article and final approval of the version of the article, making revisions and performing the ERCP procedures, carrying out the operations; Ersen O, Turel KS, Akici M, Cilekar M and Kavak O contributed to conception and design of the study, acquisition of data, drafting the article and final approval of the version of the article; Ozkececi T contributed to conception and design of the study, acquisition of data, drafting the article and final approval of the version of the article, performing the ERCP procedures; Kokulu S contributed to conception and design of the study, acquisition of data, drafting the article and final approval of the version of the article, anesthesia protocol and postoperative care; Kacar E contributed to conception and design of the study, acquisition of data, drafting the article and final approval of the version of the article, radiological evaluations; Arikan Y contributed to conception and design of the study, acquisition of data, drafting the article and final approval of the version of the article, performing the ERCP procedures, carrying out the operations and final revision of the manuscript.

**Ethics approval:** The study was reviewed and approved by the Afyon Kocatepe University, The Ethical Committee of Medical Faculty.

**Informed consent:** All the patients in the study gave written informed consent prior to study enrollment.

**Conflict-of-interest:** The authors declare that they have no conflict of interest.

**Data sharing:** Technical appendix, statistical code and dataset are available from the corresponding author (SY, [drsezgin-yilmaz@gmail.com](mailto:drsezgin-yilmaz@gmail.com)).

**Open-Access:** This article is an open-access article which was selected by an in-house editor and fully peer-reviewed by external reviewers. It is distributed in accordance with the Creative

Commons Attribution Non Commercial (CC BY-NC 4.0) license, which permits others to distribute, remix, adapt, build upon this work non-commercially, and license their derivative works on different terms, provided the original work is properly cited and the use is non-commercial. See: <http://creativecommons.org/licenses/by-nc/4.0/>

**Correspondence to:** Sezgin Yilmaz, MD, Department of General Surgery, Kocatepe University, Gazlıgöl Yolu, Ahmet Necdet Sezer Kampusü, Gazlıgöl Yolu, 03020 Afyon, Turkey. [drsezgin-yilmaz@gmail.com](mailto:drsezgin-yilmaz@gmail.com)

Telephone: +90-505-5786290

Received: September 1, 2014

Peer-review started: September 2, 2014

First decision: November 27, 2014

Revised: December 6, 2014

Accepted: January 9, 2015

Article in press: January 12, 2015

Published online: February 27, 2015

**Abstract**

**AIM:** To report the results of open surgery for patients with basket impaction during endoscopic retrograde cholangiopancreatography (ERCP) procedure.

**METHODS:** Basket impaction of either classical Dormia basket or mechanical lithotripter basket with an entrapped stone occurred in six patients. These patients were immediately operated for removal of stone(s) and impacted basket. The postoperative course, length of hospital stay, diameter of the stone, complication and the surgical procedure of the patients were reported retrospectively.

**RESULTS:** Six patients (M/F, 0/6) were operated due to impacted basket during ERCP procedure. The mean age of the patients was  $64.33 \pm 14.41$  years. In all cases the surgery was performed immediately after the failed ERCP procedure by making a right

subcostal incision. The baskets containing the stone were removed through longitudinal choledochotomy with the stone. The choledochotomy incisions were closed by primary closure in four patients and T tube placement in two patients. All patients were also performed cholecystectomy additionally since they had cholelithiasis. In patients with T-tube placement it was removed on the 13<sup>th</sup> day after a normal T-tube cholangiogram. The patients remained stable at postoperative period and discharged without any complication at median 7 d.

**CONCLUSION:** Open surgical procedures can be applied in patients with basket impaction during ERCP procedure in selected cases.

**Key words:** Biliary stone; Endoscopic retrograde cholangiopancreatography; Basket; Impaction; Surgery

© **The Author(s) 2015.** Published by Baishideng Publishing Group Inc. All rights reserved.

**Core tip:** The impaction or wire fracture of basket is an uncommon but potentially highly dangerous complication during endoscopic retrograde cholangiopancreatography and stone extraction. Although there are several endoscopic approaches to treat the basket impaction they require specialized equipments and experienced clinicians. So surgical approach can be an alternative to endoscopic procedures in selected patients.

Yilmaz S, Ersen O, Ozkececi T, Turel KS, Kokulu S, Kacar E, Akici M, Cilekar M, Kavak O, Arikan Y. Results of the open surgery after endoscopic basket impaction during ERCP procedure. *World J Gastrointest Surg* 2015; 7(2): 15-20 Available from: URL: <http://www.wjgnet.com/1948-9366/full/v7/i2/15.htm> DOI: <http://dx.doi.org/10.4240/wjgs.v7.i2.15>

## INTRODUCTION

Endoscopic retrograde cholangiopancreatography (ERCP) is mainly indicated for choledocholithiasis as well as pancreatic stones<sup>[1,2]</sup>. It can be performed to remove the biliary stones when combined with sphincterotomy. Bile duct stones are successfully removed with classical Dormia basket or balloon catheters in 85%-95% of the patients<sup>[3]</sup>. Mechanical lithotripsy is the second line method for non-extractable stones with conventional basket aside from availability and cost<sup>[4,5]</sup>. Several types of baskets (mechanic lithotripter or wire baskets) can be used for this purpose<sup>[6]</sup>. The success rates depend on several factors as size and number of the stones, degree of the jaundice and presence of cholecystitis. Complications of ERCP have been reported to occur in 5%-10% of the cases<sup>[7]</sup>. Basket related complications can be seen as impaction around a calculus or fracture of the traction wire. Endoscopic

basket impaction is a rare and unusual complication that can be seen after an attempt for removal of biliary stones with basket. It is not encountered in classical ERCP complications in textbooks due to its extremely rare occurrence. Actually it is a problem of high volume centers. It is defined as inability to withdraw the basket with stone from papillary orifice or separate the stone from the basket in biliary channel lumen. Since there are only sporadic case reports, the precise treatment is still controversial<sup>[8]</sup>. At present endoscopic or surgical procedures can be applied for the basket impaction. Non operative maneuvers like extracorporeal shock wave, intracorporeal electrohydraulic lithotripsy, catching the basket tip with a second basket, balloon dilatation of the sphincterotomy area or laser lithotripsy are recommended at high technology units<sup>[9-11]</sup>. However these procedures require experienced endoscopists and sophisticated technological equipment. Therefore open surgery is still an alternative approach for such patients. In the present study, we reported the results of six patients with endoscopic basket impaction that have been treated with open surgery. To our best knowledge the present report is the largest series so far.

## MATERIALS AND METHODS

### Patients

This retrospective observational study was carried out between June 2008 and June 2014. A total of 1065 ERCP procedures were performed at our invasive endoscopic procedures unit for choledocholithiasis at this period. The total number of ERCP was 2092. Basket impaction of either classical Dormia basket or mechanical lithotripter basket with an entrapped stone were observed in six patients (0.28%). The mean age of the patients was 64.33 ± 14.41 years and they were all female. The patients were admitted with the right upper abdominal pain. Laboratory findings were consistent with cholestasis and obstructive jaundice. Ultrasonography and magnetic resonance cholangiopancreatography (MRCP) revealed one to seven pieces of biliary stones sizes ranging from 15 mm to 30 mm in diameter and dilated choledochus which had a diameter above 15 mm. A diagnosis of obstructive jaundice secondary to choledocholithiasis was made and the patients were proceeded to an ERCP with planned removal of biliary stone. The median age of our patients was 63 years (range 45-81 years). The periampullary diverticulum was present in four patients. In five patients, impacted basket was Dormia and in one impaction occurred with mechanical lithotripter basket. The clinical data and the endoscopic features of the patients are represented in Tables 1 and 2. All patients in the work gave informed consent for the study prior to manuscript preparation.

Case	Age	LOS	Comorbidity	Surgical procedure	Additional procedure	PO complication
1	59	7	HF	T-Tube placement	Cholecystectomy	None
2	54	8	None	Primary closure	Cholecystectomy	None
3	80	4	None	Primary closure	Cholecystectomy	None
4	67	3	None	Primary closure	Cholecystectomy	Atelectesis
5	81	7	COLD	T-Tube placement	Cholecystectomy	SSI
6	45	9	HT	Primary closure	Cholecystectomy	SSI

LOS: Length of hospital stay; PO: Postoperative; HF: Heart failure; HT: Hypertension; SSI: Surgical site infection; COLD: Chronic obstructive lung disease.

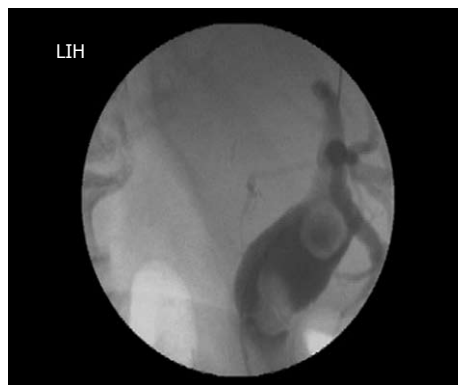Case	Diameter of the choledochus (mm)	Maximum biliary stone size (mm)	No. of stones	Impaction type	Presence of diverticula
1	15	15	1	Dormia	Yes
2	20	20	3	Dormia	No
3	30	30	6	Litotripter	No
4	30	30	1	Dormia	Yes
5	25	20	7	Dormia	Yes
6	20	20	2	Dormia	Yes

**Anaesthesia protocol and medication**

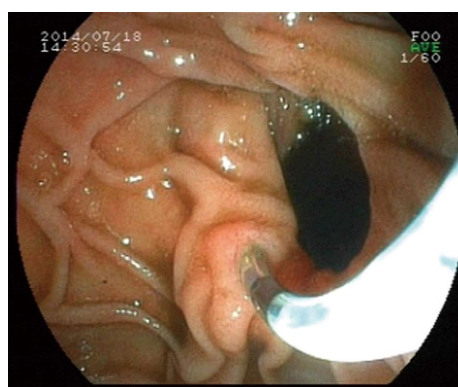
All patients received fentanyl (1 µg/kg) before the procedure and a single dose of 0.04 mg/kg midazolam intravenously and additional doses of 0.5 mg midazolam until the Ramsey Sedation Score reached 3-4 points. We used the additional doses of midazolam to keep the consciousness to allow communication, while providing the necessary degree of sedation to enable surgical comfort and an adequate quality of recovery with no negative effects on haemodynamics and respiratory parameters. During procedure a routine antibiotic prophylaxis (*iv* cefazolin 1 g) was administered and duodenal peristalsis was reduced by *iv* hyoscine-n-butylbromide.

**Endoscopic procedure**

Endoscopic procedures and ensuing surgical procedures were performed by one of the three consultant surgeons themselves (SY, TO, YA). Following the demonstration and cannulation of the papilla, a cholangiography was obtained revealing the huge stone(s) (Figure 1). First conventional basket was tried to remove the stone from papilla (Figure 2). If it was unsuccessful and the stone could be separated from basket than basket was removed and mechanical lithotripter was placed to crush the stone(s). In both instances if the basket



**Figure 1** Cholangiography demonstrating the two giant sharp edged stones.



**Figure 2** Cannulation through the papillary orifice located near to a big diverticula.

stone complex couldn't be pulled out papillary orifice despite forceful traction or basket couldn't be disengaged from the stone, the diagnosis of basket impaction was verified (Figure 3). The basket impaction occurred within the intraduodenal portion of the choledochus in all patients. In this instance the handle site of basket wire was cut with Kirshner cutter, duodenoscope was removed and the patient was transferred to operating room with distal end of the basket emerging from the mouth (Figure 4). In all cases the surgery was performed immediately after the failed ERCP procedure by making a right subcostal incision. The baskets containing the stone were removed through longitudinal choledochotomy (Figure 5). The choledochotomy incisions were closed by primary closure in four patients and T tube placement in two patients. All patients were also performed cholecystectomy additionally since they had cholelithiasis. In patients with T-tube placement it was removed on the 13<sup>th</sup> day after a normal T-tube cholangiogram. The patients remained stable at postoperative period and discharged without any complication at median 7 d.

**Statistical analysis**

Since the present study is a retrospective descript

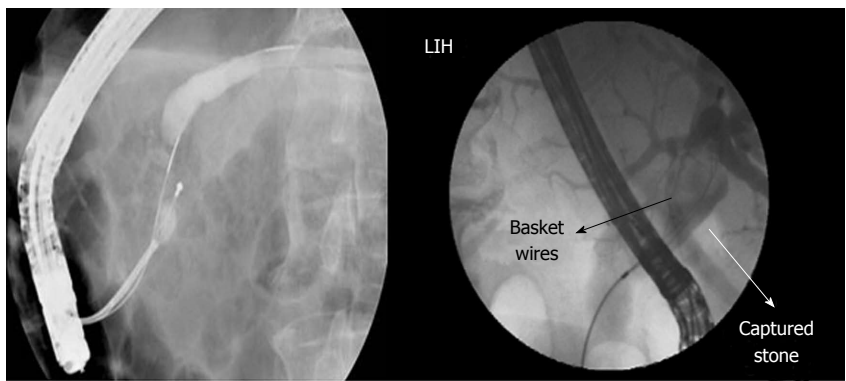


Figure 3 Basket attempts with Dormia to remove the angled (right) and round (left) stones.

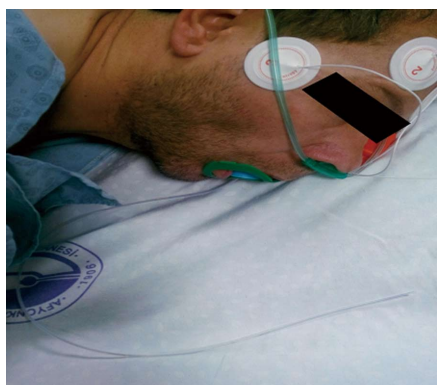

Figure 4 Following a failed removal of a stone, the transfer of the patient to the operating room while the cut edge of basket handle emerging from the mouth immediately after the procedure.

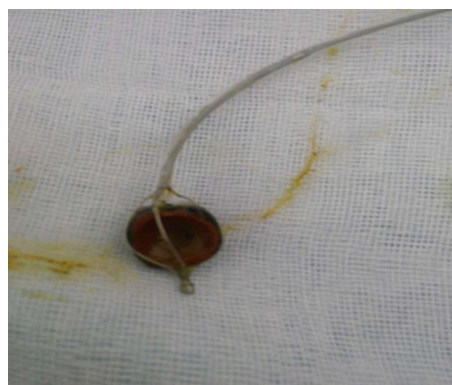

Figure 5 Removal of the entrapped basket and stone complex through a longitudinal choledochotomy incision.

study, we didn't perform any Statistical evaluation.

## DISCUSSION

ERCP is an important endoscopic procedure with more than 500000 procedures performed yearly in the United States<sup>[7]</sup>. Although the precise number in our country is not known, we are performing approximately 300 procedures annually in our centre. Nearly half of these are due to biliary stones. ERCP, sphincterotomy and stone extraction are currently the best method to remove the stones in biliary system<sup>[12]</sup>. There are several complications including bleeding, perforation sepsis, pancreatitis and cholangitis following ERCP.

Endoscopy clinicians who perform more than 200 ERCP procedures per year (high volume centre) have been shown to have fewer complications than less experienced endoscopists who perform < 200 ERCPs per year<sup>[7]</sup>. There are several kinds of baskets made from metal wires and available in a variety of sizes and configurations to remove the biliary stones. Basket impaction is relatively rare but potentially quite dangerous complication during ERCP procedure. So far Katsinelos *et al*<sup>[13]</sup> reported the largest series of basket impaction that is the seven cases within 2715 ERCP procedures<sup>[13]</sup>. They treated such cases with endoscopic approach in six cases and one case was managed successfully with

surgery. In the present study we reported the results of open surgery in six patients with basket impaction out of 2092 ERCP procedures between June 2008-June 2014. The incidence is approximately 0.28% that is quite similar to the rate observed in previous case series (0.26%). Although the incidence is very low, impaction of a basket with an entrapped stone may cause cholangitis, pancreatitis, sepsis and even death, thereby usually requiring open surgery or other specialized endoscopic techniques<sup>[12,14,15]</sup>. However endoscopic "rescue" interventions mostly require skilled experience and sophisticated endoscopic devices that are not widely available in many endoscopy centres. Additionally failed efforts may deteriorate the patient's clinical condition and even lead to perforation, hemorrhage and severe inflammation around the papilla that make an eventual open surgery more complicated. It can be seen both after conventional Dormia basket or mechanical lithotripter basket usage. Dormia basket may fail in the presence of large stone, in which case mechanical lithotripsy should be the latter choice in the treatment of choledocholithiasis. Mechanical lithotripter is able to crush the biliary stones into pieces so they can be taken out from the papillary orifice with conventional basket easily. However the success rate is low if there are multiple stones and/or calcified stones and the stone size exceeds 20 mm. If the diameter of biliary stone is more than 20 mm than the risk of basket impaction

as well as fracture of the basket at the junction between the distal and proximal parts may occur<sup>[8]</sup>. Once the basket catch the stone, there should be enough space between the stone and biliary channel wall to release the stone from basket in case of failed crushing. By definition basket impaction is expressed as inability to withdraw the basket with stone from papillary orifice or separate the stone from the basket in biliary channel lumen. Since there are only sporadic case reports, the precise treatment is still controversial. At present endoscopic or surgical procedures can be recommended after basket impaction. Endoscopic procedures should be tried if there is adequate experience and specialized endoscopic devices. In such a case extension of the sphincterotomy should be attempted first since the most likely cause of impaction is inadequate sphincterotomy and tissue edema. It can be applied when it is clear that the sphincterotomy can be safely extended. The special equipment required is a duodenoscope with a 4.2 mm working channel<sup>[16]</sup>. However this can lead to duodenal perforation in inexperienced hands. Percutaneous transhepatic route can also be used in suitable cases by using a goose-neck snare in skilled radiology department<sup>[3]</sup>. Dilating the papillary orifice is sometimes useful to remove the impacted stone-basket complex with the larger balloon<sup>[17,18]</sup>. These endoscopic procedures are sophisticated and not widely available everywhere. Basket impaction represents a surgical emergency unless other non operative maneuvers like extracorporeal shock wave, intracorporeal electrohydraulic lithotripsy or catching the basket tip with a second basket are available<sup>[9-11,19]</sup>. Additionally since our patients required additional surgical procedures for cholelithiasis, open surgery was preferred to treat the current basket impaction problem. In our series all patients also had cholelithiasis thus required cholecystectomy. The basket stone complex was removed through a longitudinal choledochotomy incision. It was repaired with primary closure in four patients and T-tube placement in two patients. In our centre we routinely close choledochotomy incision primarily in patients with previous sphincterotomy. But two patients in the present report were treated with T-tube placement since there are severe inflammation, cholangitis and transmural thickening at the biliary channel. The frequency of diverticula at our 2092 ERCP procedures is approximately 25%, but in the present report we found that 4 patients in 6 basket impaction had duodenal diverticula. This high ratio considered us that the occurrence of periampullary diverticula might be a predisposing factor for basket impaction. Small number of patients is our limitation so that the results can not be extrapolated to surgery clinics. However to our knowledge it is the largest series dealing with the open surgery in such patients. So it can suggest an

alternative surgical approach besides endoscopic interventions in otherwise healthy patients without comorbidity. In conclusion impaction or wire fracture of basket is an uncommon complication during ERCP and stone extraction. There are several treatment protocols and it should be tailored to the patient's clinical condition, endoscopist's experience and ERCP unit equipment.

## COMMENTS

### Background

Endoscopic retrograde cholangiopancreatography (ERCP) is mainly indicated for choledocholithiasis. Endoscopic basket impaction is a rare and unusual complication that can be seen after an attempt for removal of biliary stones with basket during ERCP. It is defined as inability to withdraw the basket with stone from papillary orifice or separate the stone from the basket in biliary channel lumen. Endoscopic or surgical procedures can be applied for the basket impaction. Non operative endoscopic maneuvers like extracorporeal shock wave, intracorporeal electrohydraulic lithotripsy, catching the basket tip with a second basket, balloon dilatation of the sphincterotomy area or laser lithotripsy are preferable at high technology units. However open surgical procedures can also be applied in selected cases.

### Research frontiers

In the present study, the authors reported the results of six patients with endoscopic basket impaction that have been treated with open surgery.

### Innovations and breakthroughs

In literature non-operative endoscopic procedures are widely recommended for ERCP-related basket impactions. These procedures require experienced endoscopists and sophisticated technological equipment. However these techniques and endoscopic devices are not widely available in every endoscopy centre. Therefore open surgery is still an alternative approach for such patients.

### Applications

Open surgery by performing choledochotomy can be applied for the patients with basket impaction during ERCP procedure as an alternative to endoscopic interventions in selected cases.

### Terminology

ERCP is abbreviation of endoscopic retrograde cholangiopancreatography and is an endoscopic technique to view the biliary and pancreatic channels. It is also used to remove the stones from these channels. Basket impaction is defined as inability to withdraw the basket with stone from papillary orifice or separate the stone from the basket in biliary channel lumen. It can be treated with open surgery including choledochotomy (incizing the choledochus and removing the stone and basket together) and closing the choledochus by primary closure or T-tube placement.

### Peer-review

This paper reported the results of six patients with endoscopic basket impaction that have been treated with open surgery. The results are interesting and encouraging, which provided the practical basis that open surgical procedures could be selected when endoscopic basket impaction occurred.

## REFERENCES

- 1 **Chan CH**, Donnellan F, Chan GC, Byrne MF. A novel two-step approach for retrieval of an impacted biliary extraction basket. *Case Rep Gastrointest Med* 2012; **2012**: 435050 [PMID: 22953076 DOI: 10.1155/2012/435050]
- 2 **Hlaing C**, Tamasky P, Hambrick D. Laser lithotripsy to treat basket impaction during mechanical lithotripsy of a pancreatic duct stone. *JOP* 2012; **13**: 101-103 [PMID: 22233959]
- 3 **Kwon JH**, Lee JK, Lee JH, Lee YS. Percutaneous transhepatic release of an impacted lithotripter basket and its fractured traction wire using a goose-neck snare: a case report. *Korean J Radiol* 2011; **12**: 247-251 [PMID: 21430943 DOI: 10.3348/kjr.2011.12.2.247]
- 4 **Hochberger J**, Tex S, Maiss J, Hahn EG. Management of difficult common bile duct stones. *Gastrointest Endosc Clin N Am* 2003; **13**:

- 623-634 [PMID: 14986790 DOI: 10.1016/S1052-5157(03)00102-8]
- 5 **Schneider MU**, Matek W, Bauer R, Domschke W. Mechanical lithotripsy of bile duct stones in 209 patients--effect of technical advances. *Endoscopy* 1988; **20**: 248-253 [PMID: 3168938 DOI: 10.1055/s-2007-1018186]
  - 6 **Sezgin O**, Tezel A, Sahin B. Dormia basket fracture: an unusual complication of mechanical lithotripsy. *J Clin Gastroenterol* 2000; **30**: 215 [PMID: 10730934 DOI: 10.1097/00004836-200003000-00021]
  - 7 **Silviera ML**, Seamon MJ, Porshinsky B, Prosciak MP, Doraiswamy VA, Wang CF, Lorenzo M, Truitt M, Biboa J, Jarvis AM, Narula VK, Steinberg SM, Stawicki SP. Complications related to endoscopic retrograde cholangiopancreatography: a comprehensive clinical review. *J Gastrointest Liver Dis* 2009; **18**: 73-82 [PMID: 19337638]
  - 8 **Fukino N**, Oida T, Kawasaki A, Mimatsu K, Kuboi Y, Kano H, Amano S. Impaction of a lithotripsy basket during endoscopic lithotomy of a common bile duct stone. *World J Gastroenterol* 2010; **16**: 2832-2834 [PMID: 20533607 DOI: 10.3748/wjg.v16.i22.2832]
  - 9 **Schutz SM**, China C, Friedrichs P. Successful endoscopic removal of a severed, impacted Dormia basket. *Am J Gastroenterol* 1997; **92**: 679-681 [PMID: 9128323]
  - 10 **Sheridan J**, Williams TM, Yeung E, Ho CS, Thurston W. Percutaneous transhepatic management of an impacted endoscopic basket. *Gastrointest Endosc* 1993; **39**: 444-446 [PMID: 8514084 DOI: 10.1016/S0016-5107(93)70127-3]
  - 11 **Ranjeev P**, Goh KI. Retrieval of an impacted Dormia basket and stone in situ using a novel method. *Gastrointest Endosc* 2000; **51**: 504-506 [PMID: 10744838 DOI: 10.1016/S0016-5107(00)70463-9]
  - 12 **Maple JT**, Baron TH. Biliary-basket impaction complicated by in vivo traction-wire fracture: report of a novel management approach. *Gastrointest Endosc* 2006; **64**: 1031-1033 [PMID: 17140927 DOI: 10.1016/j.gie.2006.04.023]
  - 13 **Katsinelos P**, Lazaraki G, Chatzimavroudis G, Gkagkalis S, Vasiliadis I, Papaeuthimiou A, Terzoudis S, Pilpilidis I, Zavos C, Kountouras J. Risk factors for therapeutic ERCP-related complications: an analysis of 2,715 cases performed by a single endoscopist. *Ann Gastroenterol* 2014; **27**: 65-72 [PMID: 24714755]
  - 14 **Katsinelos P**, Fasoulas K, Beltsis A, Chatzimavroudis G, Zavos C, Terzoudis S, Kountouras J. Large-balloon dilation of the biliary orifice for the management of basket impaction: a case series of 6 patients. *Gastrointest Endosc* 2011; **73**: 1298-1301 [PMID: 21492853 DOI: 10.16/j.gie.2011.01.034]
  - 15 **Nuehaus B**, Safrany L. Complications of endoscopic sphincterotomy and their treatment. *Endoscopy* 1981; **13**: 197-199 [PMID: 7274168]
  - 16 **Borgaonkar M**. Impacted biliary basket. *Gastrointest Endosc* 2005; **62**: 474 [PMID: 16111986 DOI: 10.1016/j.gie.2005.04.041]
  - 17 **Maydeo A**, Bhandari S. Balloon sphincteroplasty for removing difficult bile duct stones. *Endoscopy* 2007; **39**: 958-961 [PMID: 17701853]
  - 18 **Mabuchi M**, Iwashita T, Yasuda I, Okuno M, Uemura S, Nakashima M, Doi S, Adachi S, Shimizu M, Mukai T, Tomita E, Moriwaki H. Endoscopic papillary large balloon dilation as a salvage procedure for basket impaction during retrieval of common bile duct stones. *Dig Dis Sci* 2014; **59**: 220-223 [PMID: 23979442 DOI: 10.1007/s10620-013-2845-0]
  - 19 **Kwon CI**, Song SH, Hahm KB, Ko KH. Unusual complications related to endoscopic retrograde cholangiopancreatography and its endoscopic treatment. *Clin Endosc* 2013; **46**: 251-259 [PMID: 23767036 DOI: 10.5946/ce.2013.46.3.251]

**P- Reviewer:** Abu-Zidan FM, Han JH, Sun WB  
**S- Editor:** Ji FF **L- Editor:** A **E- Editor:** Wu HL





Published by **Baishideng Publishing Group Inc**

8226 Regency Drive, Pleasanton, CA 94588, USA

Telephone: +1-925-223-8242

Fax: +1-925-223-8243

E-mail: [bpgoffice@wjgnet.com](mailto:bpgoffice@wjgnet.com)

Help Desk: <http://www.wjgnet.com/esps/helpdesk.aspx>

<http://www.wjgnet.com>

