

Carotid intima-media thickness (CIMT) and carotid plaques in young Nepalese patients with angiographically documented coronary artery disease

Yuba Raj Limbu, Rajib Rajbhandari, Ranjit Sharma, Satish Singh, Dipak Limbu, Chandra Mani Adhikari, Dipankar Prajapati

Department of Cardiology, Shahid Gangalal National Heart Centre, PO Box NO 11360, Karhmandu, Nepal

Correspondence to: Yuba Raj Limbu, PhD. Department of Cardiology, Shahid Gangalal National Heart Centre, PO Box NO 11360, Karhmandu, Nepal. Email: yrlimbu@yahoo.com.

Background: Carotid intima-media thickness (CIMT) and carotid plaques are non-invasive surrogate markers of early evaluation of coronary artery disease (CAD) and sub clinical atherosclerosis. The objective of the study was to evaluate CIMT and carotid plaques in less than 45 years old Nepalese patients with angiographically proven CAD.

Methods: A total of 54 patients with angiographically documented CAD at less than 45 years of age were enrolled. CAD was confirmed by coronary angiography. Demographic profile was obtained. High resolution B-mode ultrasound was used to detect the CIMT and carotid plaques.

Results: The study population included 44 males and 10 females, with a mean \pm SD age of 38.4 \pm 4.3 years (range, 25-44 years). Cardiovascular risks factors included smoking in 81%, Hypertension in 52%, diabetes in 19% and alcohol consumption in 78% of patients. Lipid profile (mean \pm SD) was normal except for elevated triglyceride (TG) levels of 204 \pm 130.8 mg/dL. By angiography, 64.8% had single vessel disease, 26% had double vessel disease and 9.2% had triple vessel disease. Ultrasound detected either thickened CIMT or presence of plaques in 46 (85.2%) cases (group-A) and 8 (14.8%) had negative (normal) carotid study (group-B). Among the 46 patients with positive findings 63% had carotid plaques and 37% had thickened CIMT only. The majority (69%) of the carotid plaques were detected at the carotid bulbs. In total population, carotid plaque was detected in 53.7% of cases. There was no statistical significant difference of age, body mass index (BMI) and lipid level between group-A and group-B.

Conclusions: Increased CIMT and carotid plaques are detected in majority of the young Nepalese patients with angiographically documented CAD. The majority of carotid plaques are detected at the carotid bulbs. Routine carotid ultrasound study in young individuals with CAD risk factors appears worthwhile.

Keywords: Coronary artery disease (CAD); carotid intima-media thickness (CIMT); carotid plaques

Submitted Oct 25, 2014. Accepted for publication Jan 13, 2015.

doi: 10.3978/j.issn.2223-3652.2015.01.10

View this article at: <http://dx.doi.org/10.3978/j.issn.2223-3652.2015.01.10>

Introduction

Assessment of carotid intima-media thickness (CIMT) and carotid plaques are emerging as surrogate markers of early cardiovascular disease and sub clinical atherosclerosis (1-5). Carotid and coronary arteries are the most common sites of atherosclerosis involvement. Association of increased CIMT and carotid plaques with the extent of coronary

artery disease (CAD) has been well documented in previous postmortem and clinical of studies (6-9). Assessment of CIMT and carotid plaques is a non-invasive, feasible and reproducible method to predict the presence of coronary artery lesions.

Ultrasound measurements of arterial wall intima-media thickness correlate well with histology (10) and high

resolution B-mode ultrasonography is a valid and reliable method to assess the carotid artery dimensions, CIMT and carotid plaques (11,12). Extra cranial carotid arteries are readily assessable with high resolution ultrasonography, because of its superficial localization, size and limited movement.

Globally, CAD is a major contributor to morbidity and mortality predominantly manifests in older population. However, the incidence of asymptomatic CAD in young adults is not negligible (13) and the long term prognosis after myocardial infarction in young adults is poor (14). Therefore, the early detection of sub clinical atherosclerosis in young population is important. Data describing the prediction of clinical cardiovascular events based on CIMT and carotid plaques in younger individuals are limited (3). A thickness of less than 0.8 mm is as a normal CIMT in relatively young healthy population without traditional cardiovascular risk factors (15-17). The prevalence of carotid plaques in these populations is about 7% (18). The objective of the present study is to assess presence of carotid plaques and CIMT using carotid ultrasound in less than 45 years old Nepalese patients with angiographically proven CAD.

Methods

Study population

The source of our prospective study subjects was the hospital admitted cases with the confirmed diagnosis of CAD. All young adults with an age less than 45 years admitted with either myocardial infarction or typical anginal chest pain, who underwent coronary angiography, were enrolled in the study. The age of participants was confirmed from their citizenship card. For the study purpose, all participants were asked about smoking and alcohol habits. We attempted to find out the positive family history of CAD. Body mass index (BMI) was calculated with body weight (kg) divided by the square of height in meter. According to the current WHO classification, the normal range of BMI was considered between 18.5 to 24.9 and pre-obese or overweight was defined as BMI ≥ 25 (19).

Hypertension was defined as a systolic blood pressure ≥ 140 mmHg and/or diastolic blood pressure ≥ 90 mmHg or if they were treatment with antihypertensive medicines (20). Type 2 diabetes mellitus (T2DM) was defined in as a fasting blood glucose level was ≥ 126 mg/dL according to WHO and ADA criteria (21,22). Lipid profile of all study cases was

obtained from hospital record. Dyslipidemia was defined according to the recommendation of National Cholesterol Education Program (NCEP) guideline (23). The purpose of this study was discussed with all study participants. Verbal consent was taken from each of the participants prior to the study inclusion. Young adults with clinically overt CAD but without documents of coronary angiography were not enrolled in this study. All the study participants gave their consent and the department of the institution approved the study.

Carotid ultrasound study

All study subjects were examined in the supine position with the head tilted backward. High resolution B-mode color Doppler and pulse Doppler ultrasonography of both carotid arteries were performed with ultrasound machines (GE, vivid 7 and PHILIPS, iE33) equipped with a 7.5 MHz linear array transducer. Both common carotid arteries and internal and external carotid arteries were first identified through longitudinal images as described in our previous study (16). CIMT was defined as the distance between the leading edge of the lumen echo and the leading edge of the media-adventitia echo (24). The maximum far wall CIMT of both carotid arteries was measured through longitudinal images during diastole. The presence of carotid plaques throughout the extra cranial carotid system was meticulously observed during carotid ultrasound study. Transverse view of the both carotid arteries including carotid bulbs was also observed to enhance the interpretation of CIMT and the presence of carotid plaques during ultrasound study. A thickness of >0.8 mm was considered increased CIMT. Carotid plaque was defined as an echogenic thickening of intimal reflection that encroaches in the arterial lumen with a minimal intimal-medial thickness of >1.2 mm or a focal structure encroaching into the arterial lumen by at least 50% more of the surrounding intima-media thickness value (1,2,4,5). Plaques were characterized simply as 'present' or 'absent' with location.

Coronary angiography was performed through the femoral or radial artery using standard technique. Significant CAD was defined as a $>50\%$ reduction of the internal diameter of epicardial coronary arteries (1).

Statistical analysis

Demographic data of the study subjects are expressed in percentage and mean \pm SD. Unpaired student's *t*-test was

Table 1 Demographic profile of study population

Variables	Data
Total	54
Age (years)	
Range	25-44
Mean \pm SD	38.4 \pm 4.3
Gender (%)	
Male	81.5
Female	18.5
BMI	
Range	19.7-31.3
Mean \pm SD	24.7 \pm 2.4
CAD risk factors (%)	
Smoking	80.8
Hypertension	52.0
Diabetes mellitus	19.2
Alcohol consumption	76.9
Lipid profile (mg/dL) (mean \pm SD)	
Total cholesterol	193.2 \pm 56.6
Triglyceride	204.0 \pm 130.8
LDL-cholesterol	114.5 \pm 50.0
HDL-cholesterol	39.2 \pm 5.6
Coronary angiography profile (%)	
SVD	64.8
DVD	26.0
TVD	9.2

BMI, body mass index; CAD, coronary artery disease; SVD, single vessel disease; DVD, double vessel disease; TVD, triple vessel disease.

used to test the statistical significance of demographic data between normal CIMT group and increased CIMT or plaque containing group. Significance was accepted at $P < 0.05$.

Results

Characteristics of study population

A total of 54 patients admitted with a history of either acute myocardial infarction or typical exertional chest pain at an age of less than 45 years and angiographically proven CAD were enrolled. The age of study participants ranged from 25 to 44 years which included 44 males and 10 females. The mean \pm SD of participants' age was 38.4 \pm 4.3 years. BMI

Table 2 Comparison of age, BMI and lipid profile between group-A (either thickened CIMT or presence of carotid plaque) and group-B (normal carotid ultrasound study)

Variables	Group-A (N=46)	Group-B (N=8)	P value (NS)
Age (year)	38.9 \pm 4.7	37.7 \pm 3.7	>0.5
BMI	24.6 \pm 2.5	25.8 \pm 1.4	>0.2
Lipid profile (mg/dL)			
Total cholesterol	195.7 \pm 57.4	182.3 \pm 49.0	>0.5
Triglyceride	214.4 \pm 137.1	139.4 \pm 43.9	>0.1
LDL-cholesterol	115.6 \pm 50.4	114.4 \pm 40.8	>0.5
HDL-cholesterol	39.3 \pm 5.8	38.5 \pm 4.4	>0.5

N, number; BMI, body mass index; CIMT, carotid intima-media thickness; NS, non-significant.

of study participants ranged from 19.7 to 31.3 and mean \pm SD was 24.7 \pm 2.4. Mean total cholesterol, LDL-cholesterol and HDL-cholesterol level was found within normal range, except mean triglyceride (TG) level (204.6 mg/dL) was noted raised. Interestingly, more than 80% young CAD cases of this study were smokers. Coronary angiography revealed that 64.8% had single vessel disease, 26% had double vessel disease and 9.2% had triple vessel disease. Demographic profile of the study population is summarized in *Table 1*.

Among 54 young CAD patients, the presence of either carotid plaques or thickened CIMT was observed in 85.2% (46 cases) of the total study population (group-A). Carotid ultrasound detected the presence of carotid plaques in 53.7% (29 cases) of the total cases. So 31.5% (17 cases) of the total population had only thickened CIMT without the presence of carotid plaques. Only 14.8% cases had normal carotid ultrasound study (group-B). Statistical significance was not noted between group-A and group-B in the comparison of age, BMI, and lipid profile, although markedly elevated mean TG level in group-A than group-B (214.4 \pm 137.1 and 139.4 \pm 43.9 mg/dL, $P > 0.1$) was noted (*Table 2*). About 82% study participants were smokers in group-A, while 71% were in group-B. Similarly 51% in group-A had history of hypertension, while 71% had history of hypertension in group-B. 18% were diabetic in group-A and 28% were in group-B.

Increased CIMT, location and nature of plaques

Isolated increase of CIMT (>0.8 mm) without carotid

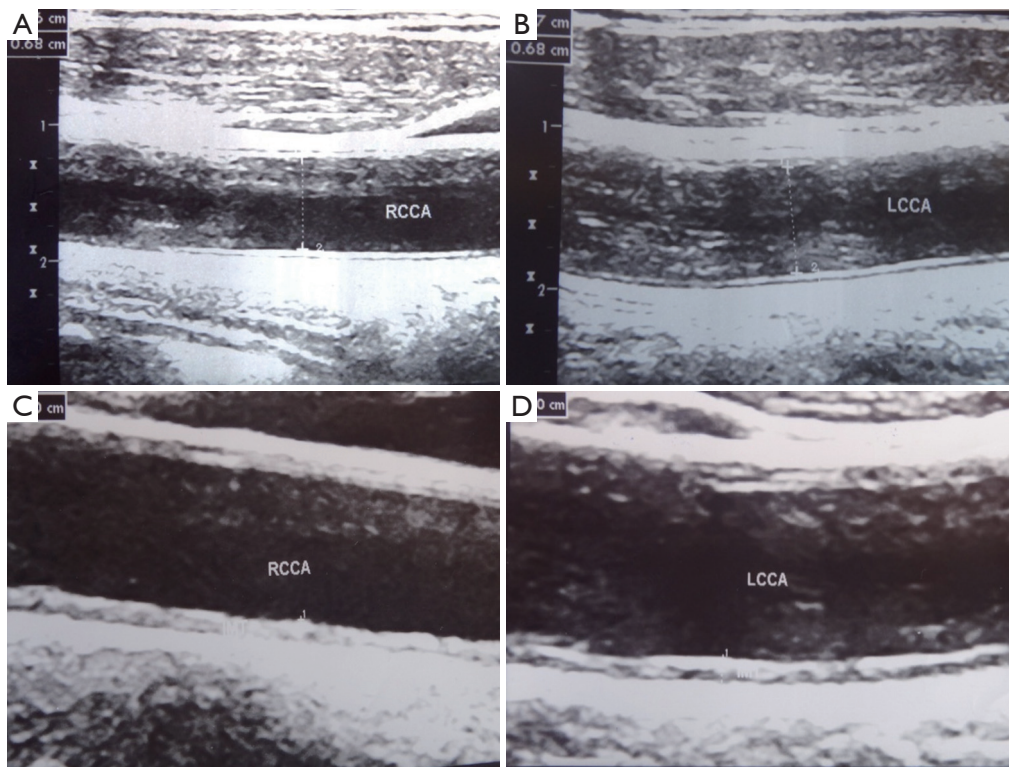


Figure 1 (A,B) Longitudinal view of bilateral common carotid arteries of 44 years old, non-smoker, non-diabetic and normotensive healthy male subject with normal bilateral CIMT; (C,D) longitudinal view of bilateral common carotid arteries of 41 years old hypertensive and smoker male patient with thickened bilateral CIMT (1.0 mm) whose coronary angiography revealed 90% stenosis in proximal LAD artery. CIMT, carotid intima-media thickness; LAD, left anterior descending.

plaques were noted in 17 (37%) out of 46 cases in group-A (*Figure 1*). Among these 17 cases 47% (8 cases) had thickened CIMT only at the level of carotid bulbs while the remaining cases had thickened CIMT at the level of common carotid arteries. Among the 46 cases in group-A, carotid plaques were detected in different carotid artery segments 29 (63%) cases. Most of the detected carotid plaques were homogenous and echolucent (soft plaques) in comparison of surrounding vascular wall. Only one calcified plaque was detected. The majority (69%) of the carotid plaques was located at carotid bulbs (*Figure 2*) and only 31% plaques were detected at carotid body (*Figure 2*).

Discussion

CAD is a major contributor to morbidity and mortality worldwide.

Rapid increment in the prevalence of CAD risk factors and CAD related hospital admissions in tertiary

heart centers in Nepal has been observed since last two decades (25). So CAD is becoming one of the most prevalent heart diseases in Nepal. Early detection of CAD and prevention programs is therefore an important goal of modern cardiovascular care. The prevalence of occult CAD in young individuals is not negligible (13), and younger patients who experience myocardial infarction have different clinical profile. Generally younger individuals do not frequently have traditional CAD risk factors (14). So they are overlooked and misdiagnosed. Non-invasive imaging studies are an emerging tool to assist in CAD risk stratification and identification of individuals at increased risk (7-9,26,27). In this study, we have used high resolution B-mode ultrasound to detect the CIMT and the presence of carotid plaques in angiographically documented less than 45 years old young Nepalese CAD patients. To our knowledge, the carotid ultrasound study of CIMT and carotid plaques in angiographically proven young CAD patients is not documented in the past.

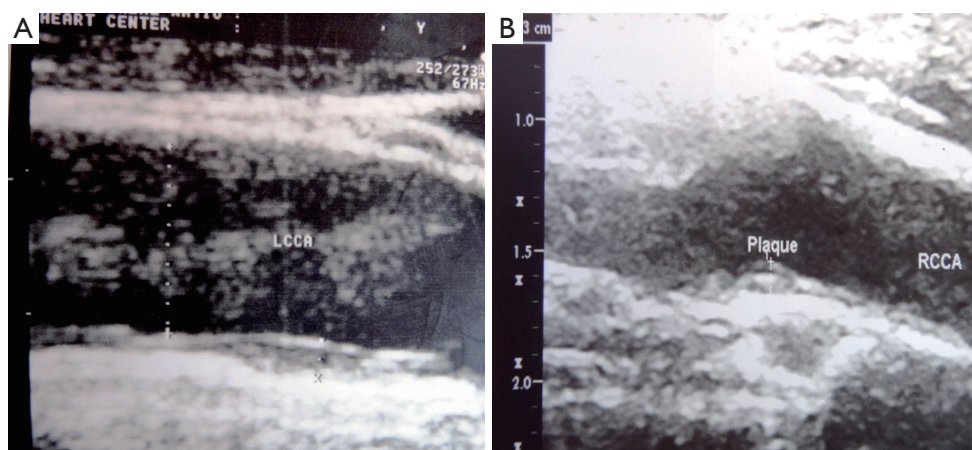


Figure 2 (A) Longitudinal view of LCCA with 1.5 mm plaque at carotid body in 39 years old hypertensive and smoker male patient. Coronary angiography revealed total occlusion of mid LAD; (B) longitudinal view of RCCA with 1.3 mm plaque at carotid bulb in 33 years old normotensive, non-smoker female patient, presented with the history of acute myocardial infarction and coronary angiography revealed total occlusion of proximal LAD, who underwent primary PCI. LCCA, left common carotid artery; LAD, left anterior descending; RCCA, right common carotid artery; PCI, percutaneous coronary intervention.

High resolution B-mode ultrasonography is a non-invasive valid and reliable method to assess the carotid artery dimensions and structures (11,12). Previous series of studies (7-9,26,28) have proved the association of increased CIMT and presence of carotid plaques with CAD. Ultrasonographic assessment of CIMT and carotid plaques is a valid and proven method for the early evaluation of cardiovascular disease (1-5). Our study attempts to reveal the findings of ultrasonographic assessment of CIMT and carotid plaque status in young CAD population of Nepal.

Previous studies in non-smoking, non-diabetic and normotensive healthy adults without traditional risk factors of both sexes, have described normal CIMT and absence of plaque in the majority of the subjects (15-17). In a recent report (18), carotid plaques were reported in only 7% of subjects at an age less than 50 years age undergoing screening for sub-clinical atherosclerosis by carotid ultrasound. In contrast, in a study of young and middle aged male population with angiographically proven CAD, carotid plaques were reported in 91.8% (29). In our young CAD population, mean age of 38.4 years, more than 85% had either increased CIMT or presence of carotid plaques. Two thirds had single vessel CAD, which confirms findings from prior study in younger patient population (13). More than 80% were smokers and more than half of the study subjects had documented hypertension. Diabetes was noted only in one fifth of the study population. Similarly more than three

fourths were alcohol consumers. Smoking, hypertension, high TGs, obesity and positive family history have been reported as a most common risk factors among young CAD population (13,14).

Most of the carotid plaques in our study were soft and homogenous with two thirds of plaques were detected at carotid bulbs. This findings are consistent with previous reports (1,30), it has been postulated that that carotid plaques develop predominantly at sites of nonlaminar turbulent flow such as in the carotid bulb and the proximal of internal carotid artery. In our study, almost one third patients had only thickened CIMT without the presence of carotid plaques and increased thickness of the carotid bulb intima-media was noted in less than fifty percent of total thickened CIMT group.

Our study is limited by the relatively small size of the study population. A control group of patients without documented CAD was not available. The carotid artery ultrasound study profile of young CAD patients who did not undergo coronary angiography is not available in this study. Furthermore, the family history of patients was unreliable due to poor knowledge about CAD in study participants and their family members.

In conclusion, increased CIMT and presence of soft carotid plaques was detected in the majority of young Nepalese patients with documented CAD. The majority of carotid plaques were detected at carotid bulbs. Single vessel

disease is most common in young coronary cases. Smoking was highly prevalent in these young individuals. Based on these results, routine carotid ultrasound in similar patient population may be worthwhile for the early detection and prevention of CAD.

Acknowledgements

Disclosure: The authors declare no conflict of interest.

References

1. Kwon TG, Kim KW, Park HW, et al. Prevalence and significance of carotid plaques in patients with coronary atherosclerosis. *Korean Circ J* 2009;39:317-21.
2. Daneshvar SA, Nagvi TZ. Carotid intima-media thickness and carotid plaques in cardiovascular risk assessment. *Curr Cardiovasc Risk Rep* 2009;3:121-30.
3. Lorenz MW, Markus HS, Bots ML, et al. Prediction of clinical cardiovascular events with carotid intima-media thickness: a systematic review and meta-analysis. *Circulation* 2007;115:459-67.
4. Touboul PJ, Hernández-Hernández R, Küçükö lu S, et al. Carotid artery intima media thickness, plaque and Framingham cardiovascular score in Asia, Africa/Middle East and Latin America: the PARC-AALA study. *Int J Cardiovasc Imaging* 2007;23:557-67.
5. Wyman RA, Fraizer MC, Keevil JG, et al. Ultrasound-detected carotid plaque as a screening tool for advanced subclinical atherosclerosis. *Am Heart J* 2005;150:1081-5.
6. Sinha AK, Eigenbrodt M, Mehta JL. Does carotid intima media thickness indicate coronary atherosclerosis? *Curr Opin Cardiol* 2002;17:526-30.
7. Kablak-Ziembicka A, Tracz W, Przewlocki T, et al. Association of increased carotid intima-media thickness with the extent of coronary artery disease. *Heart* 2004;90:1286-90.
8. Rosa EM, Kramer C, Castro I. Association between coronary artery atherosclerosis and the intima-media thickness of the common carotid artery measured on ultrasonography. *Arq Bras Cardiol* 2003;80:589-92, 285-8.
9. Honda O, Sugiyama S, Kugiyama K, et al. Echolucent carotid plaques predict future coronary events in patients with coronary artery disease. *J Am Coll Cardiol* 2004;43:1177-84.
10. Pignoli P, Tremoli E, Poli A, et al. Intimal plus medial thickness of the arterial wall: a direct measurement with ultrasound imaging. *Circulation* 1986;74:1399-406.
11. Gaitini D, Soudack M. Diagnosing carotid stenosis by Doppler sonography: state of the art. *J Ultrasound Med* 2005;24:1127-36.
12. Baldassarre D, Amato M, Bondioli A, et al. Carotid artery intima-media thickness measured by ultrasonography in normal clinical practice correlates well with atherosclerosis risk factors. *Stroke* 2000;31:2426-30.
13. Ha EJ, Kim Y, Cheung JY, et al. Coronary artery disease in asymptomatic young adults: its prevalence according to coronary artery disease risk stratification and the CT characteristics. *Korean J Radiol* 2010;11:425-32.
14. Allzadehasl A, Sepasi F, Toutan M. Risk factors, Clinical manifestations and Outcome of Acute Myocardial Infarction in Young Patients. *J Cardiovasc Thorac Res* 2010;2:29-34.
15. Denarié N, Gariepy J, Chironi G, et al. Distribution of ultrasonographically-assessed dimensions of common carotid arteries in healthy adults of both sexes. *Atherosclerosis* 2000;148:297-302.
16. Limbu YR, Gurung G, Malla R, et al. Assessment of carotid artery dimensions by ultrasound in non-smoker healthy adults of both sexes. *Nepal Med Coll J* 2006;8:200-3.
17. Paul J, Shaw K, Dasgupta S, et al. Measurement of intima media thickness of carotid artery by B-mode ultrasound in healthy people of India and Bangladesh, and relation of age and sex with carotid artery intima media thickness: An observational study. *J Cardiovasc Dis Res* 2012;3:128-31.
18. Singh S, Nagra A, Maheshwari P, et al. Rapid screening for subclinical atherosclerosis by carotid ultrasound examination: The happy (Heart Attack Prevention Program for You) substudy. *Global Heart* 2013;8:83-9.
19. Obesity: preventing and managing the global epidemic. Report of a WHO consultation. *World Health Organ Tech Rep Ser* 2000;894:i-xii, 1-253.
20. Mannami T, Baba S, Ogata J. Potential of carotid enlargement as a useful indicator affected by high blood pressure in a large general population of a Japanese city: the Suita study. *Stroke* 2000;31:2958-65.
21. WHO, definition, diagnosis and classification of diabetes mellitus. Geneva, 1999.
22. ADA (American Diabetes Association). Position Statement. *Diabetes Care* 2004;27:15-35.
23. National Cholesterol Education Program (NCEP) Expert Panel on Detection, Evaluation, and Treatment of High Blood Cholesterol in Adults (Adult Treatment Panel III). Third Report of the National Cholesterol Education Program (NCEP) Expert Panel on Detection, Evaluation,

- and Treatment of High Blood Cholesterol in Adults (Adult Treatment Panel III) final report. *Circulation* 2002;106:3143-421.
24. Sonoda M, Yonekura K, Yokoyama I, et al. Common carotid intima-media thickness is correlated with myocardial flow reserve in patients with coronary artery disease: a useful non-invasive indicator of coronary atherosclerosis. *Int J Cardiol* 2004;93:131-6.
 25. Vaidya A. Tackling cardiovascular health and disease in Nepal: epidemiology, strategies and implementations. *Heart Asia* 2011;3:87-91.
 26. Mookadam F, Moustafa SE, Lester SJ, et al. Subclinical atherosclerosis: evolving role of carotid intima-media thickness. *Prev Cardiol* 2010;13:186-97.
 27. Nambi V, Chambless L, Folsom AR, et al. Carotid intima-media thickness and presence or absence of plaque improves prediction of coronary heart disease risk: the ARIC (Atherosclerosis Risk In Communities) study. *J Am Coll Cardiol* 2010;55:1600-7.
 28. Xie W, Liang L, Zhao L, et al. Combination of carotid intima-media thickness and plaque for better predicting risk of ischaemic cardiovascular events. *Heart* 2011;97:1326-31.
 29. Kozlov S, Balachonova T, Machmudova H, et al. Carotid atherosclerosis, endothelial dysfunction, and arterial stiffness in young and middle-aged men with coronary artery disease. *Int J Vasc Med* 2012;2012:950130.
 30. Inaba Y, Chen JA, Bergmann SR. Carotid plaque, compared with carotid intima-media thickness, more accurately predicts coronary artery disease events: a meta-analysis. *Atherosclerosis* 2012;220:128-33.

Cite this article as: Limbu YR, Rajbhandari R, Sharma R, Singh S, Limbu D, Adhikari CM, Prajapati D. Carotid intima-media thickness (CIMT) and carotid plaques in young Nepalese patients with angiographically documented coronary artery disease. *Cardiovasc Diagn Ther* 2015;5(1):1-7. doi: 10.3978/j.issn.2223-3652.2015.01.10