

stability and inhibited retinal and chorioidal neovascularization with similar efficacy as anti-VEGF antibodies (Rennel et al. 2011). Several studies have shown that the simultaneous blockade of Ang-2/Tie2 and VEGF pathways reduces vascular leakage and tumour sprouting angiogenesis and has an additive effect to single-agent treatment without apparent increased systemic toxicity (Koh et al. 2010). Combined inhibition of Tie-2 and VEGF signalling was also more effective in terminating pathological retinal neovascularization than anti-VEGF therapy alone (Takagi et al. 2003).

In this study, we performed vitrectomy for the management of sight-threatening complications of ischaemic RVO in four patients (Table 1). Vitreous haemorrhage, neovascularization and some fibrosis formation were observed in all RVO eyes. None of the patients had previous ophthalmologic history or diabetes prior to RVO. Intravitreal injections of anti-VEGF blockade, such as with bevacizumab or ranibizumab, were not used in any of the study eyes preoperatively. The intravitreal concentrations of both Ang-2 and VEGF were significantly higher in eyes undergoing primary vitrectomy due to complicated RVO compared with eyes with a quiescent idiopathic macular hole or pucker ($p = 0.001$; Table 1). This observation, together with the finding of normal intravitreal total protein and plasma Ang-2 levels among the patients with RVO, suggests that ischaemic retinal ECs secrete more Ang-2 than arises due to leakage from blood as a result of blood-retinal barrier breakdown. Interestingly, Ang-1, a factor with known vasculo-protective properties, was induced in RVO eyes.

Based on these findings, we suggest that the combination of Ang-2 inhibitors with anti-VEGF therapy may be a more potent treatment for RVO than anti-VEGF therapy alone. However, clinical trials are needed to confirm our hypothesis.

Acknowledgements

This study was supported by grants from the Finnish Eye Foundation, the Eye and Tissue Bank Foundation, the Mary and Georg C. Ehrnrooth Foundation, the Nissi Foundation, and

HUCH Clinical Research Grants (TKK4150 and TYH1325).

References

- Epstein DL, Algvere PV, von Wendt G, Seregard SKvanta A (2012): Benefit from Bevacizumab for macular edema in central retinal vein occlusion: twelve-month results of a prospective, randomized study. *Ophthalmology* **119**: 2587–2591.
- Koh YJ, Kim HZ, Hwang SI *et al.* (2010): Double antiangiogenic protein, DAAP, targeting VEGF-A and angiopoietins in tumor angiogenesis, metastasis, and vascular leakage. *Cancer Cell* **18**: 171–184.
- Kurihara T, Westenskow PD, Bravo S, Aguilar EFriedlander M (2012): Targeted deletion of VEGF-A in adult mice induces vision loss. *J Clin Invest* **122**: 4213–4217.
- Rennel ES, Regula JT, Harper SJ, Thomas M, Klein CBates DO (2011): A human neutralizing antibody specific to Ang-2 inhibits ocular angiogenesis. *Microcirculation* **18**: 598–607.
- Takagi H, Koyama S, Seike H, Oh H, Otani A, Matsumura MHonda Y (2003): Potential role of the angiopoietin/tie2 system in ischemia-induced retinal neovascularization. *Invest Ophthalmol Vis Sci* **44**: 393–402.

Correspondence:

Sirpa Loukovaara, MD, PhD
Department of Ophthalmology
Unit of Vitreoretinal Surgery
Helsinki University Central Hospital
Haartmaninkatu 4 C
FI-00290
Helsinki, Finland
Tel: + 358 50 4271566
Fax: + 358 9 47175100
Email: sirpa.loukovaara@hus.fi

Cataract development in Norwegian patients with congenital aniridia

Ulla Edén,¹ Neil Lagali,¹ Anette Dellby,¹ Tor P. Utheim,^{2,3} Ruth Riise,⁴ Xiangjun Chen⁵ and Per Fagerholm¹

¹Department of Clinical and Experimental Medicine, Faculty of Health Sciences, Linköping University, Linköping, Sweden; ²Department of Medical Biochemistry, Oslo University Hospital, Oslo, Norway; ³Schepens Eye Research Institute, Massachusetts Eye and Ear Infirmary, Harvard Medical School, Boston, Massachusetts, USA; ⁴Department of Ophthalmology, Innland

Hospital, Elverum, Norway; ⁵Synslaser Kirurgi AS, Oslo, Norway

doi: 10.1111/aos.12225

Editor,

Congenital aniridia is caused by mutation of the PAX 6 gene, the so-called master gene in ocular development. Although cataract has been reported in several aniridia cohorts (Nelson et al. 1984; Sale et al. 2002; Hingorani Moore 2008; Abouzeid et al. 2009; Park et al. 2010; He et al. 2012), the timing and detailed phenotype of cataract in aniridia have not been well described. Here, we report the onset of cataract, timing of cataract surgery and phenotypic features of cataract in a Norwegian aniridia cohort.

A cohort of 26 Norwegian patients (52 eyes) with congenital aniridia was examined on a single occasion, after obtaining written informed consent and ethical approval from the Regional Committee for Medical and Health Research Ethics, Oslo. Medical records were examined to detail cataract presence and surgical intervention. Digital slit lamp photographs of the lens and visual assessment were used to analyse the type and development of cataract, and aniridia-associated keratopathy (AAK) was characterized according to our previously published grading scale (Edén et al. 2012).

Mean patient age was 29 years (range: 4–63 years). Only three eyes were phakic with clear lenses; the remaining eyes had either cataract or had been operated on for cataract. The youngest individual with cataract was 4 years old at examination, but congenital or early onset cataract was documented in medical records of five patients (six eyes). Of 12 patients with nonoperated cataract, five (nine eyes) had lens luxation upwards. Of 14 patients, 27 eyes had glaucoma. Those least affected presented with a discrete posterior polar cataract. In other cases, a discrete subcapsular opacification of varying density or opacification extending radially from the mid-periphery of the posterior capsule was found in addition to the polar cataract. A posterior subcapsular mid-peripheral ring of opacification was observed, in some also combined with a more substantial polar cataract. The size and density of the opaque ring varied

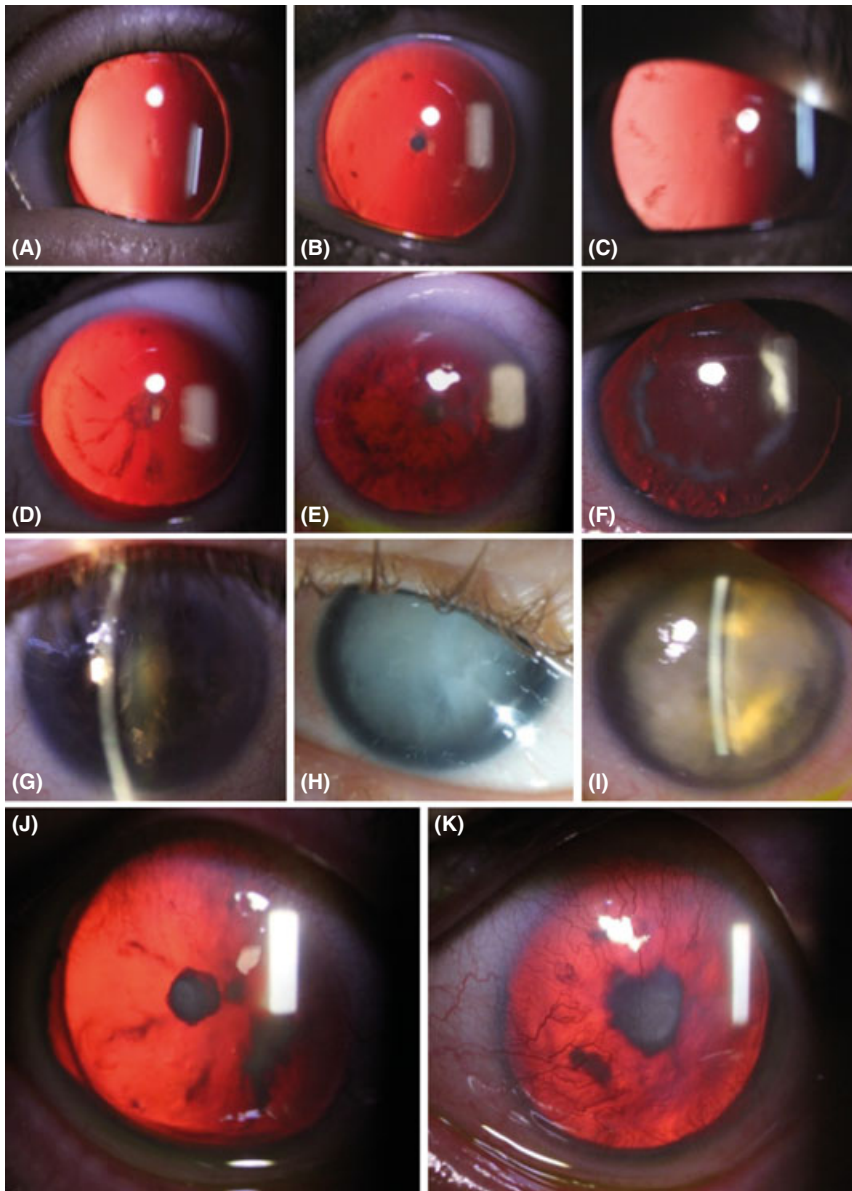


Fig. 1. Developmental patterns of cataract in aniridia patients. (A) Early stage discrete posterior subcapsular cataract. (B–E) The posterior subcapsular cataract is denser. A posterior subcapsular opacification develops on the capsule in the mid-periphery as tiny flecks (B), or short, radially oriented opacities (C). (D–F) Radial opacities extend towards to posterior pole, and a mid-peripheral ring of opacification of varying density is present. Opacification always remained subcapsular. Late lens changes included yellow and turbid nuclear cataract (G), mature cataract (H) and hypermature cataract (I). (J) Anterior polar cataract in combination with a posterior polar cataract in one patient. (K) One patient presented with anterior polar cataract only.

(Fig. 1). Findings in other patients included nuclear cataract (both turbid and yellow-brownish), one generalized subcapsular oedema (mature cataract) and one with a dehydrated opaque lens (hypermature cataract) (Fig. 1). In two patients, an anterior polar cataract was identified one of which had an additional posterior subcapsular opacification (Fig. 1).

Of the 52 eyes examined, 25 had had surgical intervention (cataract, glau-

coma or both). Nine patients (13 eyes) had cataract surgery only, six patients (eight eyes) both cataract and glaucoma surgery and three patients (four eyes) glaucoma surgery only. At the time of cataract surgery, 7 of 12 operated patients were under the age of 19 years and 4 of these were under the age of 10. Secondary cataract was observed in four patients (six eyes). Of the 25 eyes with surgical intervention, eight eyes (30%) had AAK affecting visual acuity

compared to 8/25 eyes (32%) in the group of eyes without intraocular surgery. No clear trend could be found towards an increased prevalence of AAK in operated eyes.

Cataract is common in aniridia, with over 90% prevalence in our cohort, similar to a Korean cohort with 60 eyes where 88% had cataract or were operated for cataract (Park et al. 2010). Cataract prevalence in aniridia in the literature varies from 50 to 85% (Nelson et al. 1984).

Patients in our cohort not operated for cataract showed a distribution of lens opacities that could be interpreted as a pattern of cataract development. A discrete posterior polar opacity seems to emerge first. The posterior location of polar opacities has been reported previously (Yamamoto et al. 2011; Jin et al. 2012). The next phase is an additional subcapsular opacification in the mid-periphery. These opacities then increase in density and size, radiate to the polar region and are always limited to the posterior subcapsular region. They eventually form a ring on the posterior capsule.

References

- Abouzeid H, Youssef MA, El Shakankiri N, Hauser P, Munier FL, Schorderet DF (2009): PAX6 aniridia and interhemispheric brain anomalies. *Mol Vis* **15**: 2074–2083.
- Edén U, Fagerholm P, Danyali RL, Lagali N (2012): Pathologic epithelial and anterior corneal nerve morphology in early-stage congenital aniridic keratopathy. *Ophthalmology* **119**: 1803–1810.
- He Y, Pan Z, Luo F (2012): A novel PAX6 mutation in Chinese patients with severe congenital aniridia. *Curr Eye Res* **37**: 879–883.
- Hingorani M, Williamson KA, Moore A, TVan Heyningen V (2009): Detailed ophthalmologic evaluation of 43 individuals with PAX6 mutations. *Invest Ophthalmol Vis Sci* **50**: 2581–2590.
- Jin C, Wang Q, Li J, Zhu Y, Shentu XY, Yao K (2012): A recurrent PAX6 mutation is associated with aniridia and congenital progressive cataract in a Chinese family. *Mol Vis* **18**: 465–470.
- Nelson LB, Spaeth GL, Nowinski TS, Margo CE, Jackson L (1984): Aniridia. A review. *Surv Ophthalmol* **28**: 621–642.
- Park SH, Park YG, Lee MY, Kim MS (2010): Clinical features of Korean patients with congenital aniridia. *Korean J Ophthalmol* **24**: 291–296.
- Sale MM, Craig JE, Charlesworth JC et al. (2002): Broad phenotypic variability in a

single pedigree with a novel 1410delC mutation in the PST domain of the PAX 6 gene. *Hum Mutat* **20**: 322.

Yam N, Zhao Y, Wang Y, Xie A, Huang H, Yu W, Liu X, Cai S-P (2011): Molecular genetics of familial nystagmus complicated with cataract and iris anomalies. *Mol Vis* **17**: 2612–2617.

Correspondence:

Ulla Edén, MD, PhD
Department of Clinical and
Experimental Medicine
Faculty of Health Sciences
Linköping University
581 83 Linköping, Sweden
Tel: + 46 44 2436472
Fax: + 46 10 1033065
Email: ulla.eden@gmail.com

Severe retinopathy of prematurity in twin–twin transfusion syndrome after multiple blood transfusions

Arlette van Sorge,¹ Frank Kerkhoff,²
Feico J Halbertsma³ and Noline
Schalij-Delfos¹

¹Department of Ophthalmology, Leiden University Medical Center, Leiden, The Netherlands; ²Department of Ophthalmology, Maxima Medical Center, Veldhoven, The Netherlands; ³Department of Neonatology, Maxima Medical Center, Veldhoven, The Netherlands

doi: 10.1111/aos.12229

Editor,

Retinopathy of prematurity (ROP) is a potentially blinding disease in premature infants. Several risk factors associated with the development of ROP have been reported such as gestational age (GA), birth weight (BW), duration of artificial ventilation, sepsis and blood transfusions, whereas prenatal glucocorticoids would be protective. Vascularization of the retina starts at 16 weeks and is completed around 40 weeks of gestation. Outgrowth of vessels is defined in three Zones, Zone I being the most central one (Weintraub et al. 2011). Vascular endothelial growth factor (VEGF) and insulin-like growth factor-1 (IGF-1), produced by

the placenta, play a crucial role in vascularization of the retina (Hellstrom et al. 2001). ROP is defined as abnormal vessel growth in the developing retina. In the first phase of ROP, down regulation of VEGF together with a decrease in IGF-1 causes an arrest in vessel outgrowth. In the second phase of ROP, IGF-1 levels slowly and VEGF levels more rapidly increase causing plus disease (tortuosity and dilation of retinal vessels) and neovascularizations.

Twin–Twin transfusion syndrome (TTTS) complicates 10–15% of mono-chorionic diamniotic twin pregnancies. This is a second report of TTTS accompanied by severe ROP and describes the history of two pairs of twins (Puvanachandra et al. 2009). GA, BW, risk factors and specifications about ROP are presented in Table 1. Both donor twins showed normal weight gain and catch-up growth. The course of development of ROP was remarkable as it developed rapidly although the outgrowth of retinal vessels had already progressed to peripheral zone II. In the first donor twin, ROP stage 1 without plus disease was seen up to 39 weeks postmenstrual age (PMA) then rapidly progressing to stage 5. The second donor twin presented with stage 3 ROP with plus disease at the first examination.

Multiple births are unique because of the confounding effect of certain

risk factors, such as GA and maternal risk factors, on incidence and severity of ROP. Both donor twins had several mild risk factors for ROP. The most striking difference between the donor and the recipient twins, however, is the number of blood transfusions given within 3 weeks postnatal age.

Red blood cell (RBC) transfusions are associated with an increased risk of ROP as they increase retinal oxygen levels by an increase in oxygen carrying capacity and a decrease in oxygen affinity of the red blood cell, caused by transfusing infants with adult haemoglobin having a reduced oxygen affinity as compared to foetal haemoglobin. A second explanation may be that blood transfusions increase the free, nonprotein-bound iron load leading to the production of free oxygen radicals that can cause irreversible damage to the developing retinal vessels (Chen et al. 2009).

Last, an unintended side effect of RBC transfusions could be the concomitant administration of very high doses of IGF-1. Hubler et al. (2006) reported that the IGF-1 load in RBC transfusions is equivalent to a single dose of 1 µg/kg, which is 5–10% of the adult dose. Hellstrom et al. (2001) showed that a rapid increase in IGF-1 together with high levels of VEGF induces rapid growth of new vessels.

Table 1. Characteristics of the twins.

	Twin pair 1		Twin pair 2	
	Donor	Recipient	Donor	Recipient
Birth weight (g)	771	900	1270	1590
Gestational age (weeks)	28 + 1	28 + 1	31 + 1	31 + 1
Prenatal glucocorticoids	Yes	Yes	Yes	Yes
AV (days)	8	0	7	0
RDS (grade 2–3)	Yes	No	No	No
Inhaled NO	Yes	No	No	No
Transfusions	9	0	12	0
ROP				
ROP stage	5	No ROP	3	No ROP
Plus disease	Yes	No	Yes	No
First screening	33 + 4	33 + 4	37 + 4	37 + 4
PMA ROP	35 + 3		37 + 4	
PMA severe ROP	41 + 5		37 + 4	
ROP treatment	Laser		Laser	
	Vitrectomy		Vitrectomy	
	Lensectomy		Lensectomy	

AV, artificial ventilation; ROP, retinopathy of prematurity; RDS, respiratory distress syndrome; PMA, postmenstrual age; Inhaled NO, inhaled nitric oxide; Severe ROP, ROP stage ≥ 3.