

The study of inheritance analysis and evaluation of lip prints in individuals

Anju Devi,
 Madhusudan Astekar¹,
 Vinay Kumar,
 Prabhpreet Kaur²,
 Navneet Singh³,
 Gagandeep Kaur Sidhu²
Department of Oral and Maxillofacial Pathology,
²*Post Graduate Student,*
Darshan Dental College and Hospital,
¹*Department of Oral and Maxillofacial Pathology, Pacific Dental College and Hospital,*
Udaipur,
³*Department of Oral and Maxillofacial Pathology, Surendra Dental College and Hospital, Sri Ganganagar, Rajasthan, India*


Address for correspondence:
 Dr. Madhusudan Astekar,
 Department of Oral and Maxillofacial Pathology, Pacific Dental College and Hospital,
 Udaipur, Rajasthan, India
 E-mail: madhu.tanu@gmail.com

Abstract

Context: Identification of an individual is a pre-requisite for certification of death and for personal, social, and legal reasons. The study of lip prints (cheiloscopy) was thought as a method for identification of a person. It is safe to assume that cheiloscopy, in its present stage of development, has become a means of criminalistic identification dealing with lip prints. **Aim:** The first aim of the study was to evaluate the visible lip patterns in Rajasthan population in relation to the gender and to ascertain the existence of hereditary pattern followed among parents and offsprings. The second aim was to compare visible and latent lip print patterns on non-biological materials like tracing paper, microscopic glass slides and stainless steel tumblers. **Materials and Methods:** The lip prints of 300 subjects including 25 families were obtained using lipstick. Out of these 300 individuals, 60 were selected for latent lip prints. In order to prevent any intra- and inter-observer variability single observer carried out all the observations. The lip prints were analyzed using magnifying lens and were classified using the criteria given by Suzuki and Tsuchihashi. The determination of the pattern in each segment of the lip was based on the numerical superiority of properties of the lines on the fragment. **Statistical Analysis Used:** After recording all the values for various parameters, data obtained were statistically analyzed with the help of the Statistical Package for Social Sciences software version-13 using independent *t*-test. For all the tests, a *P* value of 0.05 or less was considered. **Results:** In the present study, most predominant pattern in the entire study population among upper and lower lips considering both males and females was type III lip pattern. Hereditary resemblance was observed between parents and offsprings in 37.66%. The latent lip prints were better visualized on microscopic glass slide when compared to stainless steel tumblers. **Conclusion:** Lip prints have a good potential for use in criminal investigations. They have been used only occasionally despite their frequent occurrence at crime scenes. A place for cheiloscopy is recommended within the scope of forensic odontology, along with other means of forensic identification.

Key words: Cheiloscopy, forensic identification, forensic odontology, lip prints

Access this article online

Website: www.jfds.org	Quick Response Code
DOI: 10.4103/0975-1475.150309	

Introduction

The moral and proficient responsibility of a dental surgeon to mankind is not only to serve in examination, investigation, diagnosis, and treatment of oral and oro-facial lesions of local origin, but also in other community services and legal matters.^[1] Dental surgeon has an active role in various purposes of forensic dentistry like age and gender

determination, personal identification of unknown deceased person, analyzing bite marks as evidence, participating in mass disaster, giving evidence in child abuse etc., His/her role in personal identification and criminal investigation is very much important, as his/her evidence would be very much useful in law and justice.^[1]

Forensic is derived from the Latin word '*forum*', which means 'court of law.' Odontology refers to the study of teeth. Forensic odontology has been defined as that branch of dentistry which, in the interest of justice, deals with the proper handling and examination of dental evidence and with the proper evaluation and presentation of dental findings.^[2] Cheiloscopy is one such method employed in forensic odontology to study its significance in distinct populations.

In forensic identification, the mouth allows for a myriad of possibilities. Due to the distinctive features of teeth, dental identification is one of the most popular ways to positively identify an individual. In fact, teeth are known to have singular features and possess extraordinary resistance to extreme conditions. These properties enable fast and secure identification processes.^[3] However, since they cannot always be used, sometimes it is necessary to apply different and less known techniques.^[4]

Human identification is a universal process based on scientific principles.^[5] The traditional methods for personal identification include anthropometry, fingerprints, gender determination, age estimation, measurement of height, and differentiation by blood groups, DNA, and odontology.^[3] The numerous approaches employed in forensic odontology include rugoscopy, cheiloscopy, bite marks, tooth prints, radiographs, photographic study and molecular methods.^[6]

The latent lip prints can be developed by using a wide variety of chemicals, ranging from conventional powders to lysochrome dyes (for persistent lipstick prints). This trace evidence can provide information on the basis of the conclusion of the sex, occupation, habits, cosmetic used, and the pathological change to narrow down the investigation. But most importantly, lip prints can be used as an evidence for identification.^[7]

The present study aims to evaluate the lip print patterns of different individuals in relation to population, gender, inheritance pattern and on non-biological materials.

Materials and Methods

In the present study, lip prints of 300 randomly selected subjects including 25 families were obtained using lipstick. Out of these 300 individuals, 60 were selected for latent lip prints. Lips free from any disease and the transient zone of lips between mucosa and skin which were absolutely normal were included in the study. Those individuals

with developmental deformities of lip, chapped lips, or any previous surgery involving the lips were excluded. All the procedures followed were in accordance with the ethical standards of the institutional committee on human experimentation and with as per the guidelines of Helsinki Declaration of 1975, as revised in 2008. After acquiring the verbal informed consent, a thorough clinical examination of lips of all the included individuals was carried out. They were cleaned and then outlined using a sharp lip liner pencil. Lipstick was then applied uniformly starting at the midline and moving laterally. A tracing paper measuring 9 × 6 cm was then placed on the lips and held for few seconds, applying gentle and even pressure. Then, the tracing paper was carefully lifted from the lips, from one end to the other, avoiding any smudging of the print. The impression was subsequently visualized with the use of a magnifying lens.

To identify the latent lip prints on non-biological materials, the stainless steel tumblers and microscopic glass slides were used. The individuals were given an aerated drink in stainless steel tumblers. Lip prints of the same individuals were taken on microscopic slides. Carbon dust was sprinkled over the lip print area on both steel tumbler and glass slide to make it visible. The lip prints were analyzed macroscopically using magnifying glass and compared with the visible prints previously taken on tracing paper.

Method for analysis of lip prints

The lip prints thus obtained were classified using the criteria given by Suzuki and Tsuchihashi. The determination of the pattern in each segment of the lip was based on the numerical superiority of properties of the lines on the fragment.

Statistical analysis

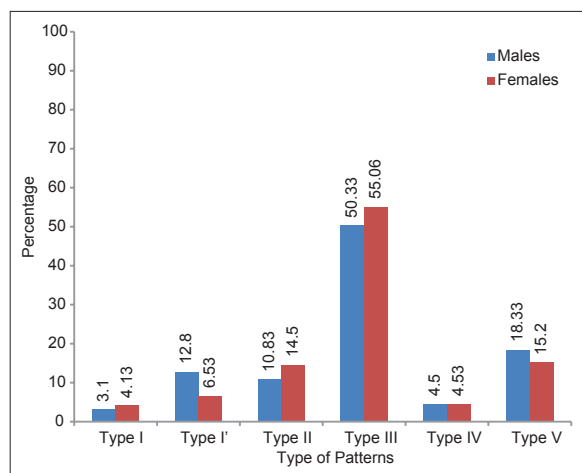
After recording all the values for various parameters, data obtained were statistically analyzed with the help of the Statistical Package for Social Sciences (SPSS) version-13 using independent *t*-test. For all the tests, a *P* value of 0.05 or less was considered for statistical significance.

Results

The most predominant lip print in the entire study population, taking both the upper and lower lips together, was type III. This was followed in descending order by type II, type V, type I', type I, and type IV [Table 1]. The most predominant lip print pattern in the entire study population, considering only the upper lip, showed type III. This was followed in descending order by type V, type II, type I', type IV, and type I [Graph 1]. The most predominant lip print pattern considering only the upper lip as per males and females showed type III, type V, type II, type I', type IV, and type I [Table 2]. The most predominant lip print in the entire study population considering only the lower lip as per the gender was concerned showed type III, this was

followed by type II, type V, type I, type I', and type IV in descending order [Table 3].

The resemblance of the lip print patterns of the offsprings with their parents in both the upper and lower lip according to the various segments like left lateral showed 24% and 56%, left medial segment 24% and 44%, left central



Graph 1: Distribution of lip print patterns among males and females in upper lip

Table 1: Distribution of lip print patterns among males and females in both upper and lower lip

Type	Count (%)		
	Males	Females	Total
I	71 (5.91)	95 (6.33)	95 (6.33)
I'	122 (10.16)	106 (7.06)	106 (7.06)
II	201 (16.7)	295 (19.66)	295 (19.66)
III	552 (46)	729 (48.6)	729 (48.6)
IV	79 (6.58)	84 (5.6)	84 (5.6)
V	175 (14.58)	191 (12.70)	191 (12.70)

Table 2: Distribution of lip print patterns in different segments of the upper lip in relation to gender

Type	Gender	ULL	ULM	ULC	URL	URM	URC	Total	P value
I	Male	4	3	6	1	1	4	19	9.91
	Female	4	3	10	3	2	9	31	(NS)
I'	Male	17	16	13	13	7	11	77	0.53
	Female	14	9	4	6	8	8	49	(NS)
II	Male	11	12	10	14	11	7	65	0.49
	Female	13	20	22	13	21	17	109	(NS)
III	Male	44	50	54	44	52	58	302	0.98
	Female	58	77	70	64	68	78	413	(NS)
IV	Male	0	3	8	1	2	13	27	0.58
	Female	1	5	14	1	4	9	34	(NS)
V	Male	24	16	9	27	27	7	110	0.22
	Female	34	11	5	38	22	4	114	(NS)
Total	Male	100	100	100	100	100	100	600	
	Female	125	125	125	125	125	125	750	

ULL: Upper left lateral; ULM: Upper left Medial; ULC: Upper left central; URL: Upper right lateral; URM: Upper right medial; URC: Upper right central; NS: Non-Significant

segment 44% and 36%, right lateral segment 32% and 36%, right medial 24% and 44%, right central 24% and 64%, respectively. When the overall lip print patterns among parents and offsprings were compared, 113 (37.66%) showed positive resemblance [Table 4].

Comparison of visible lip print patterns obtained on tracing paper with that of latent lip print patterns obtained on glass slides and steel tumblers in lip lower showed similar patterns in 297 and 226, dissimilar in 41 and 103, and not clear in 22 and 31 individuals, respectively. Upon inter-comparison, statistically significant results were obtained [Graph 2].

Discussion

Forensic odontology is a valuable component of forensic investigation in many countries. It involves dentist's

Table 3: Distribution of lip print patterns in different segments of the lower lip in relation to gender

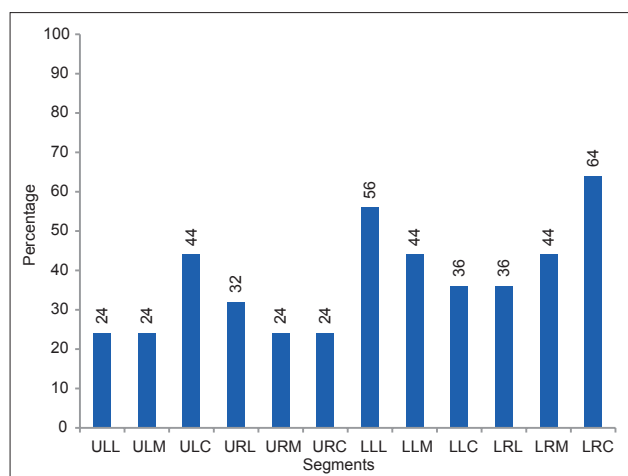
Type		LLL	LLM	LLC	LRL	LRM	LRC	TOTAL	P value
I	Males	4	2	24	2	2	18	52	0.001 (S)
	Female	2	4	28	1	4	25	64	
I'	Male	4	8	18	2	4	9	45	<0.0001 (S)
	Female	5	9	18	4	6	15	57	
II	Male	27	25	10	23	32	19	136	<0.0001 (S)
	Female	40	39	20	30	31	26	186	
III	Male	54	45	23	58	41	29	250	0.045 (S)
	Female	63	59	27	70	64	29	316	
IV	Male	2	6	23	1	2	18	52	0.0002 (S)
	Female	2	3	22	1	2	20	50	
V	Male	9	14	2	14	19	7	65	0.0006 (S)
	Female	9	11	10	19	18	10	77	
Total		100	100	100	100	100	100	600	1350
		125	125	125	125	125	125	750	

LLL: Lower left lateral; LLM: Lower left Medial; LLC: Lower left central; LRL: Lower right lateral; LRM: Lower right medial; LRC: Lower right central

Table 4: Percentage resemblance of lip print patterns among Parents and their Children in both upper lip and lower lip

Segment	Count	Percent	P value
ULL	6	24	0.009
ULM	6	24	0.009
ULC	11	44	0.554
URL	8	32	0.068
URM	6	24	0.009
URC	6	24	0.009
LLL	14	56	0.554
LLM	11	44	0.554
LLC	9	36	0.158
LRL	9	36	0.158
LRM	11	44	0.554
LRC	16	64	0.158

ULL: Upper left lateral; ULM: Upper left Medial; ULC: Upper left central; URL: Upper right lateral; URM: Upper right medial; URC: Upper right central; LLL: Lower left lateral; LLM: Lower left Medial; LLC: Lower left central; LRL: Lower right lateral; LRM: Lower right medial; LRC: Lower right central



Graph 2: Percentage resemblances of lip print patterns among parents and their children

participation in assisting legal and criminal issues. The application of dental sciences in criminal and legal investigations gathered momentum in the West during the 1950s and 1960s. Cheiloscopy is analogous to fingerprint analysis and is a genuine subspecialty of forensic odontology.^[3]

Lip prints bring added evidence to a crime scene that can be valuable, especially in cases lacking other evidence, like fingerprints. Lip prints can be a factor in many different kinds of crimes, such as tape when a person has been bound or gagged, prints on a glass that a person drank from, prints on a cigarette butt, and prints on a glass/window if they were pressed up against it. All of these are potential places where lip prints may be found and used in the investigation of a crime.^[8]

However, all lip prints are important, even the ones that are not visible. In fact, this complex process is not restricted to studying visible prints, but also the latent ones. The identification of latent print evidence is often considered the key in solving a crime. A group of Spanish investigators has studied these latent lip prints and concluded that they could be studied in a similar way to fingerprints using similar techniques. In fact, even when located on "difficult" surfaces (such as porous or multicolored ones), latent prints can be easily seen using various dyes such as aluminum powder, silver metallic powder, silver nitrate powder, plumb carbonate powder, fat black aniline dye or cobalt oxide.^[9]

The classification proposed by Suzuki and Tsuchihashi in 1970,^[10] also known as Tsuchihashi's classification, is most widely used in the literature. It was found to have a clear description of nearly all of the commonly encountered lip patterns and was easy to interpret. Its resemblance to the dental formula was also familiar to the forensic dentist.^[11]

In the present study, most predominant lip print pattern in the Rajasthan population, considering either upper lip

alone or lower lip alone or both the lips taken together, was type III pattern. Similar results have been found in various studies by Sivapathasundharam *et al.*,^[12] Augustine^[11], Ramandeep S Narang *et al.*, (2011)^[7] who also found type III pattern as the most predominant one.

In the present study, most predominant lip print patterns considering males and females were type III pattern. Our results were in accordance with Augustine *et al.*,^[11] who did not find significant differences in lip prints based on sex, age, or race.

The present study also aimed to investigate the role of heredity in lip prints. Among lip prints of families studied, 37.66% were seen to have a positive resemblance with their parents. The resemblance patterns of the offsprings with their parents were higher in lower lip when compared to the upper lip. Augustine *et al.*,^[11] found a higher (63%) percentage of resemblance of lip print patterns between parents and their offsprings.

In the present study, inter-comparison between visible lip print patterns on tracing with latent lip print patterns obtained on different non-biological substances like microscopic glass slides and stainless steel tumblers from the same individuals showed a statistical significance among similarity patterns. Similar results were noted by Uma and Gnanasundaram.^[13] However, in the present study, dissimilarities and not clear patterns on stainless steel tumblers were more in comparison with glass slide. Hence, lip prints can be used to verify the presence or absence of a person from the crime, provided there has been consumption of beverage, drinks, usage of cloth, tissue/napkin etc., at the crime scene. Lip marks can be observed on ordinary drinking glass by an individual, even without lipstick being applied.

Hence, lip prints can be used to verify the presence or absence of a person from the crime, provided there has been consumption of beverage, drinks, usage of cloth, tissue/napkin etc., at the crime scene. Lip marks can be observed on ordinary drinking glass by an individual, even without lipstick being applied. Hence, taking lip prints of all the suspected individuals and comparing with any such item found at the scene of crime could give conclusive evidence on the presence/absence of a person and should be admissible even in the court of law.^[14]

Conclusion

The most predominant pattern in the entire study population was type III pattern. The most predominant lip print pattern among upper and lower lips considering both males and females was type III pattern. The similarity of lip print patterns among parents and their offsprings persists. Lip prints were better visualized on tracing paper

followed by microscopic glass slide and then on stainless steel tumblers.

References

1. Nagasupriya A, Dhanapal R, Reena K, Saraswati T, Ramachandran C. Patterns "A crime solver". J Forensic Dent Sci 2011;3:3-7.
2. Acharya AB, Sivapathasundharam B. Forensic Odontology. In: Shafer's Textbook of Oral Pathology. Rajendran R, Sivapathasundharam B, editors. 6th ed. New Delhi: Elsevier; 2006. p. 1223-4.
3. Reddy LV. Lip prints: An overview in forensic dentistry. J Adv Dent Res 2011;2:17-20.
4. Venkatesh R, David MP. Cheiloscopy: An aid for personal identification. J Forensic Dent Sci 2011;3:67-70.
5. Sandhu SV, Bansal H, Monga P, Bhandari R. Study of lip print pattern in a Punjabi population. J Forensic Dent Sci 2012;4:24-8.
6. Kavitha B, Einstein A, Sivapathasundharam B, Saraswathi TR. Limitations in forensic odontology. J Forensic Dent Sci 2009;1:8-10.
7. Vats Y, Dhall JK, Kapoor A. Gender variation in morphological patterns of lip prints among some north Indian populations. J Forensic Dent Sci 2012;4:19-23.
8. Rashmi V, Maria PD. Cheiloscopy: An aid for personal identification. J Forensic Dent Sci 2011;3:67-70.
9. Caldas IM, Magalhães T, Afonso A. Establishing identity using Cheiloscopy and Palatoscopy. Forensic Sci Int 2007;165:1-9.
10. Suzuki K, Tsuchihashi Y. A new attempt of personal identification by means of lip print. J Indian Dent Assoc 1970;42:8-9.
11. Augustine J, Barpande SR, Tupkari JV. Cheiloscopy as an adjunct to forensic identification: A study of 600 individuals. J Forensic Odontostomatol 2008;26:44-52.
12. Sivapathasundharam B, Prakash PA, Sivakumar G. Lip prints (Cheiloscopy). Indian J Dent Res 2001;12:234-7.
13. Uma M, Gnanasundaram N. Role of Lip prints in Personal Identification and criminalization. Anil Aggrawal's Internet J Forensic Med Toxicol 2011;12. Available from: http://www.anilaggrawal.com/ij/vol_012_no_001/papers/paper005.html. [Last accessed on 2012 Nov 15].
14. Amith HV, Ankola AV, Nagesh L. Lip prints – can it aid in individual identification. J Oral Health Comm Dent 2011;5:113-8.

How to cite this article: Devi A, Astekar M, Kumar V, Kaur P, Singh N, Sidhu GK. The study of inheritance analysis and evaluation of lip prints in individuals. J Forensic Dent Sci 2015;7:49-53.

Source of Support: Nil, **Conflict of Interest:** None declared

Author Help: Reference checking facility

The manuscript system (www.journalonweb.com) allows the authors to check and verify the accuracy and style of references. The tool checks the references with PubMed as per a predefined style. Authors are encouraged to use this facility, before submitting articles to the journal.

- The style as well as bibliographic elements should be 100% accurate, to help get the references verified from the system. Even a single spelling error or addition of issue number/month of publication will lead to an error when verifying the reference.
- Example of a correct style
Sheahan P, O'leary G, Lee G, Fitzgibbon J. Cystic cervical metastases: Incidence and diagnosis using fine needle aspiration biopsy. Otolaryngol Head Neck Surg 2002;127:294-8.
- Only the references from journals indexed in PubMed will be checked.
- Enter each reference in new line, without a serial number.
- Add up to a maximum of 15 references at a time.
- If the reference is correct for its bibliographic elements and punctuations, it will be shown as CORRECT and a link to the correct article in PubMed will be given.
- If any of the bibliographic elements are missing, incorrect or extra (such as issue number), it will be shown as INCORRECT and link to possible articles in PubMed will be given.