

A study of lip print patterns among adults of Sebha city, Libya

Syed Wali Peeran^{1,2},
P. G. Naveen Kumar³,
Khaled Awidat Abdalla^{2,4},
Faiza Abdelkader
Ahmed Azaruk²,
Shahnavaz Manipady⁵,
Fatma Mojtaba Alsaïd²

Departments of ¹Periodontology and Oral Implantology and ⁴Oral Biology and Orthodontics, Sebha University, ²Faculty of Dentistry, Sebha University, Sebha, Libya, ³Department of Community and Preventive Dentistry, College of Dental Sciences, Davangere, ⁵Department of Forensic Medicine and Toxicology, K. S. Hegde Medical Academy, Mangalore, Karnataka, India

Address for correspondence:

Dr. Syed Wali Peeran,
Department of Periodontology and Oral Implantology, Faculty of Dentistry, Sebha University, Sebha, Libya.
E-mail: doctorsyedwali@yahoo.in

Abstract

Introduction: Lip print patterns are individualistic and unique and can be used for identification of individuals. **Objectives:** The objective of this study was to find out the different types of lip patterns, know the most common one and to know whether it has any gender predilection among adults of Sebha city. **Materials and Methods:** A total of 104 adults aged 18-35 years participated in this study. Lip prints were recorded and analyzed for lip print patterns. Statistical analysis was carried out using the computer software Statistical Program for Social Sciences (SPSS) 17.0 (Chicago, Illinois, USA). **Results:** Type I lip print pattern was seen in 53.37% and 60.07% of lip quadrants in males and females, respectively. 27 (25.96%) subjects had same lip print pattern in all the four quadrants. **Conclusion:** Suzuki and Tsuchihashi's Type I lip print pattern was most common type of lip print pattern in the studied population, whereas Type I' was found to be the least common.

Key words: Cheiloscropy, forensic odontology, individual identification, sex determination

Introduction

Lips contain in them various characteristic patterns of grooves, furrows, wrinkles and lines, the combination of which is individualistic and unique like finger prints.^[1] The study of this lip print patterns is called as cheiloscropy. The presence of such biological phenomenon of furrows on the red part of lips was described as early as 1902 by Fischer, an anthropologist as referred by Sivapathasundharam^[2] Lip prints are relatively new forensic odontology tools in identifying

individuals. A number of classifications have been proposed by various researchers to classify the lip print patterns, the most commonly used among them being the Santos,^[3] Suzuki and Tsuchihashi^[4] and Renaud's classification.^[5] The present work is the first known consolidated attempt to carry out a cheiloscopic study in the Libyan population. The present study aimed to find the different types of lip patterns, to find out the quadrant wise and gender wise predilection of lip print patterns and to know the most common lip print pattern, in the adults of Sebha city, Libya.

Materials and Methods

The study was conducted among 104 adults; the sample consisted of 37 males and 67 females. The subjects were aged between 18 and 35 years and were from the native population of Sebha city, Libya. Ethical clearance was obtained from the scientific committee, Faculty of Dentistry, Sebha University, Sebha, Libya. The study was conducted

Access this article online	
Website: www.jfds.org	Quick Response Code 
DOI: 10.4103/0975-1475.150322	

in a period of 3 months from December 2012 to February 2013. The adult subjects, willing to participate in the study, providing informed consent were included in the study. Subjects with gross deformities in lips, those having known allergy for lipstick materials and those having active lesions on their lips, were excluded from the study. Each individual was allowed to select any dark colored lipstick of their choice. They were asked to clean their lips and then apply the lipstick on their lips and then to rub their lips to spread the lipstick uniformly. The lip prints were then taken on a clean white paper, which was supported with a card board. Care was taken to avoid smudging of the prints.

The recorded lip prints were then studied using the magnifying lens. The lips were divided into four quadrants (upper left, upper right, lower right and lower left) and the prints were analyzed according to Suzuki and Tsuchihashi,^[4] classification, which is as follows:

- Type I: Vertical, complete (end-to-end) longitudinal fissures
- Type I': Incomplete vertical fissures
- Type II: Branching, Y shaped pattern
- Type III: Criss-cross patterns
- Type IV: Reticular, typical chequered pattern, fence-like.

All data was entered using Microsoft excel and analyzed statistically using Statistical Program for Social Sciences (SPSS) (SPSS, version 17.0) (Chicago, Illinois, USA). Chi-square test was performed to test the significance of gender-wise difference in different quadrants. $P \leq 0.05$ was considered as statistically significant.

Results

The present study was conducted to access the quadrant wise and gender-wise predilection of the lip print patterns and to know the most common lip pattern among adults in Sebha city, Libya.

Table 1 shows the distribution of various types of lip patterns in the four quadrants of the subjects in the study. This table shows overall results of the present study.

Table 2 is the simplified version of Table 1, it shows that 53.37% of quadrants in males and 60.07% of quadrants in females had Type I lip pattern. 7.43% of quadrants in males and 6.71% of quadrants in female had Type I' lip pattern. 20.94% of quadrants in males and 16.04% of quadrants in females had Type II lip pattern. 9.45% of quadrants in males and 9.32% of quadrants in females had Type III lip pattern. 8.78% of quadrants in males and 7.83% of quadrants in females had Type IV lip pattern. Overall 57.7% of quadrants had Type I. 6.97% of quadrants had Type I'. 17.78% of quadrants had Type II pattern. 9.37% of quadrants had Type III pattern. 8.17% of quadrants had Type IV pattern. These results show that Type I pattern was

Table 1: Distribution of lip print patterns

Lip quadrant	Male (%)	Female (%)
Type I		
Upper left	16 (43.24)	38 (56.71)
Upper right	16 (43.24)	35 (52.23)
Lower right	22 (59.45)	45 (67.16)
Lower left	25 (67.56)	43 (64.17)
Type I'		
Upper left	2 (5.4)	8 (11.94)
Upper right	5 (13.51)	4 (5.97)
Lower right	1 (2.70)	3 (4.47)
Lower left	3 (8.10)	3 (4.47)
Type II		
Upper left	8 (21.62)	12 (17.91)
Upper right	7 (18.91)	15 (22.38)
Lower right	10 (27.02)	9 (13.43)
Lower left	6 (16.21)	7 (10.44)
Type III		
Upper left	6 (16.21)	5 (7.46)
Upper right	4 (10.8)	6 (8.95)
Lower right	2 (5.40)	4 (5.92)
Lower left	2 (5.40)	10 (14.92)
Type IV		
Upper left	5 (13.51)	4 (5.97)
Upper right	5 (13.51)	7 (10.44)
Lower right	2 (5.4)	6 (8.95)
Lower left	1 (2.71)	4 (5.97)

Table 2: Gender wise distribution of lip print patterns

Lip print pattern	Number of quadrants: Male (%)	Number of quadrants: Female (%)	Total number of quadrants
Type I	79 (53.37)	161 (60.07)	240 (57.7)
Type I'	11 (7.43)	18 (6.71)	29 (6.97)
Type II	31 (20.94)	43 (16.04)	74 (17.78)
Type III	14 (9.48)	25 (9.32)	39 (9.37)
Type IV	13 (8.78)	21 (7.83)	34 (8.17)

the most common type of lip pattern followed by Type II, Type III and Type IV lip pattern, the least common was Type I' when overall quadrants were considered and the same was observed among males and females also.

Graph 1 shows the distribution of the subjects by gender-wise and lip print pattern in upper left quadrant. Type I pattern was seen among 43.24% of males and 56.71% of females. Type I' pattern was seen among 5.4% of males and 11.94% of females. Type II pattern was seen among 21.62% of males and 17.91% of females. Type III pattern was seen among 16.21% of males and 7.46% of females and Type IV pattern was seen among 13.51% of males and 5.47% of females. Distribution of lip print pattern among males and females in the upper left quadrant of the lip was not statistically significant (Chi-square value was 5.357 and $P > 0.05$).

Type I pattern was observed among 43.24% of males and 52.83% of females. Type I' pattern was seen in 13.51% of males and 5.97% of females. Type II pattern was seen in 18.91% of males and 22.38% of females. Type III pattern was seen in 10.8% of males and 8.95% of females. And Type IV pattern was seen in 13.51% of males and 10.44% of females. There was no statistically significant difference among all the patterns between males and females (Chi-square value 2.376 and $P > 0.05$) [Graph 2].

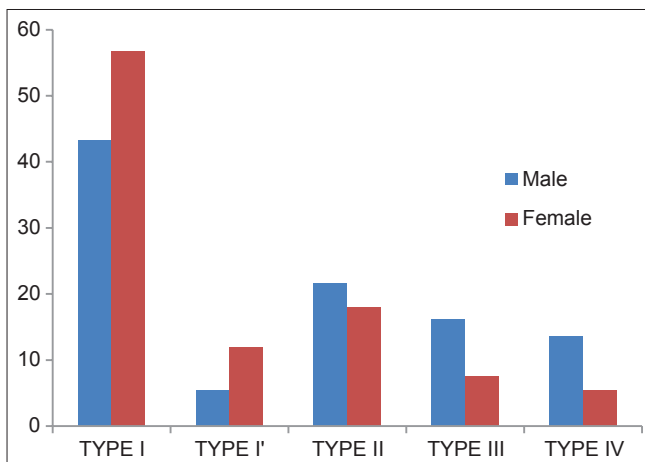
Type I pattern was seen among 59.45% of males and 67.16% of females. Type I' pattern was seen among 2.7% of males and 4.47% of females. Type II pattern was seen among 27.02% of males and 13.43% of females. Type III pattern was observed among 5.4% of males and 5.97% of females and Type IV pattern was seen among 5.4% of males and 8.95% of females. Distribution of lip print pattern among males and females in the lower right quadrant of the lip was not statistically significant (Chi-square value was 3.23 and $P > 0.05$) [Graph 3].

Type I pattern was seen in 67.56% of males and 64.17% of females, Type I' pattern was seen in 8.1% of males and 4.47% of females, Type II pattern was seen in 16.21% of males and 10.44% of females, Type III pattern was seen in 5.4% of males and 14.92% of females, Type IV pattern was seen in 2.71% of males and 5.97% of females. There was no statistically significant difference among all the patterns between males and females (Chi-square value 3.623 and $P > 0.05$) [Graph 4].

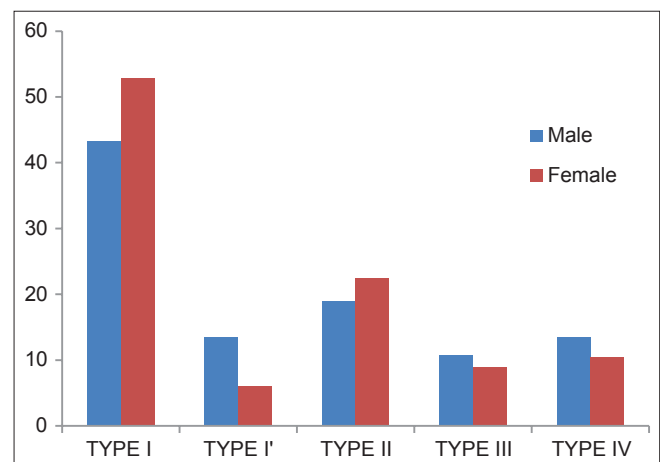
In the present study, 27 subjects had the same type of lip pattern in all the quadrants. Of the studied subjects, 26 had Type I lip pattern and one had Type I' lip pattern and out of them 20 were females.

Discussion

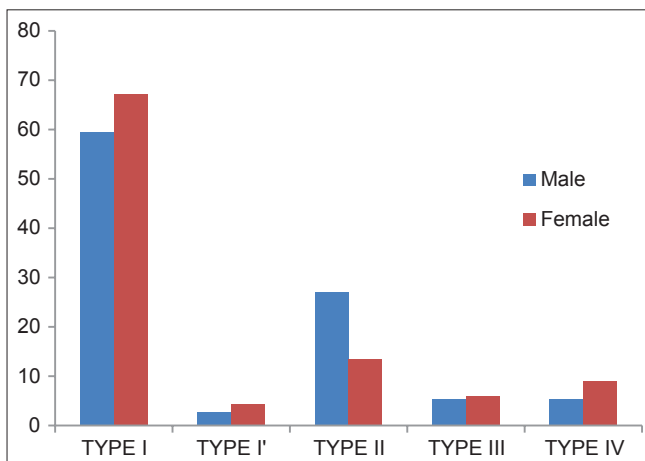
Libya was historically subdivided into three administrative regions i.e., the North-east (Tripoli province), North-west (Berca-Benghazi province) and south (Fezzan region). Sebha city is the capital city and the only large urban



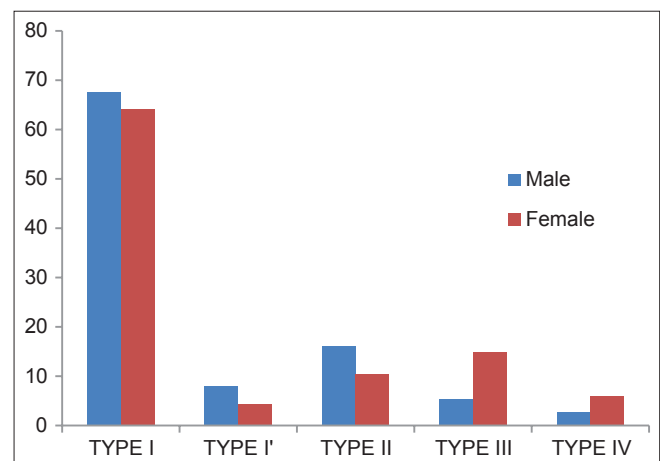
Graph 1: Distribution of subjects by gender in relation to type of lip print pattern in upper left quadrant (percentage)



Graph 2: Distribution of subjects by gender in relation to type of lip print pattern in upper right quadrant (percentage)



Graph 3: Distribution of subjects by gender in relation to type of lip print pattern in the lower right quadrant (percentage)



Graph 4: Distribution of subjects by gender in relation to type of lip print pattern in the lower left quadrant (percentage)

settlement in the Fezzan region, so Sebha city represents south of Libya. The results of the present study can be extrapolated to the South Libyan population/races-Fezzan region.

Lip prints are prints of an individualistic anatomical character of human lips. Lip print recording is a very useful tool in forensic investigation and may be at times the only available aid at a crime scene. Hence, this study was carried out to study and evaluate the common lip patterns and their variations in the study population and the differences between the sexes.

The most common pattern of lip print in the present study was Type I pattern among both the genders. The results of the present study were in complete coincidence with the studies by Ragab *et al.*^[6] among Egyptian population and Sandhu *et al.*^[7] among Punjabi Indian populations where they found complete vertical pattern to be the most common lip pattern in both genders. The present study differed with the studies conducted by El Domiaty *et al.*^[8] in Almadinah Almonawarah, Costa and Cladas,^[9] among the Portuguese population, Prabhu *et al.*^[10] among Goan Indian population where complete vertical grooves were not the most common ones.

In the present study in upper left quadrant Type I pattern of lip print was most common, which is similar to the results reported by Vahanwala and Parekh,^[11] but in contrast with results reported by Amith *et al.*^[12] which reported Type I' being the most common.

In the present study, most of the subjects, who had similar lip patterns in all the quadrants, were females. This was similar to the findings reported by Amith *et al.*^[12] and Vahanwala and Parekh.^[11]

In the present study, there was no statistically significant difference between males and females regarding any type of lip pattern and that the sex could not be differentiated from the lip print. Similar findings were reported by Ragab *et al.*^[6] among the Egyptian population and by Prabhu *et al.*^[10] in Goan Indian population, whereas contrary findings were reported by Costa and Cladas,^[9] in Portuguese population.

Limitations of the present study

The South Libyan population is generally slightly dark skinned homogenous one with the heterogeneity in that the majority being Arabic speakers and in lingual minorities

who speak languages of African accent. The authors could not record inter racial difference taking into consideration the prevalent precarious postwar security situation and the cultural sensitivities associated with lingual affiliations.

Conclusion

The conclusions of the present study are as follows:

- The most common pattern of lip print was Type I followed by Type II, Type III and Type IV. Type I' was the least common lip print pattern. This was found in both genders and was common across the various quadrants
- No gender-wise difference was observed among the lip prints pattern
- No statistically significant difference was found between the genders.

References

1. Tsuchihashi Y. Studies on personal identification by means of lip prints. *Forensic Sci* 1974;3:233-48.
2. Sivapathasundharam B, Prakash PA, Sivakumar G. Lip prints (cheiloscopy). *Indian J Dent Res* 2001;12:234-7.
3. Santos M. Queiloscopy: A supplementary stomatological means of identification. *Int Microform J Leg Med* 1967;2:64-68.
4. Suzuki K, Tsuchihashi Y. New attempt of personal identification by means of lip print. *J Indian Dent Assoc* 1970;42:8-9.
5. Renaud M. Cheiloscopy identification in forensic medicine. *Nouv Presse Med* 1973;2:2617-20.
6. Ragab AR, El-Dakroory SA, Rahman RH. Characteristic patterns of lip prints in Egyptian population sample at Dhakalia governorate. *Int J Leg Med* 2012;127:521-7.
7. Sandhu SV, Bansal H, Monga P, Bhandari R. Study of lip print pattern in a Punjabi population. *J Forensic Dent Sci* 2012;4:24-8.
8. El Domiaty MA, Al-gaidi SA, Elayat AA, Safwat MD, Galal SA. Morphological patterns of lip prints in Saudi Arabia at Almadinah Almonawarah province. *Forensic Sci Int* 2010;200:179.e1-9.
9. Costa VA, Caldas IM. Morphologic patterns of lip prints in a Portuguese population: A preliminary analysis. *J Forensic Sci* 2012;57:1318-22.
10. Prabhu RV, Dinkar A, Prabhu V. A study of lip print pattern in Goan dental students-A digital approach. *J Forensic Leg Med* 2012;19:390-5.
11. Vahanwala SP, Parekh BK. Study of lip prints as an aid to forensic methodology. *J Forensic Med Toxicol* 2000;17:12-8.
12. Amith HV, Ankola AV, Nagesh L. Lip prints-can it aid in individual identification. *J Oral Health Community Dent* 2011;5:113-8.

How to cite this article: Peeran SW, Naveen Kumar PG, Abdalla KA, Azaruk FA, Manipady S, Alsaid FM. A study of lip print patterns among adults of Sebha city, Libya. *J Forensic Dent Sci* 2015;7:67-70.

Source of Support: Nil, **Conflict of Interest:** None declared