

## Physiology of the pleural space

Charalampos Charalampidis<sup>1</sup>, Andrianna Youroukou<sup>2</sup>, George Lazaridis<sup>3</sup>, Sofia Baka<sup>4</sup>, Ioannis Mpoukovinas<sup>5</sup>, Vasilis Karavasilis<sup>3</sup>, Ioannis Kioumis<sup>6</sup>, Georgia Pitsiou<sup>6</sup>, Antonis Papaiwannou<sup>6</sup>, Anastasia Karavergou<sup>6</sup>, Kosmas Tsakiridis<sup>7</sup>, Nikolaos Katsikogiannis<sup>8</sup>, Eirini Sarika<sup>8</sup>, Konstantinos Kapanidis<sup>6</sup>, Leonidas Sakkas<sup>9</sup>, Ipokratis Korantzis<sup>10</sup>, Sofia Lampaki<sup>6</sup>, Konstantinos Zarogoulidis<sup>6</sup>, Paul Zarogoulidis<sup>6</sup>

<sup>1</sup>Department of Anatomy-Medical School, Democritus University of Thrace, Alex-polis, Greece; <sup>2</sup>Cardiothoracic Surgery Department, “Evangelismos” Hospital, Athens, Greece; <sup>3</sup>Department of Medical Oncology, Aristotle University School of Medicine, Thessaloniki, Greece; <sup>4</sup>Oncology Department, “Interbalkan” European Medical Center, Thessaloniki, Greece; <sup>5</sup>Oncology Department, “BioMedicine” Private Clinic, Thessaloniki, Greece; <sup>6</sup>Pulmonary-Oncology, “G. Papanikolaou” General Hospital, Aristotle University of Thessaloniki, Thessaloniki, Greece; <sup>7</sup>Thoracic Surgery Department, “Saint Luke” Private Hospital, Thessaloniki, Greece; <sup>8</sup>Surgery Department, University General Hospital of Alexandroupolis, Alexandroupolis, Greece; <sup>9</sup>Pathology Department, “G. Papanikolaou” General Hospital, Aristotle University of Thessaloniki, Thessaloniki, Greece; <sup>10</sup>Oncology Department, “Saint Luke” Private Hospital, Thessaloniki, Greece

*Correspondence to:* Paul Zarogoulidis, MD, PhD. Pulmonary Department-Oncology Unit, “G. Papanikolaou” General Hospital, Aristotle University of Thessaloniki, Thessaloniki, Greece. Email: pzarog@hotmail.com.

**Abstract:** The pleural cavity is created between the 4<sup>th</sup> and 7<sup>th</sup> week of embryologic development. These embryonic components of visceral and parietal pleurae develop different anatomic characteristics with regard to vascular, lymphatic, and nervous supply. There are two layers: a superficial mesothelial cell layer facing the pleural space and an underlying connective tissue layer. The pleura might present inflammatory response and maintenance of the pleural fluid is observed. The latter function is especially important in the mechanical coupling of the lung and chest wall. Fluid is filtered into the pleural space according to the net hydrostatic oncotic pressure gradient. It flows downward along a vertical pressure gradient, presumably determined by hydrostatic pressure and resistance to viscous flow. There also may be a net movement of fluid from the costal pleura to the mediastinal and interlobar regions. In these areas, pleural fluid is resorbed primarily through lymphatic stomata on the parietal pleural surface. In the current review we will present the physiology of the pleural space in a step by step manner.

**Keywords:** Pneumothorax; physiology; pleural space

Submitted Dec 07, 2014. Accepted for publication Dec 30, 2014.

doi: 10.3978/j.issn.2072-1439.2014.12.48

**View this article at:** <http://dx.doi.org/10.3978/j.issn.2072-1439.2014.12.48>

The pleural cavity is created between the 4-7 weeks of embryologic development and is lined by the splanchnopleurae and somatopleurae. These embryonic components of visceral and parietal pleurae develop different anatomic characteristics. Both pleurae have two layers. A superficial mesothelial cell layer facing the pleural space and an underlying connective tissue layer (1-10). There is a relationship of the functions of the pleural membranes—local inflammatory response and maintenance of the pleural fluid. The fluid in the pleural space transmits transpleural forces involved in normal respiration. It flows downward along a vertical pressure gradient presumably

determined by hydrostatic pressure. There a net movement of fluid from the costal pleura to the mediastinal (from lymphatic stomata on the parietal pleura surface).

A primitive body cavity with stretchable mesothelial cells endows the subsequently developed internal organs a great flexibility to expand. The lung is maintained in inflated state by the mechanical coupling between the lung and the chest wall. Normal mesothelial cells are fragile in the air (11-20). The activated mesothelial cells are resilient and rich in organelles and enzymes. Fluid and electrolytes permeate freely between normal mesothelial cells (Starling's law) with the endothelium as the main barrier. Proteins and

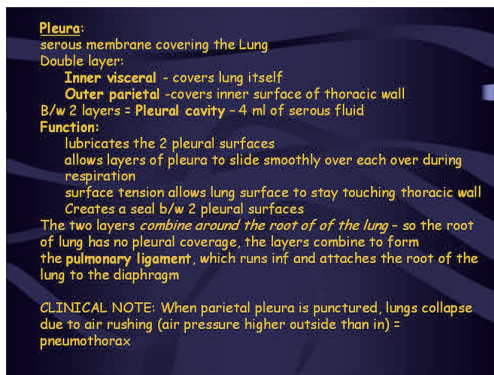


Figure 1 Pleura pathology.

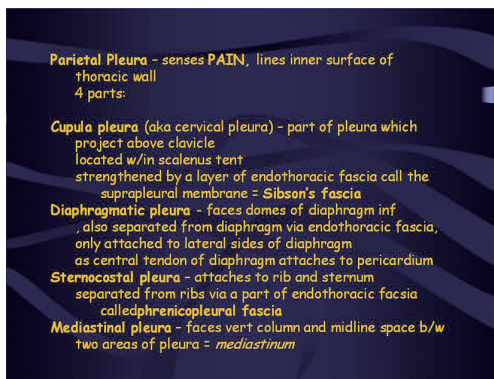


Figure 2 Pleura pathology (continue).

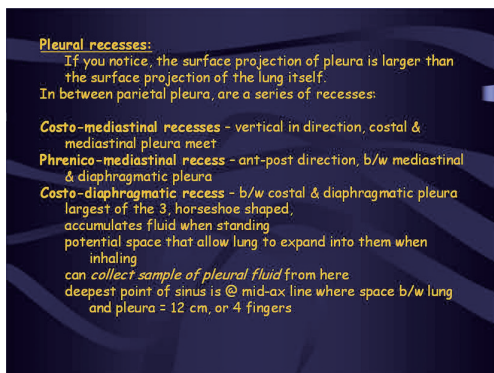


Figure 3 Pleura recesses.

cells are removed mainly from the preformed stomas and the lymphatic lacuna present in the lower mediastinum—portions of the diaphragm (21-30). This removal of the pleura fluid and particles by the lymphatic route is enhanced by the respiratory movements. Kampmeier's foci are

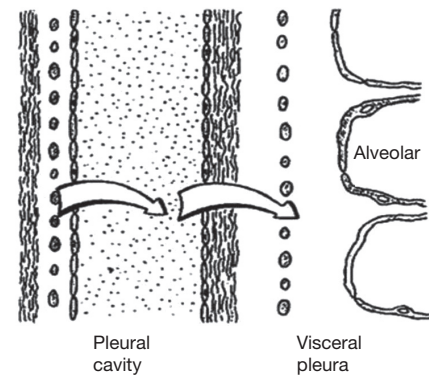


Figure 4 Physiology of the pleura.

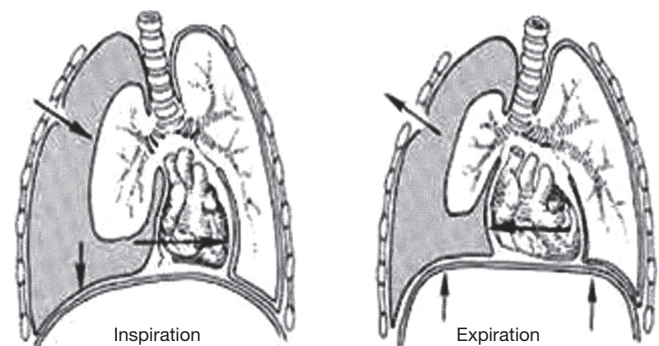


Figure 5 Mechanism of breathing showing: inspiration-exhalation.

conglomerates of activated mesothelial and lymphoreticular cells with central capillary and lymphatic vessels. They impede direct from the pleural cavity into chest wall and mediastinum (31-40).

Pneumothorax refers to air in the pleural sac. It may occur in the absence of known pulmonary disease or as a result of some thoracic or lung disorder. Secondary, it occurs with rupture of any pulmonary lesion situated close to the pleural surface allows inspired air to gain access to the pleural cavity. There are several possible complications of pneumothorax. A ball-valve leak may create a tension pneumothorax that shifts the mediastinum. Compromise of the pulmonary circulation may follow and may even be fatal. If the leak seals and the lung are not reexpanded within a few weeks, enough scarring may occur so that it can never be fully reexpanded. With prolonged collapse, the lung becomes vulnerable to infection, as does the pleura cavity when communication between it and the lung persists (32,41-48).

Pneumothorax tends to be recurrent. This is understandable when it complicates other pulmonary disease because the predisposing condition remains (Figures 1-11).

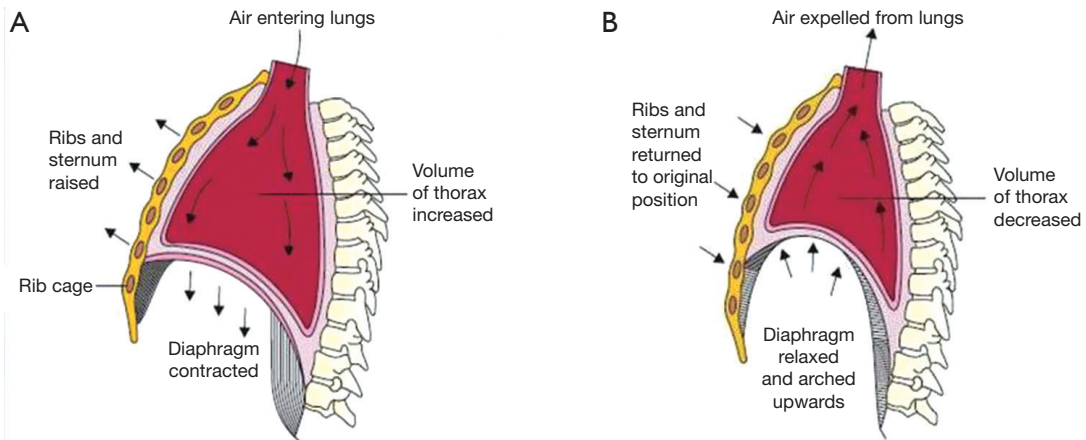


Figure 6 Mechanism of breathing showing: (A) inspiration; (B) exhalation.

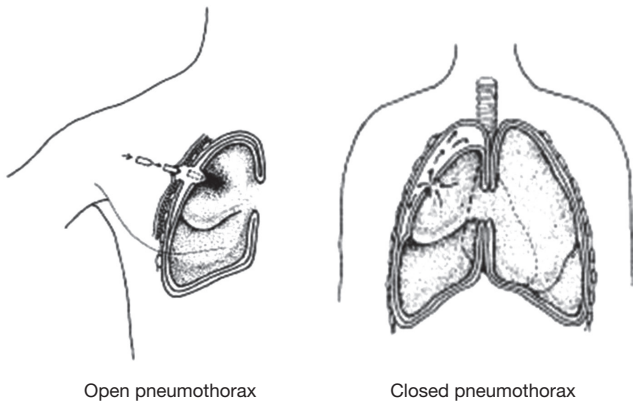


Figure 7 Types of pneumothorax.

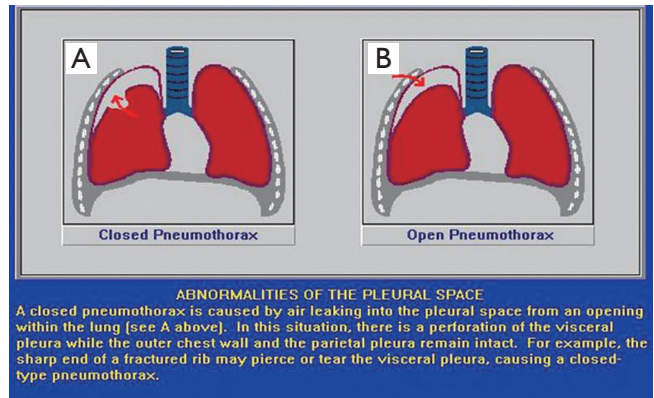


Figure 8 Closed (A) and open pneumothorax (B).

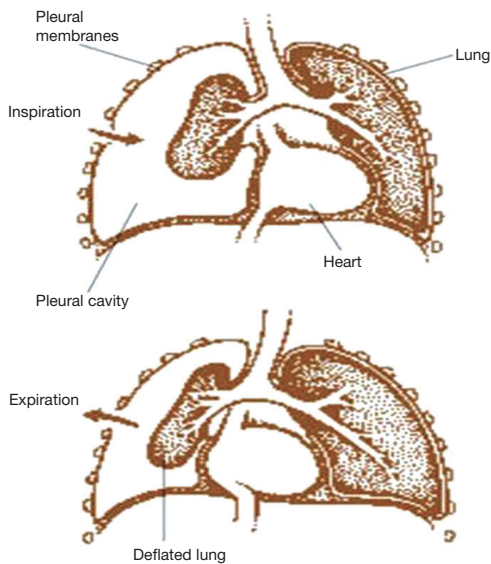


Figure 9 Pneumothorax; inspiration and exhalation.

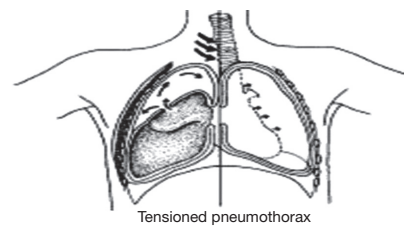


Figure 10 Tensioned pneumothorax.

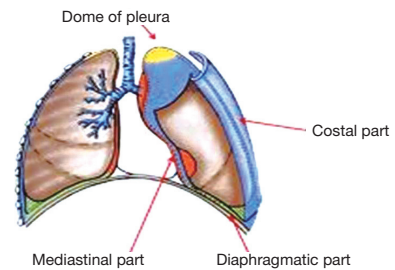


Figure 11 Thorax anatomies.

## Acknowledgements

*Disclosure:* The authors declare no conflict of interest.

## References

- Anderson RH, Sarwark AE, Spicer DE, et al. Exercises in anatomy: holes between the ventricles. *Multimed Man Cardiothorac Surg* 2014;2014.
- Fitting JW. From Breathing to Respiration. *Respiration* 2014. [Epub ahead of print].
- Wang NS. Anatomy and physiology of the pleural space. *Clin Chest Med* 1985;6:3-16.
- Lee KF, Olak J. Anatomy and physiology of the pleural space. *Chest Surg Clin N Am* 1994;4:391-403.
- Kioumis IP, Zarogoulidis K, Huang H, et al. Pneumothorax in cystic fibrosis. *J Thorac Dis* 2014;6:S480-7.
- Kuhajda I, Zarogoulidis K, Kougioumtzi I, et al. Tube thoracostomy; chest tube implantation and follow up. *J Thorac Dis* 2014;6:S470-9.
- Manika K, Kioumis I, Zarogoulidis K, et al. Pneumothorax in sarcoidosis. *J Thorac Dis* 2014;6:S466-9.
- Kuhajda I, Zarogoulidis K, Kougioumtzi I, et al. Penetrating trauma. *J Thorac Dis* 2014;6:S461-5.
- Visouli AN, Zarogoulidis K, Kougioumtzi I, et al. Catamenial pneumothorax. *J Thorac Dis* 2014;6:S448-60.
- Huang Y, Huang H, Li Q, et al. Transbronchial lung biopsy and pneumothorax. *J Thorac Dis* 2014;6:S443-7.
- Terzi E, Zarogoulidis K, Kougioumtzi I, et al. Acute respiratory distress syndrome and pneumothorax. *J Thorac Dis* 2014;6:S435-42.
- Boskovic T, Stojanovic M, Stanic J, et al. Pneumothorax after transbronchial needle biopsy. *J Thorac Dis* 2014;6:S427-34.
- Li Z, Huang H, Li Q, et al. Pneumothorax: observation. *J Thorac Dis* 2014;6:S421-6.
- Huang Y, Huang H, Li Q, et al. Approach of the treatment for pneumothorax. *J Thorac Dis* 2014;6:S416-20.
- Browning RF, Parrish S, Sarkar S, et al. Bronchoscopic interventions for severe COPD. *J Thorac Dis* 2014;6:S407-15.
- Machairiotis N, Kougioumtzi I, Dryllis G, et al. Laparoscopy induced pneumothorax. *J Thorac Dis* 2014;6:S404-6.
- Ouellette DR, Parrish S, Browning RF, et al. Unusual causes of pneumothorax. *J Thorac Dis* 2014;6:S392-403.
- Parrish S, Browning RF, Turner JF Jr, et al. The role for medical thoracoscopy in pneumothorax. *J Thorac Dis* 2014;6:S383-91.
- Terzi E, Zarogoulidis K, Kougioumtzi I, et al. Human immunodeficiency virus infection and pneumothorax. *J Thorac Dis* 2014;6:S377-82.
- Zarogoulidis P, Kioumis I, Pitsiou G, et al. Pneumothorax: from definition to diagnosis and treatment. *J Thorac Dis* 2014;6:S372-6.
- Tsakiridis K, Mpakas A, Kesisis G, et al. Lung inflammatory response syndrome after cardiac-operations and treatment of lornoxicam. *J Thorac Dis* 2014;6 Suppl 1:S78-98.
- Tsakiridis K, Zarogoulidis P, Vretzkakis G, et al. Effect of lornoxicam in lung inflammatory response syndrome after operations for cardiac surgery with cardiopulmonary bypass. *J Thorac Dis* 2014;6 Suppl 1:S7-20.
- Argiriou M, Kolokotron SM, Sakellaridis T, et al. Right heart failure post left ventricular assist device implantation. *J Thorac Dis* 2014;6 Suppl 1:S52-9.
- Madesis A, Tsakiridis K, Zarogoulidis P, et al. Review of mitral valve insufficiency: repair or replacement. *J Thorac Dis* 2014;6 Suppl 1:S39-51.
- Siminelakis S, Kakourou A, Batistatou A, et al. Thirteen years follow-up of heart myxoma operated patients: what is the appropriate surgical technique? *J Thorac Dis* 2014;6 Suppl 1:S32-8.
- Foroulis CN, Kleontas A, Karatzopoulos A, et al. Early reoperation performed for the management of complications in patients undergoing general thoracic surgical procedures. *J Thorac Dis* 2014;6 Suppl 1:S21-31.
- Nikolaos P, Vasilios L, Efstratios K, et al. Therapeutic modalities for Pancoast tumors. *J Thorac Dis* 2014;6 Suppl 1:S180-93.
- Koutentakis M, Siminelakis S, Korantzopoulos P, et al. Surgical management of cardiac implantable electronic device infections. *J Thorac Dis* 2014;6 Suppl 1:S173-9.
- Spyratos D, Zarogoulidis P, Porpodis K, et al. Preoperative evaluation for lung cancer resection. *J Thorac Dis* 2014;6 Suppl 1:S162-6.
- Porpodis K, Zarogoulidis P, Spyrtos D, et al. Pneumothorax and asthma. *J Thorac Dis* 2014;6 Suppl 1:S152-61.
- Panagopoulos N, Leivaditis V, Koletsis E, et al. Pancoast tumors: characteristics and preoperative assessment. *J Thorac Dis* 2014;6 Suppl 1:S108-15.
- Visouli AN, Darwiche K, Mpakas A, et al. Catamenial pneumothorax: a rare entity? Report of 5 cases and review of the literature. *J Thorac Dis* 2012;4 Suppl 1:17-31.
- Zarogoulidis P, Chatzaki E, Hohenforst-Schmidt W, et al.

- Management of malignant pleural effusion by suicide gene therapy in advanced stage lung cancer: a case series and literature review. *Cancer Gene Ther* 2012;19:593-600.
34. Papaioannou M, Pitsiou G, Manika K, et al. COPD assessment test: a simple tool to evaluate disease severity and response to treatment. *COPD* 2014;11:489-95.
  35. Boskovic T, Stanic J, Pena-Karan S, et al. Pneumothorax after transthoracic needle biopsy of lung lesions under CT guidance. *J Thorac Dis* 2014;6 Suppl 1:S99-107.
  36. Papaiwannou A, Zarogoulidis P, Porpodis K, et al. Asthma-chronic obstructive pulmonary disease overlap syndrome (ACOS): current literature review. *J Thorac Dis* 2014;6 Suppl 1:S146-51.
  37. Zarogoulidis P, Porpodis K, Kioumis I, et al. Experimentation with inhaled bronchodilators and corticosteroids. *Int J Pharm* 2014;461:411-8.
  38. Bai C, Huang H, Yao X, et al. Application of flexible bronchoscopy in inhalation lung injury. *Diagn Pathol* 2013;8:174.
  39. Zarogoulidis P, Kioumis I, Porpodis K, et al. Clinical experimentation with aerosol antibiotics: current and future methods of administration. *Drug Des Devel Ther* 2013;7:1115-34.
  40. Zarogoulidis P, Pataka A, Terzi E, et al. Intensive care unit and lung cancer: when should we intubate? *J Thorac Dis* 2013;5 Suppl 4:S407-12.
  41. Hohenforst-Schmidt W, Petermann A, Visouli A, et al. Successful application of extracorporeal membrane oxygenation due to pulmonary hemorrhage secondary to granulomatosis with polyangiitis. *Drug Des Devel Ther* 2013;7:627-33.
  42. Zarogoulidis P, Kontakiotis T, Tsakiridis K, et al. Difficult airway and difficult intubation in postintubation tracheal stenosis: a case report and literature review. *Ther Clin Risk Manag* 2012;8:279-86.
  43. Zarogoulidis P, Tsakiridis K, Kioumis I, et al. Cardiothoracic diseases: basic treatment. *J Thorac Dis* 2014;6 Suppl 1:S1.
  44. Kolettas A, Grosomanidis V, Kolettas V, et al. Influence of apnoeic oxygenation in respiratory and circulatory system under general anaesthesia. *J Thorac Dis* 2014;6 Suppl 1:S116-45.
  45. Turner JF, Quan W, Zarogoulidis P, et al. A case of pulmonary infiltrates in a patient with colon carcinoma. *Case Rep Oncol* 2014;7:39-42.
  46. Machairiotis N, Stylianaki A, Dryllis G, et al. Extrapelvic endometriosis: a rare entity or an under diagnosed condition? *Diagn Pathol* 2013;8:194.
  47. Tsakiridis K, Zarogoulidis P. An interview between a pulmonologist and a thoracic surgeon-Pleuroscopy: the reappearance of an old definition. *J Thorac Dis* 2013;5 Suppl 4:S449-51.
  48. Huang H, Li C, Zarogoulidis P, et al. Endometriosis of the lung: report of a case and literature review. *Eur J Med Res* 2013;18:13.

**Cite this article as:** Charalampidis C, Youroukou A, Lazaridis G, Baka S, Mpoukovinas I, Karavasilis V, Kioumis I, Pitsiou G, Papaiwannou A, Karavergou A, Tsakiridis K, Katsikogiannis N, Sarika E, Kapanidis K, Sakkas L, Korantzis I, Lampaki S, Zarogoulidis K, Zarogoulidis P. Physiology of the pleural space. *J Thorac Dis* 2015;7(S1):S33-S37. doi: 10.3978/j.issn.2072-1439.2014.12.48