



CASE REPORT

Case Report: Bilateral reexpansion pulmonary edema following treatment of a unilateral hemothorax [v1; ref status: indexed, <http://f1000r.es/4yb>]

Steven P de Wolf^{1,2,4,5}, Jaap Deunk³⁻⁵, Alexander D Cornet^{1,4,5}, Paul WG Elbers^{1,4,5}

¹Department of Intensive Care Medicine, VU University Medical Center, De Boelelaan 1117, 1081 HZ, Amsterdam, Netherlands

²Department of Anesthesiology, VU University Medical Center, De Boelelaan 1117, 1081 HZ, Amsterdam, Netherlands

³Department of Trauma Surgery, VU University Medical Center, De Boelelaan 1117, 1081 HZ, Amsterdam, Netherlands

⁴Institute for Cardiovascular Research VU (ICaR-VU), De Boelelaan 1117, 1081 HZ, Amsterdam, Netherlands

⁵Research VUmc Intensive Care (REVIVE), De Boelelaan 1117, 1081 HZ, Amsterdam, Netherlands

v1 First published: 30 Dec 2014, 3:318 (doi: [10.12688/f1000research.6000.1](https://doi.org/10.12688/f1000research.6000.1))
 Latest published: 30 Dec 2014, 3:318 (doi: [10.12688/f1000research.6000.1](https://doi.org/10.12688/f1000research.6000.1))

Abstract

Bilateral re-expansion pulmonary edema (RPE) is an extremely rare entity. We report the unique case of bilateral RPE following a traumatic, unilateral hemopneumothorax in a young healthy male. Bilateral RPE occurred only one hour after drainage of a unilateral hemopneumothorax. The patient was treated with diuretics and supplemental oxygen. Diagnosis was confirmed by excluding other causes, using laboratory findings, chest radiography, pulmonary and cardiac ultrasound and high resolution computed tomography. His recovery was uneventful. The pathophysiology of bilateral RPE is not well known. Treatment is mainly supportive and consists of diuretics, mechanical ventilation, inotropes and steroids. In case of a pulmonary deterioration after the drainage of a traumatic pneumothorax, bilateral RPE should be considered after exclusion of more common causes of dyspnea.

Open Peer Review

Referee Status:

	Invited Referees	
	1	2
version 1 published 30 Dec 2014	 report	 report
1	André Coetzee , University of Stellenbosch South Africa	
2	Ehab Farag , The Cleveland Clinic Foundation USA	

Discuss this article

Comments (0)

Corresponding author: Paul WG Elbers (p.elbers@vumc.nl)

How to cite this article: de Wolf SP, Deunk J, Cornet AD and Elbers PW. **Case Report: Bilateral reexpansion pulmonary edema following treatment of a unilateral hemothorax [v1; ref status: indexed, <http://f1000r.es/4yb>]** *F1000Research* 2014, 3:318 (doi: [10.12688/f1000research.6000.1](https://doi.org/10.12688/f1000research.6000.1))

Copyright: © 2014 de Wolf SP *et al.* This is an open access article distributed under the terms of the [Creative Commons Attribution Licence](#), which permits unrestricted use, distribution, and reproduction in any medium, provided the original work is properly cited. Data associated with the article are available under the terms of the [Creative Commons Zero "No rights reserved" data waiver](#) (CC0 1.0 Public domain dedication).

Grant information: The author(s) declared that no grants were involved in supporting this work.

Competing interests: No competing interests were disclosed.

First published: 30 Dec 2014, 3:318 (doi: [10.12688/f1000research.6000.1](https://doi.org/10.12688/f1000research.6000.1))

First indexed: 18 Feb 2015, 3:318 (doi: [10.12688/f1000research.6000.1](https://doi.org/10.12688/f1000research.6000.1))

Introduction

We report here on a unique case of bilateral re-expansion pulmonary edema (RPE). First described in 1958, RPE is a rare, but well known complication of thoracocentesis¹. RPE usually occurs unilaterally after expansion of the ipsilateral collapsed lung caused by either spontaneous pneumothorax or various types of pleural effusion². However, in this case, RPE occurred bilaterally, following expansion of a unilateral hemopneumothorax in the setting of trauma.

Case

A 31-year old caucasian male with no significant past medical history was brought to our emergency department after falling 1.5 meters down from a platform. He was fully conscious and both respiratory and hemodynamically stable. Secondary survey findings included a fractured left olecranon and fractures of costae 7 to 9 on the left side, without clinical or radiological signs of a pneumothorax.

After two days in the hospital, he underwent tension band wiring of his olecranon under general anaesthesia. There were no difficulties during mechanical ventilation. However, on the first postoperative day, his peripheral oxygen saturation was noted to be 93% without supplemental oxygen. Auscultation yielded decreased breath sounds on the left side and a chest radiograph showed a fully collapsed left lung with pleural effusion (Figure 1). A chest tube was placed which immediately drained air and 250 mL of blood.

To our surprise, follow-up chest radiography one hour after drainage, demonstrated diffuse bilateral airspace opacification, peribronchial cuffing and Kerley-B lines, indicating bilateral pulmonary edema (Figure 2). The chest tube was in a good position. In the course of several hours our patient became increasingly dyspnoeic, requiring 15 liters of oxygen via a non-rebreathing mask. He was transferred to the intensive care unit.

Intensive care ultrasound showed bilateral B-lines in all lung fields (Figure 3), normal left and right ventricular function, no valvular dysfunction, normal atrial and caval vein dimensions and no pericardial effusion. These findings are consistent with non-cardiogenic

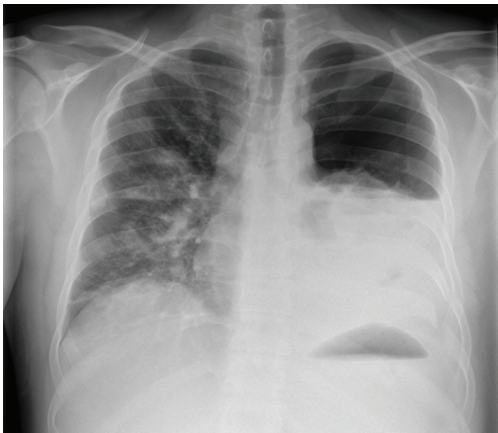


Figure 1. Chest radiograph showing a hemopneumothorax of the left lung.

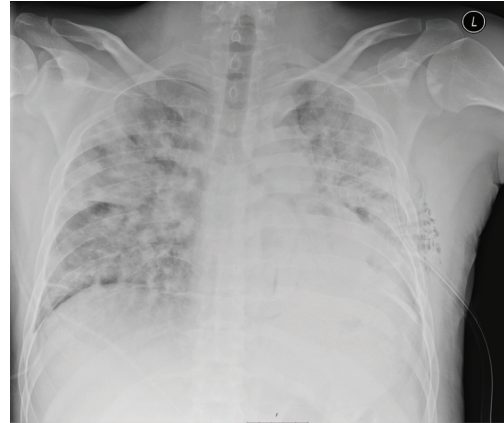

Figure 2. Chest radiograph one hour after drainage of the left hemopneumothorax showing bilateral pulmonary edema.

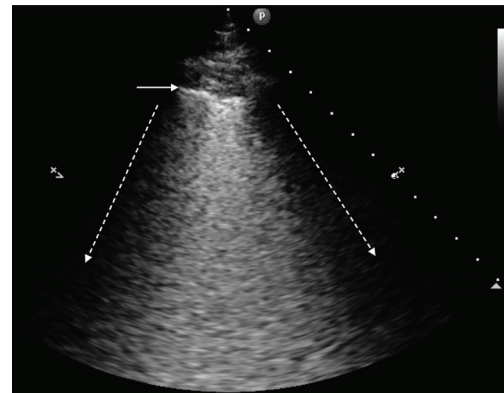


Figure 3. Ultrasound image of the upper right lobe. The dotted arrows indicate the rib shadows. The horizontal arrow indicates the pleura. Between the dotted arrows B-lines can be seen in a pattern called ground-glass rockets, showing an interstitial syndrome.

pulmonary edema. Our patient did not receive excessive fluid therapy or blood transfusions and N-terminal-pro-B-type natriuretic peptide was normal (430ng/L), as were white cell count ($9.6 \times 10^9/L$) and C-reactive protein (23mg/L). Through this process of exclusion, and consistent with recent lung re-expansion, our patient was diagnosed with bilateral RPE.

Aggressive diuretic therapy markedly improved his dyspnea without the need for mechanical ventilation and our patient was transferred back to the ward after 24 hours. Because of a persisting dependency of supplemental oxygen, high resolution computed tomography was performed two days later. This confirmed our diagnosis of bilateral pulmonary edema and revealed two additional rib fractures on the left side. Diuretics and oxygen suppletion were discontinued after a few days, and twelve days after the initial trauma our patient was discharged to home.

Discussion

To the best of our knowledge, this is the first report of bilateral RPE following thoracocentesis of a unilateral traumatic hemopneumothorax. A few cases of bilateral RPE have been described

in literature³⁻¹¹. However, none of these cases were preceded by a traumatic injury. In fact, most reported cases of either unilateral or bilateral RPE followed non-traumatic pneumothorax, pleural empyema or pleural effusion. The incidence of unilateral RPE is between 0 and 6,5% whereas bilateral RPE is extremely rare¹¹⁻¹⁴.

The pathophysiology of bilateral RPE is not well known. Increased levels of the pro-inflammatory cytokine interleukin-8 and monocyte chemo-attractant protein 1 might be involved in the inflammatory process that characterizes RPE¹⁵. In addition, re-expansion of the lung may lead to reperfusion injury and increased permeability of the endothelial cells¹⁶. A prolonged collapse seems to result in an increased risk for RPE^{4,11}. Other risk factors include the extent of lung collapse, young age¹⁷ and fast re-expansion using suction⁴. Treatment is still mainly supportive and relies mostly on diuretics but may necessitate mechanical ventilation, inotropes and steroids^{11,17}.

In conclusion, bilateral re-expansion pulmonary edema is an extremely rare but fascinating phenomenon following treatment of a unilateral traumatic hemopneumothorax. In case of a pulmonary

deterioration after the drainage of a traumatic pneumothorax, bilateral RPE should be considered, after exclusion of more common causes of dyspnea.

Consent

Written informed consent for publication of clinical details and clinical images was obtained from the patient.

Author contributions

SdW, JD and PE contributed to data acquisition. SdW prepared the first draft of the manuscript. JD, AC and PE contributed to manuscript drafting.

Competing interests

No competing interests were disclosed.

Grant information

The author(s) declared that no grants were involved in the funding of this work.

References

- Carlson RI, Classen KL, Gollan F, *et al.*: **Pulmonary edema following the rapid reexpansion of a totally collapsed lung due to a pneumothorax: a clinical and experimental study.** *Surg Forum.* 1958; **9**: 367–371.
[PubMed Abstract](#)
- Neustein SM: **Reexpansion pulmonary edema.** *J Cardiothorac Vasc Anesth.* 2007; **21**(6): 887–891.
[PubMed Abstract](#) | [Publisher Full Text](#)
- Henderson AF, Banham SW, Moran F: **Re-expansion pulmonary oedema: a potentially serious complication of delayed diagnosis of pneumothorax.** *Br Med J (Clin Res Ed).* 1985; **291**(6495): 593–594.
[PubMed Abstract](#) | [Publisher Full Text](#) | [Free Full Text](#)
- Mahfood S, Hix WR, Aaron BL, *et al.*: **Reexpansion pulmonary edema.** *Ann Thorac Surg.* 1988; **45**(3): 340–345.
[PubMed Abstract](#) | [Publisher Full Text](#)
- Ragozzino MW, Green R: **Bilateral reexpansion pulmonary edema following unilateral pleurocentesis.** *Chest.* 1991; **99**(2): 506–508.
[PubMed Abstract](#) | [Publisher Full Text](#)
- Özlü O, Kilic A, Cengizlier R: **Bilateral re-expansion pulmonary edema in a child: a reminder.** *Acta Anaesthesiol Scand.* 2000; **44**(7): 884–885.
[PubMed Abstract](#) | [Publisher Full Text](#)
- Dubose J, Perciballi J, Timmer S, *et al.*: **Bilateral reexpansion pulmonary edema after treatment of spontaneous pneumothorax.** *Curr Surg.* 2004; **61**(4): 376–379.
[PubMed Abstract](#)
- Baik JH, Ahn MI, Park YH, *et al.*: **High-resolution CT findings of re-expansion pulmonary edema.** *Korean J Radiol.* 2010; **11**(2): 164–168.
[PubMed Abstract](#) | [Publisher Full Text](#) | [Free Full Text](#)
- Paksu MS, Paksu S, Akgün M, *et al.*: **Bilateral reexpansion pulmonary edema associated with pleural empyema: a case report.** *Eur J Pediatr.* 2011; **170**(9): 1205–1207.
[PubMed Abstract](#) | [Publisher Full Text](#)
- Gleeson T, Thiessen R, Müller N: **Reexpansion Pulmonary edema computed tomography findings in 22 patients.** *J Thorac Imaging.* 2011; **26**(1): 36–41.
[PubMed Abstract](#) | [Publisher Full Text](#)
- Haga T, Kurihara M, Kataoka H: **The risk for re-expansion pulmonary edema following spontaneous pneumothorax.** *Surg Today.* 2013; **44**(10): 1823–7.
[PubMed Abstract](#) | [Publisher Full Text](#)
- Mills M, Balsch BF: **Spontaneous pneumothorax: A series of 400 cases.** *Ann Thorac Surg.* 1965; **122**: 286–297.
[PubMed Abstract](#) | [Publisher Full Text](#)
- Brooks JW: **Open thoracotomy in the management of spontaneous pneumothorax.** *Ann Surg.* 1973; **177**(6): 798–805.
[PubMed Abstract](#) | [Free Full Text](#)
- Rozenman J, Yellin A, Simansky DA, *et al.*: **Re-expansion pulmonary oedema following spontaneous pneumothorax.** *Respir Med.* 1996; **90**(4): 235–238.
[PubMed Abstract](#) | [Publisher Full Text](#)
- Sakao Y, Kajikawa O, Martin TR, *et al.*: **Association of IL-8 and MCP-1 with the development of reexpansion pulmonary edema in rabbits.** *Ann Thorac Surg.* 2001; **71**(6): 1825–1832.
[PubMed Abstract](#) | [Publisher Full Text](#)
- Sivrikoz MC, Tunçözgür B, Cekmen M, *et al.*: **The role of tissue reperfusion in the reexpansion injury of the lungs.** *Eur J Cardiothorac Surg.* 2002; **22**(5): 721–727.
[PubMed Abstract](#) | [Publisher Full Text](#)
- Matsuura Y, Nomimura T, Murakami H, *et al.*: **Clinical analysis of reexpansion pulmonary edema.** *Chest.* 1991; **100**(6): 1562–1566.
[PubMed Abstract](#) | [Publisher Full Text](#)

Open Peer Review

Current Referee Status:



Version 1

Referee Report 18 February 2015

doi:10.5256/f1000research.6419.r7695



Ehab Farag

Department of General Anesthesiology and Outcomes Research, The Cleveland Clinic Foundation, Cleveland, OH, USA

I approve this case report. It is well written and informative one.

I have read this submission. I believe that I have an appropriate level of expertise to confirm that it is of an acceptable scientific standard.

Competing Interests: No competing interests were disclosed.

Referee Report 06 January 2015

doi:10.5256/f1000research.6419.r7215



André Coetzee

Faculty of Health Sciences, Department of Anesthesiology and Critical Care, University of Stellenbosch, Tygerberg, 7505, South Africa

I approve of this submission.

It is a rare event and the authors rather succinctly highlight the uncertainties and possible mechanisms. The post X ray is rather stunning and without the history this could indeed be confusing!

I have read this submission. I believe that I have an appropriate level of expertise to confirm that it is of an acceptable scientific standard.

Competing Interests: No competing interests were disclosed.
