



# Acute Cervical Epidural Hematoma, Screw Pullout, and Esophageal Perforation After Anterior Cervical Corpectomy Surgery: Report of a Case

Ye Li, Qing-San Zhu, Jing-Chen Liu, Yun-Tao Wu

*Department of Spine Surgery, First Hospital of Jilin University, Changchun, China*

**To report a series of complications related to anterior cervical surgery in the same patient. There have been many reports of complications related to anterior cervical surgeries. These include cervical hematoma, instrumentation extrusion, or esophageal injury after anterior cervical decompression. However, there have been no reports of all these complications occurring in 1 patient. This is our report of a patient who experienced all 3 of these complications. The patient was a 73-year-old man suffering from cervical spondylotic myelopathy who was treated with C5 anterior cervical corpectomy and fusion with titanium mesh and bone graft. The patient successively experienced cervical hematoma, screw pullout, and esophageal perforation, and was treated accordingly. Although the patient suffered a series of complications after anterior cervical corpectomy, all the complications were treated successfully. It serves as a caution that a first complication such as hematoma in anterior cervical corpectomy with fusion should be given enough attention to prevent further complications.**

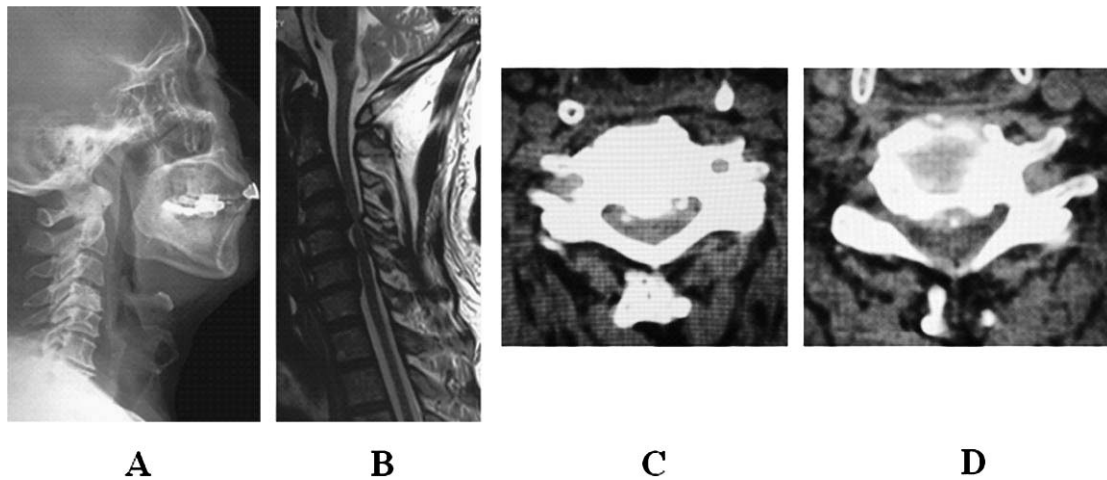
*Key words:* Anterior cervical corpectomy – Cervical spine – Esophageal perforation – Hematoma – Screw pullout

**A**nterior cervical corpectomy and decompression have long been used to manage various degenerative, traumatic, and neoplastic diseases of the cervical spine, as well as for infections, especially tuberculosis.<sup>1,2</sup> The surgical procedure has proved as safe and effective as other anterior cervical surgeries for improving nerve function, and in terms of infusion rate and complications.

---

Corresponding author: Qing-San Zhu, MD, Department of Spine Surgery, First Hospital, Jilin University, No. 71 Xinmin Street, Changchun 130021, China.

Tel: +86 431 88782854; Fax: +86 431 88782853; E-mail: liye78913@163.com



**Fig. 1** (A) Lateral radiographic image showed straightened cervical vertebrae and stenosis of disc spaces between C4 to C5 with severe deterioration. (B) Preoperative cervical MRI indicated that the spinal cord was oppressed at the level of C4–C5 and C5–C6. (C) C4–C5 CT showed that the spinal cord was oppressed by bony tissue. (D) C5–C6 CT showed that the spinal cord was oppressed by bony tissue and soft disc tissue.

There have been many reports of complications related to anterior cervical surgeries. These include cervical hematoma, early-stage breathing infarction caused by respiratory tract involvement due to fixture extrusion and consequent rupture with esophageal damage, and in the late stage, esophageal fistula caused by ischemia.<sup>3–19</sup> However, there have been no reports of all these complications occurring in 1 patient. In the present case, the patient suffered all the above complications in succession.

## Case Report

### Patient

The patient was a 73-year-old man with cervical spondylosis myelopathy, which caused him difficulty in walking and clumsiness in his hands. The preoperative Japanese Orthopaedic Association (JOA) score<sup>20</sup> was 6. There was no abnormality noted in the hematologic examination or ultrasound. Fig. 1 shows the preoperative imaging.

### Anterior cervical corpectomy

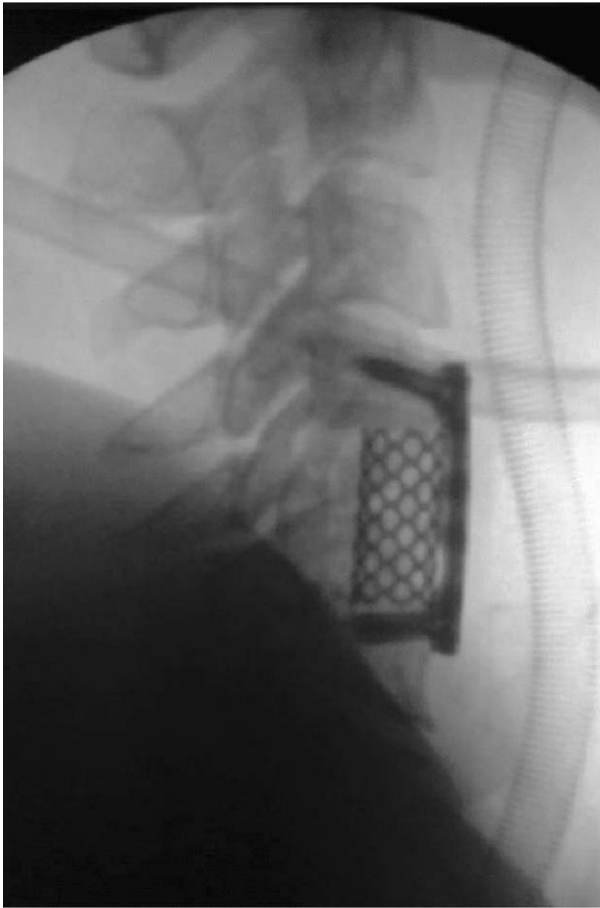
We performed C5 corpectomy, scraped off all the cartilage endplate under C4 and above C6, and preserved all the bone endplate. The C4–C5 and C5–C6 gaps were sufficiently decompressed and proliferations of the C4 posterior inferior margin and C6 posterior superior margin were removed. After complete decompression, we used bipolar coagula-

tion for hemostasis of intraspinal bleeding, and bone wax for bone hemostasis. When hemostasis was satisfactory, we crumbed the removed proliferated bone tissue into osseous granules, which were then placed into a titanium mesh. We put the mesh between the inferior endplate of C4 and superior endplate of C6. We then fixed the C4 and C6 with titanium plates with a drainage tube placed at the front. The patient woke up postoperatively and complained of paralysis in the limbs. Fig. 2 shows the fluoroscopic image taken during the surgery.

### Postoperative complications and management

Four hours after the operation, the patient complained of intolerable pain in the upper extremities, dyskinesia in both hands and upper and lower extremities, and numbness in the limbs. Magnetic resonance imaging (MRI) showed a large-scale hematoma from C2 to T2, which oppressed the spinal cord (Fig. 3).

The patient was then given emergency surgery to remove the fixture. There were blood clots beyond the titanium mesh, and we connected the suction apparatus and the infusion needle with a thin, soft tube to extract the blood clots (Fig. 4). Taking out the needle, we extended the tube into the back of C4 and C6 to clean out the clots. When it was clear around the incision, we found blood effusing from the posterior inferior of C4 and posterior superior of C6. This blood would clot quickly, which was the primary reason for hematoma. However, the bleed-



**Fig. 2** Radiofluoroscopic images taken during the first surgery showed that the position of the plate and titanium mesh was excellent.

ing and coagulation were normal. We used bone wax to lubricate the incision. The titanium mesh and steel plate were remounted and all the screws that fixed the plate were put into the same places. A tube was placed at the surface of the spinal dura mater, and the distal end was drawn out from one side of the mesh and connected with negative pressure to drain the blood on the surface of the hard die. Another negative pressure drainage tube was placed to drain blood from around the incision. Finally, the incision was sutured.

When the patient awoke from emergency surgery, he reported less pain in both upper extremities and less numbness and stronger muscle strength in upper extremities, but no improvement in the lower extremities. On the second morning after the operation, the muscle strength had restored to the preoperative level. Four days after the 2 negative-

pressure drainage tubes were placed, we found no exudation and removed them.

One week after the surgery the JOA score was 7, and increased to 9 just 1 month later, with excellent fixation of the titanium mesh and screws. Two months after the operation, an extruded screw on C6 was found, but the patient felt nothing abnormal when swallowing.

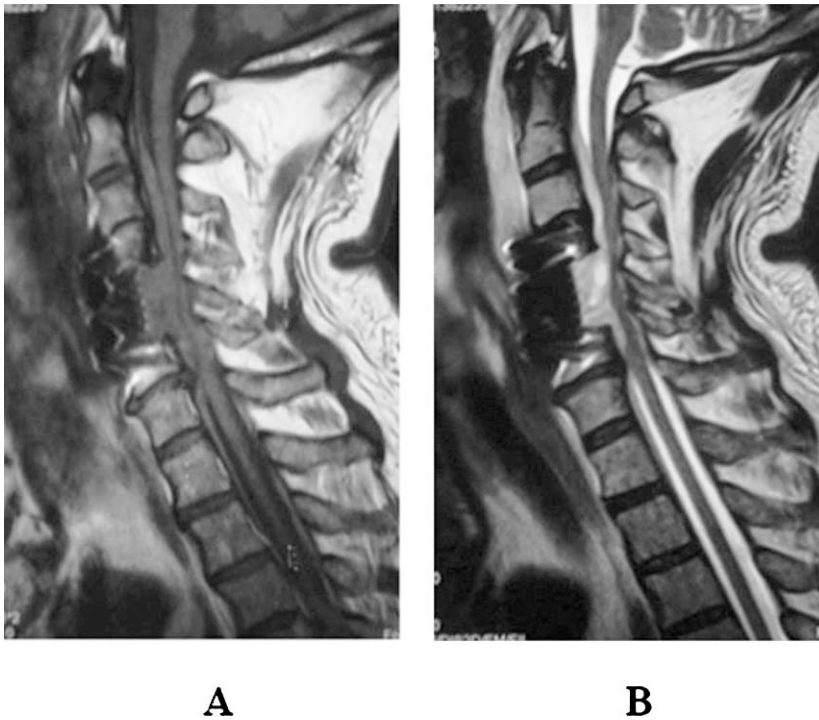
We continued to follow the patient's condition. The check-up after 3 months found no differences from that of the 2-month follow-up and the patient felt well. Five months after the operation (November 7, 2012), the JOA score was 12, but the patient complained of a foreign body sensation when swallowing. The computed tomography (CT) showed that the bone inside the titanium mesh had fused well with the bone endplate. We suggested to the patient that the steel plate and screws should be taken out, and he refused. However, it is notable that the patient believed that December 22, 2012 would be the end of the world (and therefore he would not require surgery), but if he survived he would receive the operation.

On December 23, 2012 the patient was hospitalized. A CT scan showed excellent union between the bone inside the titanium mesh and the endplate of C4 and C6 (Fig. 5). During the surgery, we found that the extruded screw had already penetrated the layers of the esophagus, but no food came out of the esophagus, and there were many inflammatory granulations on the esophageal layers around the screw. We then took out all the screws and steel plates and noted that there was much scar tissue on the surface of the titanium mesh. The esophagus was sutured and the patient was tube-fed for 2 weeks postoperatively.

Two weeks after the operation, radiography found no esophageal fistula and the feeding tube was removed (Fig. 6). One year after the repair of the esophagus, the radiography showed excellent fixation of the devices and the patient felt no abnormality in swallowing (Fig. 7).

## Discussion

As a rare complication of anterior cervical corpectomy, acute cervical epidural hematoma usually appears shortly after the operation. Emergency surgery is often needed to clear the hematoma or it will lead to rapid neurologic deterioration because of pressure on the spinal cord. Hans *et al*<sup>18</sup> reported a case of anterior cervical discectomy of C6-C7, in which difficulty in breathing and flaccid paralysis in



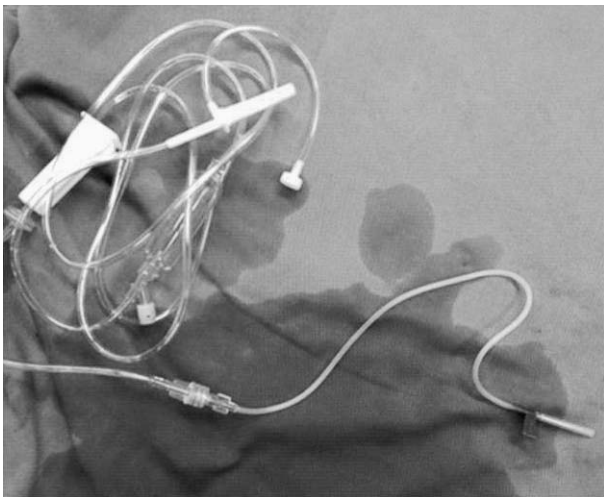**Fig. 3** (A) MRI T1W1, 4 hours after first surgery. (B) Four hours after the first surgery, MRI T2W2 indicated that hematoma from C2 to T2 oppressed the spinal cord.

the limbs occurred 2.5 hours after the operation.<sup>18</sup> The patient was immediately pushed into the operating room to receive laminectomy. MRI confirmed that there was hematoma between C3 to T3. Five days later, the patient recovered with no residual nerve dysfunction. Jankowski *et al*<sup>21</sup> reported a case of discectomy of C5 and iliac bone grafting fixed with titanium mesh. Six hours after the surgery the patient presented complete cessation

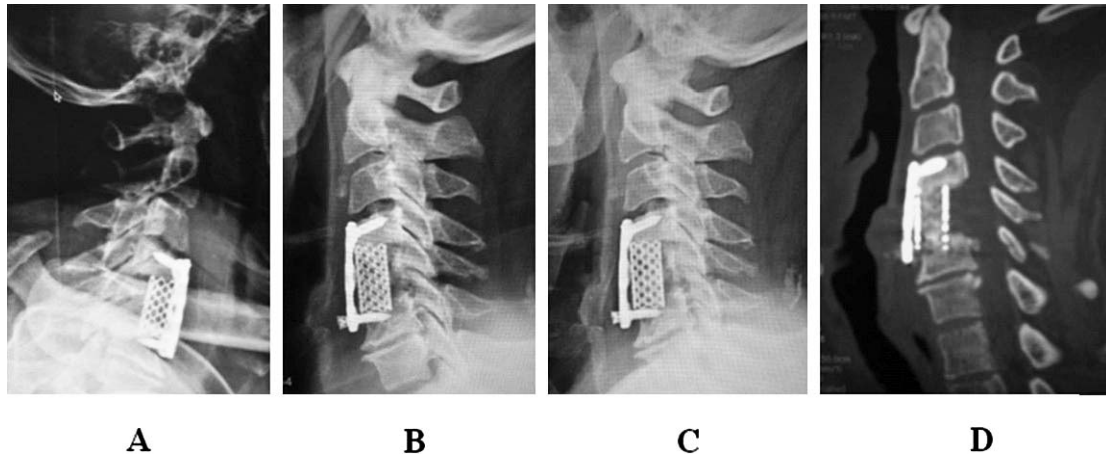
of function of the 4 extremities. MRI showed intraspinal hematoma, and anterior removal of the hematoma was performed. Twenty-four hours after the emergency operation, all nerve function had fully recovered.

Aono *et al*<sup>22</sup> retrospectively analyzed patients with postoperative epidural hematoma to find that cervical or thoracic epidural hematoma usually occurred within the first 24 hours after the surgery. A multicenter study conducted by Amiri *et al*<sup>23</sup> concluded that postoperative symptomatic epidural hematoma most often happened in the 4 hours after the operation, and early subsequent surgical intervention improved recovery of nerve function. Risk factors of epidural hematoma included alcohol consumption greater than 10 ounces a week, a multilevel surgical procedure, and previous spinal surgery. Jang *et al*<sup>24</sup> reported that risk factors of hematoma were a multilevel procedure, preoperative coagulopathy, preoperative use of nonsteroidal anti-inflammatory drugs (NSAIDs), massive hemorrhage during the surgery, Rh-positive blood type, and age greater than 60 years.<sup>24</sup>

In our case, the patient was a 73-year-old male; preoperative hematologic examination showed no abnormalities in bleeding or coagulation. The patient had no bleeding history, no drinking history, and had not undergone any previous cervical surgeries. Decompression was performed with the



**Fig. 4** A tube on the infusion apparatus was inserted into the cervical vertebra to drain the hematoma.

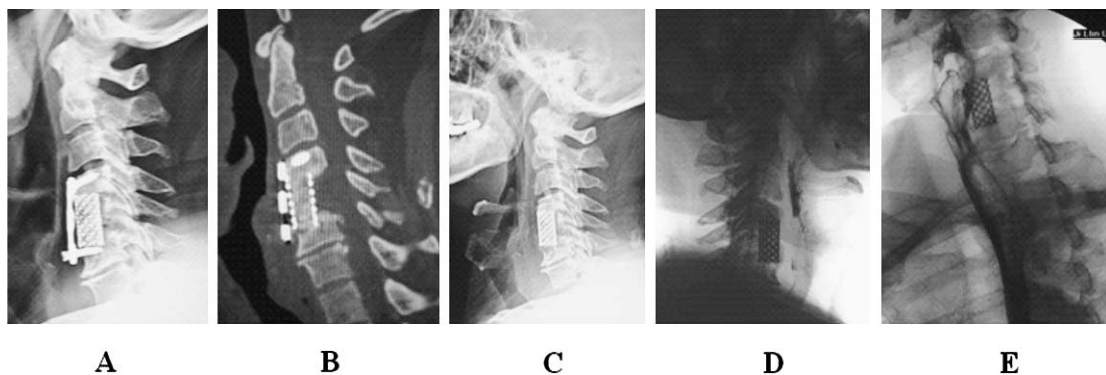


**Fig. 5** (A) Excellent position of the fixators one month after surgery. (B) Screw extrusion 2 months after surgery. (C) No further extrusion in the third month. (D) Granulated bone united with the inferior endplate of C4 and the superior endplate of C6, just 5 months after the operation.

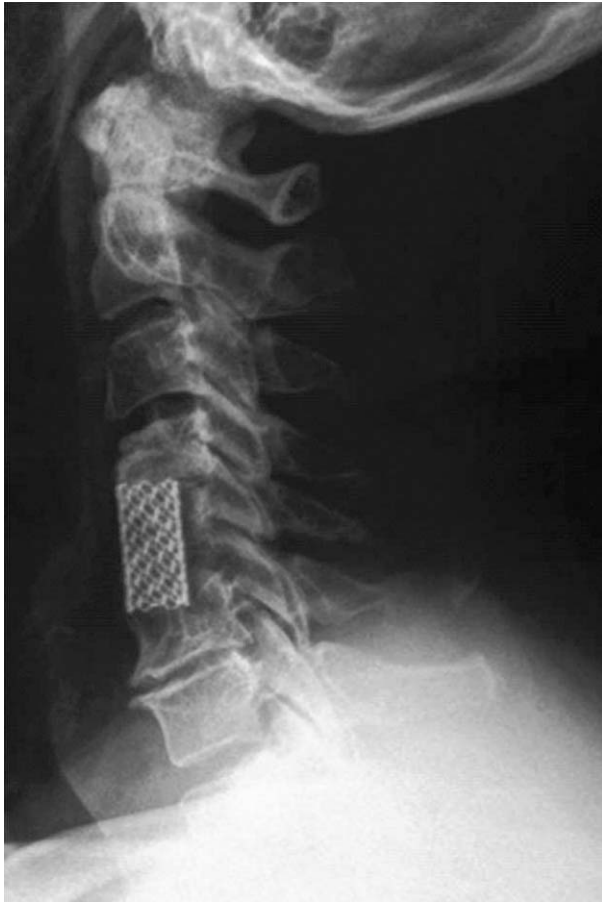identical procedure used with other patients, and the drainage tube was placed into the incision in a routine manner. There was no obvious bleeding after decompression.

However, 4 hours after the operation, paralysis of the limbs occurred in this patient. The MRI showed large-scale hematoma anterior to the dural sac, and emergency surgery was soon performed. When the hematoma was clear, it was found that effused blood clotted quickly, which made drainage difficult and was also a primary cause of hematoma. The reason for the quick solidification remains unknown. After the hematoma was cleared, to immediately drain the blood and avoid further hematoma, a drainage tube was put on the surface of the hard die. The next morning, nerve function was restored to the preoperative level.

Casha and Fehlings<sup>25</sup> reported 195 cases of anterior cervical fixation with steel plate and screws. The failure rate of internal fixation was 10.4%, and among the patients for whom fixation had failed, 2.1% suffered severe consequences and required a second surgery. Much has been reported regarding the extrusion and translocation of anterior cervical fixation devices, which may lead to esophageal damage. If the fixator has totally prolapsed, it can be removed via the mouth or gastrointestinal tract. Hitchon *et al*<sup>26</sup> and some others concluded through biomechanical studies that the length of the screw and the mineral density of the spine had a significant influence on the withdrawal force of the screw. In our case, the screw prolapsed and we put in a new screw of the same diameter into the same path, and the strength was not sufficient. Of the 2



**Fig. 6** (A) Lateral X-ray image 6 months after surgery. (B) CT scan showed that the granulated bone was well united with endplates six months after surgery. (C) X-ray image after removal of the steel plate showing the feeding tube clearly. (D, E) Barium swallow radiography 2 weeks after the start of tube feeding; there was no leakage of barium.



**Fig. 7** X-ray radiography showed excellent position of the titanium mesh 1 year after repairing of the esophagus.

ways to compensate for insufficient strength, one is to change the length of the steel plate so that the position of screw fixation changes accordingly, i.e., fix the screw in a place with high-density cancellous bone to enhance the antiwithdrawal force. The other method is to replace with thicker, longer screws to increase the strength of fixation.

The most common complication of anterior cervical discectomy is esophageal injuries.<sup>1,3-5</sup> The incidence of esophageal damage is low, but if treated inappropriately can result in severe consequences. It has been reported that the main reason for esophageal injuries is the extrusion of grafting bone and the internal fixator.<sup>1,3,4,7,8</sup> The incidence of esophageal injury is clearly higher in instrumented cases of corpectomy,<sup>9,10</sup> in which the complication rate rises from 11% to 27%. Such complications have included temporary dysphagia, temporary L5 nerve root syndrome, translocation of the steel plate and screws, and extrusion of the screws.<sup>11</sup> Usually

esophageal perforation is caused by dislocation of the internal fixator or the grafting bone, which can happen to patients with good fixation of the internal devices; pressure necrosis of the esophagus can be caused by slight friction or tiny trauma.<sup>12,13</sup> Cadaveric studies performed by Tortolani *et al*<sup>14</sup> showed that grafting the steel plate at anterior C5–C6 generates more pressure on the esophagus than grafting at anterior C3–C4. Furthermore, the more caudal the plate, the higher the incidence of dysphagia.<sup>14</sup> There are also reports that at the C6 segment the layers of the pyriform sinuses are comparatively weak, and this is responsible for the high rate of esophageal injury.<sup>4</sup> In our case, we performed C5 corpectomy and esophageal perforation was caused by extrusion of the screw, which rubbed the layers of the esophagus. This led to pressure necrosis, which finally developed into esophageal perforation.

Treatment for esophageal perforation has been dramatically controversial. If there are no complications such as pain, cellulitis, septicemia, or abscess, and no internal fixators, conservative management includes local drainage, parenteral administration of antibiotics, and tube feeding.<sup>15,16</sup> However, most cases require surgical repairing of the esophagus with local suture and packing suture with muscle flats, local debridement and drainage, and removal of internal fixators.<sup>17</sup> In our case, with an extruded screw, the preoperative evaluation determined that taking out the screw may damage the esophagus. However, during the operation it was found that the screw had already pierced all the layers of the esophagus, although there was no food effusing and no obvious inflammatory reaction. Because there was scar tissue separating the titanium mesh and the esophagus, we did not take out the titanium mesh. The thoracic surgeon sutured the esophageal layers one by one. The patient was tube fed for 2 weeks after the operation, and then ate normally. One-year follow-up found no relapse.

The first complication in this case was intraspinal hematoma, and if there had been no hematoma, the subsequent complications may not have happened. When clearing the hematoma, if the plate had been changed during the same procedure then the screw placement would also have been changed accordingly, or the screws would have been changed out for those of greater diameter. In that case, the screw would not have extruded, and there would have been no esophageal injury. Thus the complications led one to another in a chain reaction, and the details of each warrant particular attention.

## Key Points

- (1) A patient who had received anterior cervical surgery experienced a series of complications.
- (2) After postoperative clearance of intraspinal hematoma, the steel plate or screws should be changed to reinforce the fixators and avoid extrusion or other complications.
- (3) Esophageal injury due to screw extrusion tends to easily heal after repair.

## References

1. Zavery GR, Ford M. Cervical spondylosis: the role of anterior instrumentation after decompression and fusion. *J Spinal Disord* 2001;**14**(1):14–16
2. Song KJ, Lee KB, Song JH. Efficacy of multilevel anterior cervical discectomy and fusion versus corpectomy and fusion for multilevel cervical spondylotic myelopathy: a minimum 5-year follow-up study. *Eur Spine J* 2012;**21**(8):1551–1557
3. Gaudinez RF, English GM, Gebhard JS, Brugman JL, Donaldson DH, Brown CW. Esophageal perforations after anterior cervical surgery. *J Spinal Disord* 2000;**13**(1):77–84
4. Orlando ER, Caroli E, Ferrante L. Management of the cervical esophagus and hypopharynx perforations complicating anterior spine surgery. *Spine* 2003;**28**(15):E290–295
5. Patel NP, Wolcott WP, Johnson JP, Cambron H, Lewin M, McBride D *et al.* Esophageal injury associated with anterior cervical spine surgery. *Surg Neurol* 2008;**69**(1):20–24
6. Sharma RR, Sethu AU, Lad SD, Turel KE, Pawar SJ. Pharyngeal perforation and spontaneous extrusion of cervical graft with its fixation device: a late complication of C2–C3 fusion via anterior approach. *J Clin Neurosci* 2001;**8**(5):464–468
7. Yee GH, Terry AF. Esophageal penetration by an anterior cervical fixation device. *Spine* 1993;**18**(4):522–527
8. Smith MD, Bolesta MJ. Esophageal perforation after anterior cervical plate fixation: a report of two cases. *J Spinal Disord* 1992;**5**(3):357–362
9. Halligan M, Hubschmann OR. Short-term and long-term failures of anterior polymethylmethacrylate construct with esophageal perforation. *Spine* 1993;**18**(6):759–761
10. Riew KD, Sethi NS, Devney J, Goette K, Choi K. Complications of buttress plate stabilization of cervical corpectomy. *Spine* 1999;**24**(22):2404–2410
11. Ozgen S, Naderi S, Ozek MM, Pamir MN. A retrospective review of cervical corpectomy: indications, complications and outcome. *Acta Neurochir (Wien.)* 2004;**146**(10):1099–1105, discussion 1105.
12. Newhouse KE, Lindsey RW, Clark CR, Lieponis J, Murphy MJ. Esophageal perforation following anterior cervical spine surgery. *Spine* 1989;**14**(10):1051–1053
13. Witwer BP, Resnick DK. Delayed esophageal injury without instrumentation failure: complication of anterior cervical instrumentation. *Spine* 2003;**16**(6):519–523
14. Tortolani PJ, Cunningham BW, Vigna F, Hu N, Zorn CM, McAfee PC. A comparison of retraction pressure during anterior cervical plate surgery and cervical disc replacement: a cadaveric study. *J Spine Disord Tech* 2006;**19**(5):312–317
15. Konstantakos AK, Temes RT. Delayed esophageal perforation: a complication of anterior cervical spine fixation. *Ann Thorac Surg* 2005;**80**(1):349
16. Woolley SL, Smith DR. Pharyngeal perforation: a late complication of cervical spine surgery. *J Laryngol Otol* 2005;**119**(11):913–916
17. Vrouenraets BC, Been HD, Brouwer-Mladin R, Bruno M, van Lanschot JJ. Esophageal perforation associated with cervical spine surgery: report of two cases and review of the literature. *Dig Surg* 2004;**21**(3):246–249
18. Hans P, Delleuze PP, Born JD, Bonhomme V. Epidural hematoma after cervical spine surgery. *J Neurosurg Anesthesiol* 2003;**15**(3):282–285
19. Palumbo MA, Aidlen JP, Daniels AH, Thakur NA, Caiati J. Airway compromise due to wound hematoma following anterior cervical spine surgery. *Open Orthop J* 2012;**6**:108–113
20. Keller A, von Ammon K, Klaiber R, Waespe W. Spondylogenic cervical myelopathy: conservative and surgical therapy. *Schweiz Med Wochenschr* 1993;**123**(36):1682–1691
21. Jankowski R, Zukiel R, Nowak S. Acute cervical epidural hematoma as a complication of anterior cervical C5–C6 discectomy. A case report. *Neurol Neurochir Pol* 2003;**37**(4):955–962
22. Aono H, Ohwada T, Hosono N, Tobimatsu H, Ariga K, Fujii T *et al.* Incidence of postoperative symptomatic epidural hematoma in spinal decompression surgery. *J Neurosurg Spine* 2011;**15**(2):202–205
23. Amiri AR, Fouyas IP, Cro S, Casey AT. Postoperative spinal epidural hematoma (SEH): incidence, risk factors, onset, and management. *Spine J* 2013;**13**(2):134–140
24. Jang JW, Lee JK, Seo BR, Kim SH. Spontaneous resolution of tetraparesis because of postoperative cervical epidural hematoma. *Spine J* 2010;**10**(12):e1–5
25. Casha S, Fehlings MG. Clinical and radiological evaluation of the Codman semiconstrained load-sharing anterior cervical plate: prospective multicenter trial and independent blinded evaluation of outcome. *J Neurosurg* 2003;**99**(3 Suppl):264–270
26. Hitchon PW, Brenton MD, Coopes JK, From AM, Torner JC. Factors affecting the pullout strength of self-drilling and self-tapping anterior cervical screws. *Spine* 2003;**28**(1):9–13