

The Success of Surgery in the First 24 Hours in Patients with Esophageal Perforation

Özofagus Perforasyonlarında İlk 24 Saat İçinde Yapılan Cerrahi Müdahalenin Başarısı

Ahmet Sami Bayram, Mehmet Muharrem Erol, Huseyin Melek, Mehmet Ali Colak, Tayfun Kermenli, Cengiz Gebitekin

Department of Thoracic Surgery, Uludag University Faculty of Medicine, Bursa, Turkey

Abstract

Objective: Esophageal perforation (EP) is a critical and potentially life-threatening condition with considerable rates of morbidity and mortality. Despite many advances in thoracic surgery, the management of patients with EP is still controversial.

Materials and Methods: We retrospectively reviewed 34 patients treated for EP, 62% male, mean age 53.9 years. Sixty-two percent of the EPs were iatrogenic. Spontaneous and traumatic EP rates were 26% and 6%, respectively. Three patients had EP in the cervical esophagus and 31 in the thoracic esophagus.

Results: Mean time to initial treatment was 34.2 hours. Twenty patients comprised the early group (<24 h) and 14 patients the late group (>24 h). Management of the EP included primary closure in 30 patients, non-surgical treatment in two, stent in one and resection in one. Mortality occurred in nine of the 34 patients (26%). Mortality was EP-related in four patients. Three of the nine patients that died were in the early group ($p<0.05$). Mean hospital stay was 13.4 days.

Conclusion: EP remains a potentially fatal condition and requires early diagnosis and accurate treatment to prevent the morbidity and mortality.

Keywords: Esophageal perforation, emergency treatment, thoracic surgery

Özet

Amaç: Özofagus perforasyonları (ÖP) kritik, hayatı tehdit eden mortalite ve morbidite riski yüksek olgulardır. Göğüs Cerrahisi'ndeki tüm gelişmelere rağmen bu olgulara yaklaşım günümüzde de tartışmalıdır.

Gereç ve Yöntem: ÖP nedeniyle tedavi ettiğimiz 34 hastayı retrospektif olarak değerlendirdik. Erkek hastalar tüm hastaların %62' sini oluşturmaktaydı. Ortalama yaş: 53,9 olarak saptandı. Tüm perforasyonların %62'si iatrojenik nedenlerden kaynaklanmaktaydı. Spontan ve travmatik perforasyon oranları sırasıyla %26 ve %6 olarak hesaplandı. 3 Hastada boyunda, 31 hastada ise torasik özofagusda perforasyon saptandı.

Bulgular: Tedavinin ortalama başlama süresi 34, 2 saattir. 20 hasta erken grup içindeydi (<24 saat), 14 hasta ise geç grup (>24 saat) olarak sınıflandırıldı. Cerrahi olarak; 30 hastada primer onarım, 1 hastada özofagus rezeksiyon ve anastomoz, 1 hastada stent ve 2 hastada medikal tedavi uygulandı. Mortalite 9 hastada gelişti %26. Mortalite nedeni 4 hastada ÖP'a sekonderdi. 9 Hastanın 3' ü erken tedavi grubundaydı ($p<0,05$). Ortalama hastanede yatış süresi 13,4 gündü.

Sonuç: ÖP potansiyel ölümcül sonuçlar doğurabileceğinden morbidite ve mortaliteyi azaltmak için erken tanı ve etkili tedavi gereklidir.

Anahtar Kelimeler: Özofagus perforasyonu, acil tedavi, göğüs cerrahisi

Introduction

Since esophageal perforation (EP) was originally described more than 50 years ago, the diagnosis has been challenging, its management is controversial and mortality is high [1]. The clinical course of EP essentially depends on the location and the extent of the injury as well as the time elapsing between the perforation and the start of the treatment [2]. Primary surgical repair is the treatment of choice in early diagnosed EP. Surgical treatment of old or recurrent EP, however, is associated with local and systemic sepsis, which is often accompanied by significant morbidity and mortality [3]. Despite the use of broad spectrum antibiotics and improved nutritional support, the mortality rate in

EP is more than 20% [4]. The aim of this report is to review the diagnostic examination, treatment and outcomes of 34 patients with EP.

Materials and Methods

Written informed consent was obtained from the patients. Thirty-four patients (n=34) with EP were evaluated in this study. These were retrospectively reviewed on the basis of age, gender, primary disease, etiology, perforation site, diagnostic methods, time to presentation, specific treatment methods, morbidity, mortality, survival and the cause of death. They were then divided into early (n=20) and late (n=14) groups (Tables 1 and 2).

Received: March 27, 2014 / **Accepted:** June 27, 2014 / **Available Online Date:** December 5, 2014

Correspondence to: M. Muharrem Erol, Department of Thoracic Surgery, Uludag University Faculty of Medicine, Bursa, Turkey
Phone: +90 506 535 06 30 e-mail: muharremrol@hotmail.com

©Copyright 2015 by the Atatürk University School of Medicine - Available online at www.eajm.org

DOI:10.5152/eajm.2014.55



Table 1. Profile of the patients with esophageal perforation (early group)

No	Gender	Age	Primary disease	Aetiology	Localization	Time (h)*	Management	Complication	Re-operation	Survival	Reason of Exitus
1	F	30	Acalasia	Iatrogenic-Dilatation	Thoracic	23	Primary closure	Leakage	Primary closure+icf	Yes	
2	F	50	Esophageal stricture	Iatrogenic-Dilatation	Thoracic	6	Primary closure			Yes	
3	F	53	Foreign body exclusion (meat)	Iatrogenic-Endoscopy	Thoracic	1	Primary closure			Yes	
4	F	36	Sarcoma, compress of esophagus	Iatrogenic-Stent	Thoracic	2	Primary closure			No	Primary disease-Po 6 th days
5	M	44	Esophageal stricture	Iatrogenic-Dilatation	Thoracic	1	Conservative			Yes	
6	M	66	Inoperable lung cancer, compress of esophagus	Iatrogenic-Stent	Thoracic	1	Primary closure+pf			No	Primary disease-Po 5 th days
7	F	72		Boerhaave	Thoracic	22	Primary closure+pf			Yes	
8	F	65		Boerhaave	Thoracic	4	Primary closure			Yes	
9	M	58		Boerhaave	Thoracic	13	Primary closure	Sepsis		No	Septic shock-Po 5 th days
10	M	71		Boerhaave	Thoracic	11	Primary closure			Yes	
11	M	49		Boerhaave	Thoracic	9	Primary closure	Emphysema-Tube thoracostomy		Yes	
12	M	52	Inoperable lung cancer, compress of esophagus	Iatrogenic-Stent	Thoracic	2	Conservative			Yes	
13	M	24	Corrosive intake, Esophageal stricture	Iatrogenic-Dilatation	Thoracic	7	Primary closure+icf	Abscess	Abscess drainage	Yes	
14	F	62	Foreign body exclusion (chicken bone)	Iatrogenic-Endoscopy	Thoracic	1	Primary closure			Yes	
15	M	53	Foreign body exclusion (meat)	Iatrogenic-Endoscopy	Thoracic	8	Primary closure			Yes	
16	E	58	Inoperable lung cancer, compress of esophagus	Iatrogenic-Stent	Thoracic	10	Primary closure			Yes	
17	M	28		Trauma-GSW	Cervical	1	Primary closure			Yes	
18	F	38		Iatrogenic-Dilatation	Thoracic	16	Primary closure			Yes	
19	K	62		Iatrogenic-Dilatation	Thoracic	12	Primary closure			Yes	
20	K	54	Corrosive intake, Esophageal stricture	Iatrogenic-Dilatation	Thoracic	12	Primary closure	Leakage	Resection+ Cervical esophagog-astrostomy	Yes	

*Perforation to operation; GSW: gun shot wound; pf: pleural flap; icf: intercostal flap; df: diaphragmatic flap; Po: postoperative

Table 2. Profile of patients with esophageal perforation (late group)

No	Gender	Age	Primary disease	Aetiology	Localization	Time*	Management	Complication	Re-operation	Survival	Reason of Exitus
21	E	73		Boerhave	Thoracic	7 th days	Primary closure	Leakage	Primary closure+icf	No	Electrolyte imbalance-Po 45 th days
22	M	72	Esophageal disease	Iatrogenic-Endoscopy	Thoracic	60h	Primary closure+icf	sepsis		No	Septic shock-Po 5 th days
23	M	56	Inoperable larynx cancer	Iatrogenic-Dilatation	Cervical	4 th days	Primary closure	DNM	Mediastinal drainage	No	Septic shock-Po 38 th days
24	M	46		Boerhave	Thoracic	26h	Exclusion-Diversion/Resection	Sepsis, respiratory failure		No	Innominate artery-tracheal fistula-Po 60 th days
25	F	48	Esophageal disease	Iatrogenic-Endoscopy	Cervical	48h	Primary closure	Abscess	Abscess drainage	Yes	
26	M	40		Trauma-GSW	Thoracic	7 th days	Primary closure+icf (Figure 1)			Yes	
27	F	72	Esophageal disease	Iatrogenic-Endoscopy	Thoracic	36h	Primary closure+df			Yes	
28	M	10		Foreign body	Thoracic	36h	Primary closure			Yes	
29	F	48		Foreign body	Thoracic	4 th days	Primary closure			Yes	
30	M	52		Iatrogenic-NG tube	Thoracic	48h	Primary closure	Leakage	Primary closure+icf (Figure 2)	No	Septic shock-Po 7 th days
31	M	60	Inoperable lung cancer, compress of esophagus	Iatrogenic-Stent	Thoracic	3 th days	Stent			No	Primary disease-Po 2 th days
32	M	56		Boerhave	Thoracic	36h	Primary closure+icf	Leakage	Primary closure+df	Yes	
33	M	48		Boerhave	Thoracic	26h	Primary closure			Yes	
34	M	42	Operated with laparoscopic nissen fundoplication	Iatrogenic	Thoracic	72h	Primary closure+df	Abscess	Re-thoracotomy, drainage	Yes	

*Perforation to operation; GSW: gun shot wound; pf: pleural flap; icf: intercostal flap; df: diaphragmatic flap; Po: postoperative

Statistical Analysis

Fischer's exact test (Copyright IBM Corp. 1989, 2011) was used to compare the mortality rates of the early and late groups.

Results

Twenty-one (62%) patients were male. Mean age of patients was 53.9 (10-73) years.

Aetiology of the EP was iatrogenic in 21 (62%) patients, Boerhaave's syndrome in 9 (26%), trauma in 2

(6%) and foreign body in 2 (6%) of the patients, respectively (Table 3).

Esophageal perforation was located in the cervical esophagus in 3 patients (9%) and in the thoracic esophagus in 31 (91%). The interval between the rupture and initial treatment ranged from 1 to 148 h (mean 32.9 h). Twenty patients comprised the early group (<24 h) (1 to 23 h, mean 8.1 h) and 14 the late group (>24 h) (26 to 148 h, mean 75.8 h). Table 4 shows the characteristics of the patients in the early and late groups.

Pain was the most common symptom in 20 of the 34 patients (59%). Other symptoms included dyspnoea in 14 patients (41%), dysphagia in 12 (35%) and fever in 6 (18%). Subcutaneous emphysema was recorded in 7 patients (21%).

Esophageal perforation was diagnosed using contrast computerized tomography (CT) in 17 patients and esophagography in 10. Subcutaneous emphysema was detected in chest x-rays of 3 patients and during endoscopy in 4.

Primary closure was performed in 30 patients. Two patients received non-surgical treatment, while stenting was performed in one patient and resection in another. Eight patients were supported with flap following the primary closure, 4 with intercostal muscle, 2 with parietal pleura and 2 with diaphragm. All patients received antibiotic therapy and fluid resuscitation. The mainstay of a non-operative treatment was broad spectrum antibiotics, hyperalimentation and nasogastric suction.

We re-operated on 8 (3 in the early group) of the 30 patients: 4 had leakage (one patient in the early group. All

were closed primarily. Three were supported with intercostal flap and one with diaphragm), 2 had abscess (one cervical and one thoracic perforation in the early group) and one had mediastinal abscess drainage (cervical perforation). Tube thoracostomy was performed on one patient in the early group to treat empyema.

Complications occurred in 11 patients (4 in the early group) (32%), in the form of leakage in 4 patients, sepsis in 3 (one patient had respiratory failure), abscess in 2, descending necrotizing mediastinitis in one patient and empyema in one. Overall mortality in the 34 patients was 26% (nine patients). Four of these died due to EP. One patient (aged 73) died on the 45th day postoperatively due to electrolyte imbalance, 3 patients died from primary disease (2 from inoperable lung cancer, one from sarcoma) and one died from tracheo-innominate artery fistula on the 60th day postoperatively (this patient received a tracheostomy tube). A significant difference was determined between the mortality rates of the patients in the early (<24 h) and late (>24 h) groups ($p<0.05$).

Mean hospital stay was 13.4 days (range 6-40). When discharged, all patients were thought to have a normal diet without dysphasia.

Table 3. Etiological factors determined

Aetiology	No	%
I. Iatrogenic	21	62
Dilatation	9	
Esophagoscopy	6	
Placement of stent	5	
Nasogastric tube replacement	1	
II. Boerhaave's syndrome	9	26
III. Foreign bodies	2	6
IV. Trauma	2	6

Discussion

Esophageal perforation still represents a diagnostic and therapeutic challenge in spite of the increased clinical experience and innovations in surgical technique. Signs of EP have been described previously in the literature [1]. Although EP was first described by Boerhaave in 1724, the first successful surgical repair was reported by Barrett in 1947 [1, 3].

Iatrogenic perforations are the most common cause of EP. These most commonly result from endoscopic manipulation

Table 4. Characteristics of early group and late group patients

	n	Early Group (<24h)					Late Group (>24h)				
		morbidity		mortality			morbidity		mortality		
		n	n	%	n*	%	n	n	%	n*	%
Location											
Cervical	3	1	-	-	-	-	2	2	100	1	50
Thoracic	31	20	5	24	2	18	11	6	50	5	50
Treatment											
Primary Repair	22	15	4	23	2	15	7	4	67	3	50
Primary Repair + Reinforced	8	3	1	33	1	33	5	3	50	1	25
Stent		-	-	-	-	-	1	-	-	1	100
Resection	1	-	-	-	-	-	1	1	100	1	100
Conservative	2	2	-	-	-	-	-	-	-	-	-

* $p<0.05$

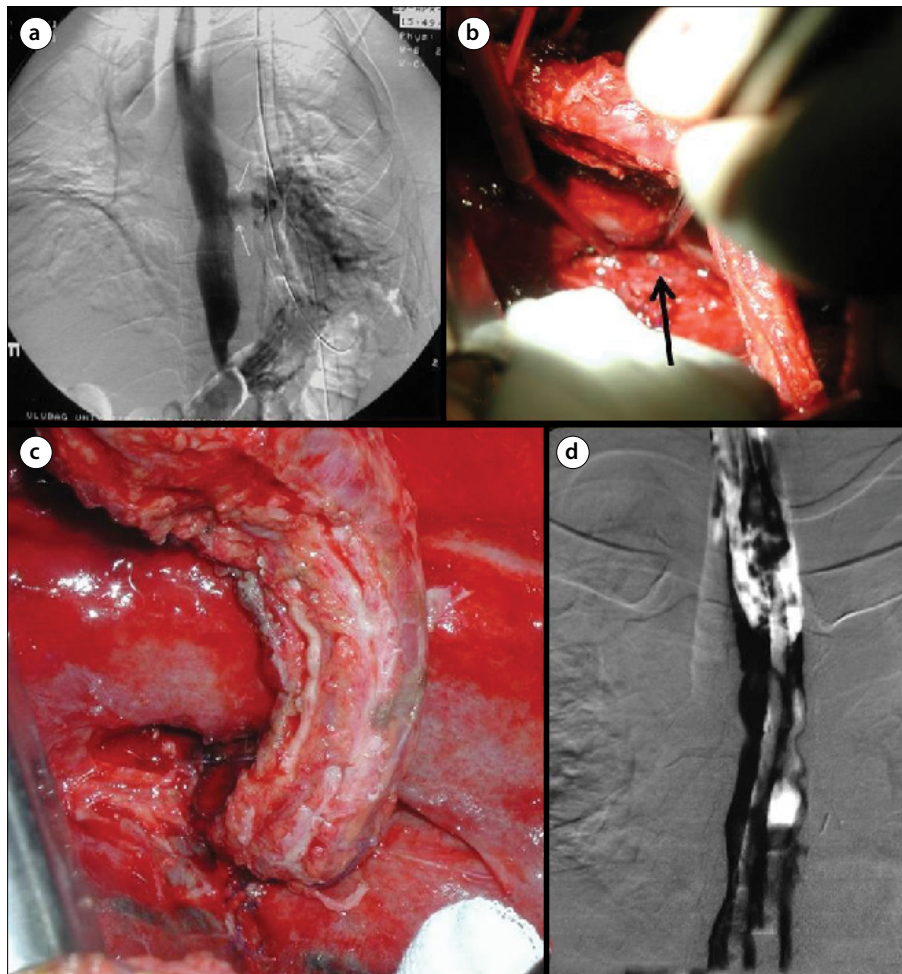


Figure 1. a-d. Photographs of a patient (Number 25). Esophageal perforation at esophagography (a), site of perforation (black arrow shows perforation area) (b), intercostal muscle flap (c), postoperative esophagography (d).

or dilatations or as a complication of paraesophageal surgery, and account for up to 75% of published cases [3, 5-7]. In our series too, iatrogenic causes were the most important factor in EP, at a rate of 62%.

Cervical perforation of the esophagus is generally less severe and more easily treated than intrathoracic or intra-abdominal perforation. Intrathoracic perforations cause rapid contamination of the mediastinum [1]. Cervical perforation was encountered in 3 patients (9%) in our series.

Diagnosis of EP can be difficult, as the presentation is often non-specific and mimics other disorders, such as spontaneous pneumothorax, myocardial infarction, aortic dissection, peptic ulcer, pancreatitis and pneumonia. The symptoms of EP vary depending on the location, primary cause and time of rupture [1, 7, 8]. Common clinical manifestations of EP include chest pain, dysphagia, dyspnoea, subcutaneous emphysema,

epigastric pain, fever, tachycardia and tachypnea. If pain and subcutaneous emphysema develop following the surgical instrumentation, perforation should be suspected. Pain has been emphasized as the most common symptom in EP [1, 7], and was observed at a level of 59% in our series.

Diagnosis can be confirmed using contrast radiography, computed tomography (CT) scans or endoscopy [7]. Contrast esophagography remains as the standard method of evaluation in the diagnosis of EP. CT is essential if the location of EP cannot be determined by contrast esophagography [1]. In this study, contrast CT and esophagography facilitated the diagnosis of EP in 25 patients.

Intrathoracic EP represents a formidable challenge for thoracic surgeons. EP in intrathoracic esophagus leads to extravasation of oral secretions and intraluminal bacteria as well as gastric contents being refluxed into the mediastinum.

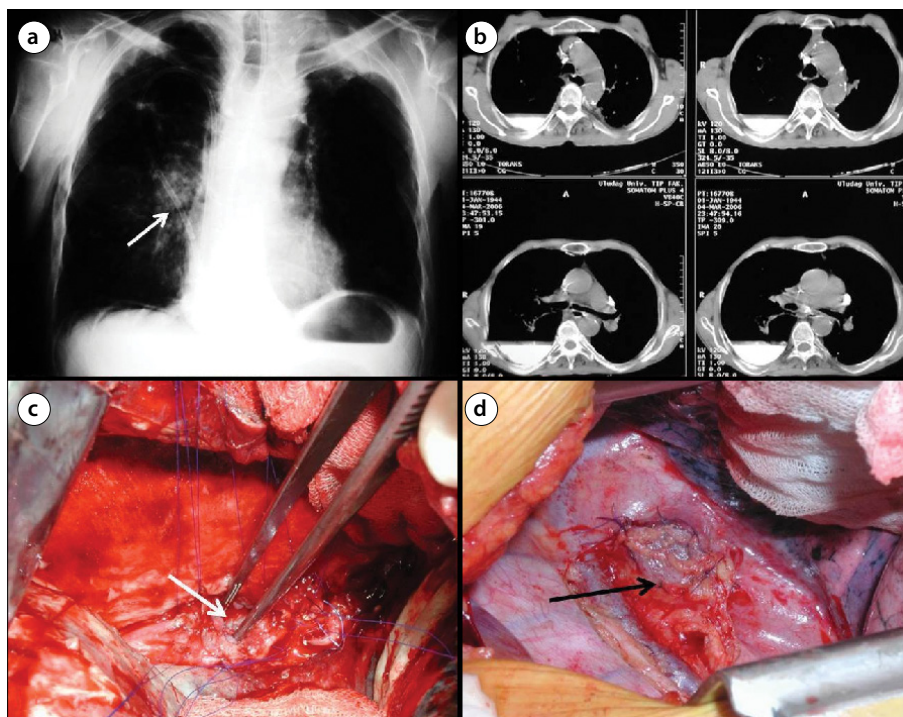


Figure 2. a-d. Photographs of a patient (Number 27). NG in right hemithorax at PA imaging (white arrow (a)), perforation at CT with oral contrast (b), site of perforation (white arrow shows perforation area (c), parietal flap (black arrow shows flap) (d).

A mixture of digestive enzymes and bacteria covers the mediastinal tissue and leads to fulminant and rapidly progressing infections that are usually fatal. Delayed diagnosis and treatment of EP are associated with increased morbidity and mortality [9, 10].

Esophageal perforations [11] occurring within 24 h before or after the admission are regarded as early and late, respectively [4]. The reported mortality for treated EP is 10% to 25% when treatment is initiated within 24 h of perforation [12]. If treatment is delayed or started after 24 h, however, mortality increases (33-66%) [5, 11]. Nineteen of our 34 patients constituted the early group and 15 the late group. Three patients (16%) in the early group and 6 patients (54%) in the late group died, which is a significant difference.

Treatment of EP is aimed at preventing further spoilage of the EP, control and elimination of the infection, restoration and continuity of the gastrointestinal tract and maintenance of adequate nutrition [1, 3]. Surgery is still, however, the "gold standard." Various surgical procedures have been described, including the primary repair, reinforced repair, debridement, drainage and esophageal resection with simultaneous or staged (after exclusion and diversion) reconstruction [10]. Nonviable tissues are the primary factor in the success of meticulous repair of the mucosal and muscular layers sepa-

rately [12]. The problem of persistent leakage and deterioration of the primary repair site led to the development of reinforced primary repair, in which tissue grafts are implanted to bolster the repair site [1]. The tissues used for the reinforcement of the primary repair include free pericardial patch grafts, vascular pedicled flaps (pleura, diaphragm, intercostal muscle, gastric fundus and rhomboid and latissimus dorsi muscles). Sternothyroid and sternocleidomastoid muscles are also used for cervical perforation [1, 13, 14].

Conservative treatment of EP remains as a controversial topic. Non-operative management of EP is appropriate in the selected patients with well-contained perforations, intramural perforations, benign defects, absence of sepsis and minimal mediastinal and pleural contamination. This therapy involves a total prohibition of oral food intake for a minimum of 7 days, administration of broad spectrum antibiotics and parenteral hyperalimentation [14, 16-19, 20]. In our series, 2 patients received conservative treatment [14-20]. Broad spectrum antibiotic therapy, prohibition of oral food intake for 5 days and parenteral hyperalimentation were applied in these cases [15]. Patients were monitored using contrast CT on the 5th day and discharged on the 6th day.

In conclusion, EP is a rarely encountered and challenging condition requiring early diagnosis and accurate treatment

to prevent morbidity and mortality [20]. Our experience suggests that early diagnosis and primary repair of EP should be urgently applied in order to achieve favourable postoperative results.

Ethics Committee Approval: Study was performed with our Medical School Ethics Committee's permission number 2008-17/24.

Informed Consent: Written informed consent was obtained from the patients who participated in this study.

Peer-review: Externally peer-reviewed.

Author Contributions: Concept - S.B., M.M.E., H.E.; Design - M.M.E.; Supervision - M.A.Ç., T.K.; Funding - C.G.; Materials - M.A.Ç., T.K., S.B., T.K.; Data Collection and/or Processing - M.M.E., S.B.; Analysis and/or Interpretation - C.G.; Literature Review - A.S.B., M.M.E.; Writing - A.S.B., M.M.E., M-H.E.; Critical Review - A.S.B., H.E.

Conflict of Interest: No conflict of interest was declared by the authors.

Financial Disclosure: The authors declared that this study has received no financial support.

References

1. Brinster CJ, Singhal S, Lee L, et al. Evolving options in the management of esophageal perforation. *Ann Thorac Surg* 2004; 77: 1475-83.
2. Fernandez FF, Richter A, Freudenberg S, et al. Treatment of endoscopic esophageal perforation. *Surg Endosc* 1999; 13: 962-6.
3. Mumtaz H, Barone GW, Ketel BL, et al. Successful management of a nonmalignant esophageal perforation with a coated stent. *Ann Thorac Surg* 2002; 74: 1233-5.
4. Okten I, Cangir AK, Ozdemir N, et al. Management of esophageal perforation. *Surg Today* 2001; 31: 36-9.
5. Salo JA, Savola JK, Toikkanen VJ, et al. Successful Treatment of mediastinal gas gangrene due to esophageal perforation. *Ann Thorac Surg* 2000; 70: 2143-5.
6. Muir AD, White J, McGuigan JA, et al. Treatment and outcomes of oesophageal perforation in a tertiary referral centre. *Eur J Cardiothorac Surg* 2003; 23: 799-804.
7. Eroğlu A, Kürkçüoğlu I, Karaoglanoglu N, et al. Esophageal perforation: the importance of early diagnosis and primary repair. *Dis Esophagus* 2004; 17: 91-4.
8. Port JL, Kent MS, Korst RJ, et al. Thoracic esophageal perforations: a decade of experience. *Ann Thorac Surg* 2003; 75: 1071-4.
9. Iannettoni MD, Vlessis AA, Whyte RI, et al. Functional outcome after surgical treatment of esophageal perforation. *Ann Thorac Surg* 1997; 64: 1606-9.
10. Fischer A, Thomusch O, Benz S, et al. Nonoperative treatment of 15 benign esophageal perforations with self-expandable covered metal stents. *Ann Thorac Surg* 2006; 81: 467-72.
11. Mason GR. Esophageal perforations, anastomotic leaks, and strictures: the role of prostheses. *Am J Surg* 2001; 181: 195-7.
12. Gupta NM, Kaman L. Personal management of 57 consecutive patients with esophageal perforation. *Am J Surg*. 2004; 187: 58-63.
13. Sung SW, Park JJ, Kim YT, et al. Surgery in thoracic esophageal perforation: primary repair is feasible. *Dis Esophagus* 2002; 15: 204-9.
14. Erol MM, Ural A, Melek H, et al. Gebitekin C. Descending necrotizing mediastinitis: increased mortality due to delayed presentation. *Turk J Med Sci* 2012; 42: 1437-42.
15. Cameron JL, Kieffer RF, Hendrix TR, et al. Selective nonoperative management of contained intrathoracic esophageal disruptions. *Ann Thorac Surg* 1979; 27: 404-8.
16. Altorjay A, Kiss J, Vörös A, et al. Nonoperative management of esophageal perforations: is it justified? *Ann Surg* 1997; 225: 415-41.
17. Huber-Lang M, Henne-Bruns D, Schmitz B, et al. Esophageal perforation: principles of diagnosis and surgical management *Surg Today* 2006; 36: 332-4.
18. Turkyılmaz A, Eroglu A, Aydın Y, et al. The Management of Esophagogastric Anastomotic Leak after Esophagectomy for Esophageal Carcinoma. *Dis of the Esophagus* 2009; 22: 119-26.
19. Turkyılmaz A, Eroğlu A, Aydın Y, et al. Survival in esophageal cancer patients with hematogenous distant organ metastases. *Turk J Med Sci* 2009; 39: 415-21.
20. Eroglu A, Turkyılmaz A, Aydın Y, et al. Current management of esophageal perforation: 20 years experience. *Dis Esophagus* 2009; 22: 374-80.