

# THE PHYSIOLOGICAL RESPONSE OF THE CIRCULATORY SYSTEM TO EXPERIMENTAL ALTERATIONS

## III. THE EFFECT OF AORTIC AND PULMONIC STENOSES

BY EMILE HOLMAN AND CLAUDE S. BECK

*(Laboratory of Surgical Research, The Lakeside Hospital and the Western Reserve University School of Medicine)*

(Received for publication June 3, 1926)

### INTRODUCTION

“The heart and blood vessels place themselves in harmony with an increased volume flow of blood through them, the former by dilatation<sup>1</sup> and hypertrophy and the latter by dilatation” (1, 2). This concept was established experimentally by the production of peripheral (3) and intracardiac arteriovenous fistulae (1). In the presence of such fistulae there occurred a rapidly developing enlargement of the heart, demonstrable both by the roentgenogram and by postmortem examination. This enlargement of the heart consisted primarily of dilatation, and secondarily of hypertrophy. The enlargement was proportional to the size of the fistula, which determined the volume flow of blood through the abnormal communication and, therefore, through the heart.

The following studies were undertaken to determine the effect of altering the flow through the heart by introducing into the circulatory system a pulmonic stenosis or an aortic stenosis, and to compare the effect of such stenoses with the effect of a defect in the interventricular septum. It may be considered that the effect of such stenoses is to impede the flow of blood through the circulatory system by increasing the peripheral resistance against which the right and left ventricles perform their work while the effect of the septal defect is to increase the flow of blood through the heart.

<sup>1</sup> “Dilatation” as used here refers to an enlargement of the intracardiac cavities due to distention and not to a pathological state of the cardiac musculature.

## EXPERIMENTAL METHODS

The heart was exposed at operation under aseptic precautions. Ether anesthesia was used. Mechanical respiration was provided by the Erlanger double cylinder. Stenoses of the aorta and pulmonary artery were produced in dogs by placing around the vessel a constricting band of tape or aluminum (4). Interventricular fistulae were produced by incising the septum with a long slender knife inserted through the left ventricle.

During the period of observation the pulse rate and the presence of thrills and murmurs were noted. The volume of the circulating blood was determined by the intravenous injection of brilliant vital red. Changes in the size of the heart were determined by roentgenograms and at autopsy the heart was measured and the cardiac muscle was studied histologically.

## DISCUSSION

Certain observations in the protocols which follow may be emphasized. A stenosis which permanently constricted the pulmonary artery to a circumference less than one-half the normal size was invariably fatal. A pulmonic stenosis of marked degree was immediately followed by an acceleration in pulse rate and by a drop in general blood pressure, both of which gradually approximated normal. The recovery of blood pressure was more rapid in the presence of a pulmonic stenosis than in the presence of a large interventricular septal defect (1). The stenosis was followed immediately by a dilatation of the right ventricle (experiments 6 and 9), a dilatation which gradually subsided during the subsequent months until the heart again assumed a normal size as shown by roentgenographic studies (experiment 4). At necropsy (experiment 4) a slight thickening of the right ventricular wall was found as previously observed by Reid (5). Microscopically, the right heart showed evidence of hypertrophy definitely more marked than in the left heart. The slight effect of a pulmonic stenosis of this duration upon the size and thickness of the right ventricle was in marked contrast to the pronounced effect of a large interventricular defect of equal duration as observed in our previous study (1). The latter was followed by a conspicuous dilatation and thickening of the

wall of the right heart. There was no demonstrable increase in total blood volume after pulmonic stenosis such as developed in the presence of interventricular defects.

The production of the pulmonic stenosis resulted in a well marked systolic bruit followed by an accentuated pulmonic second sound. A thrill was felt at the time of operation limited to the vessel beyond the stenosis. It could not be felt by palpation of the chest wall, whereas the septal defect invariably produced a pronounced thrill palpable over the chest wall.

The establishment of an interventricular septal defect some days after the production of a pulmonic stenosis in the same animal resulted, when the animal survived, in a relatively much greater enlargement of the heart from the septal defect, as compared to the slight enlargement which followed the production of the pulmonic stenosis alone (experiments 10, 11 and 12). This enlargement of the heart is due almost entirely to dilatation rather than to hypertrophy. It may be inferred, therefore, that an increase volume flow through the right heart resulting from a septal defect is a more effective means of producing right sided cardiac enlargement than is the increased peripheral resistance resulting from a pulmonic stenosis.

Additional evidence was also obtained indicating that in the presence of interventricular defects there is an increased flow of blood through the pulmonary circulation and that this may be diminished by producing in the same animal a pulmonic stenosis. In experiments 10 and 11, the animals survived large septal defects when associated with a pulmonic stenosis, whereas interventricular defects of equal or of smaller size in other animals proved invariably fatal due to pulmonary congestion and edema. That this pulmonary congestion and edema which accompanies excessively large interventricular defects may be the important factor in the death of these animals was indicated by the turn of events in experiment 10 following erosion of the constricting tape through the pulmonary artery. This erosion permitted an increased flow through the pulmonary circuit producing marked congestion and edema of the lungs which proved fatal.

Aortic stenosis beyond the left subclavian artery lowered peripheral blood pressure but caused no acceleration in pulse (experiments 3 and 1). Such a stenosis not only lowered femoral pressure but increased

carotid pressure. Well marked aortic stenosis of six months' duration produced no roentgenographic increase in the size of the heart, and at necropsy there was no apparent dilatation of the heart, but a slight increase in thickness of the left ventricular wall, which microscopically showed a slight hypertrophy.

An instructive comparison may be made between experiment 1, in which an aortic stenosis of six months' duration was produced, and an experiment already published, in which a large septal defect of eight months' duration had been produced. These animals were of the same breed and weight, but at necropsy the heart of the former animal weighed 165 grams, whereas the heart of the latter animal weighed 226 grams. It is quite evident that the septal defect with its resulting increased flow of blood through the heart produced a much greater hypertrophy of the cardiac muscle than did an aortic stenosis sufficient to cause a permanent lowering of the peripheral femoral pressure. We may infer, therefore, that *an increased flow of blood through the heart is a more effective stimulus to cardiac dilatation and hypertrophy than increased peripheral resistance*. The total blood volume remained relatively unchanged in the presence of an aortic stenosis. The production of an aortic stenosis was followed by a systolic bruit heard best along the left vertebral border. There was no palpable thrill.

Certain other differences may be noted in the effects produced by large interventricular septal lesions as compared to the effect of a pulmonic or aortic stenosis. In the former there were invariably microscopic and macroscopic evidences of pulmonary congestion and edema. In the latter these were not consistently observed either macroscopically or microscopically, and in most of the cases of uncomplicated pulmonic stenosis a marked emphysema was noted (experiments 6, 7 and 8). In those animals with an aortic stenosis in which a sudden exsanguination occurred through erosion of the vessel wall there was also microscopic emphysema of the lungs. Respirations were more rapid in the presence of an increased flow through the lungs as produced by interventricular defects than in the presence of a pulmonic stenosis.

It is evident also that, roentgenographically, a marked enlargement of the heart usually indicates dilatation. Hypertrophy, if it exists,

produces little evidence of its presence by the roentgenograms (experiments 1 and 4). One may infer, therefore, that any great increase in the size of the heart observed clinically is in greater part due to dilatation and in lesser degree to hypertrophy.

Partial constriction of the pulmonary artery or aorta by a metal band or tape frequently ended fatally through erosion of the vessel wall.

#### PROTOCOLS OF EXPERIMENTS

##### *Aortic stenosis*

*Experiment 1 (dog X43).* Male, weight 20 kilos. Before operation the blood pressure was 170/80, pulse rate 116, and the total blood volume 1800 cc. On March 6, 1925, the aorta was constricted to one-half its normal diameter by a broad tape at a point just beyond the left subclavian artery. A marked thrill could be felt beyond the constriction for about 10 to 12 cm. There was no thrill proximal to the tape. The pulse rate at the end of the operation was 132. A loud systolic bruit was audible along the left vertebral border posteriorly, but not elsewhere. The femoral artery was easily compressible and the blood pressure could not be recorded.

On March 7th the pulse rate was 108. The systolic pressure in the femoral artery was about 90, and the diastolic pressure could not be determined. On March 10th the pulse rate was 84, and the systolic pressure in the femoral artery was 90. On April 21st the pulse rate was 105, and the blood pressure in the right femoral artery had risen to 115/65. A total blood volume of 1940 cc. was determined. On July 18th the pulse was 114, the blood pressure in the right femoral artery was 120/60 and a blood volume of 1930 cc. was determined.

On September 4th the blood volume was 1710 cc., the pulse was 129, and the femoral blood pressure according to the Pachon apparatus was 140/60. A well marked systolic bruit was still audible along the left vertebral border. The animal was anesthetized with ether, the right femoral and right carotid arteries were cannulated and blood pressure readings were obtained with a mercury manometer. The femoral blood pressure varied with respirations from 136 to 142, corresponding well with the readings of the Pachon apparatus. Simultaneous readings of the blood pressure in the carotid artery varied with respirations from 168 to 180. Normally the femoral pressure in dogs is recorded as being higher than the carotid pressure. The lower femoral pressure in this instance is ascribed to the degree of aortic stenosis present.

The animal was killed. The heart appeared normal in size; the liver was large and weighed 830 grams; the lungs were everywhere normal and weighed 230 grams. The heart was opened; there was no dilatation of its cavities (fig.1), but the left ventricular wall appeared slightly thickened. The heart weighed 165 grams.

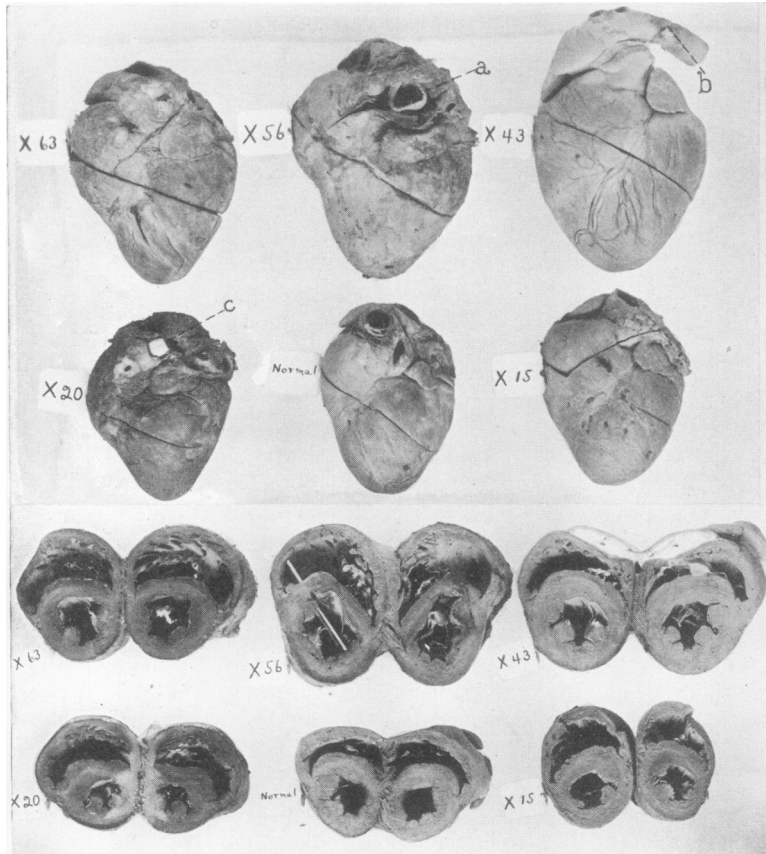


FIG. 1. HEARTS REMOVED AT NECROPSY

Experiment 9 (dog X63): Pulmonic stenosis of 35 days' duration. Slight dilatation of right ventricular cavity.

Experiment 10 (dog X56): Pulmonic stenosis of 62 days' duration and interventricular septal defect of 19 days' duration in the same animal. Constricting tape *a* eroded through wall of pulmonary artery into its lumen. Marked dilatation of both ventricular cavities.

Experiment 1 (dog X43): Aortic stenosis at *b* of 6 months' duration. No dilatation. Slight if any hypertrophy of left ventricular wall.

Experiment 4 (dog X20): Pulmonic stenosis at *c* of 6½ months' duration. Dilatation of right ventricular cavity with slight hypertrophy.

Experiment 5 (dog X15): Pulmonic stenosis of 30 days' duration showing dilatation of right ventricle.

Roentgenographic studies during life had shown no demonstrable increase in the size of the cardiac shadow.<sup>2</sup> The aorta at its emergence from the heart measured 40 mm. in circumference and at the point of stenosis 20 mm. in circumference. The pulmonary artery measured 44 mm. in circumference. There was no dilatation of the aorta either proximal or distal to the constriction.

Microscopic sections revealed slight evidence of hypertrophy in the walls of both chambers of the heart, not at all comparable with that found in the presence of interventricular septal defects.

*Experiment 2 (dog X57).* Weight 9.9 kilos. Preoperative studies revealed a pulse rate of 80 per minute and a blood pressure of 140/50 mm. On June 3, 1925, a constricting figure-of-eight tape was applied to the descending aorta just beyond the left subclavian artery. On June 8th a pulse rate of 84 and a blood pressure of 95/35 were recorded. On June 30th the animal was killed in a fight. At necropsy, the area of constriction was well healed. The heart was small, not dilated, nor were the walls thickened. The aorta admitted a 28 mm. bougie at its origin, and a 10 mm. bougie at the point of constriction. The pulmonary artery admitted a 30 mm. bougie at its origin. The lungs were everywhere air-containing and showed no areas of congestion. Microscopic sections showed some emphysema with areas also of partial atelectasis. The liver was normal.

*Experiment 3 (dog X59)* permitted some interesting observations at the original operation. The carotid and femoral arteries were cannulated and connected with mercurial manometers. Complete occlusion of the descending aorta resulted in a fall in femoral pressure from 120 to 0 and rise in carotid pressure from 140 to 174. After only partial occlusion of the aorta there was an immediate rise in carotid pressure which soon subsided. The partial constriction resulted in a slight permanent fall in femoral pressure. The death of the animal prevented subsequent observation.

In *experiment 1 (dog X43)* similar manometric studies were made just before death, six months after the production of an aortic stenosis, and there was still a slight lowering of the femoral pressure as compared to the carotid pressure.

#### *Pulmonic stenosis*

*Experiment 4 (dog X20).* Weight 11.3 kilos. On November 4, 1924, the pulmonary artery was constricted by an aluminum band applied with the Halsted band roller (4). The pulse rate increased immediately from 124 to 220. The dog was obviously ill during the next few days with respirations of 40 to 50 per minute. On November 10th the pulse rate was 196; on November 13th, 172. The blood pressure readings were as follows: before operation 250/98, the day

---

<sup>2</sup> Standardized roentgenograms were taken by having the target and the film at fixed distances from the heart, the former being placed at a distance of 5 feet from the film and the latter touching the animal. By this method direct comparison of the cardiac shadows was possible.

after operation 152/48. Within twelve days the femoral blood pressure had recovered to 220/94. On April 20th, five months later, the pulse was 140. On auscultation a snapping pulmonic second sound was heard, preceded by a high pitched systolic bruit.

The roentgen-ray studies showed an interesting sequence of events (fig. 2). Immediately after the production of the stenosis, the cardiac shadow was increased,

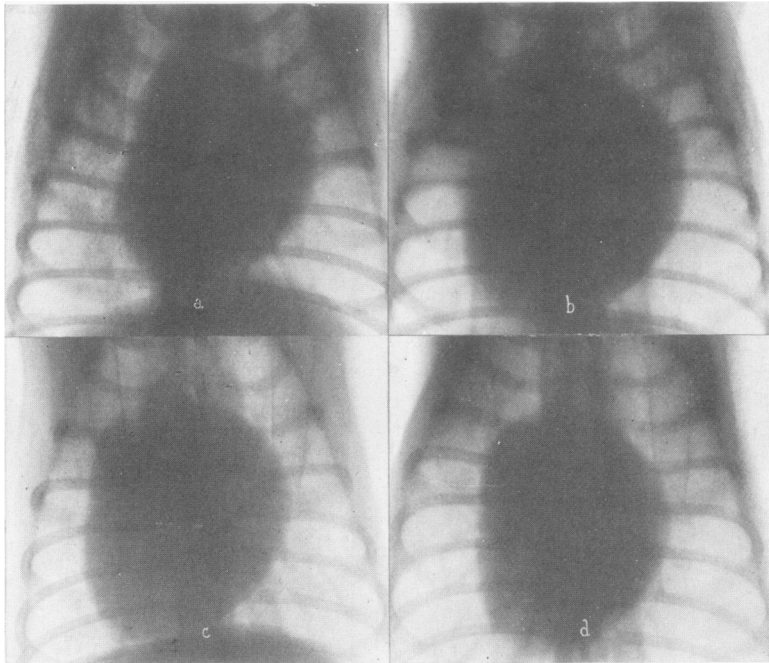


FIG. 2. ROENTGENOGRAMS OF EXPERIMENT 4

*a*, November 4, 1924, before producing pulmonic stenosis; *b*, November 11, 1924, showing definite enlargement due to a prominent right ventricle; *c*, December 26, 1924, enlargement less marked but still present; *d*, February 20, 1925, enlargement has completely subsided.

principally by the prominence of the right ventricle. According to the roentgenogram this enlargement persisted for several months and then gradually diminished, so that by February 20th the cardiac shadow had again reverted to the preoperative size.

Blood-volume studies were made. The normal blood-volume of a dog weighing 11 kilos is about 1000 to 1100 cc. As the necessary dye was not available, no preoperative studies were possible, but on February 17th, three months after the



production of the stenosis, the animal had a blood volume of 784 cc. A second determination on April 21st indicated a volume of 880 cc. It is apparent that there was no increase in blood volume such as was demonstrated in the presence of interventricular septal defects. The evidence, on the contrary, pointed to a blood volume that was less than that which normally exists in a dog weighing 11 kilos, but no definite conclusions are possible at the present time. An electrocardiogram (fig. 3) revealed a relative preponderance of the right heart.

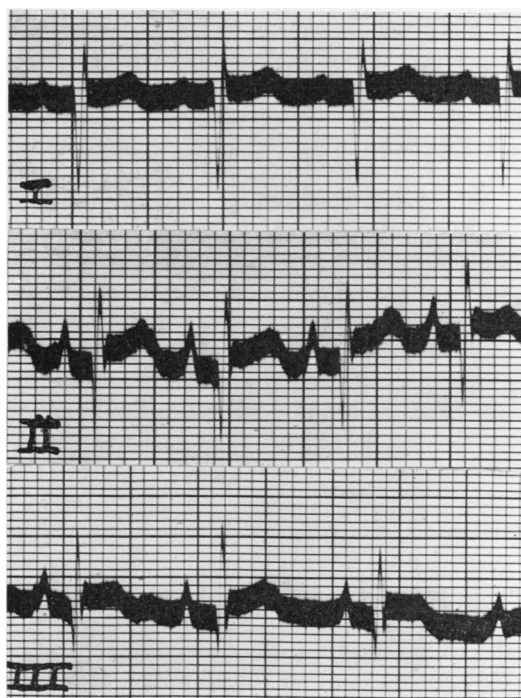


FIG. 3. RELATIVE PREPONDERANCE OF RIGHT HEART IN ELECTROCARDIOGRAM OF EXPERIMENT 4 WITH PULMONIC STENOSIS OF 5 MONTHS' DURATION

On May 22nd, following a short illness in which the dog lost weight rapidly, he was found dead. At necropsy, the aluminum band around the pulmonary artery was deeply imbedded in fibrous tissue. The lungs were congested and firm throughout with edema. There were a number of petechial hemorrhages over the surface of the heart and pericardium. The dog had probably died of an acute infection with an associated septicemia. As already indicated by roentgen-ray studies made during life, the heart appeared small or normal in size (fig. 1). It weighed 117 grams. The pulmonary artery admitted a 20 mm. bougie at the

site of constriction; the aorta admitted a 32 mm. bougie. The right ventricular wall was slightly thicker than normal, being 7 mm. wide at its narrowest portion. The right ventricular cavity appeared somewhat larger than the left ventricular cavity (fig. 1). The liver was congested, the spleen and kidneys were normal. Microscopic sections showed some congestion and edema of the lungs, with central congestion of the liver. Microscopically the heart showed a slight degree of hypertrophy *more definitely evident in the right heart than in the left.*

*Experiment 5 (dog X15).* Male, weight 11 kilos. On September 24, 1924, the pulmonary artery was constricted by a tape, placed just beyond the pulmonary valve. The diameter of the artery was reduced from 1.7 to 1.2 cm. A thrill could be felt at the time of the operation by direct palpation of the pulmonary artery and its branches beyond the stenosis. The right ventricle appeared dilated immediately after the application of the tape. The pulse rate increased from 124 to 129. Two days later the pulse rate was 164; respirations were not increased, and there was no cyanosis. Following the operation there was at no time a palpable thrill over the chest wall, but a systolic bruit could be heard followed by an accentuated pulmonic second sound. The animal remained active and well, but was killed in a fight thirty days after the above operation.

At necropsy, the lungs showed a few areas of congestion in the lower lobes, but there was no generalized congestion. The heart was normal except for a slight prominence of the right ventricle and of the conus arteriosus, and on cross-section the right ventricular cavity was dilated (fig. 1). The pulmonary artery admitted a 24 mm. bougie at the site of the constriction, and the aorta a 34 mm. bougie. The heart weighed 88 grams.

*Experiment 6 (dog X19).* Female, weight 13 kilos. On October 24, 1924, an aluminum band 8 mm. broad was applied to the pulmonary artery and rolled so as to diminish its diameter by one-half. The right ventricle immediately became dilated. The pulse rate increased from 132 to 144 and within a few minutes to 176 rising gradually to 208 at the end of the operation, and to 220 twelve hours later. At this time the animal looked ill; the blood pressure in the femoral artery could not be recorded and respirations were rapid. The animal was found dead thirty-six hours after operation.

At necropsy, the lungs were everywhere normal in appearance. The liver was congested, whereas the spleen and kidneys did not appear congested. The heart showed a marked dilatation of the right ventricle and of the conus arteriosus. On cross-section the right ventricular cavity was dilated whereas the left ventricular cavity appeared small. The right auricle was prominent. The aluminum band lay 1 cm. above the valves. The pulmonary artery admitted a 38 mm. bougie at its emergence from the heart and an 18 mm. bougie at the site of the constriction. The aorta admitted a 34 mm. bougie. Microscopic sections revealed marked emphysema of the lungs but no edema nor congestion. There was marked congestion of liver and kidney.

*Experiment 7 (dog X22).* Male, weight 12 kilos. On October 30, 1924, a

pulmonic stenosis was produced as in experiment 6. The pulse rate increased from 148 to 196. The animal became very ill with rapid though shallow respirations and was found dead forty-eight hours later. At necropsy, the right ventricle was dilated. The stenosed pulmonary artery admitted an 18 mm. bougie, the aorta a 34 mm. bougie. Microscopic sections revealed emphysema of the lungs, with moderate congestion of the liver.

*Experiment 8 (dog X48).* Weight 15.7 kilos. On April 21, 1924, the pulmonary artery was constricted to one-half its normal diameter by applying a figure-of-eight tape at a point just beyond the pulmonary valves. The dog died twenty-two days later from hemopericardium following erosion of the pulmonary artery just proximal to the tape. Microscopically the lungs showed a marked emphysema with some areas of atelectasis. The liver showed marked congestion with slight congestion also of the kidneys. The animal is included in the series because it illustrates a frequent complication attending the partial ligation of large arteries, namely, the erosion of the wall of the vessel by a constricting band, either of metal or of tape.

*Experiment 9 (dog X63).* Female, weight 18 kilos. Preoperative studies revealed a pulse rate of 116 and a blood pressure of 150/75. On July 15th the pulmonary artery was constricted to one-half its normal diameter. There developed a dilatation of the right ventricle and conus arteriosus and an immediate acceleration of pulse rate from 136 to 164. Two days later the animal was breathing normally with a respiratory rate of 32, a pulse rate of 180, and a blood pressure in the femoral artery of 90/50. There was a marked systolic murmur with a definitely accentuated pulmonic second sound. On July 30th the pulse rate was 152 and the blood pressure was 90/40. On August 20th the animal was killed. The right ventricle appeared slightly dilated, and the heart weighed 130 grams (fig. 1). The aorta admitted a 38 mm. bougie, the constricted pulmonary artery a 30 mm. bougie. As determined by the roentgenogram the transverse diameter of the heart measured 6.8 cm. before operation and 7.8 cm. on July 30th, the increased width being due to the dilated right ventricle.

*Pulmonic stenosis associated with an interventricular septal defect*

*Experiment 10 (dog X56).* Male, weight 19.8 kilos. Before operation the pulse rate was 120 and the blood pressure 170/70. On May 11, 1925, a pulmonic stenosis was produced by the application of a tape just distal to the pulmonary valves. When this tape was first applied it was constricted to such a degree that the left auricle collapsed, and the right heart became markedly dilated. It was, therefore, loosened so as to constrict the artery only one-half its normal size and with only slight dilatation of the right ventricle. On the next day, the respirations were slow, pulse 153 and blood pressure 140/55. On June 1, 1925, a pulse of 124 and a blood pressure of 140/70 were recorded. There was a well marked systolic bruit followed by an accentuated pulmonic second sound.

On June 24th the animal was anesthetized with ether and the heart exposed.

It appeared normal in size. The constricting tape around the pulmonary artery was buried in fibrous tissue. The conus arteriosus was somewhat prominent. A large interventricular defect was established with a knife introduced through the apex of the left ventricle (1). This was followed by a marked systolic thrill over the right ventricle, and an immediate acceleration of pulse from 112 to 168. At the end of the operation the pulse rate was 220. A few hours later, the respirations were 120 and were labored and grunting; the femoral pulse was imperceptible and the heart beat was so rapid it could not be counted. Judging from our previous experiences following the establishment of large interventricular defects, this animal was not expected to live. On the following morning we were astonished to find the dog standing in his cage, having eaten a good breakfast. The respirations were 72, and the pulse rate 171. The blood pressure in the femoral artery was below 90. There was a marked systolic and diastolic thrill over the right side of the chest. On June 25th, the pulse rate was 165, blood pressure 110/60 and respirations 64.

On July 1st, the pulse rate was 148, respirations 52, and blood pressure 130/50. July 13th, quite unexpectedly, the animal was found dead. At necropsy, the mouth was filled with frothy, bloody fluid. There was no free fluid either in the abdomen or in the thorax, and no congestion of liver, spleen or kidneys. The lungs, however, were blue black in appearance, with a consistency like that of liver and with no air-containing areas. The lungs weighed 780 grams, whereas the liver weighed only 680 grams. The bronchi were filled with frothy, bloody fluid. The heart was large and appeared dilated. On cross-section both ventricular cavities were large (fig. 1). The interventricular defect admitted a 34 mm. bougie. The aorta admitted a 36 mm. bougie, and the pulmonary artery admitted a 30 mm. bougie at the site of constriction. The constricting tape was found lying within the lumen of the pulmonary artery having eroded its way through the wall of the artery. Perforation into the thoracic cavity had been prevented by the thick fibrous deposits around the tape.

This animal died with a marked pulmonary edema and congestion, and exhibited at necropsy the same picture noted in those animals in which excessively large interventricular defects had been established. In these latter animals it was found that a defect larger than 30 mm. was invariably fatal. This animal, however, withstood a defect of 34 mm. for nineteen days. The sequence of events may be interpreted as follows: During the time following the second operation in which the constricting tape prevented an excessive volume flow of blood through the lungs, the animal remained well. In fact, his survival with so large a septal defect may be definitely attributed to the presence of the constriction of the pulmonary artery. When the tape eroded through the wall of the pulmonary artery on the nineteenth day, its lumen became larger allowing an excessive amount of blood to flow through the pulmonary circuit, followed by marked pulmonary congestion, edema and death.

The roentgenographic studies were instructive. Before operation the trans-

verse diameter measured 7.4 cm. On June 23rd, forty-two days after the constriction of the pulmonary artery the diameter measured 8.0 cm. On July 9th, fifteen days after the establishment of an interventricular septal defect, the diameter measured 9.3 cm., showing a rapid increase in the size of the heart accompanying the septal defect.

*Experiment 11 (dog X55).* Male, weight 14.8 kilos. A preoperative pulse rate of 92 and a blood pressure of 170/75 were determined. On May 14, 1925, the pulmonary artery was exposed and a tape applied so as to encircle it tightly but not to constrict it. The pulse rate rose to 177. An interventricular septal defect was then established. The pulse rate increased to 208. There was an intense thrill over the right ventricle. It seemed that the flow through the pulmonary circuit was excessive and if allowed to persist would probably end fatally. Accordingly, the tape around the pulmonary artery was tightened, constricting the artery to a slightly greater degree. The pulse rate fell immediately to 184 and the intensity of the thrill over the right ventricle was diminished. The right ventricle was dilated.

Four hours later the dog showed labored breathing with a very rapid small pulse which could not be counted. We believed the animal would die. Twenty-four hours later he had taken some milk and was standing in his cage. The pulse rate was 160 with a femoral blood pressure of 110 and respirations of 40. The thrill over the right chest had greatly diminished but was still palpable. During the next few days the animal was obviously ill with a pulse rate of 180, rapid, labored breathing, and a blood pressure of 100. Gradual improvement followed, and by June 2nd the blood pressure had recovered to 115/30, with a pulse rate of 165. There was a definite though circumscribed thrill over the pulmonic area, with a loud systolic bruit, corresponding more to the bruit of a pulmonic stenosis than to that of an interventricular leak. On July 9th the animal had a pulse rate of 168 and a blood pressure of 120/50.

On July 20th, two months after the operation, the animal was found dead. On opening the chest, both thoracic cavities were filled with blood, and examination revealed complete erosion of the wall of the pulmonary artery by the tape, a part of the tape lying within the lumen and a part without. The right ventricle appeared dilated and more capacious than the left. The septal defect admitted a 26 mm. bougie, the pulmonary artery a 26 mm. bougie and the aorta a 32 mm. bougie. The heart weighed 156 grams. The liver appeared normal and weighed 540 grams. The lungs were everywhere soft, air-containing and weighed 180 grams (in marked contrast to the weight of 780 grams in experiment 10). Microscopic sections revealed no edema and no congestion of the lung, but a slight compression atelectasis.

Roentgenographic studies before operation showed a heart with a transverse diameter of 8.0 cm.; fifty-seven days after the establishment of the combined pulmonary stenosis and interventricular defect the diameter measured 9.1 cm.

*Experiment 12 (dog X16).* Male, weight 12.4 kilos. On September 25, 1924,

a pulmonary stenosis was produced by means of a constricting tape with an immediate acceleration of pulse rate from 160 to 240. Before operation the pulse rate was 108 and the blood pressure was 196/96. Two days following the operation the pulse rate was 194, blood pressure 136/48 and respirations 36. There was a well marked systolic bruit, but no palpable thrill. The pulmonic second sound was snapping and accentuated. By October 3rd the blood pressure had recovered to 194/80. October 11th a pulse rate of 198 was recorded, and October 30th the rate was 100. There was no visible cyanosis in spite of a well marked pulmonic stenosis.

On December 9, 1924, a septal defect was established, with the immediate development of a palpable thrill over the right ventricle. On the following day, the pulse rate was 177. There was a blowing systolic murmur accompanied by a palpable thrill. On December 24th it was noticed that the dog had a slightly distended abdomen. This rapidly grew worse and was obviously due to an ascites. Three hundred cubic centimeters of clear brownish yellow fluid were removed from the abdomen. The hind legs were markedly swollen. The pulse rate was 172.

On January 7th the dog was examined under ether anesthesia and then killed. The chest contained a liter of pink fluid. The lungs were normal, and showed no areas of congestion. The abdomen contained three liters of clear yellowish fluid. The liver was congested, but the other abdominal organs were normal. The heart, which was surrounded by dense pericardial adhesions, appeared very small. There was a slight thrill over the right ventricle. The tape surrounding the pulmonary artery was deeply imbedded in fibrous tissue. The pulmonary artery admitted a 26 mm. bougie at the point of stenosis. There was still a small opening in the septum which admitted a 14 mm. bougie. The aorta admitted a 34 mm. bougie. The heart weighed 94.5 grams. Microscopic sections revealed a slight edema of the lungs, but no congestion, a marked congestion of the liver, and a definite chronic glomerular nephritis, with thickening of the capsule and casts in the tubules.

The roentgenograms presented interesting information (fig. 4). The preoperative transverse diameter of the heart measured 6.5 cm. On November 6th, forty-two days after the constriction of the pulmonary artery, the diameter measured 7.3 cm. On December 23rd, fourteen days after the establishment of the interventricular defect, it measured 9.5 cm. Roentgenograms subsequent to this date showed very obscure shadows of the heart due to the accumulation of fluid in the thoracic cavity. At necropsy, after the development of a very remarkable generalized edema, hydrothorax and ascites, the heart appeared small, certainly much smaller than the roentgenographic evidence of December 23rd had suggested. Is it possible that with the development of the edema and gradual cardiac decompensation the volume flow through the heart decreased with retrogression in the size of the heart? It was quite evident that the establishment of an interventricular defect resulted in a much greater enlargement of the heart than had occurred following the production of a pulmonic stenosis alone.

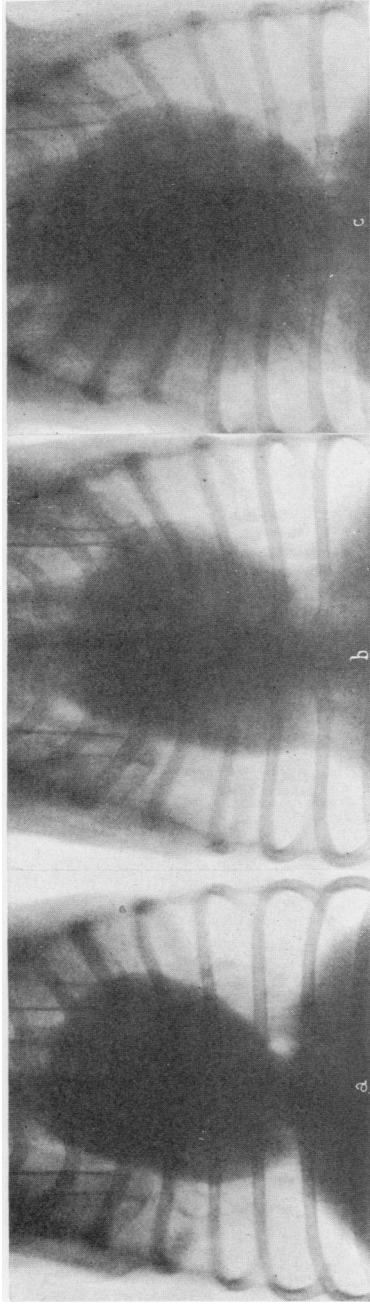


FIG. 4. ROENTGENOGRAMS OF EXPERIMENT 12

*a*, September 24, 1924, before operation; *b*, November 6, 1924, 42 days after production of pulmonic stenosis. Slight enlargement of heart; *c*, marked enlargement of heart on December 23, 14 days after establishing a septal defect in addition to the pulmonic stenosis.

## BIBLIOGRAPHY

1. Holman, E., and Beck, C. S.: J. Exper. Med., 1925, xlii, 661. The Physiological Response of the Circulatory System to Experimental Alterations. I. The Effect of Intracardiac Fistulae.
2. Beck, C. S., and Holman, E.: J. Exper. Med., 1925, xlii, 681. The Physiological Response of the Circulatory System to Experimental Alterations. II. The Effect of Variations in Total Blood Volume.
3. Holman, E.: Arch. Surg. 1924, ix, 856. Experimental Studies in Arteriovenous Fistulas. III. Cardiac Dilatation and Blood Vessel Changes.
4. Halsted, W. S.: J. Exper. Med., 1909, xi, 373. Partial, Progressive and Complete Occlusion of the Aorta and Other Larger Arteries in the Dog by Means of the Metal Band.
5. Reid, M. R.: J. Exper. Med., 1924, xl, 289. Partial Occlusion of the Pulmonary Aorta and Inferior Vena Cava with the Metallic Band; Observations on Changes in the Vessel Wall and in the Heart.