

# Stercoral Perforation of the Sigmoid Colon in a Schizophrenic Patient

SHIV KUMAR BUNKAR<sup>1</sup>, AMIT SINGH<sup>2</sup>, ROHIT PRATAP SINGH<sup>3</sup>

## ABSTRACT

Stercoral perforation of the colon is a life threatening condition, due to pressure necrosis by hard fecaloma which, are commonly found in chronic constipated patients. We report the case of a 45-year-old schizophrenic woman, under psychiatric treatment for two years, presenting with a 10-day history of absolute obstipation and distension. On physical examination the patient had signs of generalized peritonitis. Preoperative diagnostic workup gave no clear-cut clues about diagnosis. Emergency laparotomy revealed a single perforation over the antimesenteric border of the sigmoid colon with hard fecal matter protruding through perforation margin. A segmental resection of the sigmoid colon with colonic lavage and end to end anastomosis was performed. The patient made an uneventful recovery. We have discussed the diagnostic work-up, and the management of this rare entity. Patient was on antipsychotic, anticholinergic and NSAID'S drugs for long time with longstanding immobilisation and poor oral intake. Association of these etiological factors with chronic constipation which ultimately leads to stercoral perforation have been corroborated.

**Keywords:** Antipsychotic drugs, Colon perforation, Fecaloma

## CASE REPORT

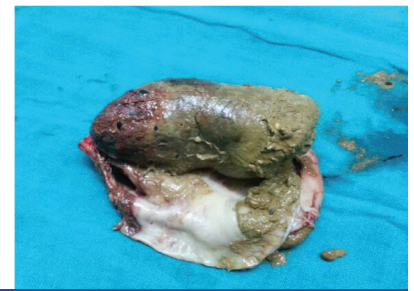
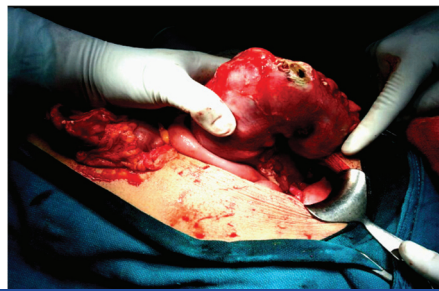
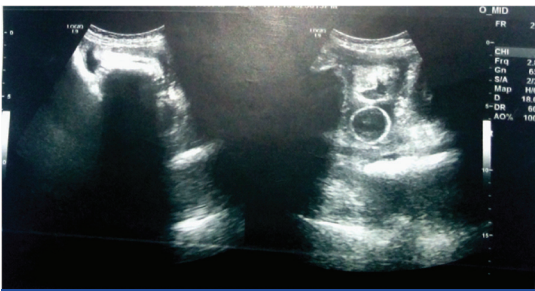
A 45-year-old woman arrived to the emergency department because of diffuse abdominal pain and not passing stool for 10 d. The patient was on psychiatric treatment due to abnormal behaviour for last two years, with haloperidol 10 mg/day and trihexyphenidyl 6 mg/day. Her parents gave history of her violent and bizarre behaviour. She did not conceive after 20 y of marriage. From last three months she was mute and devoid of social interactions, with fixed and stony facial expressions. Patient also had history of taking ibuprofen for non specific joint pain as self medication from five years; however there was no other drug abuse history. Patient also had history of longstanding constipation which was usually treated with laxatives or enema. On clinical examination abdomen was distended, a 5×7 cm tender, firm lump was palpated in hypogastrium. Tenderness and guarding was present all over abdomen, bowel sounds were absent. On per rectal examination few fecoliths were found which were manually removed. Heart rate was 92/minute and blood pressure was 110/80mmhg. Haematological investigations revealed leukocytosis (WBC 18000 mm<sup>3</sup>) and anaemia (Hb 8.0 mg %), the other values were within the normal limits. X-ray abdomen revealed dilated gut loops with few air fluid levels. Ultrasonography abdomen revealed dilated bowel loops with no peristalsis and multiple 70-76 mm size of echogenic shadows probably fecoliths, features suggestive of sub acute intestinal obstruction and reactionary ascites [Table/Fig-1]. Four hour after admission patient passed hard stools 2-3 times and abdominal girth reduced by 1cm, so conservative management was planned. CT scan abdomen revealed grossly dilated bowel loops involving large intestine along with small rounded well defined opacities with central lucency and gross ascites suggestive of intestinal obstruction due to fecoliths or foreign body. A diagnosis of acute intestinal obstruction was made. But next day due to an increase in abdominal tenderness and tachycardia (pulse-126/min), an emergency laparotomy was planned. On exploration around 1.5 litre feco-purulent fluid was present in peritoneal cavity. Whole colon was grossly distended and a 1x2 cm perforation with protruding fecaloma was identified along antimesenteric border of sigmoid colon [Table/Fig-2]. Inspection of the colon did not reveal neoplasm or diverticulosis.

Segmental resection of perforated sigmoid colon with end to end anastomosis was performed. On opening resected sigmoid colon,

a large fecaloma found protruding through perforation margins [Table/Fig-3]. An intraluminal lavage of the proximal and distal colon before anastomosis was done and many hard fecoliths were evacuated during lavage. Surgery was supplemented with medical therapy in the form of antibiotics (ceftriaxone, and metronidazole), analgesics and proton pump inhibitors for stress ulcer prophylaxis. On postoperative psychiatric opinion, the clinical history and previous treatment suggested the diagnosis of schizophrenia (F 20). Psychiatrist advised to start atypical antipsychotic risperidone 6mg daily instead of haloperidol, since it has fewer side effects and patient tolerated the drug orally. The patient made an uneventful recovery and was discharged on the 8<sup>th</sup> postoperative day. Histopathology revealed multiple perforations and ulcers along the antimesenteric border are seen, evidence suggestive of acute ischemic necrosis. The patient was followed-up for a period of two months, but unfortunately patient died after two months due to some respiratory complications.

## DISCUSSION

Stercoral colonic perforation is a rare, life-threatening disease defined as "perforation of the large bowel due to pressure necrosis from a fecal mass" i.e. in the absence of lesions such as a tumour, diverticulosis or external injury [1,2]. To the best of our knowledge fewer than 150 cases of stercoral perforation of the colon have been reported in literature up to 2011 [3]. The disease was first described by Berry in 1894 [4]. It may represent 3.2% of all colonic perforations and 2.2% of randomly selected autopsy examinations [5], can be life threatening with mortality rates ranging between 32-57% [6]. The pathogenesis is related to poor hydration of the feces, resulting in hard and impacted feces, also called fecaloma [7]. This increases intraluminal pressure and causes ischemic necrosis of the colonic wall, stercoral ulcer formation and, subsequently, colonic perforation [7]. Stercoral ulcers usually occur in debilitated, bed-ridden, mentally ill, or narcotic-dependent patients [2]. Dehydration is common in these patients because nutrition and water administration is often insufficient. The most influential factor in development of a stercoral ulcer is chronic severe constipation [2]. In our case, the patient was on haloperidol and trihexyphenidyl from two years. Haloperidol is a butyrophenone, and has D2 receptor antagonist activity with anticholinergic property therefore constipation is a common side



**[Table/Fig-1]:** Ultrasonography abdomen shows features of intestinal obstruction due to fecolith with reactionary ascites **[Table/Fig-2]:** Intraoperative photograph shows a perforation on antimesenteric border of sigmoid colon and protruding fecaloma **[Table/Fig-3]:** Cut section of resected sigmoid colon shows large fecaloma

effect of this antipsychotic drug, and trihexyphenidyl is centrally acting anticholinergic is used to treat extra pyramidal side effects occurring during antipsychotic treatment. Trihexyphenidyl binds M1 muscarinic receptor and blocks parasympathic tone of smooth muscle of gastrointestinal tract so tone and amplitude of intestinal contractions reduced; constipation and ileus may occur [8]. In our case, the patient was also on nonsteroidal anti-inflammatory drug for nonspecific joint pain, these drugs inhibit prostaglandin synthesis and prostaglandins provides cyto-protection to intestinal integrity, so NSAID'S may be possible cause of stercoral perforation [9]. Mauer et al., proposed four diagnostic criteria of stercoral perforation: 1) A round and ovoid antimesenteric colonic perforation larger than 1cm in diameter 2). The colon full of stool that protrudes through the perforation site 3) Microscopic evidence of multiple pressure ulcer and acute inflammatory reaction surrounding the perforation 4) Absence of external injury, diverticulitis or obstruction due to neoplasm or adhesions [1,10]. All the four criteria were satisfied in our case. The most common locations for stercoral ulceration and perforation are the anterior rectum, the antimesenteric border of the recto sigmoid junction, and the sigmoid colon because of the physiological characteristics of these segments, such as lower water content of the stool, poor blood supply and high pressure due to the narrowed intraluminal diameter [1,7]. The mean age of presentation in such cases is 59 y and the age range is 22–85 y [10]. The most common presenting symptom of stercoral perforation is acute or diffuse abdominal pain with fever. X-ray of the abdomen demonstrates pneumoperitoneum, sometimes air-fluid intestinal levels and fecaloma [1,11]. Only 10% of the patients are definitely diagnosed before surgery [11]. Surgery seems to be the only therapeutic treatment. It is considered that the inflammatory process due to fecaloma involves a long colonic segment, along with occurrence of multiple ulcers and necrotic changes. This means that a simple closure or a limited colonic resection should be avoided without exploration of other colonic segments or without washing out the colon of the redundant fecal material [1,10].

Intraoperative colonoscopy is a advised to rule out additional stercoral ulcerations, which may be possible cause of delayed colonic perforations [11]. Simple primary closure, colostomy, Simple primary closure plus colostomy, Hartmann surgery and Intraoperative colonic lavage are common surgical approaches

depending on physical status, laboratory findings and degree of peritonitis [1,11]. Subtotal colectomy must be considered in cases with multiple dilations and a thin bowel wall in order to avoid postoperative perforations [1].

## CONCLUSION

In our case, the patient was schizophrenic with a history of chronic constipation, longstanding immobilisation, poor water administration and was under treatment with antipsychotic, anticholinergic drugs. Our case report lends support to this association antipsychotic, anticholinergic drugs leading to constipation that could result in stercoral perforation due to pressure necrosis by fecaloma. The present experience has shown that in the old age group with antipsychotic treatment constipation is common but once radiology shows large bowel obstruction, and clinical signs suggestive of peritonitis, stercoral perforation should be considered in differential diagnosis because early diagnosis and aggressive management lowers the morbidity and mortality.

## REFERENCES

- [1] E Falidas, S Mathioulakis, K Valachos, F Archontovasilis, C Villias. Stercoral perforation of the sigmoid colon. A case report and brief review of the literature. *G Chir.* 2011;32(8-9):368-71.
- [2] Jeonghyun Kang, Min Chung. A stercoral perforation of the descending colon. *Journal of Korean surgical society.* 2012;82(2):125–27.
- [3] Kumar P, Pearce O, Higginson A. Imaging manifestations of faecal impaction and stercoral perforation. *Clin Radiol.* 2011;66:83-88.
- [4] Berry J. Dilatation and rupture of sigmoid flexure short report. *Br Med J.* 1894;1:301.
- [5] Hsiao TF, Chou YH. Stercoral perforation of colon: a rare but important mimicker of acute appendicitis. *Am J Emerg Med.* 2010;28(1):112.e1-2.
- [6] Wu CH, Huang CC, Wang LJ, et al. Value of CT in the discrimination of fatal from non-fatal stercoral colitis. *Korean J Radiol.* 2012;13(3):283-89.
- [7] Monika Sharma and Anjali Agrawal. Stercoral sigmoid colonic perforation with fecal peritonitis. *Indian J Radiol Imaging.* 2010;20(2):126–28.
- [8] KD Tripathi. Essentials of medical pharmacology 6<sup>th</sup> Edition 2008: P; 106-15.
- [9] Patel VG, Kalakuntla V, Fortson JK, Weaver WL, Joel MD, Hammami A. Stercoral perforation of the sigmoid colon: report of a rare case and its possible association with nonsteroidal anti-inflammatory drugs. *Am Surg.* 2002;68:62–64.
- [10] Maurer CA, Renzulli P, Mazzucchelli L, Egger B, Seiler CA, Büchler MW. Use of accurate diagnostic criteria may increase incidence of stercoral perforation of the colon. *Dis Colon Rectum.* 2000;43:991–98.
- [11] Huang WS, Wang CS, Hsieh CC, Lin PY, Chin CC, Wang JY. Management of patients with stercoral perforation of the sigmoid colon: report of five cases. *World Journal of Gastroenterol.* 2006;12:500-03.

### PARTICULARS OF CONTRIBUTORS:

1. Associate Professor, Department of Surgery, Jawahar Lal Nehru Medical College, Ajmer, Rajasthan, India.
2. Senior Resident, Department of Surgery, Jawahar Lal Nehru Medical College, Ajmer, Rajasthan, India.
3. Post Graduate Student, Department of Surgery, Jawahar Lal Nehru Medical College, Ajmer, Rajasthan, India.

### NAME, ADDRESS, E-MAIL ID OF THE CORRESPONDING AUTHOR:

Dr. Amit Singh,  
Senior Resident, Department of Surgery, Jawahar Lal Nehru Medical College, Ajmer-305001, Rajasthan, India.  
Phone : 9460387152, E-mail : dr.amit5280@gmail.com

FINANCIAL OR OTHER COMPETING INTERESTS: None.

Date of Submission: Jul 28, 2014  
Date of Peer Review: Oct 12, 2014  
Date of Acceptance: Nov 08, 2014  
Date of Publishing: Jan 01, 2015