



New daily persistent headache with isolated sphenoiditis in children

Jeongho Lee, MD, Minhee Rhee, MD, Eun Sook Suh, MD, PhD

Department of Pediatrics, Soonchunhyang University Seoul Hospital, Soonchunhyang University College of Medicine, Seoul, Korea

Isolated sphenoid sinusitis is a rare disease in children, and its symptoms are often nonspecific and confusing. Rarely, severe headache can be the first or only symptom of isolated sphenoid sinusitis. New daily persistent headache (NDPH) is a form of chronic daily headache that may have features of both migraines and tension-type headaches. NDPH is difficult to diagnose and requires a multifaceted approach. Here, we report on a 10-year-old boy and an 11-year-old girl who both presented with typical NDPH symptoms. These patients had no nasal symptoms or signs of infection. Neither nonsteroidal anti-inflammatory drugs nor topiramate had any effect on the headaches. Their neurological and ophthalmological examinations were normal. The results of routine blood work, including thyroid function tests, inflammatory markers, complete blood count, tests for viral infection, and a metabolic panel, were normal. A brain magnetic resonance imaging scan showed isolated sphenoid sinusitis. Both patients' symptoms resolved completely after approximately 1 month of oral antibiotics for sinusitis.

Key words: Chronic headache, Sphenoid sinusitis

Corresponding author: Eun Sook Suh, MD, PhD
Department of Pediatrics, Soonchunhyang University Seoul Hospital, 22 Daesagwan-ro, Yongsan-gu, Seoul, 110-744, Korea
Tel: +82-2-709-9158
Fax: +82-2-795-3687
E-mail: essuh@schmc.ac.kr

Received: 26 September, 2014

Revised: 21 November, 2014

Accepted: 12 December, 2014

Introduction

Sinusitis is a well-recognized cause of both acute and chronic childhood headache, but isolated sphenoid sinusitis is a rare disease and its symptoms are often nonspecific and confusing. Thus a delay in diagnosis occurs frequently^{1,2}. Although chronic severe complications are possible, sinus-induced chronic headache has a good prognosis if diagnosed and treated early².

New daily persistent headache (NDPH) is form of chronic daily headache (CDH) that may have features of both migraines and tension-type headaches. NDPH is difficult to diagnose and requires a multifaceted approach³. NDPH is more frequent in children and adolescents than adults, and accounts for 1.7%–10.8% of patients with CDH cases in children and adolescents⁴. Infections are associated with NDPH and may provoke symptom⁵.

In this article we present two cases of children with isolated sphenoid sinusitis that caused symptoms of NDPH.

Case reports

1. Case 1

A 10-year-old boy was referred to headache clinic in Soonchunhyang University Seoul Hospital for evaluation of CDH. He had no family history of migraine. His first headache

Copyright © 2015 by The Korean Pediatric Society

This is an open-access article distributed under the terms of the Creative Commons Attribution Non-Commercial License (<http://creativecommons.org/licenses/by-nc/3.0/>) which permits unrestricted non-commercial use, distribution, and reproduction in any medium, provided the original work is properly cited.

with diplopia had occurred 6 months previously, and he remembered the exact date. The patient described his headache as a dull, pressing sensation located in both parietal areas that was accompanied by photophobia and lasted about 4 hours. These events occurred nearly every day, and were occasionally not relieved by sleep. His CDH type was consistent with NDPH. The patient had trials of nonsteroidal anti-inflammatory drugs (NSAIDs) and topiramate, but these had no effects on his headaches.

He denied any nasal symptoms or fever. Sinus percussion and examination of his cardiorespiratory and abdominal systems were normal. His vital signs were within normal limits. His neurological and ophthalmological examinations were normal. Routine blood work included thyroid function, inflammatory markers, complete blood count, virus study, and metabolic profile, and the results were normal. We did not check the cerebral spinal fluid (CSF) study. A brain magnetic resonance imaging (MRI)

scan showed isolated right sphenoid sinusitis (Fig. 1). After oral antibiotic treatment for about 4 weeks, his symptoms resolved completely.

2. Case 2

An 11-year-old girl presented with severe headache with dizziness and nausea over a 6-month period. Her mother has a typical migraine history. The patient and her mother could recall the exact date that the girl's headaches began and that these had caused changes in her daily routine. The headaches affected both the periorbital and temporal areas, were constant and throbbing, and were exacerbated by head movement. The symptoms lasted about 4–5 hours and occurred every other day. Her chronic headache type was regarded as NDPH. She was given NSAIDs and amitriptyline, but the response was not good.

The patient had no nasal symptoms or signs of infection. Sinus percussion and neurological examinations were normal. Results

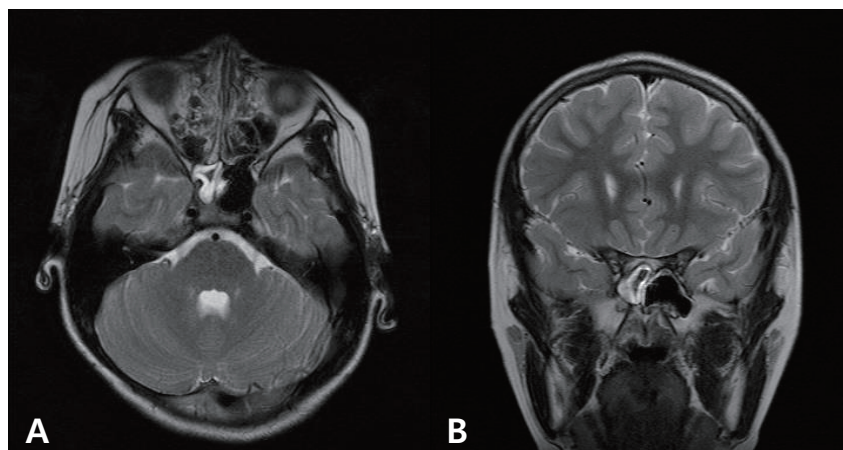


Fig. 1. The results of T2-weighted axial (A) and coronal (B) magnetic resonance imaging demonstrate an abnormal hyperintense signal in the right sphenoid sinus (case 1).

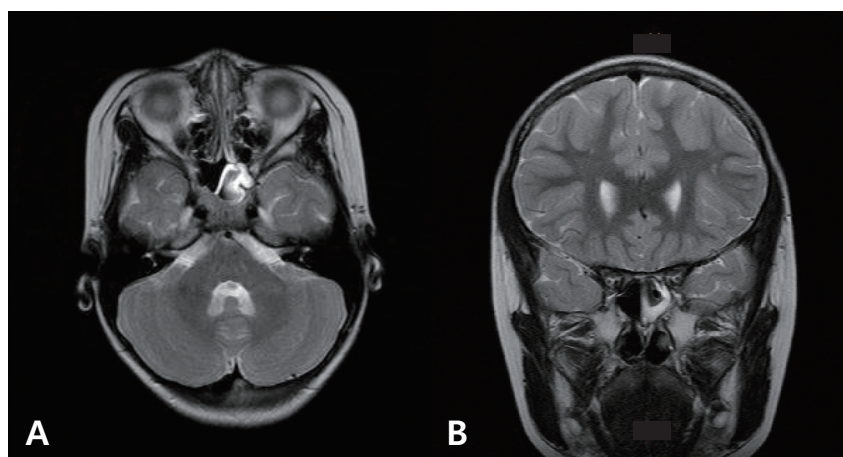


Fig. 2. The results of T2-weighted axial (A) and coronal (B) magnetic resonance imaging demonstrate an abnormal signal in the left sphenoid sinus (case 2).

of basic laboratory tests including a complete blood count, thyroid function, and infection markers were normal. A virus study that included Epstein-Barr virus was also normal. Her vital signs were within normal limits. CSF study was not performed. A brain MRI was requested to rule out intracranial pathology, and it revealed isolated sphenoid sinusitis (Fig. 2). After about 1 month of oral antibiotics for sinusitis, the patient's symptoms resolved completely.

Discussion

CDH is defined as a headache lasting more than 4 hr/day on more than 15 day/month for more than 3 months. According to the International Classification of Headache Disorders, 2nd edition⁶, NDPH is one of four types of CDH and comprises daily headaches within 3 days of onset that are unremitting for >3 months. Because most patients with NDPH complain of a headache that begins abruptly, they often remember the exact date the event started. Their headache subtype resembles tension-type overlapping typical migraine³. In general population studies, CDH is estimated to affect about 5% of adults and 1% of children and adolescents, and the prevalence of NDPH has been reported at 0.03%–0.1%⁷. NDPH has been reported in children and adolescents than adults^{3,7}.

Patients with NDPH should have no symptoms of increased intracranial pressure or other neurological symptoms and no papilledema³. Any secondary headache may come on suddenly, as in NPDH, and it is important to distinguish between primary and secondary causes. Well-known secondary causes of NPDH are cerebral venous sinus thrombosis, carotid or vertebral dissection, vascular disorder, exposure to a toxin, temporomandibular joint disease, endocrine disorders such as Hashimoto's thyroiditis, sphenoid sinusitis, some virus infection and posttraumatic headache³. The clinician should apply tests such as routine blood work, thyroid studies, and assessment of erythrocyte sedimentation rate and the complete metabolic profile.

As a cause of secondary NPDH, isolated sphenoid sinusitis is rare in children and is difficult to diagnosis^{3,8}. Most cases of isolated sinusitis have no nasal symptoms and signs of infection. The sphenoid sinus is often referred to as the "neglected" sinus because it is invisible to superficial examination and cannot be seen on standard endoscopy or plain radiographs⁹. Therefore, unless the physician has a high degree of suspicion of a sphenoid problem, the diagnosis can be missed for long time⁹.

The two patients presented with typical NPDH features such as frequent and prolonged headaches that began abruptly and that occurred on both sides in the periorbital area. They did not complain of nasal symptoms. The headaches had adversely affected their lifestyle, and their parents were concerned about

the effects. The effects of NSAIDs and/or migraine drugs were poor. The patients' responses to the treatment of sinusitis with antibiotics were dramatic, and their symptoms resolved without complications.

Headaches are present in 85%–98% of patients with isolated sphenoid sinusitis¹⁰. The symptoms of headache are periorbital and temporal, worsen on bending forward, and characteristically involve the frontal and parietal regions³. According to the American Academy of Neurology practice parameters, neuroimaging studies should not be done routinely in children with recurrent headaches and normal neurological examination results¹⁰. Despite these recommendations, neuroimaging is sometimes necessary in children. First NDPH or other CDH causes parental anxiety and impairs the patient's quality of life. Second, rare conditions such as isolated sphenoid sinusitis are difficult to diagnosis without brain computerized tomography scanning or MRI.

NDPH can cause sleep disturbances, dizziness, generalized weakness, visual disturbances, abdominal pain, and fatigue. Mood disorders, such as anxiety and depression, are also associated with CDH¹⁰. Some cases involve medication overuse and can contribute to frequent school absences. Thus, patients with NDPH should undergo multimodal evaluations, most of which will be clearly negative or positive³. There are still many unanswered questions about NDPH, and further study is needed to understand it better.

There are few reports of isolated sphenoid sinusitis associated with NDPH in children. Our report may be the first in the field of pediatric headache, because other studies have been reported in the otorhinolaryngology literature^{2,3,8}.

Isolated sphenoid sinusitis is rare in children and is usually misdiagnosed because of its atypical manifestations. Thus, suspicion is required when assessing children with NDPH or atypical headache without migraine history or visual symptoms^{2,3}.

Conflict of interest

No potential conflict of interest relevant to this article was reported.

References

- Lewis DW, Qureshi F. Acute headache in children and adolescents presenting to the emergency department. *Headache* 2000;40:200-3.
- McKay-Davies I, Buchanan MA, Prinsley PR. An unusual headache: sphenoiditis in children and adolescents. *Int J Pediatr Otorhinolaryngol* 2011;75:1486-91.
- Baron EP, Rothner AD. New daily persistent headache in children

- and adolescents. *Curr Neurol Neurosci Rep* 2010;10:127-32.
4. Bigal ME, Lipton RB, Tepper SJ, Rapoport AM, Sheftell FD. Primary chronic daily headache and its subtypes in adolescents and adults. *Neurology* 2004;63:843-7.
 5. Diaz-Mitoma F, Vanast WJ, Tyrrell DL. Increased frequency of Epstein-Barr virus excretion in patients with new daily persistent headaches. *Lancet* 1987;1:411-5.
 6. Headache Classification Subcommittee of the International Headache Society. The International Classification of Headache Disorders: 2nd ed. *Cephalalgia* 2004;24 Suppl 1:9-160.
 7. Castillo J, Munoz P, Guitera V, Pascual J. Kaplan Award 1998. Epidemiology of chronic daily headache in the general population. *Headache* 1999;39:190-6.
 8. Pascual J. Other primary headaches. *Neurol Clin* 2009;27:557-71.
 9. Ng YT, Butler IJ. Sphenoid sinusitis masquerading as migraine headaches in children. *J Child Neurol* 2001;16:882-4.
 10. Gilony D, Talmi YP, Bedrin L, Ben-Shosan Y, Kronenberg J. The clinical behavior of isolated sphenoid sinusitis. *Otolaryngol Head Neck Surg* 2007;136:610-5.