

Endosonography in the diagnosis and management of pancreatic cysts

Vivek Kadiyala, Linda S Lee

Vivek Kadiyala, Linda S Lee, Division of Gastroenterology, Hepatology and Endoscopy, Brigham and Women's Hospital, Boston, MA 02115, United States

Linda S Lee, Harvard Medical School, Boston, MA 02115, United States

Author contributions: Kadiyala V and Lee LS solely contributed to this paper.

Conflict-of-interest: The authors declare that they have no competing interests.

Open-Access: This article is an open-access article which was selected by an in-house editor and fully peer-reviewed by external reviewers. It is distributed in accordance with the Creative Commons Attribution Non Commercial (CC BY-NC 4.0) license, which permits others to distribute, remix, adapt, build upon this work non-commercially, and license their derivative works on different terms, provided the original work is properly cited and the use is non-commercial. See: <http://creativecommons.org/licenses/by-nc/4.0/>

Correspondence to: Linda S Lee, MD, Division of Gastroenterology, Hepatology and Endoscopy, Brigham and Women's Hospital, 75 Francis St, Boston, MA 02115, United States. lslee@partners.org

Telephone: +1-617-2780359

Fax: +1-617-2645132

Received: August 29, 2014

Peer-review started: August 30, 2014

First decision: September 19, 2014

Revised: September 30, 2014

Accepted: December 16, 2014

Article in press: December 17, 2014

Published online: March 16, 2015

Abstract

Rapid advances in radiologic technology and increased cross-sectional imaging have led to a sharp rise in incidental discoveries of pancreatic cystic lesions. These cystic lesions include non-neoplastic cysts with no risk of malignancy, neoplastic non-mucinous serous cystadenomas with little or no risk of malignancy, as well as neoplastic mucinous cysts and solid pseudopapillary neoplasms both with varying risk

of malignancy. Accurate diagnosis is imperative as management is guided by symptoms and risk of malignancy. Endoscopic ultrasound (EUS) allows high resolution evaluation of cyst morphology and precise guidance for fine needle aspiration (FNA) of cyst fluid for cytological, chemical and molecular analysis. Initially, clinical evaluation and radiologic imaging, preferably with magnetic resonance imaging of the pancreas and magnetic resonance cholangiopancreatography, are performed. In asymptomatic patients where diagnosis is unclear and malignant risk is indeterminate, EUS-FNA should be used to confirm the presence or absence of high-risk features, differentiate mucinous from non-mucinous lesions, and diagnose malignancy. After analyzing the cyst fluid for viscosity, cyst fluid carcinoembryonic antigen, amylase, and cyst wall cytology should be obtained. DNA analysis may add useful information in diagnosing mucinous cysts when the previous studies are indeterminate. New molecular biomarkers are being investigated to improve diagnostic capabilities and management decisions in these challenging cystic lesions. Current guidelines recommend surgical pancreatic resection as the standard of care for symptomatic cysts and those with high-risk features associated with malignancy. EUS-guided cyst ablation is a promising minimally invasive, relatively low-risk alternative to both surgery and surveillance.

Key words: Endoscopic ultrasound; Pancreatic cyst; Serous cystadenoma; Intraductal papillary mucinous neoplasms; Mucinous cystic neoplasm; Solid pseudopapillary neoplasms; diagnosis; Management; Ablation

© **The Author(s) 2015.** Published by Baishideng Publishing Group Inc. All rights reserved.

Core tip: Endoscopic ultrasound with fine needle aspiration (EUS-FNA) is an important and safe diagnostic tool in pancreatic cystic lesions to help

diagnose malignancy, identify features concerning for malignancy, and differentiate mucinous from non-mucinous cysts. More recently EUS-guided pancreatic cyst ablation may offer a minimally invasive and safer alternative to surgical resection for carefully selected pancreatic cysts.

Kadiyala V, Lee LS. Endosonography in the diagnosis and management of pancreatic cysts. *World J Gastrointest Endosc* 2015; 7(3): 213-223 Available from: URL: <http://www.wjgnet.com/1948-5190/full/v7/i3/213.htm> DOI: <http://dx.doi.org/10.4253/wjge.v7.i3.213>

INTRODUCTION

Endoscopic ultrasound with fine needle aspiration (EUS-FNA) has revolutionized diagnosis, and more recently treatment, of a variety of gastrointestinal conditions accurately and safely. This includes the seemingly ubiquitous pancreatic cystic lesion. The rapid advancement and widespread use of cross-sectional imaging has resulted in more incidentally discovered pancreatic cysts. Recent studies from the United States have estimated an overall prevalence of 2.5%^[1]. Pancreatic cysts may be seen in as many as 14%-20% of magnetic resonance imaging (MRI) studies^[2,3] and in 3% of computed tomography (CT) scans^[4]. The prevalence of these incidental cystic lesions is directly correlated to increasing age^[5]. Internationally, studies have shown steadily increasing rates of detection of pancreatic cysts over the years^[6] and, specifically, intraductal papillary mucinous neoplasms (IPMN)^[7]. In addition to increased frequency, the median size of these incidentally detected lesions has decreased by about half from 3 cm to 1.5 cm over 12 years in a Korean study^[6] and from 4 cm to 2 cm over 5 years in a study from the United States^[8].

This trend of increased discovery of pancreatic cysts is particularly important because specific types of pancreatic cystic lesions have varying potential for malignant transformation^[9]. A study of a large national database estimated the overall prevalence of malignant cysts as 33 in 100000^[1], and recent natural history studies have estimated 1.3%-3.3%^[6,8]. Pancreatic cysts can generally be classified as non-neoplastic, neoplastic and necrosis of solid tumors. Non-neoplastic cysts have no malignant potential; these include pseudocysts, retention cysts, mucinous non-neoplastic cysts, lymphoepithelial cysts and benign epithelial cysts. Two-thirds of pancreatic cysts are cystic neoplasms (Table 1); these include mucinous cysts [mucinous cystic neoplasms (MCN) and intraductal papillary mucinous neoplasms (IPMN)], non-mucinous cysts [serous cystadenoma (SCA)] and solid pseudopapillary neoplasms (SPEN). Mucinous cysts and SPENs are considered premalignant or may harbor malignancy. There is further variability in

malignant potential among the premalignant mucinous subtypes [MCN, branch duct (BD)-IPMN, main duct (MD)-IPMN and mixed/combined IPMN]. Non-mucinous SCAs have little to no malignant potential. Consequently, these different types of cystic lesions require a range of different management strategies, from monitoring to surgical resection, depending on the risk of malignant transformation^[10,11]. Therefore, accurate diagnosis is of the utmost importance.

Initial diagnostic testing usually focuses on radiologic imaging. Following incidental identification of a pancreatic cyst, MRI of the pancreas with magnetic resonance cholangiopancreatography (MRCP) is recommended^[12]. If MRI/MRCP cannot be performed, a pancreatic protocol multidetector (MD) CT should be obtained. MRI/MRCP is preferable as it is better able to evaluate septa, nodules, main pancreatic duct involvement, branch duct involvement, communication with the main pancreatic duct and cyst contents/debris; and is 79%-82% accurate in identifying mucinous cysts^[13-16]. Both CT and MRI predict the presence of malignancy in pancreatic cysts with 73%-79% accuracy^[17]. A recent retrospective study of resected pancreatic cysts noted MRI was 100% accurate for diagnosing mucinous and malignant cysts, although sample size was small (4-7 patients), while CT was 53%-56% accurate^[18].

ROLE OF EUS IN DIAGNOSIS OF PANCREATIC CYSTS

Clinical evaluation, MDCT and MRI may be sufficient to make the diagnosis and guide management when certain pathognomonic and/or characteristic features are present^[9-11,19]. While individual cyst types do have characteristic morphologic features, their actual appearance on imaging studies can be very similar^[20,21]. Clinical and radiologic findings are often indeterminate, making diagnosis and estimating risk of malignancy difficult. A recent study examined the diagnostic utility of EUS and EUS-FNA beyond that of radiology. EUS with or without cyst fluid aspirate analysis [cytology, amylase and carcinoembryonic antigen (CEA)] was more sensitive (76%) than CT or MRI (48% and 34%) for differentiating neoplastic from non-neoplastic cysts^[22]. While these results indicate EUS may be useful in identifying neoplastic cysts, the accuracy of radiologic imaging in this study was far lower than has been demonstrated by others. This study also only applies to resected cysts, which may bias in favor of EUS.

Following initial evaluation it is necessary to decide if a patient requires further diagnostic testing by EUS/EUS-FNA, radiologic surveillance or surgical resection. Patients with symptomatic pancreatic cysts (*e.g.*, pancreatitis) should be evaluated for surgery. In addition, the 2012 International Association of Pancreatology (IAP) guidelines for mucinous cysts

Table 1 Characteristics of common pancreatic cystic lesions

Characteristic	Pseudocyst	SCA	MCN	MD-IPMN ¹	BD-IPMN ¹	SPEN
Male:female	1:1	1:4	Nearly all female	2:1	2:1	1:4
Age (yr)	40-70	60-80	30-50	60-80	60-80	20-30
Location	Any	Any	Body, tail (90%)	Any (head and uncinata 50%)	Any (head and uncinata 50%)	Body, tail (60%)
Imaging features	Unilocular, thick or thin walled	Multilocular, lobulated. Typically microcystic appearance. Central scar	Unilocular, smooth and encapsulated. Septations and peripheral calcifications possible	Diffuse or focal main duct dilation. Fish-mouth papilla with visible mucus	Dilated side branches. Lobular with septations. "Bunch of grapes" appearance	Unilocular, encapsulated with solid and cystic structure. Hemorrhagic components
Communication with main duct	Variable	None	None	Yes	Yes	None
Cytology	Cyst contents	Cuboidal cells. Glycogen (+), PAS (+) and hemosiderin-laden macrophages	Columnar cells. Atypia varies. Mucin (+)	Columnar cells. Atypia varies. Mucin (+)	Columnar cells. Atypia varies. Mucin (+)	Branching papillae and fibrovascular stroma. Vimentin (+), chromogranin (-) and keratin (-)
Amylase (U/L)	> 250	< 250	< 250	> 250	> 250	N/A
CEA (ng/mL)	< 5	< 5	> 192	> 192	> 192	N/A
KRAS mutation	None	None	Yes	Yes	Yes	N/A
Malignant potential	None	Very rare	Yes (6%-27%)	Yes (40%-70%)	Yes (15%-20%)	Yes (2%-15%)
Morphological predictors of malignancy	None	None	> 6 cm, solid component, peripheral nodules or calcifications	Main duct \geq 8 mm, solid component, nodules	\geq 3 cm, solid component, nodules, main duct \geq 1 cm, and suspicious/malignant cytology	None

¹Mixed IPMN have features of both MD and BD-IPMN. SCA: Serous cystadenoma; MCN: Mucinous cystic neoplasm; MD-IPMN: Main duct intraductal papillary mucinous neoplasm; BD-IPMN: Branch duct intraductal papillary mucinous neoplasm; SPEN: Solid pseudopapillary neoplasm; PAS: Periodic acid-Schiff stain; CEA: Carcinoembryonic antigen.

recommends that patients with these "high risk stigmata" for malignancy should undergo surgical evaluation: obstructive jaundice with a cyst located in the pancreatic head, a solid component with post-contrast enhancement, or a main pancreatic duct diameter \geq 10 mm^[23]. Patients suspected of having SPENs should also be referred for surgery. Among asymptomatic patients with incidental cysts, a decision analysis study compared three management strategies: radiologic follow-up, surgery for all surgical candidates and an EUS-directed approach. The most cost-effective approach was to use EUS-FNA to guide the decision to manage the cystic lesion with radiologic follow-up or surgery^[24].

The suggested approach to asymptomatic patients with incidentally discovered cysts is based on cyst size and the presence of features concerning for malignancy (solid component, mural nodule and main pancreatic duct \geq 1 cm) (Figure 1)^[10]. Patients with cysts < 1 cm and no concerning features can be followed with radiologic imaging unless any change (*e.g.*, increased size) is detected, at which point EUS-FNA is warranted. In patients with cysts > 1 cm, further investigation by EUS-FNA would be advised to rule out the presence of concerning features and determine if the cyst is mucinous. In a recent retrospective study of resected cysts > 3 cm, EUS-FNA with cytology and cyst fluid analysis correctly identified mucinous and non-mucinous lesions in 88% of cases^[18]. Even in patients with high risk features or imaging consistent with SPEN where surgery is indicated, evaluation by EUS-

FNA and/or endoscopic retrograde pancreatography may be helpful in confirming risk of malignancy (or malignancy) prior to resection, particularly if the patient is a poor or reluctant surgical candidate. The same study of resected cysts > 3 cm found that 65% of these cysts were benign and that cytology, cyst fluid CEA and amylase had a negative predictive value of 94.1% for malignancy, which may allow conservative management in high-risk surgical candidates^[18].

Among the mucinous lesions, MCN and IPMN can often be difficult to distinguish. In cases where these two types are lesions are suspected, the 2012 IAP guidelines recommend EUS in patients who present with pancreatitis or "worrisome features" (size \geq 3 cm, thick enhancing wall, non-enhancing nodule, main pancreatic duct diameter 5-9 mm, abrupt change in duct diameter with distal gland atrophy and lymphadenopathy)^[23]. In these cases EUS should be used to confirm nodules, main duct involvement and cytological atypia with FNA. Surgery is indicated if any of these three features are confirmed. In cases where these features are absent, close surveillance of cysts > 2 cm by EUS and MRI is recommended. Alternatively, surgery may be considered in a young otherwise healthy person who would require prolonged monitoring. When initial EUS is inconclusive, cysts should be closely monitored with EUS and MRI^[23].

EUS MORPHOLOGY

EUS is a minimally invasive procedure allowing high

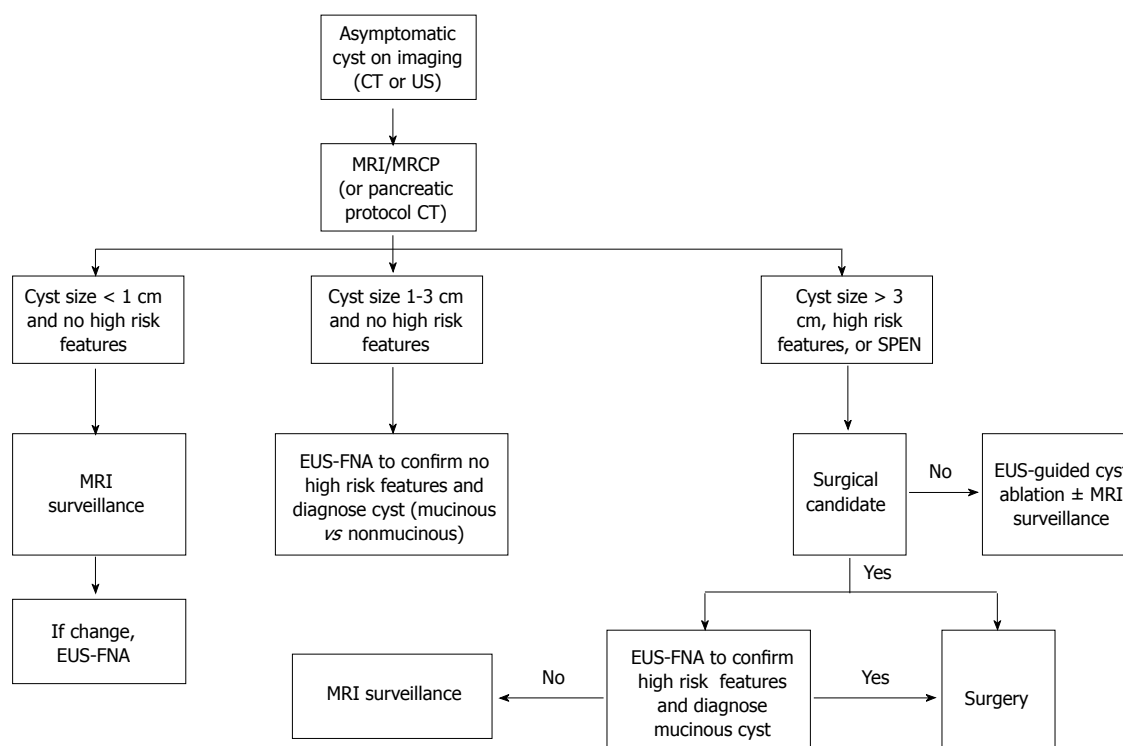


Figure 1 Approach using endoscopic ultrasound in the diagnosis of asymptomatic pancreatic cystic lesions. CT: Computed tomography; EUS: Endoscopic ultrasound; EUS-FNA: Endoscopic ultrasound-guided fine needle aspiration; MRCP: Magnetic resonance cholangiography; MRI: Magnetic resonance imaging; SPEN: Solid pseudopapillary neoplasm; US: Ultrasound.

Table 2 Endoscopic ultrasound features suggestive of mucinous or malignant cysts

EUS Feature	Type of cyst	Concerning for increased risk of malignancy
Size	-	> 3 cm
Shape	Smooth unilocular: pseudocyst or MCN Lobular, multilocular: SCA or BD-IPMN	-
Number of cysts	Multiple: BD-IPMN	-
Calcifications	Central scar: pathognomonic for SCA Peripheral calcification: pseudocyst, SPEN, MCN	Peripheral calcification in MCN
Cyst wall	Thick: pseudocyst, cystic neuroendocrine, MCN, SPEN	Thick
Septa	-	Thick
Nodule	-	Presence
Solid mass	-	Presence
Debris	Pseudocyst	-
Pancreatic duct diameter	Dilated > 5 mm: MD-IPMN or mixed IPMN	Dilated > 8-10 mm
Communication with pancreatic duct	IPMN, pseudocyst	-

EUS: Endoscopic ultrasound; MCN: Mucinous cystic neoplasm; SCA: Serous cystadenoma; BD-IPMN: Branch duct intraductal papillary mucinous neoplasm; MD-IPMN: Main duct intraductal papillary mucinous neoplasm; SPEN: Solid pseudopapillary neoplasm; IPMN: Intraductal papillary mucinous neoplasm.

resolution diagnostic evaluation of the pancreatic parenchyma and ductal system. A linear echoendoscope should be used to evaluate pancreatic cystic lesions as FNA may be performed. EUS is particularly valuable in assessing diagnostic features and potential predictors of malignancy, including size, shape (lobular vs smooth contour), number of cysts, calcifications, cyst wall structure (thick vs thin wall), septa, nodules, solid masses associated with the cyst, pancreatic duct diameter, communication with the pancreatic duct, and lymphadenopathy (Table 2, Figures 2A-G). In a study of 50 patients EUS was found to be comparable

to MRI in its sensitivity for identifying septa (77.8%), mural nodules (58.3%), main duct dilation (85.7%) and communication with the pancreatic duct (88.9%)^[17].

Nodules are an important predictor of malignancy, but may be difficult to distinguish from mucus. Mucus appears as a hypoechoic lesion relative to adjacent tissue with a smooth, hyperechoic rim (Figure 2H). On the other hand, nodules are iso- or hyperechoic compared to adjacent tissue without a hyperechoic rim or smooth edge (Figure 2I). During EUS, rotating the patient and trying to move the lesion with a FNA needle can also help to differentiate mucus from a

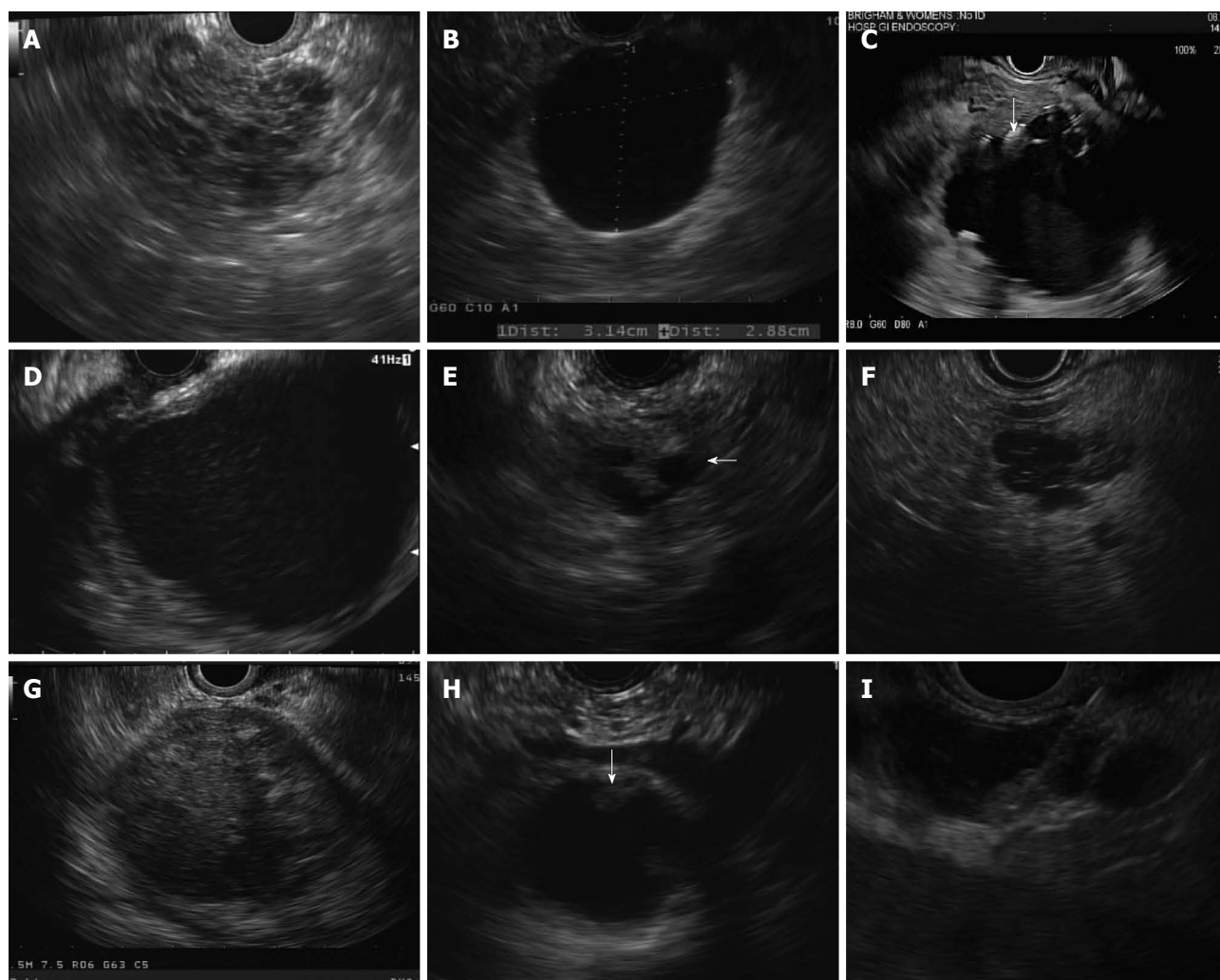


Figure 2 Endoscopic ultrasound imaging. A: A lobular microcystic lesion consistent with serous cystadenoma; B: A smooth, unilocular, thin walled cyst consistent with mucinous cystic neoplasm; C: A cyst with peripheral calcification (arrow) and debris layering at the bottom of the cyst consistent with pseudocyst; D: A thick walled cyst filled with debris representing walled-off pancreatic necrosis; E: A cyst communicating with a nondilated main pancreatic duct (arrow) representing branch duct intraductal papillary mucinous neoplasm; F: A multiseptated lobular cyst appearing like a “cluster of grapes” consistent with branch duct intraductal papillary mucinous neoplasm; G: A well-defined heterogeneous mass-like lesion with hyperechoic foci and small anechoic focus diagnosed as solid pseudopapillary neoplasm on cytology; H: A unilocular cyst with mucus (arrow) appearing hypoechoic relative to the adjacent pancreatic parenchyma with a smooth hyperechoic rim; I: Endoscopic ultrasound-guided fine needle aspiration of a nodule which appears isoechoic with pancreatic parenchyma without a hyperechoic rim within a dilated main pancreatic duct. Cytology showed adenocarcinoma.

nodules. A pathology-based study of MCN and BD-IPMN confirmed the modest diagnostic accuracy of EUS for a nodule (57%)^[25]. However, after training endosonographers in the above EUS criteria for differentiating a nodule from mucus, accuracy improved to 79%. The sensitivity and specificity of EUS (75% and 83%) were superior to CT (24% and 100%) for nodules^[25], and likely surpasses diagnostic yield of MRI as well when using these defined criteria. In addition, EUS is superior to CT and potentially MRI for detecting small pancreatic masses^[26,27]. EUS demonstrated 98% sensitivity compared with 86% for MDCT for identifying pancreatic masses^[26]. Data comparing EUS and MRI is limited with an older study supporting higher sensitivity for EUS. More studies are needed using the newer MRI machines.

A recent multicenter study from Korea examined 84

resected BD-IPMNs in order to evaluate EUS predictors of malignancy in BD-IPMNs^[28]. An EUS scoring system (0-10) was developed in which points were assigned based on cyst size, mural nodules, pancreatic duct dilation, thick septa and the characteristic “patulous” papilla^[28]. This scoring system was found to have an overall area under the curve of 0.944 with 75% sensitivity and 94% specificity for malignant BD-IPMN using an EUS score cutoff of ≥ 7 . In their data, this EUS score was more specific than the 2012 IAP criteria (16%) and mural nodules alone (46%), but less sensitive (2012 IAP criteria 100% and mural nodules 94%).

Despite the utility of EUS imaging in diagnostic evaluation and estimating malignant potential of pancreatic cysts, EUS alone is not adequate for diagnosis of pancreatic cysts. A multicenter trial

Table 3 Endoscopic ultrasound-fine needle aspiration cyst fluid analysis

Cyst fluid marker	Type of cyst	Sensitivity	Specificity
CEA < 5 ng/mL	SCA, pseudocyst, neuroendocrine tumor	54%	94%
CEA >192 ng/mL	Mucinous cyst (MCN or IPMN)	73%	84%
CEA > 800 ng/mL	Mucinous cyst (MCN or IPMN)	98%	48%
Amylase < 250 U/L	Excludes pseudocyst	44%	98%
KRAS mutation + LOH	Malignant cyst	37%	96%
KRAS mutation	Mucinous cyst (MCN or IPMN)	54%	100%

CEA: Carcinoembryonic antigen; SCA: Serous cystadenoma; MCN: Mucinous cystic neoplasm; IPMN: Intraductal papillary mucinous neoplasm; LOH: Loss of heterozygosity.

of 341 patients found EUS morphology to be only 56% sensitive and 45% specific (51% accurate) in distinguishing mucinous from non-mucinous cysts^[29]. Furthermore, EUS performance is highly operator dependent. Agreement among expert endosonographers (performed > 1000 pancreas EUS) was better than semi-experts (performed 50-200 pancreas EUS) in a Dutch study^[30]. However, even among expert endosonographers, interobserver agreement was fair to moderate in distinguishing mucinous and non-mucinous cysts [intraclass correlation coefficient (ICC) = 0.43]^[30,31]. There was good agreement among experts for nodules (ICC 0.65); moderate for solid component (ICC = 0.52) and communication between cyst and main duct (ICC = 0.44); and fair for suspected malignancy (ICC = 0.27)^[30]. An earlier study of 31 cases found only fair interobserver agreement (κ = 0.24) among 8 endosonographers at tertiary care referral centers for distinguishing neoplastic from non-neoplastic lesions by EUS, with accuracy ranging from 40%-93%^[31].

EUS-FNA

Due to the limitations of imaging alone, diagnosing pancreatic cysts requires a combination of diagnostic imaging and cyst fluid analysis. Under EUS-guidance, FNA can safely obtain cyst fluid for cytologic and molecular analysis^[32]. Cysts should be at least 1 cm in size to obtain sufficient fluid for analyses. The general technique of EUS-FNA of pancreatic cysts is similar to FNA of solid lesions with a few differences to minimize complications. Cyst fluid is usually aspirated with a single pass using a 22 or 25-gauge aspiration needle with the goal of completely collapsing the cyst. Occasionally 19-gauge aspiration needles can be advanced into larger cysts with thick fluid although these larger needles are difficult to use in the pancreatic head or uncinata process. A dose of prophylactic intravenous antibiotics (usually fluoroquinolone) is recommended followed by 3 d of oral antibiotic to prevent infection from cyst aspiration^[33].

Before sending the cyst fluid for testing, visual inspection of the fluid may offer diagnostic clues. Fluid viscosity may be evaluated by the "string sign": a drop of fluid is placed between the thumb and first finger and slowly pulled apart. If the fluid stretches

out at least 3.5 mm, this is consistent with a mucinous cyst^[34]. SCAs typically have thin, serosanguinous or frankly bloody fluid while pseudocyst fluid appears cola-colored and fluid from lymphangiomas may look like milk.

Cyst fluid aspirates are often virtually acellular and consequently cytology has generally limited utility (< 50% sensitive) in diagnosing mucinous lesions^[29,35,36]. Exceptions include cyst fluid cytology of cystic neuroendocrine tumors, SPENs, and lymphangiomas where diagnostic yield may be higher^[37-41]. Specifically targeting the cyst wall during aspiration has been shown to increase the diagnostic yield of cytology for mucinous lesions by 29% compared to fluid cytology^[42]. This is a simple technique whereupon after cyst fluid is aspirated and the cyst wall collapsed, the needle is advanced back and forth through the wall several times, and the tissue sent for cytology. A core biopsy needle may increase diagnostic yield from pancreatic cysts without increased complications. A study of 60 cysts biopsied using the 22 gauge Procore Echotip biopsy needle (Cook Medical, Ireland) reported a 65% sample adequacy rate and 100% concordance between biopsy diagnosis and surgical pathology (available in 28% of the patients) with only minor complications in 3.3% of patients^[43]. Further studies are needed to compare fine needle biopsy with fine needle aspiration. In order to further improve diagnostic yield and accuracy, FNA should also target mural nodules and/or solid components when present.

Chemical analysis of cyst fluid usually measures carcinoembryonic antigen (CEA) and amylase concentrations (Table 3). Amylase below 250 U/L can rule out a pseudocyst with 98% specificity^[44]. Usually, although not always, amylase is lower in SCA. Typically amylase levels are higher in IPMN than MCN although they can be similar as well. CEA is the main biomarker used to determine if a cyst is mucinous. CEA > 192 ng/mL is 73% sensitive, 84% specific, and 79% accurate for mucinous lesions from the classic study by Brugge *et al.*^[29]. The exact threshold used for diagnosing mucinous cysts remains debated with higher levels yielding greater specificity but lower sensitivity. For example, CEA > 800 ng/mL is 98% specific but only 48% sensitive for mucinous cysts, which means that cysts with elevated CEA are almost always mucinous while many mucinous cysts with CEA < 800 will be missed^[44].

Conversely, low CEA < 5 ng/mL is 95% specific for SCA, pseudocyst, or neuroendocrine tumor^[44]. Cyst fluid CEA is not predictive of malignancy^[45]. It is important to note that currently available assays are validated for measuring serum, but not cyst fluid, CEA concentrations. Consequently, there is as much as 85% variation in mean cyst fluid CEA concentrations among the various assays^[46].

Molecular analysis of aspirated cyst fluid for DNA mutations may help to distinguish mucinous from non-mucinous cysts. A study including 142 surgically resected cysts found that KRAS mutation was 54% sensitive and 100% specific for mucinous cysts^[47]. Specifically, KRAS mutations were 67% sensitive for IPMNs but only 14% sensitive for MCN. Using a combination of CEA and KRAS improved sensitivity for mucinous lesions to 83% but specificity dropped to 85%^[47]. On the other hand, a smaller study of 48 resected cysts reported that combining KRAS, CEA and cytology did not improve accuracy compared to CEA and cytology or KRAS alone^[48]. Two or more loss of heterozygosity (LOH) mutations and DNA quantity > 40 ng/ μ L were each less than 11% sensitive for mucinous cysts. However, the presence of any molecular changes (KRAS, LOH or elevated DNA quantity) was over 90% specific for mucinous cysts. Consequently, the utility of DNA analysis may be limited to patients whose evaluation is indeterminate for a mucinous cyst.

The multicenter pathology-based PANDA study suggested that KRAS followed by LOH mutations could diagnose malignant cysts with 96% specificity and 37% sensitivity^[49]. Our group evaluated the diagnostic accuracy for malignant cysts of the 2006 and 2012 IAP guidelines and commercially available DNA analyses (KRAS, LOH mutations, and DNA quantity) in 257 pancreatic cysts^[50]. The 2012 guidelines were the most accurate for malignant cysts (90% specificity and 88% sensitivity). The addition of DNA mutation analysis contributed no significant improvement in diagnostic performance. To date, studies of commercial DNA analyses have not been able to clearly define their role in clinical practice^[49-53].

Current cyst fluid analyses are unable to consistently differentiate specific cyst types or predict malignant potential^[20,54]. Consequently, differentiating benign from pre-malignant cystic lesions remains challenging. Recent studies have found that the preoperative diagnostic accuracy for specific cyst type ranged from 47% to 68% compared to surgical pathology^[55,56]; accuracy improved to 73% when cysts were categorized as benign, premalignant and malignant^[56]. A retrospective study of 118 patients in a community setting suggested a higher accuracy for EUS (87%) in distinguishing benign, premalignant, and malignant cysts; however, this study is limited because 65% of patients were diagnosed mainly by CT radiologic surveillance with a median follow-up of only 337 d^[57].

Therefore, in light of the limitations of current diagnostic tools, novel diagnostic biomarkers have received considerable interest^[58]. GNAS mutations have been associated with IPMNs in resected tissue, cyst aspirates and pancreas fluid^[59,60]. The combination of GNAS and KRAS mutations in aspirated cyst fluid has been shown to be specific and sensitive for IPMN^[61]. Our own study (accepted for publication) on resected cysts found GNAS mutations to be significantly more prevalent in IPMNs (42%) than in SCAs (10%), adenocarcinomas (0%) and MCNs (0%). In addition, double mutations in KRAS and GNAS only occurred in IPMNs ($P = 0.006$). A recent study of genetic mutations in cyst fluid aspirated by EUS-FNA from 91 cysts found that GNAS mutations occurred in 39% of IPMNs and 22% of IPMNs with adenocarcinoma while KRAS mutations were present in 68% and 78%, respectively^[61]. Notably, mutations in either GNAS or KRAS occurred in 83% of IPMNs, 89% of IPMNs with cancer and 6% of MCNs, and no mutations found in PNETs, SCAs and non-neoplastic cysts^[61]. The combination of GNAS and KRAS was 98% specific and 84% sensitive for IPMN. Poor sensitivity for MCNs, as in other mutation studies, resulted in only 65% sensitivity for mucinous lesions overall. Neither gene was predictive of malignant potential within mucinous lesions.

MicroRNA (miRNA) are small noncoding RNA which may help diagnose a variety of malignancies and potentially pancreatic cystic lesions as well^[62]. We evaluated miRNA in 69 pathology specimens of pancreatic cystic neoplasms, and identified several miRNA panels (4 miRNA in each) that differentiated SCAs from MCNs and IPMNs, and MCNs from BD-IPMNs (sensitivity 85%-100% and specificity 100%)^[63]. These promising miRNA panels now need to be validated in EUS-FNA cyst fluid aspirates obtained during diagnostic evaluation. A recent study of the cyst fluid proteome demonstrated that proteomic profiling of mucin in cyst fluid (obtained by EUS-FNA) was 98% accurate for pre-malignant and malignant cysts^[64]. A study of select proteins in 22 cyst fluid samples identified a 3 biomarker panel of protein glycoforms that was 91% accurate for mucinous cysts^[65]. Metabolomic analysis has demonstrated that metabolites, glucose and kynurenine, were lower in mucinous cysts compared to non-mucinous cysts^[66]. These molecular biomarkers may be able to provide improved diagnostic accuracy while requiring only small amounts of fluid, particularly as the number of small cysts identified by imaging continues to increase.

EUS-GUIDED THERAPY

For patients with pancreatic cystic neoplasms that are symptomatic, malignant, or have a high potential for malignant transformation, the current standard of care is surgery. Pancreatic surgical resections are major procedures associated with a high complication

rate (> 40%)^[67,68] and long-term morbidity due to loss of pancreatic tissue (*i.e.*, diabetes and exocrine insufficiency). EUS-guided therapies may provide a minimally invasive alternative to surgery in poor or reluctant surgical candidates and a low-risk intervention in cases where conservative management is unsatisfactory because malignant potential is uncertain.

To date ethanol (80%-98%) and paclitaxel have been investigated as ablative agents in pancreatic cysts. Ethanol has effectively destroyed solid and cystic tumors in a number of organs, and elicits better response in pancreatic cysts than saline^[69]. Ethanol lavage is believed to induce cell membrane breakdown, rapid protein degradation and vascular blockage^[70,71]. Paclitaxel is a commonly used chemotherapeutic agent which stabilizes the microtubule polymer to inhibit its disassembly and consequently induce apoptosis. Its hydrophobic and viscous nature allows it to exert a long-lasting effect on the epithelial lining of the cyst while posing little risk of leakage^[72].

Prospective studies evaluating EUS-guided pancreatic cyst ablation have shown cyst resolution (no visible residual cyst on cross-sectional imaging) in 33%-38% of patients using ethanol alone^[69,73,74]. Injection of paclitaxel produced improved response with 60%-79% cyst resolution (< 5% of original size on CT follow-up)^[75-77]. Long term follow-up of 9 patients who achieved resolution after ethanol lavage found that cyst resolution persisted in all patients over a median 26 mo follow-up (range 13-39 mo)^[78]. In 22 patients undergoing EUS-guided ablation with ethanol and paclitaxel, 75% of patients demonstrated at least a 75% reduction in cyst volume (complete cyst resolution in 50% of patients) over a mean 27 mo follow-up (range 17-42 mo), and elimination of pre-operatively detected DNA mutations in LOH and KRAS in 36% of patients^[79]. Although this may suggest that ablation leads to DNA changes that decrease risk of malignant progression, this has yet to be proven and new mutations were actually detected in 3 patients.

The technique of EUS-guided pancreatic cyst ablation uses a curvilinear-array echoendoscope. Following cyst puncture with a 22-gauge needle, a syringe is used to completely aspirate cyst fluid, similar to when performing standard EUS-FNA of a pancreatic cyst. Complete evacuation of highly viscous fluid may not be possible, and saline injection (0.5-1.0 cc) may help thin the fluid to achieve this^[80]. Without removing the needle, the cyst cavity is then injected with ethanol, equal in volume to the aspirated cyst fluid. For 5 min, the cyst cavity is repeatedly evacuated and injected. This involves 3-4 lavages over the 5 min when cyst fluid is thick, or 7-8 lavages if the fluid is thin. The ethanol is then completely removed. If used, paclitaxel is then injected into the cyst but not removed. At no point should the cyst be expanded beyond its original size. Care should be taken to ensure that the needle tip remains within the

cyst during the whole procedure to avoid injury to the pancreatic parenchyma and leaks in the cyst wall^[80-82].

Ideally, cysts considered amenable to ablation should be benign with no malignant features, 2-4 cm in diameter, uni/oligolocular, and demonstrate no connection with the pancreatic duct. Cysts consistent with MD-IPMN or features suggestive of malignancy should not undergo ablation. Patients with active pancreatitis, ascites, portal hypertension or coagulopathy are also excluded from cyst ablation.

Cyst ablation has been overall well tolerated although complication rates are higher than for EUS-FNA of pancreatic cysts. The most common acute complication is non-specific post-procedure abdominal pain (2%-20%)^[69,73-77,79]. Pancreatitis rates range between 2%-10% with no reports of severe pancreatitis, while other less common adverse events include chemical peritonitis with ileus in 3%, gastric wall cyst in 3%, and intracystic bleeding in 2% of cases.

While promising, this procedure is still being studied as concerns about remnant premalignant epithelium, unclear effects on the natural history of cysts, and uncertainty over long term monitoring and outcomes remain^[9,78,82].

CONCLUSION

The increasing number of incidentally discovered pancreatic cystic lesions, and their varying potential for malignant transformation, makes accurate diagnosis and choosing appropriate management strategies vitally important. Under current guidelines, EUS and EUS-FNA are critical components in the approach to evaluating and monitoring these lesions. EUS-FNA may provide additional information when the diagnosis is unclear, confirm the presence/absence of features associated with increased risk of malignancy, diagnose malignancy, and monitor for changes in the cysts. Even so, diagnosis remains challenging as current radiologic imaging modalities and EUS-FNA have proven to be limited in diagnostic accuracy. Promising research into new imaging, chemical and molecular biomarkers, as well as EUS-guided therapies may be able to improve diagnosis and management of pancreatic cystic lesions.

REFERENCES

- 1 **Gardner TB**, Glass LM, Smith KD, Ripple GH, Barth RJ, Klibansky DA, Colacchio TA, Tsapakos MJ, Suriawinata AA, Tsongalis GJ, Pipas JM, Gordon SR. Pancreatic cyst prevalence and the risk of mucin-producing adenocarcinoma in US adults. *Am J Gastroenterol* 2013; **108**: 1546-1550 [PMID: 24091499 DOI: 10.1038/ajg.2013.103]
- 2 **Zhang XM**, Mitchell DG, Dohke M, Holland GA, Parker L. Pancreatic cysts: depiction on single-shot fast spin-echo MR images. *Radiology* 2002; **223**: 547-553 [PMID: 11997566 DOI: 10.1148/radiol.2232010815]
- 3 **Lee KS**, Sekhar A, Rofsky NM, Pedrosa I. Prevalence of incidental pancreatic cysts in the adult population on MR imaging. *Am J*

- Gastroenterol* 2010; **105**: 2079-2084 [PMID: 20354507 DOI: 10.1038/ajg.2010.122]
- 4 **Laffan TA**, Horton KM, Klein AP, Berlanstein B, Siegelman SS, Kawamoto S, Johnson PT, Fishman EK, Hruban RH. Prevalence of unsuspected pancreatic cysts on MDCT. *AJR Am J Roentgenol* 2008; **191**: 802-807 [PMID: 18716113 DOI: 10.2214/AJR.07.3340]
 - 5 **de Jong K**, Bruno MJ, Fockens P. Epidemiology, diagnosis, and management of cystic lesions of the pancreas. *Gastroenterol Res Pract* 2012; **2012**: 147465 [PMID: 22007199 DOI: 10.1155/2012/147465]
 - 6 **Chung JW**, Chung MJ, Park JY, Bang S, Song SY, Chung JB, Park SW. Clinicopathologic features and outcomes of pancreatic cysts during a 12-year period. *Pancreas* 2013; **42**: 230-238 [PMID: 23146922 DOI: 10.1097/MPA.0b013e31826ae31a]
 - 7 **Klibansky DA**, Reid-Lombardo KM, Gordon SR, Gardner TB. The clinical relevance of the increasing incidence of intraductal papillary mucinous neoplasm. *Clin Gastroenterol Hepatol* 2012; **10**: 555-558 [PMID: 22210438 DOI: 10.1016/j.cgh.2011.12.029]
 - 8 **Morris-Stiff G**, Falk GA, Chalikhonda S, Walsh RM. Natural history of asymptomatic pancreatic cystic neoplasms. *HPB (Oxford)* 2013; **15**: 175-181 [PMID: 23374357 DOI: 10.1111/j.1477-2574.2012.00522.x]
 - 9 **Farrell JJ**, Fernández-del Castillo C. Pancreatic cystic neoplasms: management and unanswered questions. *Gastroenterology* 2013; **144**: 1303-1315 [PMID: 23622140 DOI: 10.1053/j.gastro.2013.01.073]
 - 10 **Lee LS**. Incidental Cystic Lesions in the Pancreas: Resect? EUS? Follow? *Curr Treat Options Gastroenterol* 2014; **12**: 333-349 [PMID: 24903582 DOI: 10.1007/s11938-014-0019-6]
 - 11 **Sahani DV**, Kambadakone A, Macari M, Takahashi N, Chari S, Fernandez-del Castillo C. Diagnosis and management of cystic pancreatic lesions. *AJR Am J Roentgenol* 2013; **200**: 343-354 [PMID: 23345356 DOI: 10.2214/AJR.12.8862]
 - 12 **Berland LL**. The American College of Radiology strategy for managing incidental findings on abdominal computed tomography. *Radiol Clin North Am* 2011; **49**: 237-243 [PMID: 21333775 DOI: 10.1016/j.rcl.2010.10.003]
 - 13 **Berland LL**, Silverman SG, Gore RM, Mayo-Smith WW, Megibow AJ, Yee J, Brink JA, Baker ME, Federle MP, Foley WD, Francis IR, Herts BR, Israel GM, Krinsky G, Platt JF, Shuman WP, Taylor AJ. Managing incidental findings on abdominal CT: white paper of the ACR incidental findings committee. *J Am Coll Radiol* 2010; **7**: 754-773 [PMID: 20889105 DOI: 10.1016/j.jacr.2010.06.013]
 - 14 **Waters JA**, Schmidt CM, Pinchot JW, White PB, Cummings OW, Pitt HA, Sandrasegaran K, Akisik F, Howard TJ, Nakeeb A, Zyromski NJ, Lillemoie KD. CT vs MRCP: optimal classification of IPMN type and extent. *J Gastrointest Surg* 2008; **12**: 101-109 [PMID: 17917784 DOI: 10.1007/s11605-007-0367-9]
 - 15 **Macari M**, Finn ME, Bennett GL, Cho KC, Newman E, Hajdu CH, Babb JS. Differentiating pancreatic cystic neoplasms from pancreatic pseudocysts at MR imaging: value of perceived internal debris. *Radiology* 2009; **251**: 77-84 [PMID: 19332847 DOI: 10.1148/radiol.2511081286]
 - 16 **Sainani NI**, Saokar A, Deshpande V, Fernández-del Castillo C, Hahn P, Sahani DV. Comparative performance of MDCT and MRI with MR cholangiopancreatography in characterizing small pancreatic cysts. *AJR Am J Roentgenol* 2009; **193**: 722-731 [PMID: 19696285 DOI: 10.2214/AJR.08.1253]
 - 17 **Kim YC**, Choi JY, Chung YE, Bang S, Kim MJ, Park MS, Kim KW. Comparison of MRI and endoscopic ultrasound in the characterization of pancreatic cystic lesions. *AJR Am J Roentgenol* 2010; **195**: 947-952 [PMID: 20858823 DOI: 10.2214/AJR.09.3985]
 - 18 **Chehib I**, Yaeger K, Mino-Kenudson M, Pitman MB. The role of cytopathology and cyst fluid analysis in the preoperative diagnosis and management of pancreatic cysts > 3 cm. *Cancer Cytopathol* 2014; **122**: 804-809 [PMID: 25044974 DOI: 10.1002/cncy.21460]
 - 19 **Yoon WJ**, Brugge WR. Endoscopic ultrasound and pancreatic cystic lesions-diagnostic and therapeutic applications. *Endosc Ultrasound* 2012; **1**: 75-79 [PMID: 24949341 DOI: 10.7178/eus.02.004]
 - 20 **Al-Haddad M**, Schmidt MC, Sandrasegaran K, Dewitt J. Diagnosis and treatment of cystic pancreatic tumors. *Clin Gastroenterol Hepatol* 2011; **9**: 635-648 [PMID: 21397725 DOI: 10.1016/j.cgh.2011.03.005]
 - 21 **Khalid A**, Brugge W. ACG practice guidelines for the diagnosis and management of neoplastic pancreatic cysts. *Am J Gastroenterol* 2007; **102**: 2339-2349 [PMID: 17764489 DOI: 10.1111/j.1572-0241.2007.01516.x]
 - 22 **Khashab MA**, Kim K, Lennon AM, Shin EJ, Tignor AS, Amateau SK, Singh VK, Wolfgang CL, Hruban RH, Canto MI. Should we do EUS/FNA on patients with pancreatic cysts? The incremental diagnostic yield of EUS over CT/MRI for prediction of cystic neoplasms. *Pancreas* 2013; **42**: 717-721 [PMID: 23558241 DOI: 10.1097/MPA.0b013e3182883a91]
 - 23 **Tanaka M**, Fernández-del Castillo C, Adsay V, Chari S, Falconi M, Jang JY, Kimura W, Levy P, Pitman MB, Schmidt CM, Shimizu M, Wolfgang CL, Yamaguchi K, Yamao K. International consensus guidelines 2012 for the management of IPMN and MCN of the pancreas. *Pancreatol* 2012; **12**: 183-197 [PMID: 22687371 DOI: 10.1016/j.pan.2012.04.004]
 - 24 **Das A**, Ngamruengphong S, Nagendra S, Chak A. Asymptomatic pancreatic cystic neoplasm: a cost-effectiveness analysis of different strategies of management. *Gastrointest Endosc* 2009; **70**: 690-699.e6 [PMID: 19647240 DOI: 10.1016/j.gie.2009.02.013]
 - 25 **Zhong N**, Zhang L, Takahashi N, Shalmiyev V, Canto MI, Clain JE, Deutsch JC, DeWitt J, Eloubeidi MA, Gleeson FC, Levy MJ, Mallery S, Raimondo M, Rajan E, Stevens T, Topazian M. Histologic and imaging features of mural nodules in mucinous pancreatic cysts. *Clin Gastroenterol Hepatol* 2012; **10**: 192-198 [PMID: 21982970 DOI: 10.1016/j.cgh.2011.09.029]
 - 26 **DeWitt J**, Devereaux B, Chriswell M, McGreevy K, Howard T, Imperiale TF, Ciaccia D, Lane KA, Maglinte D, Kopecky K, LeBlanc J, McHenry L, Madura J, Aisen A, Cramer H, Cummings O, Sherman S. Comparison of endoscopic ultrasonography and multidetector computed tomography for detecting and staging pancreatic cancer. *Ann Intern Med* 2004; **141**: 753-763 [PMID: 15545675 DOI: 10.7326/0003-4819-141-10-200411160-00006]
 - 27 **Rösch T**, Lorenz R, Braig C, Feuerbach S, Siewert JR, Schusdziarra V, Classen M. Endoscopic ultrasound in pancreatic tumor diagnosis. *Gastrointest Endosc* 1991; **37**: 347-352 [PMID: 2070987 DOI: 10.1016/S0016-5107(91)70729-3]
 - 28 **Lee KH**, Lee SJ, Lee JK, Ryu JK, Kim EY, Kim TH, Moon JH, Lee WJ, Cho YK, Kim JJ. Prediction of malignancy with endoscopic ultrasonography in patients with branch duct-type intraductal papillary mucinous neoplasm. *Pancreas* 2014; **43**: 1306-1311 [PMID: 25036913 DOI: 10.1097/MPA.000000000000177]
 - 29 **Brugge WR**, Lewandrowski K, Lee-Lewandrowski E, Centeno BA, Szydlot T, Regan S, del Castillo CF, Warsaw AL. Diagnosis of pancreatic cystic neoplasms: a report of the cooperative pancreatic cyst study. *Gastroenterology* 2004; **126**: 1330-1336 [PMID: 15131794 DOI: 10.1053/j.gastro.2004.02.013]
 - 30 **de Jong K**, Verlaan T, Dijkgraaf MG, Poley JW, van Dullemen H, Bruno MJ, Fockens P. Interobserver agreement for endosonography in the diagnosis of pancreatic cysts. *Endoscopy* 2011; **43**: 579-584 [PMID: 21717378 DOI: 10.1055/s-0030-1256434]
 - 31 **Ahmad NA**, Kochman ML, Brensinger C, Brugge WR, Faigel DO, Gress FG, Kimmey MB, Nickl NJ, Savides TJ, Wallace MB, Wiersema MJ, Ginsberg GG. Interobserver agreement among endosonographers for the diagnosis of neoplastic versus non-neoplastic pancreatic cystic lesions. *Gastrointest Endosc* 2003; **58**: 59-64 [PMID: 12838222 DOI: 10.1067/mge.2003.298]
 - 32 **Lee LS**, Saltzman JR, Bounds BC, Poneris JM, Brugge WR, Thompson CC. EUS-guided fine needle aspiration of pancreatic cysts: a retrospective analysis of complications and their predictors. *Clin Gastroenterol Hepatol* 2005; **3**: 231-236 [PMID: 15765442 DOI: 10.1016/S1542-3565(04)00618-4]
 - 33 **Banerjee S**, Shen B, Baron TH, Nelson DB, Anderson MA, Cash BD, Dominitz JA, Gan SI, Harrison ME, Ikenberry SO,

- Jagannath SB, Lichtenstein D, Fanelli RD, Lee K, van Guilder T, Stewart LE. Antibiotic prophylaxis for GI endoscopy. *Gastrointest Endosc* 2008; **67**: 791-798 [PMID: 18374919 DOI: 10.1016/j.gie.2008.02.068]
- 34 **Layfield LJ**, Ehya H, Filie AC, Hruban RH, Jhala N, Joseph L, Vielh P, Pitman MB. Utilization of ancillary studies in the cytologic diagnosis of biliary and pancreatic lesions: the Papanicolaou Society of Cytopathology guidelines for pancreatobiliary cytology. *Diagn Cytopathol* 2014; **42**: 351-362 [PMID: 24639398 DOI: 10.1002/dc.23093]
- 35 **Maker AV**, Lee LS, Raut CP, Clancy TE, Swanson RS. Cytology from pancreatic cysts has marginal utility in surgical decision-making. *Ann Surg Oncol* 2008; **15**: 3187-3192 [PMID: 18766406 DOI: 10.1245/s10434-008-0110-0]
- 36 **Attasaranya S**, Pais S, LeBlanc J, McHenry L, Sherman S, DeWitt JM. Endoscopic ultrasound-guided fine needle aspiration and cyst fluid analysis for pancreatic cysts. *JOP* 2007; **8**: 553-563 [PMID: 17873459]
- 37 **Law JK**, Ahmed A, Singh VK, Akshintala VS, Olson MT, Raman SP, Ali SZ, Fishman EK, Kamel I, Canto MI, Dal Molin M, Moran RA, Khashab MA, Ahuja N, Goggins M, Hruban RH, Wolfgang CL, Lennon AM. A systematic review of solid-pseudopapillary neoplasms: are these rare lesions? *Pancreas* 2014; **43**: 331-337 [PMID: 24622060 DOI: 10.1097/MPA.0000000000000061]
- 38 **Jani N**, Dewitt J, Eloubeidi M, Varadarajulu S, Appalaneeni V, Hoffman B, Brugge WR, Lee K, Khalid A, McGrath K. Endoscopic ultrasound-guided fine-needle aspiration for diagnosis of solid pseudopapillary tumors of the pancreas: a multicenter experience. *Endoscopy* 2008; **40**: 200-203 [PMID: 18067066 DOI: 10.1055/s-2007-995364]
- 39 **Lee LS**. Diagnosis of pancreatic neuroendocrine tumors and the role of endoscopic ultrasound. *Gastroenterol Hepatol (N Y)* 2010; **6**: 520-522 [PMID: 20978556]
- 40 **Fonseca R**, Pitman MB. Lymphangioma of the pancreas: a multimodal approach to pre-operative diagnosis. *Cytopathology* 2013; **24**: 172-176 [PMID: 21810124 DOI: 10.1111/j.1365-2303.2011.00897.x]
- 41 **Morales-Oyarvide V**, Yoon WJ, Ingkakul T, Forcione DG, Casey BW, Brugge WR, Fernández-del Castillo C, Pitman MB. Cystic pancreatic neuroendocrine tumors: the value of cytology in preoperative diagnosis. *Cancer Cytopathol* 2014; **122**: 435-444 [PMID: 24591417 DOI: 10.1002/cncy.21403]
- 42 **Hong SK**, Loren DE, Rogart JN, Siddiqui AA, Sendecki JA, Bibbo M, Coben RM, Meckes DP, Kowalski TE. Targeted cyst wall puncture and aspiration during EUS-FNA increases the diagnostic yield of premalignant and malignant pancreatic cysts. *Gastrointest Endosc* 2012; **75**: 775-782 [PMID: 22317883 DOI: 10.1016/j.gie.2011.12.015]
- 43 **Barresi L**, Tarantino I, Traina M, Granata A, Curcio G, Azzopardi N, Baccarini P, Liotta R, Formelli A, Maimone A, Jovine E, Cennamo V, Fabbri C. Endoscopic ultrasound-guided fine needle aspiration and biopsy using a 22-gauge needle with side fenestration in pancreatic cystic lesions. *Dig Liver Dis* 2014; **46**: 45-50 [PMID: 23916241 DOI: 10.1016/j.dld.2013.06.008]
- 44 **van der Waaij LA**, van Dullemen HM, Porte RJ. Cyst fluid analysis in the differential diagnosis of pancreatic cystic lesions: a pooled analysis. *Gastrointest Endosc* 2005; **62**: 383-389 [PMID: 16111956 DOI: 10.1016/S0016-5107(05)01581-6]
- 45 **Ngamruengphong S**, Bartel MJ, Raimondo M. Cyst carcinoembryonic antigen in differentiating pancreatic cysts: a meta-analysis. *Dig Liver Dis* 2013; **45**: 920-926 [PMID: 23790480 DOI: 10.1016/j.dld.2013.05.002]
- 46 **Boot C**. A review of pancreatic cyst fluid analysis in the differential diagnosis of pancreatic cyst lesions. *Ann Clin Biochem* 2014; **51**: 151-166 [PMID: 24097809 DOI: 10.1177/0004563213503819]
- 47 **Nikiforova MN**, Khalid A, Fasanella KE, McGrath KM, Brand RE, Chennat JS, Slivka A, Zeh HJ, Zureikat AH, Krasinskas AM, Ohori NP, Schoedel KE, Navina S, Mantha GS, Pai RK, Singhi AD. Integration of KRAS testing in the diagnosis of pancreatic cystic lesions: a clinical experience of 618 pancreatic cysts. *Mod Pathol* 2013; **26**: 1478-1487 [PMID: 23743931 DOI: 10.1038/modpathol.2013.91]
- 48 **Al-Haddad M**, DeWitt J, Sherman S, Schmidt CM, LeBlanc JK, McHenry L, Coté G, El Chafic AH, Luz L, Stuart JS, Johnson CS, Klochan C, Imperiale TF. Performance characteristics of molecular (DNA) analysis for the diagnosis of mucinous pancreatic cysts. *Gastrointest Endosc* 2014; **79**: 79-87 [PMID: 23845445 DOI: 10.1016/j.gie.2013.05.026]
- 49 **Khalid A**, Zahid M, Finkelstein SD, LeBlanc JK, Kaushik N, Ahmad N, Brugge WR, Edmundowicz SA, Hawes RH, McGrath KM. Pancreatic cyst fluid DNA analysis in evaluating pancreatic cysts: a report of the PANDA study. *Gastrointest Endosc* 2009; **69**: 1095-1102 [PMID: 19152896 DOI: 10.1016/j.gie.2008.07.033]
- 50 **Lee LS**, Wu BU, Banks PA, Kadiyala V, Mehta S, Saltzman JR, Thompson CC, Bellizzi AM. Utility of commercial DNA analysis in detecting malignancy within pancreatic cysts. *JOP* 2014; **15**: 182-188 [PMID: 24618422 DOI: 10.6092/1590-8577/2004]
- 51 **Shen J**, Brugge WR, Dimaio CJ, Pitman MB. Molecular analysis of pancreatic cyst fluid: a comparative analysis with current practice of diagnosis. *Cancer* 2009; **117**: 217-227 [PMID: 19415731 DOI: 10.1002/cncy.20027]
- 52 **Schoedel KE**, Finkelstein SD, Ohori NP. K-Ras and microsatellite marker analysis of fine-needle aspirates from intraductal papillary mucinous neoplasms of the pancreas. *Diagn Cytopathol* 2006; **34**: 605-608 [PMID: 16900481 DOI: 10.1002/dc.20511]
- 53 **Sawhney MS**, Devarajan S, O'Farrel P, Cury MS, Kundu R, Vollmer CM, Brown A, Chuttani R, Pleskow DK. Comparison of carcinoembryonic antigen and molecular analysis in pancreatic cyst fluid. *Gastrointest Endosc* 2009; **69**: 1106-1110 [PMID: 19249035 DOI: 10.1016/j.gie.2008.08.015]
- 54 **Megibow AJ**, Baker ME, Gore RM, Taylor A. The incidental pancreatic cyst. *Radiol Clin North Am* 2011; **49**: 349-359 [PMID: 21333781 DOI: 10.1016/j.rcl.2010.10.008]
- 55 **Correa-Gallego C**, Ferrone CR, Thayer SP, Wargo JA, Warshaw AL, Fernández-Del Castillo C. Incidental pancreatic cysts: do we really know what we are watching? *Pancreatol* 2010; **10**: 144-150 [PMID: 20484954 DOI: 10.1159/000243733]
- 56 **Cho CS**, Russ AJ, Loeffler AG, Rettammel RJ, Oudheusden G, Winslow ER, Weber SM. Preoperative classification of pancreatic cystic neoplasms: the clinical significance of diagnostic inaccuracy. *Ann Surg Oncol* 2013; **20**: 3112-3119 [PMID: 23595223 DOI: 10.1245/s10434-013-2986-6]
- 57 **Wright GP**, Morrow JB, Shaheen M, Goslin BJ, Baatenburg L, Chung MH. Accuracy of endoscopic ultrasound in the evaluation of cystic pancreatic neoplasms: a community hospital experience. *Pancreas* 2014; **43**: 465-469 [PMID: 24622081 DOI: 10.1097/MPA.0000000000000057]
- 58 **Lee LS**. Diagnostic approach to pancreatic cysts. *Curr Opin Gastroenterol* 2014; **30**: 511-517 [PMID: 25003604 DOI: 10.1097/MOG.0000000000000098]
- 59 **Kanda M**, Knight S, Topazian M, Syngal S, Farrell J, Lee J, Kamel I, Lennon AM, Borges M, Young A, Fujiwara S, Seike J, Eshleman J, Hruban RH, Canto MI, Goggins M. Mutant GNAS detected in duodenal collections of secretin-stimulated pancreatic juice indicates the presence or emergence of pancreatic cysts. *Gut* 2013; **62**: 1024-1033 [PMID: 22859495 DOI: 10.1136/gutjnl-2012-302823]
- 60 **Amato E**, Molin MD, Mafficini A, Yu J, Malleo G, Rusev B, Fassan M, Antonello D, Sadakari Y, Castelli P, Zamboni G, Maitra A, Salvia R, Hruban RH, Bassi C, Capelli P, Lawlor RT, Goggins M, Scarpa A. Targeted next-generation sequencing of cancer genes dissects the molecular profiles of intraductal papillary neoplasms of the pancreas. *J Pathol* 2014; **233**: 217-227 [PMID: 24604757 DOI: 10.1002/path.4344]
- 61 **Singhi AD**, Nikiforova MN, Fasanella KE, McGrath KM, Pai RK, Ohori NP, Bartholow TL, Brand RE, Chennat JS, Lu X, Papachristou GI, Slivka A, Zeh HJ, Zureikat AH, Lee KK, Tsung A, Mantha GS, Khalid A. Preoperative GNAS and KRAS testing in the diagnosis of pancreatic mucinous cysts. *Clin Cancer Res* 2014; **20**: 4381-4389 [PMID: 24938521 DOI: 10.1158/1078-0432.CCR-14-0513]
- 62 **Lee LS**, Szafranska-Schwarzbach AE, Andruss BF, Conwell DL. Can miRNA biomarkers be utilized to improve the evaluation and management of pancreatic cystic lesions? *MicroRNA*

- Diagnostics and Therapeutics* 2013; **1**: 24-34 [DOI: 10.2478/micrnat-2013-0003]
- 63 **Lee LS**, Szafranska-Schwarzbach AE, Wylie D, Doyle LA, Bellizzi AM, Kadiyala V, Suleiman S, Banks PA, Andruss BF, Conwell DL. Investigating MicroRNA Expression Profiles in Pancreatic Cystic Neoplasms. *Clin Transl Gastroenterol* 2014; **5**: e47 [PMID: 24476997 DOI: 10.1038/ctg.2013.18]
- 64 **Jabbar KS**, Verbeke C, Hyltander AG, Sjövall H, Hansson GC, Sadik R. Proteomic mucin profiling for the identification of cystic precursors of pancreatic cancer. *J Natl Cancer Inst* 2014; **106**: djt439 [PMID: 24523528 DOI: 10.1093/jnci/djt439]
- 65 **Cao Z**, Maupin K, Curnutte B, Fallon B, Feasley CL, Brouhard E, Kwon R, West CM, Cunningham J, Brand R, Castelli P, Crippa S, Feng Z, Allen P, Simeone DM, Haab BB. Specific glycoforms of MUC5AC and endorepellin accurately distinguish mucinous from nonmucinous pancreatic cysts. *Mol Cell Proteomics* 2013; **12**: 2724-2734 [PMID: 23836919 DOI: 10.1074/mcp.M113.030700]
- 66 **Park WG**, Wu M, Bowen R, Zheng M, Fitch WL, Pai RK, Wodziak D, Visser BC, Poultsides GA, Norton JA, Banerjee S, Chen AM, Friedland S, Scott BA, Pasricha PJ, Lowe AW, Peltz G. Metabolomic-derived novel cyst fluid biomarkers for pancreatic cysts: glucose and kynurenine. *Gastrointest Endosc* 2013; **78**: 295-302.e2 [PMID: 23566642 DOI: 10.1016/j.gie.2013.02.037]
- 67 **Valsangkar NP**, Morales-Oyarvide V, Thayer SP, Ferrone CR, Wargo JA, Warshaw AL, Fernández-del Castillo C. 851 resected cystic tumors of the pancreas: a 33-year experience at the Massachusetts General Hospital. *Surgery* 2012; **152**: S4-12 [PMID: 22770958 DOI: 10.1016/j.surg.2012.05.033]
- 68 **Gaujoux S**, Brennan MF, Gonen M, D'Angelica MI, DeMatteo R, Fong Y, Schattner M, DiMaio C, Janakos M, Jarnagin WR, Allen PJ. Cystic lesions of the pancreas: changes in the presentation and management of 1,424 patients at a single institution over a 15-year time period. *J Am Coll Surg* 2011; **212**: 590-600; discussion 600-603 [PMID: 21463795 DOI: 10.1016/j.jamcollsurg.2011.01.016]
- 69 **DeWitt J**, McGreevy K, Schmidt CM, Brugge WR. EUS-guided ethanol versus saline solution lavage for pancreatic cysts: a randomized, double-blind study. *Gastrointest Endosc* 2009; **70**: 710-723 [PMID: 19577745 DOI: 10.1016/j.gie.2009.03.1173]
- 70 **Bean WJ**, Rodan BA. Hepatic cysts: treatment with alcohol. *AJR Am J Roentgenol* 1985; **144**: 237-241 [PMID: 3880981 DOI: 10.2214/ajr.144.2.237]
- 71 **Gelczer RK**, Charboneau JW, Hussain S, Brown DL. Complications of percutaneous ethanol ablation. *J Ultrasound Med* 1998; **17**: 531-533 [PMID: 9697961]
- 72 **Rowinsky EK**, Donehower RC. Paclitaxel (taxol) *N Engl J Med* 1995; **332**: 1004-1014 [PMID: 7885406 DOI: 10.1056/NEJM199504133321507]
- 73 **Gan SI**, Thompson CC, Lauwers GY, Bounds BC, Brugge WR. Ethanol lavage of pancreatic cystic lesions: initial pilot study. *Gastrointest Endosc* 2005; **61**: 746-752 [PMID: 15855986 DOI: 10.1016/S0016-5107(05)00320-2]
- 74 **DiMaio CJ**, DeWitt JM, Brugge WR. Ablation of pancreatic cystic lesions: the use of multiple endoscopic ultrasound-guided ethanol lavage sessions. *Pancreas* 2011; **40**: 664-668 [PMID: 21562447 DOI: 10.1097/MPA.0b013e3182128d06]
- 75 **Oh HC**, Seo DW, Lee TY, Kim JY, Lee SS, Lee SK, Kim MH. New treatment for cystic tumors of the pancreas: EUS-guided ethanol lavage with paclitaxel injection. *Gastrointest Endosc* 2008; **67**: 636-642 [PMID: 18262182 DOI: 10.1016/j.gie.2007.09.038]
- 76 **Oh HC**, Seo DW, Song TJ, Moon SH, Park do H, Soo Lee S, Lee SK, Kim MH, Kim J. Endoscopic ultrasonography-guided ethanol lavage with paclitaxel injection treats patients with pancreatic cysts. *Gastroenterology* 2011; **140**: 172-179 [PMID: 20950614 DOI: 10.1053/j.gastro.2010.10.001]
- 77 **Oh HC**, Seo DW, Kim SC, Yu E, Kim K, Moon SH, Park do H, Lee SS, Lee SK, Kim MH. Septated cystic tumors of the pancreas: is it possible to treat them by endoscopic ultrasonography-guided intervention? *Scand J Gastroenterol* 2009; **44**: 242-247 [PMID: 18949629 DOI: 10.1080/00365520802495537]
- 78 **DeWitt J**, DiMaio CJ, Brugge WR. Long-term follow-up of pancreatic cysts that resolve radiologically after EUS-guided ethanol ablation. *Gastrointest Endosc* 2010; **72**: 862-866 [PMID: 20883866 DOI: 10.1016/j.gie.2010.02.039]
- 79 **DeWitt JM**, Al-Haddad M, Sherman S, LeBlanc J, Schmidt CM, Sandrasegaran K, Finkelstein SD. Alterations in cyst fluid genetics following endoscopic ultrasound-guided pancreatic cyst ablation with ethanol and paclitaxel. *Endoscopy* 2014; **46**: 457-464 [PMID: 24770971 DOI: 10.1055/s-0034-1365496]
- 80 **DeWitt J**. Endoscopic ultrasound-guided pancreatic cyst ablation. *Gastrointest Endosc Clin N Am* 2012; **22**: 291-302, ix-x [PMID: 22632951 DOI: 10.1016/j.giec.2012.04.001]
- 81 **Oh HC**, Brugge WR. EUS-guided pancreatic cyst ablation: a critical review (with video). *Gastrointest Endosc* 2013; **77**: 526-533 [PMID: 23321339 DOI: 10.1016/j.gie.2012.10.033]
- 82 **Kelvin YMC**, Park JS, Seo DW. Role of endosonography in the management of incidental pancreatic cystic lesions. *Gastrointest Intervention* 2014; **3**: 40-45 [DOI: 10.1016/j.gii.2014.04.003]

P- Reviewer: Lee CL, Skok P **S- Editor:** Tian YL **L- Editor:** A
E- Editor: Zhang DN





Published by **Baishideng Publishing Group Inc**

8226 Regency Drive, Pleasanton, CA 94588, USA

Telephone: +1-925-223-8242

Fax: +1-925-223-8243

E-mail: bpgoffice@wjgnet.com

Help Desk: <http://www.wjgnet.com/esps/helpdesk.aspx>

<http://www.wjgnet.com>

