

# Charcot-Marie-Tooth 4B2 caused by a novel mutation in the *MTMR13/SBF2* gene in two related Portuguese families

LUÍS NEGRÃO<sup>1</sup>, LUCIANO ALMENDRA<sup>1</sup>, JOANA RIBEIRO<sup>1</sup>, ANABELA MATOS<sup>1</sup>, ARGEMIRO GERALDO<sup>1</sup> AND JORGE PINTO-BASTO<sup>2</sup>

<sup>1</sup> Unidade de Doenças Neuromusculares, Serviço de Neurologia, Centro Hospitalar e Universitário de Coimbra, Coimbra, Portugal; <sup>2</sup> Centro de Genética Clínica, Porto, Portugal

**Introduction.** CMT4B2 is a rare subtype of CMT caused by pathogenic mutations in the myotubularin-related protein-13/set binding factor 2 (*MTMR13/SBF2*) gene. Nerve conduction velocities are markedly reduced and focally folded myelin sheaths are present on nerve biopsies. We presented two patients from two related Portuguese families with peripheral neuropathy caused by a novel mutation in the *MTMR13/SBF2* gene.

**Case report.** Family 1: Patient 1: A 30-year-old woman, with disease onset in early childhood presented pes cavus and hammer toes and walked with a steppage gait. Muscle weakness was present distally, myotactic reflexes were abolished and sensory examination revealed a stocking and glove pattern of hypoesthesia to all sensory modalities.

Family 2: Patient 2: A 43-year-old man, second degree cousin of patient 1, born of a consanguineous marriage. At the age of 9 months, he was diagnosed with congenital glaucoma on the left eye, with progressive visual loss up to total blindness. He presented bilateral claw hand deformity, pes cavus and hammer toes and walked with a steppage gait. Myotactic reflexes were abolished and muscle weakness was severe distally in the upper and lower limbs. Sensory examination revealed a stocking and glove pattern of hypoesthesia to all modalities. In both patients electrodiagnostic studies evidenced an uniform and generalized sensorimotor demyelinating polyneuropathy and the molecular study found a frameshift/truncating homozygous novel mutation c.5073\_5074del (p.Ser1692Tyrfs\*42) in the *MTMR13/SBF2* gene.

**Conclusions.** We report a novel mutation in the *MTMR13/SBF2* gene associated with a classical CMT phenotype. Congenital glaucoma associated with a frameshift/truncating mutation in CMT4B2 is reported for the first time.

**Key words:** CMT4B2, *MTMR13/SBF2* gene, autosomal recessive CMT, congenital glaucoma

## Introduction

Charcot-Marie-Tooth (CMT) disease, also called hereditary motor and sensory neuropathy (HMSN), is the most common inherited neuromuscular disorder with an estimated prevalence of 1/2500 (1).

According to mode of inheritance, it can be classified into autosomal dominant, recessive or X-linked forms; based on neurophysiologic findings it can be further sub classified into demyelinating or axonal, if nerve conduction velocity is below or above 38 m/s, respectively (2). The subtype CMT1A accounts for 60-70% of all cases of CMT. It is caused by a 1,4 Mb duplication of chromosome 17p11.2 that includes the *PMP22* gene (3) and nerve biopsy shows demyelination and remyelination with onion bulbs formations (4).

Autosomal recessive demyelinating CMT (CMT4) is a very rare form of CMT disease. It is clinically and genetically heterogeneous. Reported CMT4B2 families present similar clinical, electrodiagnostic and pathologic features (5-7). Congenital/early-onset glaucoma is a very characteristic, although not universal, clinical feature of the disease (8-10). The CMT4B2 locus was mapped in 1999 (6) and the myotubularin-related protein-13/set binding factor 2 (*MTMR13/SBF2*) gene was identified in 2003 (7, 9). *MTMR13/SBF2* belong to the family of myotubularins and is a catalytic inactive phosphatase (11, 12). *MTMR13/SBF2* interacts with *MTMR2* to form tetramers and the interaction significantly increases the catalytic activity of *MTMR2* (13), but a full understanding of its function it is still not known in detail (14).

We present the clinical, neurophysiologic and molecular findings of two patients from two related Portuguese families with CMT4B2, one with unilateral congenital glaucoma, caused by a novel frameshift/truncating homozygous mutation in the *MTMR13/SBF2* gene.

## A. Clinical findings

### Family description

**Family 1: Patient 1** – The patient is a 30-year-old woman, the single offspring of a non-consanguineous couple. The mother's parents are first degree cousins (Fig. 1) and her parents were clinical and electrophysiological normal. The patient's delivery was normal and she presented a normal motor and intellectual development in infancy. She attended University and graduated in Social Service.

At 4 years of age, the parents noticed a slight gait disturbance, which did not interfere significantly with her participation in the school physical activities. At the end of the first decade, running became increasingly more difficult and lastly impossible.

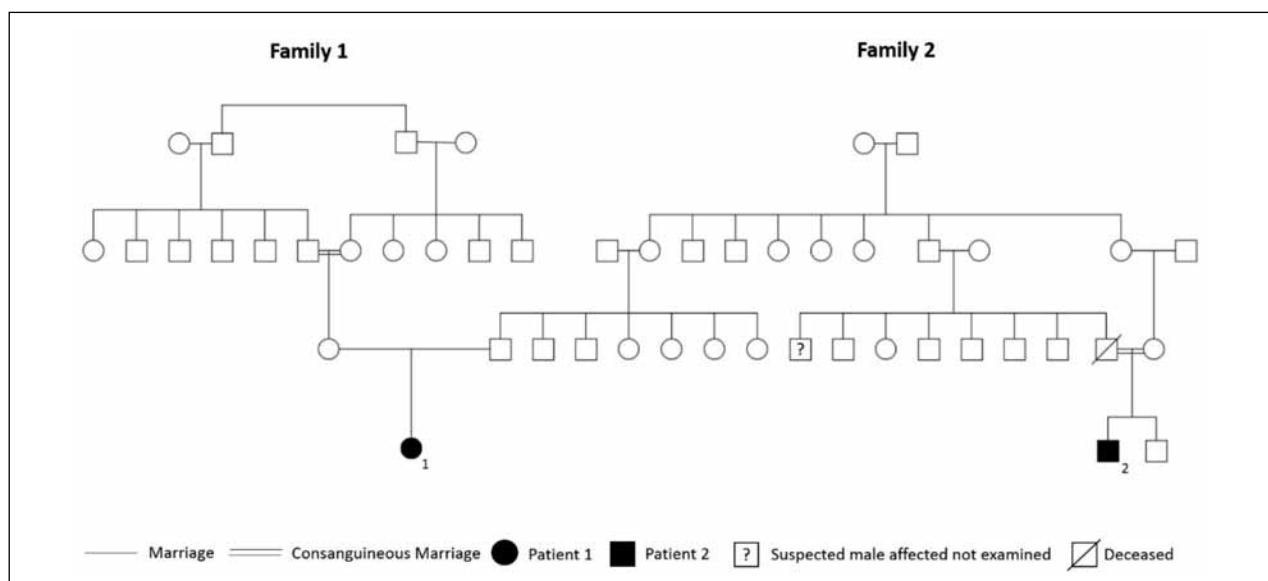
By the age of 9, the medical records from the local pediatric hospital described bilateral pes cavus, hammer-toes, distal lower limb muscular atrophy, absent ankle jerks and a flexor plantar response.

The muscle weakness and atrophy were slowly progressive in the following years, with involvement of the intrinsic hand muscles at the end of the second decade. Several corrective feet orthopedic surgeries were performed at the ages 15, 18 and 19.

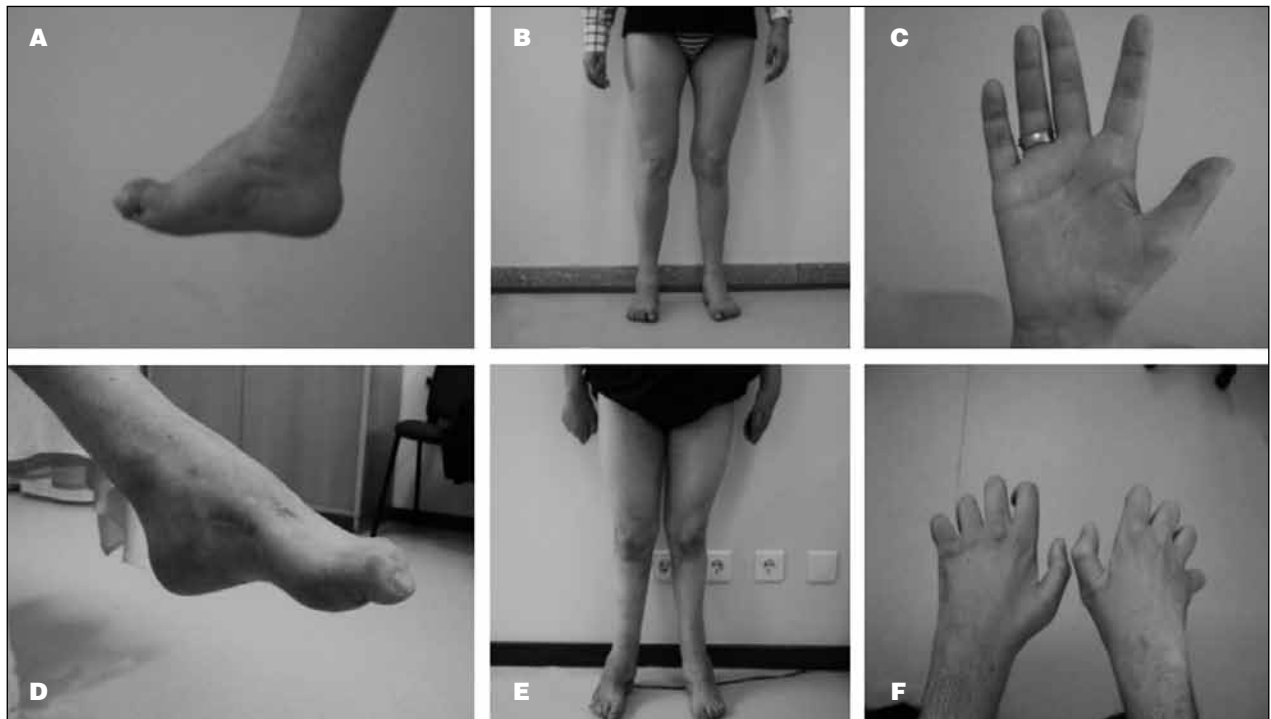
By the age of 30 she presented pes cavus and hammer-toes (Fig. 2a), with inverse champagne bottle legs (Fig. 2b). The thenar muscles were severely atrophic (Fig. 2c). Walking was difficult on tiptoes and impossible on heels and she walked with a bilateral steppage gait without ataxia. In the upper limbs the finger flexors, extensors and abductor muscles were weak (4/5 MRC); the abductor pollicis brevis muscle was more severely affected (0/5 MRC), bilaterally. In the lower limbs, extensor (0/5 MRC) and flexor muscles (4-5 MRC) of the feet and toes were weak, bilaterally. Muscle stretch reflexes were absent throughout. There were no cranial nerve deficits (including II cranial nerve and the VII nerve innervated muscles). Sensory examination revealed diminished tactile and pain sensation in a stocking and glove pattern and vibratory sensation was reduced distally in the upper and lower limbs, 10 and 6 seconds, respectively.

**Family 2: Patient 2** – The patient is a 43-year-old man, born of a first degree consanguineous marriage and second degree cousin of Patient 1 (Fig. 1). His mother is a first degree cousin of Patient's 1 father and he has one brother with a suspected similar neuromuscular condition (not available to examination). His parents were clinical and electrophysiological normal (the father died recently). The patient's delivery was normal and when he was 9 months old, he was diagnosed with congenital glaucoma on the left eye, with progressive visual loss up to total blindness. His right eye is not affected and does not present intra-ocular hypertension. He presented a normal motor and intellectual development in infancy.

By the age of 4, he walked on tiptoes. He underwent



**Figure 1.** Pedigree of Families 1 and 2.



**Figure 2.** a, d: Pes cavus and hammertoes; b, e: inverse champagne bottle legs; c: atrophy of the thenar eminence; f: global intrinsic hand muscle atrophy with claw hand appearance.

corrective orthopedic surgeries, because of pes equinovarus, at 4 and 18 years of age.

At his first clinical appointment at the Neuromuscular Disease Unit in 2014, by the age of 43 years, neurological

examination showed pes cavus and hammertoes (Fig. 2d) and inverse champagne bottle legs (Fig. 2e). The hand muscles were severely atrophic, with claw hand deformity (Fig. 2f). He walked with a bilateral steppage gait,

**Table 1.** Neurophysiologic investigations.

Nerve Conduction Study										
	Median Nerve				Ulnar Nerve				Peroneal Nerve	
	CMAP (mV)	DML (ms)	MNCV (m/sec)	SAP (µV)	CMAP (mV)	DML (ms)	MNCV (m/sec)	SAP (µV)	CMAP (mV)	DML (ms)
Family 1										
Patient 1	0.5	9.1	14	∅	3.6	7.4	19	∅	∅	
Family 2										
Patient 1	∅			∅	0.5	7.3	14	∅	∅	

Nerve Conduction Study						
	Sural Nerve		Facial Nerve		Blink Reflex	
	SAP (µV)		CMAP (mV)	DML (ms)	R1 (ms)	R2i (ms)
Family 1						
Patient 1	∅		0.4	6.5	22	57.6
Family 2						
Patient 1	∅		0.4	6.5	18	54

DML: distal motor latency; CMAP: compound muscle action potential; MNCV: motor nerve conduction velocity; SAP: sensory action potential; ms: milliseconds; mV: millivolt; m/sec: meters per second; µV: microvolt; ∅: absent

which was impossible on tiptoes and heels. Muscle stretch reflexes were absent throughout. In the upper limbs, the hand extensor muscles were weak (4/5 MRC), as well as the intrinsic hand muscles and the distal finger extensor muscles (0/5 MRC). In the lower limbs, the feet and toes extensor and flexor muscles were weak (0/5 MRC). Facial nerve muscles and right eye visual acuity were normal. Sensory examination revealed diminished tactile and pain sensation in a stocking and glove pattern and vibratory sensation was reduced distally in the upper and lower limbs, 8 and 5 seconds, respectively.

## B. Neurophysiological Investigations (Table 1)

In both patients, the median, ulnar and sural sensory nerve responses and the peroneal motor response recorded in the EDB muscle were absent bilaterally. In the upper limbs, the distal motor latencies recorded were prolonged and the motor nerve conduction velocities were severely reduced. No temporal dispersion or motor conduction block were observed. The latency of the direct motor response of the facial nerve and the R1 and R2i components of the blink reflex study were significantly prolonged in both patients. All the recorded motor responses were of very low amplitude. It was diagnosed a generalized demyelinating sensorimotor peripheral neuropathy with hereditary features.

## C. Molecular studies (Fig. 3)

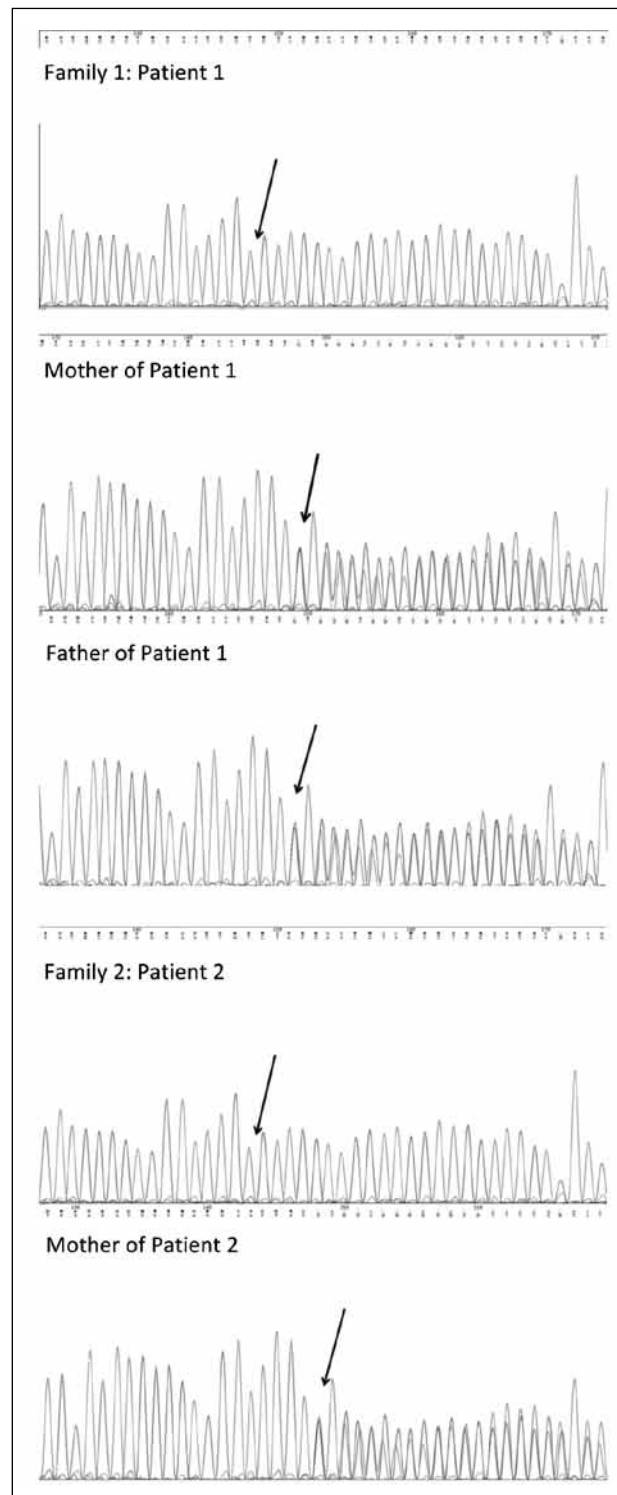
The patients, patient's 1 parents and the mother of patient 2 underwent genetic testing. The molecular study included polymerase chain reaction and sequencing of the entire coding region, including the adjacent intronic regions, of the *MTMR13/SBF2* gene (chromosome 11). Reference sequence: NM\_030962.3 with the A of the initial ATG in position 1.

A frameshift/truncating homozygous novel mutation, variant c.5073\_5074del (p.Ser1692Tyrfs\*42), was found in a homozygous state in Patients 1 and 2 and in a heterozygous state in patient 1's parents and the mother of Patient 2.

This mutation is predicted to be pathogenic as it introduces a premature stop codon, producing a truncated protein.

## Discussion

These two Portuguese patients with CMT4B2 present a classical CMT phenotype: clinical onset of a sensorimotor peripheral neuropathy in the first decade of life, which was slowly progressive, predominantly motor and severe



**Figure 3.** Chromatograms of the mutation site sequence (arrow).

distally in the upper and lower limbs and associated feet deformities. There was no proximal muscle weakness, sensory symptoms have never been a major complaint

and there was no sensory ataxia, cognitive impairment or psychiatric symptoms. The patients are still able to walk without support and are engaged on a productive life. A generalized demyelinating sensorimotor neuropathy was present in the neurophysiologic studies.

The characteristic histological feature of CMT4B2 is a markedly irregular contour and thickness of the myelin sheaths related to the presence of irregular myelin foldings, associated with marked reduction in the density of large myelinated fibers, segmental demyelination, and numerous onion bulb formations (6, 15). This pathologic feature is not unique to CMT4B2. The demyelinating nature of CMT4B can be easily confirmed by neurophysiologic techniques and nerve biopsies are exceptionally performed to confirm the demyelinating nature of the neuropathy.

Congenital glaucoma associated with a demyelinating CMT was reported in three members of a Brazilian family of Turkish ancestry (8). Early-onset glaucoma with a demyelinating CMT was later reported in families from Japan (10), Tunisia and Morocco (9). The affected members of these consanguineous families had nonsense mutations of the *MTMR13/SBF2* gene, while CMT4B2 families without congenital or early-onset glaucoma had other types of mutations (in-frame deletions and mutations in the splicing site of the *MTMR13/SBF2* gene) (6, 16). A genotype-phenotype correlation and a pathogenic mechanism were suggested, with nonsense mutations associated with complete absence of MTMR13/SBF2 protein and a partially functional protein in the other type mutations, capable of preventing the development of glaucoma, but not peripheral neuropathy (17). The mutation found in the Portuguese patients compromises the normal function of the MTMR13/SBF2 protein. It causes a premature stop codon, therefore it has the same consequence of the previously reported nonsense type of mutations related with the presence of congenital/early-onset glaucoma. Surprisingly, the glaucoma is not present in the female patient, which suggested that other genetic or epigenetic factors rather than this particular mutation could be responsible for the development of glaucoma.

## References

1. Skre H. Genetic and clinical aspects of Charcot-Marie-Tooth's disease. *Clin Genet* 1974;6:98-118.
2. Harding AE, Thomas PK. The clinical features of hereditary motor and sensory neuropathy types I and II. *Brain* 1980;103:259-80.
3. Raeymaekers P, Timmerman V, Nelis E, et al. Duplication in chromosome 17p11.2 in Charcot-Marie-Tooth neuropathy type 1a (CMT 1a). The HMSN Collaborative Research Group. *Neuromuscul Disord* 1991;1:93-7.
4. Hattori N, Yamamoto M, Yoshihara T, et al. Study group for hereditary neuropathy in Japan. Demyelinating and axonal features of Charcot-Marie-Tooth disease with mutations of myelin-related proteins (PMP22, MPZ and Cx32): a clinicopathological study of 205 Japanese patients. *Brain* 2003;126:134-51.
5. Gambardella A, Bolino A, Muglia M, et al. Genetic heterogeneity in autosomal recessive hereditary motor and sensory neuropathy with focally folded myelin sheaths (CMT4B). *Neurology* 1998;50:799-801.
6. Othmane KB, Johnson E, Menold M, et al. Identification of a new locus for autosomal recessive Charcot-Marie-Tooth disease with focally folded myelin on chromosome 11p15. *Genomics* 1999;62:344-9.
7. Senderek J, Bergmann C, Weber S, et al. Mutation of the *SBF2* gene, encoding a novel member of the myotubularin family, in Charcot-Marie-Tooth neuropathy type 4B2/11p15. *Hum Mol Genet* 2003;12:349-56.
8. Arruda WO, Comerlato EA, Scola RH, et al. Hereditary motor and sensory neuropathy with congenital glaucoma. Report on a family. *Arq Neuropsiquiatr* 1999;57(2-A):190-4.
9. Azzedine H, Bolino A, Taieb T, et al. Mutations in *MTMR13*, a new pseudophosphatase homologue of *MTMR2* and *Sbf1*, in two families with an autosomal recessive demyelinating form of Charcot-Marie-Tooth disease associated with early-onset glaucoma. *Am J Hum Genet* 2003;72:1141-53.
10. Kiwaki T, Umehara F, Takashima H, et al. Hereditary motor and sensory neuropathy with myelin folding and juvenile onset glaucoma. *Neurology* 2000;55:392-7.
11. Laporte J, Bedez F, Bolino A, et al. Myotubularins, a large disease-associated family of cooperating catalytically active and inactive phosphoinositides phosphatases. *Hum Mol Genet* 2003;12:R285-92.
12. Bolis A, Zordan P, Coviello S, et al. Myotubularin-related (MTMR) phospholipid phosphatase proteins in the peripheral nervous system. *Mol Neurobiol* 2007;35:308-16.
13. Berger P, Berger I, Schaffitzel C, et al. Multi-level regulation of myotubularin-related protein-2 phosphatase activity by myotubularin-related protein-13/set-binding factor-2. *Hum Mol Genet* 2006b;15:569-79.
14. Parman Y and Battaloglu E. Recessively transmitted predominantly motor neuropathies. *Handbook of Clinical Neurology* 2013;48:847-61.
15. Ohnishi A, Murai Y, Ikeda M, et al. Autosomal recessive motor and sensory neuropathy with excessive myelin outfolding. *Muscle Nerve* 1989;112:568-75.
16. Conforti FL, Muglia M, Mazzei R, et al. A new *SBF2* mutation in a family with recessive demyelinating Charcot-Marie-Tooth (CMT4B2). *Neurology* 2004;63:1327-8.
17. Hirano RR, Takashima H, Umehara F, et al. SET binding factor 2 (*SBF2*) mutation causes CMT4B with juvenile onset glaucoma. *Neurology* 2004;63:577-80.