

Case Report

A Case of Dural Arteriovenous Fistula of Superior Sagittal Sinus after Tamoxifen Treatment for Breast Cancer

Sung-Kyun Hwang, M.D.

Department of Neurosurgery, College of Medicine, Ewha Womans University, Mokdong Hospital, Seoul, Korea

We are reporting an unusual case of dural arteriovenous fistula (AVF) of the superior sagittal sinus (SSS) after tamoxifen treatment for breast cancer. A 30-year-old female arrived at the emergency room with a sudden headache and left sided weakness and sensory loss. In her past medical history, she was diagnosed with breast cancer 1 year prior, and subsequently underwent a breast conserving mastectomy with whole breast radiation and adjuvant chemotherapy with tamoxifen. At the time of admission, computed tomography showed a small acute intracerebral hemorrhage at the right parietal cortex, and magnetic resonance imaging showed that a dural AVF at the SSS with a prominent and tortuous venous enhancement along the centrum semiovale was present. Cerebral angiography showed that the dural AVF at the mid-portion of the SSS with meningeal arterial feeding vessels entering the wall of the SSS, then draining through the dilated cortical veins. Our patient had no signs of active malignancy or any abnormalities in her coagulation profile, so it can be concluded that the tamoxifen was the likely cause of the SSS thrombosis and dural AVF. The dural AVF was treated by an endovascular coil embolization for the arterialized segment of the SSS. The patient dramatically recovered favorably from left side motor and sensory deficit. The best clinical approach is to screen potential patients of tamoxifen hormonal therapy and educate them on the sign and symptoms of life threatening thromboembolic events while taking tamoxifen.

Key Words : Dural fistula · Superior sagittal sinus · Tamoxifen · Breast cancer.

INTRODUCTION

Tamoxifen, a selective estrogen receptor modulator with antagonistic effects in the breast, is an effective treatment for breast cancer. However, with these benefits comes the risk of a variety of side effects, including cerebral venous thrombosis. Although studies imply an association between chemotherapy with tamoxifen and cerebral venous thrombosis, their lack of control patients in their observations prevent definite conclusions. The possibility that chemotherapy with tamoxifen contributed to thrombotic complications has been suggested for patients with breast cancer^{1,3,7,11,12,14,18-20,22}.

A dural arteriovenous fistula (AVF) is characterized by abnormal arteriovenous shunting confined to the pachymeninges region. The precise cause of a dural AVF remains unclear, however, a host-related factor such as a cerebral sinus thrombosis is likely associated with the development of a dural AVF^{4,5,8,9,15,17}.

We are presenting the unusual case of a patient with breast cancer receiving tamoxifen treatment who developed a superior sagittal sinus (SSS) thrombosis and a dural AVF.

CASE REPORT

A 30-year-old female arrived at the emergency room with a sudden headache and left sided weakness and sensory loss. In her past medical history, she had been diagnosed with infiltrating ductal breast cancer 1 year before. She subsequently underwent a breast conserving mastectomy and was treated by a sentinel lymph node biopsy with radiation on the entire breast and adjuvant chemotherapy with tamoxifen daily (20 mg) for 11 months. At the time of admission, neurologic examination revealed signs of a mild left sided hemiparesis (grade 4) and mild sensory loss. Non-contrast computed tomography (CT) showed a small acute intracerebral hemorrhage at the right parietal cor-

• Received : April 29, 2014 • Revised : June 21, 2014 • Accepted : June 21, 2014

• Address for reprints : Sung-Kyun Hwang, M.D.

Department of Neurosurgery, College of Medicine, Ewha Womans University, Mokdong Hospital, 1071 Anyangcheon-ro, Yangcheon-gu, Seoul 158-710, Korea
Tel : +82-2-2650-2872, Fax : +82-2-2650-2652, E-mail : nshsg@ewha.ac.kr

• This is an Open Access article distributed under the terms of the Creative Commons Attribution Non-Commercial License (<http://creativecommons.org/licenses/by-nc/3.0>) which permits unrestricted non-commercial use, distribution, and reproduction in any medium, provided the original work is properly cited.

tex (Fig. 1A). Magnetic resonance imaging (MRI) demonstrated dural AVF at the mid-portion of the SSS with an occluded posterior segment of the SSS in addition to a prominent and tortuous venous enhancement along the centrum semiovale (Fig. 1B, C). Cerebral angiography showed that the dural AVF at the mid-portion of the SSS with a meningeal arterial feeding vessels entering the wall of the SSS, then draining through dilated cortical veins. The dilated cortical veins with venous hypertension are related to acute right intracerebral hemorrhage at the right parietal cortex (Fig. 2). Routine hematology and biochemistry of the laboratory findings were normal. Anticoagulation tests, antithrombin III, protein S, and C levels were also found to be normal. Our patient had no signs of active malignancy nor any abnormalities in her coagulation profile so it can be concluded that tamoxifen was the likely cause of the SSS thrombosis. The dural AVF at the arterIALIZED segment of the SSS was treated by an endovascular coil embolization (Fig. 3). Post-embolization angiography showed disappearance of the dural AVF in the SSS (Fig. 4A, B). Postoperative CT revealed resolved subarachnoid hemorrhage without additional lesions. Postoperative MRI showed interval improvement of the dilated cortical veins (Fig. 4C). The patient dramatically recovered to a normal state with a left side motor and sensory deficit.

DISCUSSION

Tamoxifen, a selective anti-estrogen property of hormonal therapy, is one of the widely used drug, specifically in breast cancer patients. In addition, this drug has been shown to prevent breast cancer in high-risk patients when developing it for the first time or for contralateral recurrence. However, anti-estrogen therapy with tamoxifen has been known to increase the risk of venous sinus thrombosis^{1,3,7,11-14,18-20}. Our patient had previously been diagnosed with breast cancer and was currently taking adjuvant tamoxifen therapy. She had no signs of active malignancy or any abnormalities in her coagulation profile, so it can be concluded that tamoxifen was the possible cause of the SSS thrombosis. She had two known contributing factors for her cerebral sinus thrombosis; cancer and anti-estrogen treatment. Cancer patients are particularly vulnerable to systemic venous thrombosis during the course of their illness. This is due to hypercoagulability caused by malignancy as well as disease and treatment-related complications^{11,18,19,21}. The mech-

anisms by which tamoxifen increases the risk of venous sinus thrombosis are still unknown. The mechanism of action with regard to changes in coagulation parameters which could potentially explain venous thrombogenic activity of tamoxifen was not completely understood. They suggested that tamoxifen may contribute to a hypercoagulable state among patients with breast cancer. Alterations of hemostasis that may contribute to this hypercoagulable state include decreased levels of protein C and S, decreased levels of antithrombin III, and fibrinolytics (fibrinogen, plasminogen, tissue plasminogen activator). We believe that the increased thromboembolic complications observed among patients who received tamoxifen therapy for breast cancer is probably multi-factorial, but may be contributed to these perturbations of proteins C and S, and antithrombin III^{1,3,11,18-20,22}.

The SSS was the most frequently affected sinus in reports of cancer patients with cerebral sinus thrombosis. The SSS may be more susceptible to thrombosis due to its length and location. Lower pressures and slower blood flow can lead to increased stasis of blood and subsequent thrombosis. The slower blood flow may lead to tissue hypoxia and a decrease in the clearance of clotting factors. In addition, it is contiguous throughout its length with the skull, a frequent site of bone metastasis, which can com-

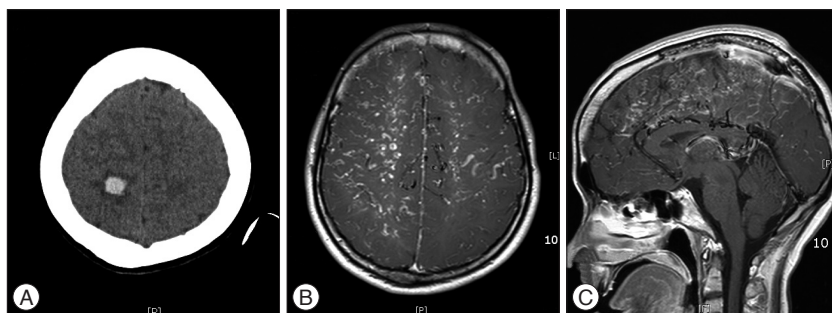


Fig. 1. A : Computed tomography axial image demonstrate a small intracerebral hemorrhage in the right parietal cortex. B and C : Magnetic resonance imaging demonstrate thrombosis at the posterior segment of superior sagittal sinus and dural arteriovenous fistula with a prominent and tortuous venous enhancement along the centrum semiovale.

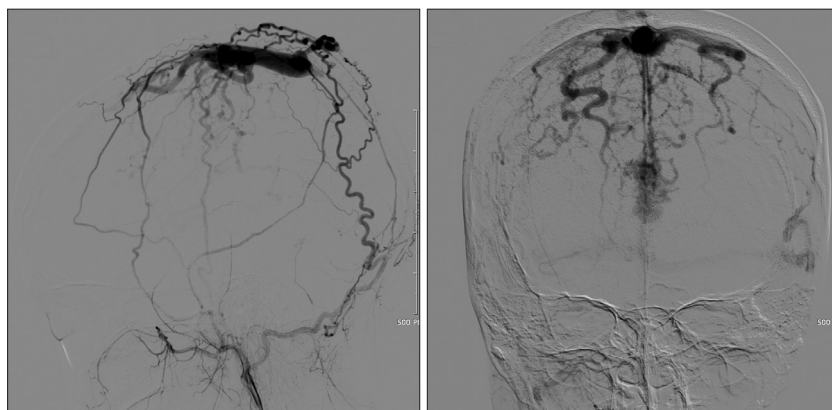


Fig. 2. External carotid artery angiography demonstrate dural arteriovenous fistula at the mid-portion of a superior sagittal sinus. The meningeal arterial feeders enter the wall of the superior sagittal sinus, and, then drain through the dilated cortical veins (corkscrew vessels). The dilated cortical veins with venous hypertension, may be related to acute right intracerebral hemorrhage at the right parietal cortex.

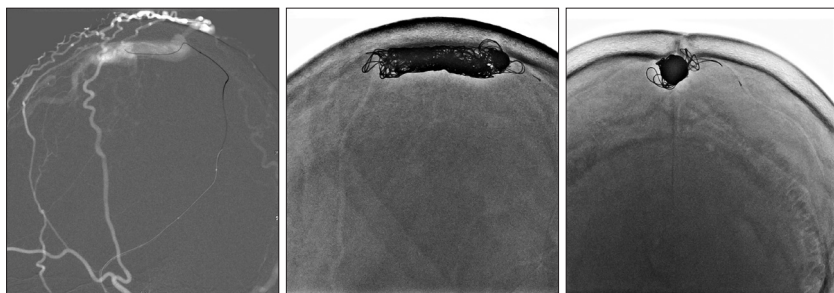


Fig. 3. The dural arteriovenous fistula was treated by an endovascular coil embolization for a superior sagittal sinus through navigation of the meningeal artery.

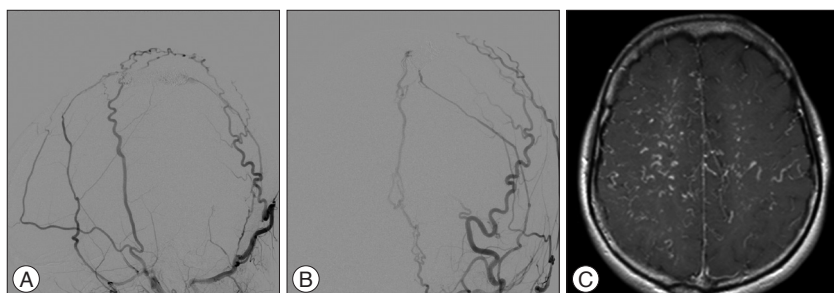


Fig. 4. A and B : Post-embolization angiography shows the disappearance of the dural arteriovenous fistula at the mid-portion of the superior sagittal sinus. C : Postoperative MRI shows an interval improvement of the dilated cortical veins.

press or invade the SSS. Venous sinus thrombosis is also more common in young women than in other groups, and development during puerperium is still common in developing countries. Oral contraceptives may play a role in the pathogenesis of venous sinus thrombosis in young women. Premenopausal patients who received chemotherapy and tamoxifen developed significantly more venous sinus thrombosis than patients who received chemotherapy without tamoxifen, and also suffered no arterial thrombotic complications. A postmenopausal woman taking estrogen-progesterone therapy was reported to have developed a venous sinus thrombosis^{21,22}.

A dural AVF is characterized by abnormal arteriovenous shunting confined to the region of the pachymeninges. In the analysis of dural AVFs by Awad et al.²⁾, these lesions of SSS accounted for 7.4% of all dural AVFs. The precise cause of a dural AVF remains unclear, however, host-related factor such as a cerebral sinus thrombosis is likely associated with the development of a dural AVF. Hormonal or hemostatic mechanisms may play a role. The lesions may thrombose or regress spontaneously, and alternatively, it may acquire additional arterial sources that converge into the same region of involved dura. Reversal of blood flow into leptomeningeal channels may produce venous dilation, varicosities, and venous aneurysms. The symptom from these lesions, similar to other dural AVFs, depends on the pattern of venous drainage. If the venous drainage is shared by cortical veins, there is a high incidence of hemorrhage or neurological deficits like our patient^{5,6,8-10,15-17}. Our patient revealed a vascular blood supply from the external carotid artery to the fistula through branches of the middle meningeal, and superficial temporal ar-

tery. This is similar to dural AVFs in other locations, especially when all antero-grade drainage through the venous sinus has thrombosed, leaving retrograde cortical venous routes, which induce the intracerebral hemorrhage (Fig. 2).

The association between venous sinus thrombosis and a dural AVF has been recognized. This link is also thought to be related to the altered hemodynamics induced by a dural AVF. Hypercoagulable states are associated with numerous conditions. Factors involved in hypercoagulability include protein C, protein S, antithrombin III, and fibrinolytics (fibrinogen, plasminogen, tissue plasminogen activator). A disequilibrium or altered functionality of these factors can result in hypercoagulable states, contributing to venous sinus thrombosis and a dural AVF.

CONCLUSION

The best clinical approach is to screen potential patients of tamoxifen hormone therapy and educate them on the signs and symptoms of life threatening thromboembolic events while taking tamoxifen. The search for the disease entity by which tamoxifen increases the risk of venous sinus thrombosis is still unknown. Future studies of women with breast cancer using tamoxifen should be designed to determine stroke etiologies, the role of additional chemotherapy, existing stroke risk factors, family history and the potential mechanisms of venous sinus thrombosis.

References

1. Akdal G, Dönmez B, Cakmakçi H, Yener GG : A case with cerebral thrombosis receiving tamoxifen treatment. *Eur J Neurol* 8 : 723-724, 2001
2. Awad IA, Little JR, Akarawi WP, Ahl J : Intracranial dural arteriovenous malformations : factors predisposing to an aggressive neurological course. *J Neurosurg* 72 : 839-850, 1990
3. Bushnell C : The cerebrovascular risks associated with tamoxifen use. *Expert Opin Drug Saf* 4 : 501-507, 2005
4. Cognard C, Casasco A, Toevi M, Houdart E, Chiras J, Merland JJ : Dural arteriovenous fistulas as a cause of intracranial hypertension due to impairment of cranial venous outflow. *J Neurol Neurosurg Psychiatry* 65 : 308-316, 1998
5. Cognard C, Gobin YP, Pierot L, Bailly AL, Houdart E, Casasco A, et al. : Cerebral dural arteriovenous fistulas : clinical and angiographic correlation with a revised classification of venous drainage. *Radiology* 194 : 671-680, 1995
6. Cognard C, Januel AC, Silva NA Jr, Tall P : Endovascular treatment of intracranial dural arteriovenous fistulas with cortical venous drainage : new management using Onyx. *AJNR Am J Neuroradiol* 29 : 235-241, 2008

7. D'Angelo-Donovan D, Guarino MJ : Sagittal sinus thrombosis while on tamoxifen requiring craniectomy. *Del Med J* 84 : 31-32, 2012
8. Davies MA, Saleh J, Ter Brugge K, Willinsky R, Wallace MC : The natural history and management of intracranial dural arteriovenous fistulae. Part 1 : benign lesions. *Interv Neuroradiol* 3 : 295-302, 1997
9. Davies MA, Ter Brugge K, Willinsky R, Wallace MC : The natural history and management of intracranial dural arteriovenous fistulae. Part 2 : aggressive lesions. *Interv Neuroradiol* 3 : 303-311, 1997
10. Davies MA, TerBrugge K, Willinsky R, Coyne T, Saleh J, Wallace MC : The validity of classification for the clinical presentation of intracranial dural arteriovenous fistulas. *J Neurosurg* 85 : 830-837, 1996
11. Duvelleroy Hommet C, De Toffol B, Corcia P, Autret A : Cerebral venous thrombosis and estrogen-progesterone therapy. *Eur Neurol* 39 : 245-247, 1998
12. Fatehi F, Saadatnia M, Zare M : Cerebral venous sinus thrombosis following tamoxifen prescription. *Neurosciences (Riyadh)* 13 : 320, 2008
13. Finelli PF : Thrombosis of the cerebral veins and sinuses. *N Engl J Med* 353 : 314-315, 2005
14. Finelli PF, Schauer PK : Cerebral sinus thrombosis with tamoxifen. *Neurology* 56 : 1113-1114, 2001
15. Halbach VV, Higashida RT, Hieshima GB, Rosenblum M, Cahan L : Treatment of dural arteriovenous malformations involving the superior sagittal sinus. *AJNR Am J Neuroradiol* 9 : 337-343, 1988
16. King WA, Martin NA : Intracerebral hemorrhage due to dural arteriovenous malformations and fistulae. *Neurosurg Clin N Am* 3 : 577-590, 1992
17. Liu JK, Choudhry OJ, Barnwell SL, Delashaw JB Jr, Dogan A : Single stage transcranial exposure of large dural venous sinuses for surgically-assisted direct transvenous embolization of high-grade dural arteriovenous fistulas : technical note. *Acta Neurochir (Wien)* 154 : 1855-1859, 2012
18. Masjuan J, Pardo J, Callejo JM, Andrés MT, Alvarez-Cermeño JC : Tamoxifen : a new risk factor for cerebral sinus thrombosis. *Neurology* 62 : 334-335, 2004
19. Meier CR, Jick H : Tamoxifen and risk of idiopathic venous thromboembolism. *Br J Clin Pharmacol* 45 : 608-612, 1998
20. Meyer MA : Cerebral sinus thrombosis with tamoxifen. *Neurology* 57 : 2150, 2001
21. Raizer JJ, DeAngelis LM : Cerebral sinus thrombosis diagnosed by MRI and MR venography in cancer patients. *Neurology* 54 : 1222-1226, 2000
22. Saphner T, Tormey DC, Gray R : Venous and arterial thrombosis in patients who received adjuvant therapy for breast cancer. *J Clin Oncol* 9 : 286-294, 1991