

In-Depth Review

# Maternal, pregnancy and fetal outcomes in *de novo* anti-glomerular basement membrane antibody disease in pregnancy: a systematic review

Benjamin Thomson<sup>1</sup>, Geena Joseph<sup>2,\*</sup>, William F. Clark<sup>1,3,\*</sup>, Michelle Hladunewich<sup>4,\*</sup>, Amit Patel<sup>1</sup>, Peter Blake<sup>1</sup>, Genevieve Eastabrook<sup>5</sup>, Doreen Matsui<sup>6</sup>, Ajay Sharma<sup>6</sup> and Andrew House<sup>1</sup>

<sup>1</sup>Division of Nephrology, Department of Medicine, London Health Sciences Centre and Western University, London, ON, Canada, <sup>2</sup>Division of Nephrology, Department of Medicine, McMaster University, Hamilton, ON, Canada, <sup>3</sup>Kidney Clinical Research Unit, Schulich School of Medicine and Dentistry, Western University, London, ON, Canada, <sup>4</sup>Division of Nephrology, Department of Medicine, University of Toronto, Toronto, ON, Canada, <sup>5</sup>Department of Obstetrics and Gynaecology, London Health Sciences Centre and Western University, London, ON, Canada and <sup>6</sup>Department of Paediatrics, Western University, London, ON, Canada

Correspondence and offprint requests to: Benjamin Thomson; E-mail Benjamin.thomson@londonhospitals.ca

\*Authors G.J., W.F.C. and M.H. are equal second authors.

## Abstract

**Background.** Outside of pregnancy, anti-glomerular basement membrane (GBM) antibody disease is associated with significant morbidity and mortality. However, there is limited knowledge regarding *de novo* anti-GBM disease in pregnancy.

**Methods.** A systematic review was performed to identify maternal, pregnancy and fetal outcomes in *de novo* anti-GBM disease in pregnancy. Studies were selected from PubMed, EMBASE, Cochrane Library databases and conference proceedings, without language restriction.

**Results.** Data from eight patients were derived from seven case reports and one unpublished case. Most (6/8) patients presented after the first trimester. During pregnancy, acute kidney injury (5/8), anemia (5/8), hematuria (8/8) and proteinuria (8/8) were common. When hemodialysis was required antepartum (5/8), renal function recovery to independence of renal replacement was unlikely (2/5). While pulmonary involvement was common (5/8), no permanent damage was reported (0/8). The majority of cases ended in live births (6/8) although prematurity (6/6), intrauterine growth restriction (2/6), small for gestational age (4/6) and complications of prematurity (1/6) were common. When anti-GBM levels were tested in the living newborn, they were detectable (2/5), but no newborn renal or lung disease was reported (0/6). Complications in pregnancy included gestational diabetes (3/8), hyperemesis gravidarum (2/8) and preeclampsia (2/8).

**Conclusions.** Live births can be achieved in *de novo* anti-GBM disease in pregnancy, but are commonly associated with adverse maternal, pregnancy and fetal outcomes. Only with awareness of common presentations, and management strategies can outcomes be optimized.

**Keywords:** anti-GBM; Goodpasture's disease; placenta; pregnancy; vasculitis

## Introduction

Anti-glomerular basement membrane (anti-GBM) antibody disease commonly leads to rapidly progressive glomerulonephritis (RPGN) [1, 2], end-stage kidney disease and death [3]. Named eponymously for its discoverer in 1919 [4], Goodpasture's syndrome consists of pulmonary hemorrhage and glomerulonephritis [5] caused by an auto-antibody to alveolar and glomerular basement membrane antigens [6].

Acute kidney injury (AKI) occurs in ~1:15 000–1:20 000 pregnancies [7] and is associated with adverse maternal and fetal outcomes. A number of etiologies are well established for obstetric AKI [8], but there is limited knowledge regarding *de novo* glomerulonephritis, and in particular

*de novo* Goodpasture's disease in pregnancy. Given the implications of systemic vasculitis and its management in maternal and fetal outcomes, literature on this topic is essential.

We performed a systematic review of *de novo* anti-GBM disease in pregnancy, reporting on clinical presentation, management and pregnancy outcomes.

## Methods

### Search strategy and selection criteria

Electronic databases (PubMed, EMBASE and the Cochrane Library) were searched up to 20 April 2014. Conference abstracts (American Society of Nephrology 2003–2013,

European Renal Association 2002–2013) were searched. The search terms were ‘anti-GBM,’ ‘Glomerular basement membrane,’ ‘pregnancy,’ ‘gestation,’ ‘Goodpasture’s disease,’ ‘Goodpasture’s syndrome’. There were no restrictions on language, publication form or study type.

Studies and case reports were included if they met the following criteria: (i) Patient was pregnant during diagnosis or management of *de novo* anti-GBM disease. (ii) Anti-GBM disease was confirmed by positive anti-GBM antibody, renal biopsy findings considered diagnostic for anti-GBM disease, or both.

#### Data extraction and quality assessment

One investigator (B.T.) twice used the search strategy to identify potentially relevant articles. Full reports of potentially relevant studies were obtained and each was reviewed using predefined eligibility criteria. Data were abstracted for study and patient characteristics, management strategy as well as maternal, fetal and pregnancy outcome assessment.

#### Data synthesis and analysis

Patient characteristics including maternal and gestational age, obstetric history (gravidity and parity), and medical/surgical history were collected. Clinical, laboratory and radiologic features at presentation were recorded. Chest imaging was recorded when available. When renal biopsy was performed, the timing relative to pregnancy, and whether it was diagnostic for anti-GBM disease was recorded. Information regarding immunosuppressive management was collected.

Maternal outcomes included antepartum and postpartum (i) renal function, defined by serum creatinine, creatinine clearance or the need for renal replacement therapy, (ii) lung function, defined by the presence of cough, dyspnea, hemoptysis or the result of radiologic imaging (chest X-ray, ventilation-perfusion scan or pulmonary function tests). Pregnancy outcomes included (i) vaginal versus cesarean section delivery, (ii) presence of pregnancy-related complications, such as placenta praevia or abruptio, hyperemesis gravidarum, gestational diabetes, gestational hypertension or preeclampsia. Fetal outcomes included (i) gestational age at birth, (ii) intrauterine growth restriction or small for gestational age, (iii) live birth or non-live birth (therapeutic abortion, miscarriage, stillborn), (iv) presence of congenital abnormalities at birth, (v) newborn anti-GBM antibodies, (vi) newborn kidney or lung disease.

## Results

#### Selected studies

Of 160 initial study abstracts reviewed, 12 qualified for full review (Figure 1). A total of seven case reports were identified that related to *de novo* anti-GBM disease in pregnancy. One case report was from the 2006 American Society of Nephrology annual conference abstracts [9], and was the first of two cases from our research group. When an additional case from our research group was added, there were eight total case reports of *de novo* anti-GBM disease in pregnancy.

#### Patient characteristics

Maternal age ranged from 19 to 34 (mean 27.3) years (Table 1). Most women presented in the second trimester

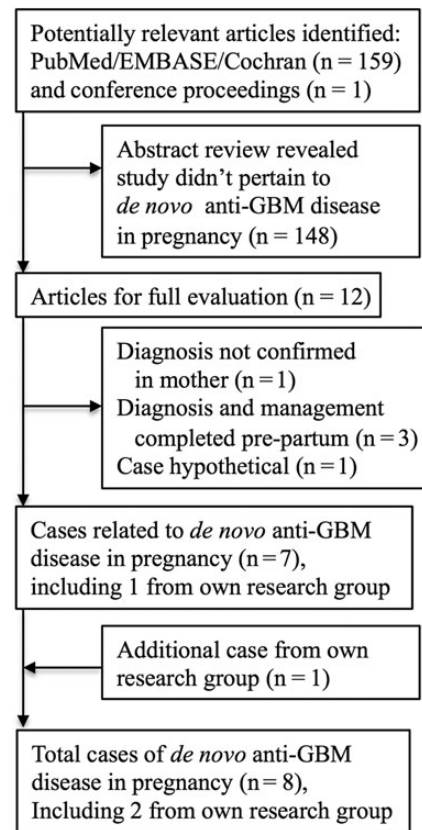


Fig. 1. Flow and selection of studies through review. GBM, glomerular basement membrane.

(6/8) with only the case of Deubner *et al.* presenting at 12 weeks gestation and the case of Yankowitz *et al.* being diagnosed 3 months prior to pregnancy. Most (5/8) women had no prior pregnancies, two women had other living children. Underlying renal disease (‘possible IgA nephropathy’) was found in only one woman [15], and underlying hypertension only in London, 2013.

#### Investigations

Markedly elevated serum creatinine was reported in 5/8 cases (Table 2), and anemia in all cases that reported a serum hemoglobin (5/5). When reported, serum anti-GBM titer was elevated at presentation (6/7). Urinalysis consistently showed hematuria (6/6) and proteinuria (6/6). Urine microscopy confirmed red blood cells (rbc) (6/6) but only rarely revealed dysmorphic rbc (1/6) or cellular casts (1/6). When performed, chest X-ray commonly (3/4) found evidence of parenchymal disease suggestive of pulmonary hemorrhage. Renal biopsy was performed in most (7/8) cases, once pre-pregnancy and equally frequently during (3/7) and after pregnancy (3/7). Every kidney biopsy performed was diagnostic for anti-GBM disease (7/7).

#### Immunosuppression

Immunosuppressive therapy was used during pregnancy in half (4/8) of the cases (Table 1). All immunosuppression regimes included corticosteroids (8/8). Cyclophosphamide exposure occurred during pregnancy in a minority of cases (2/8) and was delayed to the post-partum period in three cases. All patients received plasmapheresis during their

**Table 1.** Patient characteristics and immunosuppressive management of *de novo* anti-GBM disease in pregnancy

	Nillsen [10]	Yankowitz [11]	Deubner [12]	Al-Harbi [13]	Vasiliou [14]	Nair [15]	Joseph [9]	London 2013
Patient characteristics								
Maternal age (years)	19	28	21	30	34	23	33	30
Gestational age (weeks) at presentation	19	3 months	12	28	18	13	15	25
Previous obstetric history (gravidity/parity)	G0 P0	G0 P0	G0 P0	G7 P7	G1 P0	G0 P0	G0 P0	G2 P1
Relevant past medical history						Possible IgA nephropathy		HTN
Immunosuppressive management								
Timing (pre-pregnancy, during or post-partum)	Post	Pre	Post	During	During	Post	During	During
Induction: corticosteroids	(+)	(+)	(+)	(+)	(+)	(+)	(+)	(+)
Cyclophosphamide	(+)	(+)	(+)	(-)	(-)	(+)	(-)	(+)
Plasmapheresis	(+) (n = NR)	(+) (n = 5)	(+) (n = NR)	(+) (n = NR)	(+) (n = 6)	(+) (n = 14)	(+) (n = 20)	(+) (n = 32)
Azathioprine	(-)	(-)	(-)	(-)	(+)	(-)	(+)	(+)
Other	None	PO CYC and PRED continued in pregnancy	None	Post-partum management NR	None	None	Low-dose ASA	Azathioprine post-3 IV CYC doses, 32 weeks gestation

ASA, acetylsalicylic acid; CYC, cyclophosphamide; HTN, hypertension; IV, intravenous; NR, not reported; PCOS, polycystic ovarian syndrome; PO, per oral; PRED, prednisone.

**Table 2.** Investigations in patients with *de novo* anti-GBM disease in pregnancy

	Nillsen [10]	Yankowitz [11]	Deubner [12]	Al-Harbi [13]	Vasiliou [14]	Nair [15]	Joseph [9]	London 2013
Laboratory investigations at presentation								
Creatinine ( $\mu\text{mol/L}$ )	NR	(CrCl = 198 mL/min)	97	1217	1306	318	1132	1130
Hemoglobin (g/dL)	NR	NR	NR	6.6	7.8	7.3	6.7	5.9
Anti-GBM antibody	NR	(+)	12 U/mL ('borderline')	(-)	(+)	(+)	(+)	(+)
Urinalysis	(1+)HEM, (1+)PRO	(3+)HEM, (2+)PRO	NR	(3+)HEM, (2+)PRO	(1+)HEM, (1+)PRO	NR	(+)HEM, (+)PRO	>3.0 g/L PRO Large Blood
Urine microscopy	NR	NR	5-6 wbc/HPF, 15-20 rbc/HPF	>25 rbc/HPF, no casts	Dysmorphic rbc, no casts	0-2 wbc/HPF ++ rbc/HPF no casts	Rbc, Cellular casts	>100 rbc/HPF <10 wbc/HPF, granular casts
24-h urine protein quantification (g/day)	NR	0.196	3.2	NR	NR	NR	NR	0.91
Chest imaging	NR	CXR: 'Bilateral interstitial/nodular infiltrates'	NR	CXR: 'Congested lungs'	NR	NR	Normal	CXR: 'Congested' VQ scan: 'suggestive of pulmonary hemorrhage' (-)
Renal biopsy: performed	(+)	(+)	(+)	(+)	(+)	(+)	(+)	(+)
Timing (pre-pregnancy, during or post-partum)	Post	Pre	Post	Post	During (18 weeks)	During (14 weeks)	During (15 weeks)	During (15 weeks)
Diagnostic of anti-GBM disease	(+)	(+)	(+)	(+)	(+)	(+)	(+)	(+)
Crescents ( $\pm$ , %)	(+), 'advanced'	(+), NR	(+), 100%	(+), 100%	(+), 80%	(+), 60%	(+), 100%	(+), 100%

CXR, chest X-ray; g, grams; HEM, hematuria; HPF, high powered field; mL, milliliter; L, liter; NR, not reported; PRO, proteinuria; rbc, red blood cell; U, units; VQ, ventilation-perfusion scan; wbc, white blood cell.

treatment course, but the number of treatments varied dramatically (range 5–32). Azathioprine was used in the absence of cyclophosphamide induction in two cases.

#### Outcomes: maternal

Most (7/8) women required hemodialysis during their clinical course, with most (5/8) requiring hemodialysis during pregnancy (Table 3). Two women recovered renal function following termination of pregnancy to the point of not

requiring hemodialysis, one after a therapeutic abortion at 15 weeks and the other after delivery at 26 weeks. While many (5/8) women presented with potential pulmonary hemorrhage, none were reported to have any permanent pulmonary disease.

#### Outcomes: pregnancy

Vaginal and cesarean section delivery were equally performed for live births (3/6 for both) (Table 3). Gestational

**Table 3.** Maternal, fetal and pregnancy-associated outcomes in *de novo* anti-GBM disease in pregnancy

	Nillsen [10]	Yankowitz [11]	Deubner [12]	Al-Harbi [13]	Vasiliou [14]	Nair [15]	Joseph [9]	London 2013
Outcomes: maternal								
Renal: antepartum	Normal	Normal	Proteinuria hematuria, mild RF	RPGN, daily HD	RPGN, daily HD	RPGN, alternate day HD	RPGN, daily HD	RPGN, daily HD
Post-partum	RPGN, HD, RTx	Normal	HD, RTx	HD	Partial renal recovery	Full renal recovery	HD, RTx	HD
Lung: Antepartum	Normal	'Hemoptysis' 'Dyspnea'	Normal	'Dyspnea', CXR: 'Congested'	'Hemoptysis' 'cough'	'Cough' 'Dyspnea'	Normal	Cough, dyspnea, VQ: 'pulmonary hemorrhage'
Post-partum	Normal	Normal	Normal	Normal	Normal	Normal	Normal	Normal
Outcomes: pregnancy								
Delivery method	V	C	V	C	C	V	V	V
Pregnancy-related complications	(-)	(-)	PEC	(-)	GDM, PEC	HG	GDM, HG, PCP	GDM, HG
Outcomes: fetal								
Livebirth	(-)(SB)	(+)	(+)	(+)	(+) <sup>a</sup>	(-)(TA)	(+)	(+)
Delivery date (weeks gestation)	28	37	35	34	26.5	15	35	35
Intrauterine growth restriction	NR	(-)	NR	NR	(+)	NR	(+)	(-)
Small for gestational age	NR	(-)	NR	(+)	(+)	NR	(+)	(+)
Complication of prematurity	NR	(-)	NR	(-)	(+)	NR	(-)	(-)
Newborn anti-GBM antibodies	NR	NR	(-)	(-)	(-)	NR	(+)	(+)
Newborn kidney or lung disease	NR	(-)	(-)	(-)	(-)	NR	(-)	(-)

CXR, chest X-ray; GDM, gestational diabetes mellitus; HD, hemodialysis; HG, hyperemesis gravidarum; NR, not reported; PCP, Pneumocystis carinii pneumonia; PEC, preeclampsia; RPGN, rapidly progressive glomerulonephritis; RTx, renal transplantation; SB, stillborn; TA, therapeutic abortion; VQ, ventilation-perfusion lung scan.

<sup>a</sup>Livebirth in Vasiliou born with 'massive intraventricular hemorrhage,' developed neurodevelopmental delay, visual dysfunction, failure to thrive.

diabetes (3/8), preeclampsia (2/8), hyperemesis gravidarum (2/8) and severe infections (1/8) were reported complications in pregnancy.

#### Outcomes: fetal

Most (6/8) cases resulted in singleton live births (Table 3). However, all live births were premature (6/6 live births), with severe prematurity (26.5 weeks) in one case. When reported, intrauterine growth restriction (3/4) and small for gestational age (4/5) were common. One infant had severe complications of prematurity with intraventricular and intraparenchymal hemorrhage, and at 1 year continued to have neurocognitive delay [14]. Anti-GBM antibodies were measured (5/8) and present in only two newborns. However, no kidney or lung disease was reported in any of the newborns.

## Discussion

Our study confirms that maternal, pregnancy and fetal outcomes in *de novo* anti-GBM disease in pregnancy are poor, comparable to systemic lupus erythematosus (SLE). From a maternal perspective, the chance of renal recovery is very low. Interestingly, one dialysis-dependent patient had complete recovery of renal function with aggressive treatment and therapeutic abortion at 15 weeks compared with all other patients who reached ESRD or had severe renal dysfunction despite coming off hemodialysis. Pregnancy may worsen the clinical course in SLE patients [16], and therapeutic abortion may be recommended in

severe circumstances [17]. This may suggest that similar to SLE patients, pregnancy may worsen the clinical course. Pregnancy complications were also high in *de novo* anti-GBM disease treated with immunosuppression, with high rates of gestational diabetes (3/8), preeclampsia (2/8), hyperemesis gravidarum (2/8) and serious infection (1/8). Finally, fetal complications in *de novo* anti-GBM disease in pregnancy are high, with prematurity (6/6 live births), intrauterine growth restriction (3/4), small for gestational age (4/5) and congenital abnormalities (2/6 live births). Fetal demise or severe adverse fetal outcomes were present in three of eight. While live births are possible in *de novo* anti-GBM disease (6/8), understanding the risks of renal biopsy, immunosuppression and hemodialysis are crucial to fully inform the mother of her optimal management decisions.

Renal biopsy during pregnancy was performed in only a minority (3/8) of cases (Table 2). While initial reports of antepartum renal biopsies were associated with high rates of bleeding complications [18], this was confounded by concurrent hypertension and preeclampsia, conditions in which a bleeding complication is well recognized [19]. Indeed, more recent trials indicate similar complication rates between pregnant and non-pregnant patients [20, 21]. Furthermore, renal biopsy results can significantly alter management decisions. In Vasiliou *et al.* and Joseph *et al.* cases, renal biopsy revealed >50% crescentic glomeruli [14] suggesting renal recovery was quite unlikely [22]. Under such circumstances, immunosuppression with the potentially teratogenic cyclophosphamide could be avoided if the patient does not have persisting pulmonary hemorrhage. Nair *et al.* [15] renal biopsy results may have informed patient counseling and decision-making. Thus,



renal biopsy during pregnancy should be performed with caution, but ultimately should be considered when it offers the opportunity to make a diagnosis other than severe preeclampsia (far) from term [23].

The goal of treatment in *de novo* Goodpasture's disease in pregnancy must be to induce remission, in light of the significant maternal and fetal morbidity and mortality associated with uncontrolled vasculitis [17, 24]. Induction therapy for *de novo* Goodpasture's disease may require a combination of corticosteroid with oral or intravenous cyclophosphamide (CYC), followed by maintenance immunosuppression with azathioprine [25–27]. Systemic corticosteroids are generally considered low risk for teratogenicity, with historical links to cleft palate [28, 29] although this association is unclear [30]. Reported associations with adverse pregnancy outcomes [30, 31] are difficult to disentangle from the effects of the disorder for which the pregnant women is being treated [28]. Of cases in which immunosuppression was started in pregnancy with a goal of a live birth, all received a high dose then tapering doses of corticosteroids. Corticosteroids increase the risk of gestational diabetes [32], a complication seen often in our review (3/8) [9, 11, 14]. Thus, it is important to monitor for adverse effects of corticosteroids while simultaneously inducing disease remission, particularly pulmonary hemorrhage, as a primary goal.

The Food and Drug Administration (FDA) has evaluated cyclophosphamide as Category D, indicating positive evidence of human fetal risk, but potential benefits may warrant use of the drug in pregnant women despite potential risks [33]. Use of cyclophosphamide during the first trimester, during organogenesis, has been associated with malformation [34, 35] and miscarriages [35]. Growth retardation, suppression of fetal hematopoiesis and impaired neurological development have been reported with use later in pregnancy in the second and third trimesters [34, 35]. Cyclophosphamide use during pregnancy has been associated with adverse outcomes in SLE [36–38]. Cyclophosphamide exposure increases long-term risk of malignancies in patients treated with the drug [39] and papillary thyroid cancer and neuroblastoma was reported in a child exposed *in utero* to cyclophosphamide [40]. It is difficult to extrapolate the effects of cyclophosphamide during pregnancy in *de novo* anti-GBM disease in pregnancy from our study, since only one of our cases was exposed. Potential benefits may warrant use of the drug in select pregnant women with severe disease despite the known potential fetal risks. The decision whether or not to initiate cyclophosphamide should be made after considering the stage of pregnancy, weighing the relative efficacy of alternative therapies, and counseling of patients regarding maternal and fetal risks.

The use of azathioprine has been established as safe throughout pregnancy in a variety of clinical settings; transplant, inflammatory bowel and SLE literature [41, 42]. A meta-analysis did not find an association between maternal thiopurine exposure for inflammatory bowel disease and congenital defects [43]. Lower birth weight and higher prematurity rate have been reported but may be an effect of maternal underlying disease [44]. While ineffective for induction of severe anti-GBM disease, use of azathioprine may be appropriate in mild *de novo* anti-GBM disease in pregnancy. Moreover, use of azathioprine in combination with plasmapheresis may permit deferral of cyclophosphamide use until after pregnancy. Azathioprine-associated bone marrow suppression should be monitored [45]. Maternal thiopurine use has been associated with anemia and

thrombocytopenia [46, 47] and leucopenia [48] in newborns. Thus, judicious use of azathioprine, with close monitoring for associated side effects, may be appropriate to optimize maternal and fetal outcomes.

In non-pregnant patients with incident Goodpasture's disease, plasmapheresis may be indicated in the presence of pulmonary hemorrhage [49] or AKI with a reasonable likelihood of recovery [27]. Typically, daily or alternate daily plasma exchanges with albumin are performed for 2–3 weeks [22, 26, 49], unless ongoing bleeding is present, in which case fresh frozen plasma may be used to replace blood clotting factors [25]. In combination with immunosuppression, plasmapheresis reduces titers of anti-GBM antibodies. Most mothers in our series (6/8) had detectable anti-GBM antibodies during pregnancy, and the levels were significantly lowered with plasmapheresis. Plasmapheresis is generally considered safe in pregnancy [50].

There is strong evidence that anti-GBM antibodies bind human placental antigens [51]; however, the clinical impact of this is controversial. Deubner et al. [12] hypothesized a protective effect of non-specific placental binding of anti-GBM antibodies, leading to decreased transfer to the fetus, and decreased total anti-GBM antibody maternal levels.

Joseph et al. [9] performed placental testing of IgG antibodies and showed diffuse binding of IgG antibodies; unfortunately, specific testing for anti-GBM antibodies could not be done. They postulated that anti-GBM binding to placenta may increase the risk of placental insufficiency and ultimately preeclampsia if not treated aggressively similar to Vasillou et al. [14]. Anti-GBM antibodies are IgG antibodies and as such are actively transported across the placenta via placental transporters; therefore, it is expected that the fetus would be exposed to all maternal IgG antibodies including anti-GBM antibodies.

Newborn anti-GBM antibody levels were commonly negative in our series (3/5) [12–14]. However, maternal anti-GBM levels in these three cases were negative [13], 'decreasing,' [14] or 'borderline' when measured closer to delivery [12]. To determine whether anti-GBM antibodies transfer across the placenta, simultaneous collection of maternal, neonatal and cord blood must be performed at a time when maternal anti-GBM titers are detectable. Simultaneous evaluation at delivery confirmed anti-GBM titers equivalent (mother = 4.3 U/mL, newborn = 6.5 U/mL, cord blood = 5.8 U/mL) [9] or lower in the mother (London, 2013: mother < 2.5 U/mL, newborn = 9.0 U/mL). Thus, anti-GBM antibodies cross the placenta, and it is unlikely that the placenta plays a protective role. While there remain no reported cases of newborn anti-GBM disease, this provides only some reassurance given only six described live births from mothers with *de novo* anti-GBM disease in pregnancy (Table 3). Moreover, transplacental antibody transmission has been linked to neonatal pulmonary-renal syndrome from myeloperoxidase-ANCA antibodies [52, 53], and neonatal lupus erythematosus from a variety of lupus antibodies [54].

Literature regarding hemodialysis in pregnancy has expanded since the first report of *de novo* anti-GBM disease in pregnancy, in 1986 [10]. Comprehensive reviews of this topic are available [55, 56]. Adverse maternal and fetal outcomes in women with end-stage kidney disease on hemodialysis are common, including maternal hypertension, anemia and preeclampsia, and fetal intrauterine growth restriction, polyhydramnios, prematurity and death [57, 58]. Ultimately, great attention to calcium and phosphate balance, nutrition, iron supplementation and anemia, dialysis duration, target weight, and blood pressure is required [55, 56], to optimize outcomes.

Pregnancies complicated by vasculitis, the need for hemodialysis and immunosuppression require special expertise using a multidisciplinary approach to optimize maternal, pregnancy and fetal outcomes. Input from high risk obstetrics, dietician, social work, clinical pharmacy, neonatology, nephrology, pediatrics and anesthesia are all beneficial. The need for this expertise necessitates patient admission to an academic hospital with the resources to facilitate management.

In conclusion, *de novo* anti-GBM disease in pregnancy is associated with poor maternal and fetal outcomes. Given the complexity of issues and decisions surrounding renal biopsy and immunosuppression, a multidisciplinary team is needed to provide comprehensive patient counseling and to optimize maternal, pregnancy and fetal outcomes.

*Conflict of interest statement.* None declared.

## References

- Couser WG. Rapidly progressive glomerulonephritis: classification, pathogenetic mechanisms, and therapy. *Am J Kidney Dis* 1988; 11: 449–464
- Andrassy K, Kuster S, Waldherr R *et al.* Rapidly progressive glomerulonephritis: analysis of prevalence and clinical course. *Nephron* 1991; 59: 206–212
- Kambham N. Crescentic Glomerulonephritis: an update on Pauci-immune and Anti-GBM diseases. *Adv Anat Pathol* 2012; 19: 111–124
- Goodpasture EW. The significance of certain pulmonary lesions in relation to the etiology of influenza. *Am J Med Sci* 1919; 158: 863–870
- Benoit FL, Rulon DB, Theil GB *et al.* Goodpasture's syndrome: a clinicopathologic entity. *Am J Med* 1964; 37: 424–444
- Bolton WK. Goodpasture's syndrome. *Kidney Int* 1996; 50: 1753–1766
- Gammill HS, Jeyabalan A. Acute renal failure in pregnancy. *Crit Care Med* 2005; 33: S372–S384
- Krane NK. Acute renal failure in pregnancy. *Arch Intern Med* 1988; 148: 2347–2357
- Joseph G, Edris F, Martens M *et al.* SA-PO750: A Pregnancy Complicated by RPGN Secondary to Anti-GBM Disease. San Diego, CA, USA: American Society of Nephrology, 2006. Journal of the American Society of Nephrology 2006; p. 732A.
- Nilssen DE, Talseth T, Brodwall EK. The many faces of Goodpasture's syndrome. *Acta Med Scand* 1986; 220: 489–491
- Yankowitz J, Kuller JA, Thomas RL. Pregnancy complicated by Goodpasture syndrome. *Obstet Gynecol* 1992; 79: 806–808
- Deubner H, Wagnild JP, Wener MH *et al.* Glomerulonephritis with anti-glomerular basement membrane antibody during pregnancy: potential role of the placenta in amelioration of disease. *Am J Kidney Dis* 1995; 25: 330–335
- Al-Harbi A, Malik GH, Al-Mohaya SA *et al.* Anti-glomerular basement membrane antibody disease presenting as acute renal failure during pregnancy. *Saudi J Kidney Dis Transpl* 2003; 14: 516–521
- Vasiliou DM, Maxwell C, Shah P *et al.* Goodpasture syndrome in a pregnant woman. *Obstet Gynecol* 2005; 106: 1196–1199
- Nair S, George J, Kumar S *et al.* A case of Goodpasture's syndrome complicating pregnancy with dialysis requiring renal failure responding to plasmapheresis and termination of pregnancy. *Ren Fail* 2013; 35: 1173–1175
- Lateef A, Petri M. Managing lupus patients during pregnancy. *Best Pract Res Clin Rheumatol* 2013; 27: 435–447
- Rahman A, Isenberg DA. Systemic lupus erythematosus. *N Engl J Med* 2008; 358: 929–939
- Schwartz LJ, Friedman IA, Pollak VE. Bleeding after renal biopsy in pregnancy. *Obstet Gynecol* 1965; 26: 295–304
- Wide-Svensson D, Strevens H, Willner J. Antepartum percutaneous renal biopsy. *Int J Gynaecol Obstet* 2007; 98: 88–92
- Packham D, Fairley KF. Renal biopsy: indications and complications in pregnancy. *Br J Obstet Gynaecol* 1987; 94: 935–939
- Day C, Hewins P, Hildebrand S *et al.* The role of renal biopsy in women with kidney disease identified in pregnancy. *Nephrol Dial Transplant* 2008; 23: 201–206
- Levy JB, Turner AN, Rees AJ *et al.* Long-term outcome of anti-glomerular basement membrane antibody disease treated with plasma exchange and immunosuppression. *Ann Intern Med* 2001; 134: 1033–1042
- Kuller JA, D'Andrea NM, McMahon MJ. Renal biopsy and pregnancy. *Am J Obstet Gynecol* 2001; 184: 1093–1096
- Nalli C, Iodice A, Andreoli L *et al.* The effects of lupus and anti-phospholipid antibody syndrome on foetal outcomes. *Lupus* 2014; 23: 507–517
- Lockwood CM, Rees AJ, Pearson TA *et al.* Immunosuppression and plasma-exchange in the treatment of Goodpasture's syndrome. *Lancet* 1976; 1: 711–715
- Jindal KK. Management of idiopathic crescentic and diffuse proliferative glomerulonephritis: evidence-based recommendations. *Kidney Int Suppl* 1999; 70: S33–S40
- Johnson JP, Moore J Jr, Austin HA 3rd *et al.* Therapy of anti-glomerular basement membrane antibody disease: analysis of prognostic significance of clinical, pathologic and treatment factors. *Medicine (Baltimore)* 1985; 64: 219–227
- Fraser FC, Sajoo A. Teratogenic potential of corticosteroids in humans. *Teratology* 1995; 51: 45–46
- Park-Wyllie L, Mazzotta P, Pastuszak A *et al.* Birth defects after maternal exposure to corticosteroids: prospective cohort study and meta-analysis of epidemiological studies. *Teratology* 2000; 62: 385–392
- Bermas BL. Non-steroidal anti inflammatory drugs, glucocorticoids and disease modifying anti-rheumatic drugs for the management of rheumatoid arthritis before and during pregnancy. *Curr Opin Rheumatol* 2014; 26: 334–340
- Reinisch JM, Simon NG, Karow WG *et al.* Prenatal exposure to prednisone in humans and animals retards intrauterine growth. *Science* 1978; 202: 436–438
- Vejrazkova D, Vcelak J, Vankova M *et al.* Steroids and insulin resistance in pregnancy. *J Steroid Biochem Mol Biol* 2014; 139: 122–129
- Sannerstedt R, Lundborg P, Danielsson BR *et al.* Drugs during pregnancy: an issue of risk classification and information to prescribers. *Drug Saf* 1996; 14: 69–77
- Baer AN, Witter FR, Petri M. Lupus and pregnancy. *Obstet Gynecol Surv* 2011; 66: 639–653
- Lannes G, Elias FR, Cunha B *et al.* Successful pregnancy after cyclophosphamide therapy for lupus nephritis. *Arch Gynecol Obstet* 2011; 283: 61–65
- Clowse ME, Magder L, Petri M. Cyclophosphamide for lupus during pregnancy. *Lupus* 2005; 14: 593–597
- Brucato A, Cimaz R, Caporali R *et al.* Pregnancy outcomes in patients with autoimmune diseases and anti-Ro/SSA antibodies. *Clin Rev Allergy Immunol* 2011; 40: 27–41
- Smyth A, Oliveira GH, Lahr BD *et al.* A systematic review and meta-analysis of pregnancy outcomes in patients with systemic lupus erythematosus and lupus nephritis. *Clin J Am Soc Nephrol* 2010; 5: 2060–2068
- Radis CD, Kahl LE, Baker GL *et al.* Effects of cyclophosphamide on the development of malignancy and on long-term survival of patients with rheumatoid arthritis. A 20-year follow-up study. *Arthritis Rheum* 1995; 38: 1120–1127
- Zemlickis D, Lishner M, Erlich R *et al.* Teratogenicity and carcinogenicity in a twin exposed in utero to cyclophosphamide. *Teratog Carcinog Mutagen* 1993; 13: 139–143
- Schramm C, Herkel J, Beuers U *et al.* Pregnancy in autoimmune hepatitis: outcome and risk factors. *Am J Gastroenterol* 2006; 101: 556–560

42. Moskovitz DN, Bodian C, Chapman ML et al. The effect on the fetus of medications used to treat pregnant inflammatory bowel-disease patients. *Am J Gastroenterol* 2004; 99: 656–661
43. Akbari M, Shah S, Velayos FS et al. Systematic review and meta-analysis on the effects of thiopurines on birth outcomes from female and male patients with inflammatory bowel disease. *Inflamm Bowel Dis* 2013; 19: 15–22
44. Goldstein LH, Dolinsky G, Greenberg R et al. Pregnancy outcome of women exposed to azathioprine during pregnancy. *Birth Defects Res A Clin Mol Teratol* 2007; 79: 696–701
45. Patel AA, Swerlick RA, McCall CO. Azathioprine in dermatology: the past, the present, and the future. *J Am Acad Dermatol* 2006; 55: 369–389
46. Jharap B, de Boer NK, Stokkers P et al. Intrauterine exposure and pharmacology of conventional thiopurine therapy in pregnant patients with inflammatory bowel disease. *Gut* 2014; 63: 451–457
47. de Boer NK, de Meij T, van Bodegraven AA. Thiopurines during pregnancy in inflammatory bowel disease: is there a risk for the (unborn) child? *Expert Rev Gastroenterol Hepatol* 2013; 7: 669–671
48. Davison JM, Dellagrammatikas H, Parkin JM. Maternal azathioprine therapy and depressed haemopoiesis in the babies of renal allograft patients. *Br J Obstet Gynaecol* 1985; 92: 233–239
49. Savage CO, Pusey CD, Bowman C et al. Antiglomerular basement membrane antibody mediated disease in the British Isles 1980–4. *Br Med J (Clin Res Ed)* 1986; 292: 301–304
50. Watson WJ, Katz VL, Bowes WA Jr. Plasmapheresis during pregnancy. *Obstet Gynecol* 1990; 76: 451–457
51. Derry CJ, Pusey CD. Tissue-specific distribution of the Good-pasture antigen demonstrated by 2-D electrophoresis and western blotting. *Nephrol Dial Transplant* 1994; 9: 355–361
52. Schlieben DJ, Korbet SM, Kimura RE et al. Pulmonary-renal syndrome in a newborn with placental transmission of ANCA. *Am J Kidney Dis* 2005; 45: 758–761
53. Bansal PJ, Tobin MC. Neonatal microscopic polyangiitis secondary to transfer of maternal myeloperoxidase-antineutrophil cytoplasmic antibody resulting in neonatal pulmonary hemorrhage and renal involvement. *Ann Allergy Asthma Immunol* 2004; 93: 398–401
54. Porcel Chacon R, Tapia Ceballos L, Diaz Cabrera R et al. Neonatal lupus erythematosus: a five-year case review. *Reumatol Clin* 2013; 10: 170–173
55. Nadeau-Fredette AC, Hladunewich M, Hui D et al. End-stage renal disease and pregnancy. *Adv Chronic Kidney Dis* 2013; 20: 246–252
56. Furaz-Czerpak KR, Fernandez-Juarez G, Moreno-de la Higuera MA et al. Pregnancy in women on chronic dialysis: a review. *Nefrologia* 2012; 32: 287–294
57. Piccoli GB, Conijn A, Consiglio V et al. Pregnancy in dialysis patients: is the evidence strong enough to lead us to change our counseling policy? *Clin J Am Soc Nephrol* 2010; 5: 62–71
58. Malik GH, Al-Harbi A, Al-Mohaya S et al. Pregnancy in patients on dialysis—experience at a referral center. *J Assoc Physicians India* 2005; 53: 937–941

Received for publication: 3.7.14; Accepted in revised form: 10.7.14