



ELSEVIER

Contents lists available at ScienceDirect

International Journal for Parasitology:  
Parasites and Wildlifejournal homepage: [www.elsevier.com/locate/ijppaw](http://www.elsevier.com/locate/ijppaw)

Invited Review

Species of *Angiostrongylus* (Nematoda: Metastrongyloidea) in wildlife:  
A review

David M. Spratt \*

Australian National Wildlife Collection, CSIRO National Research Collections, GPO Box 1700, Canberra, ACT 2601, Australia

## ARTICLE INFO

## Article history:

Received 15 January 2015

Revised 16 February 2015

Accepted 20 February 2015

## Keywords:

*Angiostrongylus* spp

Wildlife

Life cycles

Geographical distribution

Pathology

Zoonoses

## ABSTRACT

Twenty-one species of *Angiostrongylus* plus *Angiostrongylus* sp. (Nematoda: Metastrongyloidea) are known currently in wildlife. These occur naturally in rodents, tupaiids, mephitids, mustelids, procyonids, felids, and canids, and aberrantly in a range of avian, marsupial and eutherian hosts including humans. Adults inhabit the pulmonary arteries and right atrium, ventricle and vena cava, bronchioles of the lung or arteries of the caecum and mesentery. All species pass first-stage larvae in the faeces of the host and all utilise slugs and/or aquatic or terrestrial snails as intermediate hosts. Gastropods are infected by ingestion or penetration of first-stage larvae; definitive hosts by ingestion of gastropods or gastropod slime. Transmission of at least one species may involve ingestion of paratenic hosts. Five developmental pathways are identified in these life cycles. Thirteen species, including *Angiostrongylus* sp., are known primarily from the original descriptions suggesting limited geographic distributions. The remaining species are widespread either globally or regionally, and are continuing to spread. Small experimental doses of infective larvae (ca. 20) given to normal or aberrant hosts are tolerated, although generally eliciting a granulomatous histopathological response; large doses (100–500 larvae) often result in clinical signs and/or death. Two species, *A. cantonensis* and *A. costaricensis*, are established zoonoses causing neurological and abdominal angiostrongyliasis respectively. The zoonotic potential of *A. mackerrasae*, *A. malaysiensis* and *A. siamensis* particularly warrant investigation. *Angiostrongylus cantonensis* occurs in domestic animals, mammalian and avian wildlife and humans in the metropolitan areas of Brisbane and Sydney, Australia, where it has been suggested that tawny frogmouths and brushtail possums may serve as biosentinels. A major conservation issue is the devastating role *A. cantonensis* may play around zoos and fauna parks where captive rearing of endangered species programmes may exist and where *Rattus* spp. are invariably a problem. Crown Copyright © 2015 Published by Elsevier Ltd on behalf of Australian Society for Parasitology. This is an open access article under the CC BY-NC-ND license (<http://creativecommons.org/licenses/by-nc-nd/4.0/>).

## Contents

1. Introduction .....	179
2. Taxonomy .....	179
3. Host and geographic distribution of species occurring in wildlife .....	180
4. Life cycles .....	181
4.1. Type I .....	182
4.2. Type II .....	182
4.3. Type III .....	183
4.4. Type IV .....	183
4.5. Type V .....	183
5. Geographic distribution and epidemiology .....	184
6. Impacts on hosts – pathology and pathogenesis .....	184
7. Biodiversity and conservation issues .....	185
8. Species in need of further investigation .....	185
9. Conclusions .....	186

\* Australian National Wildlife Collection, CSIRO National Research Collections, GPO Box 1700, Canberra, ACT 2601, Australia. Tel.: +61 2 62421648; fax: +61 2 6242 1688. E-mail address: [dave.spratt@csiro.au](mailto:dave.spratt@csiro.au).

Acknowledgements .....	186
References .....	186

## 1. Introduction

The parasitic nematode genus *Angiostrongylus* Kamensky, 1905 belongs to the superfamily Metastrongyloidea, the so-called “lung-worms” of vertebrates. Species occur naturally in cricetid, heteromyid, soricid, glirid, sciurid and murid rodents, tupaiids, mephitids, mustelids, procyonids, felids, canids and aberrantly in a range of avian, marsupial and eutherian hosts including humans. Some species inhabit the pulmonary arteries and right ventricle, some develop in the brain and then migrate via the venous system to the heart and pulmonary arteries, some occur in mesenteric veins and others occur in the bronchioles of the lung. Regardless of site in the definitive host, all first-stage larvae pass through the gastrointestinal tract and exit with the faeces. All species in which the life cycle is known utilise gastropods (slugs and terrestrial and aquatic snails) as intermediate hosts and some species may also use paratenic or transport hosts.

## 2. Taxonomy

Readers are referred to [Ubelaker \(1986\)](#) and [Costa et al. \(2003\)](#) for a detailed taxonomic history of the genus *Angiostrongylus* and its treatment by numerous workers. Here, I offer only sufficient background to clarify the species I consider as occurring in wildlife.

The genus *Angiocaulus* was proposed by [Schulz \(1951\)](#) for *Angiostrongylus gubernaculatus* [Dougherty, 1946](#) from mustelids; however, [Chabaud \(1965\)](#) placed *Angiocaulus* as a synonym of *Angiostrongylus* and this was followed by [Drózdź \(1970\)](#) and [Anderson \(1978\)](#). [Drózdź \(1970\)](#) recognised two subgenera, *Angiostrongylus* (*Angiostrongylus*) and *Angiostrongylus* (*Parastrongylus*). In the former, the externolateral (sometimes termed anterolateral) ray of the bursa of males is separate from the other two lateral rays, and in the latter the externolateral ray is joined to a common stalk with the other lateral rays. [Chabaud \(1972\)](#) recognised *Angiostrongylus* and *Parastrongylus* as separate genera based on the above features of the bursa, the former occurring in carnivores with *A. vasorum*, *A. raillieti*, *A. chabaudi* and *A. gubernaculatus*; the latter occurring in rodents with *P. tateronae*, *P. cantonensis*, *P. mackerrasae*, *P. sandarsae*, *P. sciuri*, *P. dujardini* and *P. schmidti*.

[Anderson \(1978\)](#) proposed the family Angiostrongylidae for the genus *Angiostrongylus* and 16 related genera. He followed [Drózdź \(1970\)](#) in recognising two subgenera while appreciating that some authors ([Chabaud, 1972](#)) might prefer to regard these as separate genera. [Ubelaker \(1986\)](#) recognised separate genera, using morphological criteria of the male bursa which allowed separation along host groups as well. He relegated species often placed in the genus *Angiostrongylus* to six distinct genera all containing species located primarily in specific host groups. He recognised *Angiostrongylus* Kamensky, 1905 (syn. *Haemoststrongylus* [Railliet & Henry, 1907](#)) parasitic in the arterial vasculature of the heart and lungs of carnivores and *Parastrongylus* [Baylis, 1928](#) (syn. *Pulmonema* [Chen, 1935](#), *Rattoststrongylus* [Schulz, 1951](#), *Morerastrongylus* [Chabaud, 1972](#), *Chabaudistrongylus* [Kontrimavichus and Delyamure, 1979](#)) occurring in the arterial circulatory system of rodents (primarily Muridae). He placed the following species in each genus: *Angiostrongylus chabaudi*, *A. raillieti*, *A. vasorum*; *Parastrongylus cantonensis*, *P. costaricensis*, *P. dujardini*, *P. mackerrasae*, *P. malaysiensis*, *P. petrowi*, *P. rryjikovi*, *P. sandarsae*, *P. schmidti*, *P. siamensis* and *P. tateronae*. All the above species occur in the pulmonary arteries, right ventricle and lungs, with the exceptions of *A. costaricensis* and *A. siamensis* which occur in the mesenteric arteries of their hosts.

[Ubelaker \(1986\)](#) retained the genus *Angiocaulus* with type species *A. gubernaculatus* and placed *Cardionema ten Yamaguti, 1941* from *Martes malampus* in Japan in *Angiocaulus*, while recognising its close relationship with *Parastrongylus*. I follow [Chabaud \(1965\)](#), [Drózdź \(1970\)](#) and [Anderson \(1978\)](#) in recognising *Angiocaulus* as a synonym of *Angiostrongylus* and thus recognise *Angiostrongylus gubernaculatus*. Given the importance of the male bursa in defining genera in the Angiostrongylidae, I follow [Yamaguti \(1961\)](#) and recognise the species *A. ten* as *incerta sedis*, given it is based on female specimens only.

[Yanchev and Genov \(1988\)](#) described *Angiostrongylus daskalovi* from three mustelid species in Bulgaria incorrectly placing it in the Filarioidea rather than Angiostrongylidae and distinguishing it from *A. chabaudi*, *A. gubernaculatus* and *A. vasorum*. Subsequently, several new species of *Angiostrongylus* have been reported from members of the genus *Akodon* (Cricetidae) in South America; *A. morerai* from *Ak. azarae* in Argentina ([Robles et al., 2008](#)), *A. lenzii* from *Ak. montensis* in Brazil ([Souza et al., 2009](#)) and *A. sp.* from *Ak. cursor* and *Ak. montensis* in Brazil ([Simões et al., 2011](#)).

*Angiocaulus raillieti* was first described by [Travassos \(1927\)](#) as *Haemoststrongylus raillieti* from the crab-eating fox, *Cerdocyon thous azarae* (as *Canis azarae*) in Rio de Janeiro, Brazil. It was subsequently redescribed by [Grisi \(1971\)](#) from domestic dogs in Rio and he placed *Angiostrongylus vasorum* from dogs in Rio as a synonym of *Angiocaulus raillieti*. [Dougherty \(1946\)](#) reported *Angiostrongylus raillieti* in *C. a. thous* (as *Dusicyonhous azarae*), noting that the species was quite likely the same as *A. vasorum* from domestic dogs. [Gonçalves \(1961\)](#) identified *Angiostrongylus vasorum* in *C. a. thous* in Columbia and in domestic dogs in Brazil. [Rosen et al. \(1970\)](#) recognised *Angiocaulus raillieti* as a synonym of *Angiostrongylus vasorum*. [Costa et al. \(2003\)](#) redescribed *A. vasorum* from experimentally infected dogs in Brazil and concluded that *Angiocaulus* should be considered, if not a *nomen nudum* (sic), then at least a synonym of *Angiostrongylus*. Several other workers in South America have reviewed, in particular, morphological criteria of the male bursa of *A. vasorum* from dogs in Brazil ([Robles et al., 2008](#)) and foxes in Italy ([Souza et al., 2009](#)) demonstrating either that the lateral rays have a common trunk, although the externolateral ray is deeply cleft, a character shared by *A. chabaudi* and *A. morerai* ([Robles et al., 2008](#)), or that the right externolateral ray does not arise from a single trunk while the left externolateral ray does ([Souza et al., 2009](#)). Recently, [Jefferies et al. \(2009\)](#) looked at the molecular characterisation of isolates of *A. vasorum* from dogs in Europe and Brazil on the basis of the mitochondrial COI gene and the second ribosomal internal transcribed spacer. Sequence analyses revealed two distinct genotypes. Estimated rates of evolution based on the COI sequences for both nematodes and hosts were consistent with the hypothesis that the occurrence of *A. vasorum* in South America represents an ancient evolutionary event and may represent a cryptic species separate to that in Europe, implying that the synonymy of *A. raillieti* with *A. vasorum* may be premature.

*Angiostrongylus felineus* has recently been described from the puma, *Puma (Herpailurus) yagouaroundi*, in Brazil ([Vieira et al., 2013](#)).

As indicated above, features of the bursa and the morphology of its rays primarily define genera in the Angiostrongylidae including the genus *Angiostrongylus*. Despite the efforts to divide the genus *Angiostrongylus* into subgenera that conveniently separate species in carnivores from species in rodents, this separation now appears artificial rather than phylogenetic. With the exception of *A. ten*, *incerta sedis*, this review of *Angiostrongylus* in wildlife shall deal with each of the 21 above-mentioned species plus *Angiostrongylus sp.*,

**Table 1**  
Species of *Angiostrongylus* (n = 13) from wildlife known only from the original description and possibly an additional geographic record or discussion.

Parasite species	Host species	Site in host	Geographic locale	References
<i>A. chabaudi</i>	<i>Felis silvestris</i>	Lungs	Central Italy	Biocca, 1957
<i>A. daskalovi</i>	<i>Meles meles</i> , <i>Martes martes</i> , <i>M. foina</i> ,	Pulmonary arteries	Bulgaria,	Yanchev & Genov, 1988; Gerrikagoitia et al., 2010
<i>A. felineus</i>	<i>Puma (Herpailurus) yagouaroundi</i>	Pulmonary arteries	Brazil, Iberian Peninsula,	Vieira et al., 2013
<i>A. gubernaculatus</i>	<i>Taxidea taxus</i> , <i>Mephitis mephitis</i> , <i>Urocyon littoralis</i>	Heart (Right ventricle)	California, USA	Dougherty, 1946; Faulkner et al., 2001
<i>A. lenzii</i>	<i>Akodon montensis</i>	Pulmonary arteries	Rio de Janeiro, Brazil	Souza et al., 2009
<i>A. morerai</i>	<i>Akodon azarae</i>	Pulmonary arteries	Buenos Aires, Argentina	Robles et al., 2008
<i>A. petrovi</i>	<i>Dryomys nitedula</i>	Heart and bronchi	Azerbaijan, SSR	Tarzhimanova & Chertkova, 1969
<i>A. raillieti</i>	<i>Cercodyon thous azarae</i> , <i>Canis familiaris</i> , <i>Nasua nasua</i>	Pulmonary arteries (dubious, from mesenterium)	Rio de Janeiro, Brazil	Travassos, 1927; Grisi, 1971; Vieira et al., 2008; Jefferies et al., 2009;
<i>A. ryjickovi</i>	<i>Clethrionomys rutilus</i>		Northern Urals, USSR	Jushkov, 1971
<i>A. sandarsae</i>	<i>Praomys (=Mastomys) natalensis</i> , <i>Gerbil tatera</i>	Pulmonary arteries	Mozambique, Kenya, Africa	Alicata, 1968; Kamiya & Fukumoto, 1988
<i>A. sciuri</i>	<i>Sciurus vulgaris</i>	Pulmonary arteries	Turkey	Merdivenci, 1964
<i>Angiostrongylus</i> sp.	<i>Cercodyon thous</i> , <i>Eira barbara</i> , <i>Akodon cursor</i> , <i>A. montensis</i> ,	Lungs	Brazil	Vieira et al., 2008; Simões et al., 2011
<i>A. tateronae</i>	<i>Apodemus mystacinus</i>	Uncertain tissue site	Nigeria, Albania	Baylis, 1928; Erchardová, 1960

ignoring the increasingly controversial issue of subgenera and recognising that members of the genus *Angiostrongylus* represent a group of species exhibiting great variation in the arrangement of the lateral rays of the male bursa.

### 3. Host and geographic distribution of species occurring in wildlife

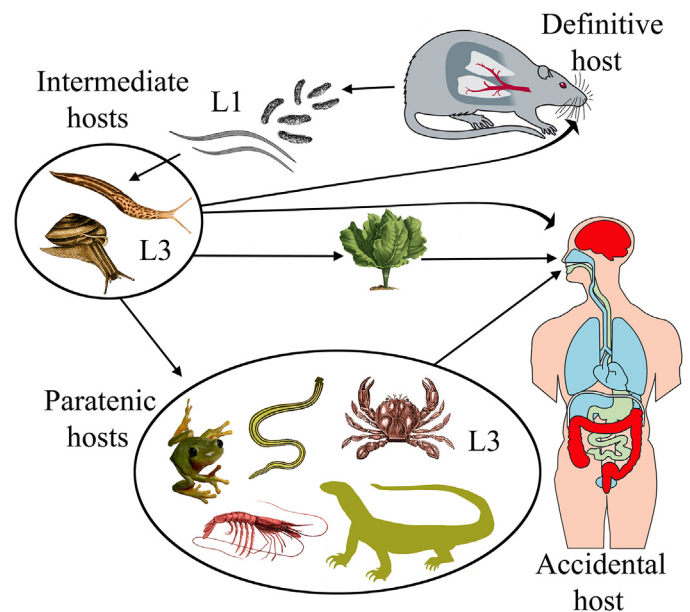
Species of *Angiostrongylus* (n = 13) occurring in wildlife and known only from the original description and possibly an additional geographic record or brief discussion are listed in Table 1.

*Angiostrongylus andersoni* was described from large abscesses in the lungs of the African gerbillid rodents, *Taterillus nigeriae* and *Tatera kempfi* from Upper Volta (Petter, 1972). First-stage larvae collected from the faeces of a host identified as being similar to (cf.) *Tatera nigrita* from Tchad were used to study the life cycle in molluscan intermediate hosts and in *T. cf. nigrita* and *Taterillus cf. congicus* from Tchad (Petter, 1974; Petter and Cassone, 1975).

*Angiostrongylus cantonensis* is a parasite of the pulmonary arteries and right ventricle of numerous wild *Rattus* spp., *Bandicota indica*, *Melomys burtoni*, *M. cervinipes* and *Suncus murinus* in the Asian, Pacific and Australian regions (Mackerras and Sandars, 1955; Cross, 1979a; Smales et al., 2004). Discovered originally in the pulmonary arteries and right ventricle of *Rattus rattus* and *R. norvegicus* in Guangzhou, China (Chen, 1935), it spread subsequently to South Asia, the Pacific islands and Australia where it is endemic (Alicata, 1988). The first reports of *A. cantonensis* in rats and humans in the Western Hemisphere were from Cuba (Aguiar et al., 1981), then Puerto Rico (Andersen et al., 1986), followed by the southeastern United States (Campbell and Little, 1988; Kim et al., 2002) where it is now considered endemic in wildlife. It has subsequently been reported from Jamaica (Lindo et al., 2002), Haiti (Raccurt et al., 2003) and Brazil (Simões et al., 2011). *Angiostrongylus cantonensis* is the causative agent of eosinophilic meningoencephalitis, a zoonotic infection of humans (Fig. 1). Consequently, there is an extensive literature. Readers are referred to relevant literature reviews: historical events (Alicata, 1988), the complex life cycle of this nematode and its myriad of natural and experimental intermediate and wildlife definitive hosts (Anderson, 1968, 1992; Jindrak, 1968; Wallace and Rosen, 1969; Bhaibulaya, 1975), the situation in Southeast Asia and Australia (Alicata and Jindrak, 1970; Cross, 1979a) and documented worldwide cases in humans (Wang et al., 2008).

*Angiostrongylus costaricensis*, like *A. cantonensis*, is a zoonotic infection and the causative agent of abdominal angiostrongyliasis in

humans in Costa Rica, Honduras, Mexico, Nicaragua, Brazil, Guatemala, Columbia and islands of the Caribbean (Miller et al., 2006). It was first discovered in the small branches of the mesenteric artery of humans in Costa Rica (Morera and Céspedes, 1971).



**Fig. 1.** The life cycle of *Angiostrongylus cantonensis*. Rat **definitive hosts** acquire third-stage larvae by ingesting infected **intermediate hosts**, aquatic or terrestrial snails and slugs. Larvae penetrate the stomach, enter the hepatic portal and mesenteric lymphatic systems and are carried to the heart and lungs. They enter alveoli, invade the pulmonary veins, are returned to the left heart and distributed around the body by the arterial circulation. Larvae reach the CNS, predominantly the cerebrum and cerebellum, grow and moult twice in the parenchyma and young adults invade the subarachnoid space of the brain. After about two weeks they invade the cerebral vein and move to the heart and pulmonary arteries where they mature. Eggs are carried in the blood to the lungs where they embryonate. First-stage larvae escape up the bronchial escalator, are swallowed, pass out in the faeces, are ingested by **intermediate hosts**, snails and slugs, and develop to third-stage infective larvae. A broad spectrum of animals – planarians, prawns, crabs, frogs and lizards may serve as **paratenic hosts** in which infective larvae reside but undergo no further development. Humans are an **accidental host** and infection may occur through ingestion of **intermediate** or **paratenic** hosts, the latter often eaten raw or their juices used in preparation of local dishes. Infective larvae may also leave molluscs and contaminate vegetables such as lettuce (adapted from Wang et al., 2008, fig. 1).

Granulomatous lesions with massive eosinophilic infiltrations occurred in the intestine and regional lymph nodes and contained encapsulated eggs and larvae, but these were never passed in faeces. Subsequently, *A. costaricensis* was found to occur commonly in arteries of the caecum and branches of the cranial mesenteric artery of rodent species in the families Cricetidae (*Sigmodon hispidus*, *Oligoryzomys* (= *Oryzomys*) *fulvescens*, *Sooretamys angouya* (syn. *Oryzomys nigripes*), *Zygodontomys microtinus*), Heteromyidae (*Liomys adspersus*) and Muridae (*Rattus rattus*, *R. norvegicus*) in Costa Rica, Brazil, Ecuador, the Canal Zone and the Republic of Panama (Tesh et al., 1973; Monge et al., 1978; Morera, 1978, 1985; Morera et al., 1983; Graeff-Teixeira et al., 1990).

*Angiostrongylus dujardini* occurs in the heart and pulmonary arteries of *Apodemus sylvaticus* and *Clethrionomys glareolus* in southern France (Drózdź and Doby, 1970a) and in *A. sylvaticus dichrurus* and *Apodemus* sp. in Portugal (Doby et al., 1971). Mészáros (1972) reported the species in these hosts plus *A. flavicollis* and *Pitymys subterraneanus* in Hungary. Tenora et al. (1983) recorded *A. dujardini* for the first time in Finland but only in *C. glareolus*; it was not found in *C. rutilus*, *C. rufocanus*, *Microtus agrestis*, *M. oeconomus*, *Arvicola terrestris* and *Apodemus flavicollis*. This species has also been reported in rodents in the Iberian Peninsula (Cordero del Campillo, 1994 cited in Gerrikagoitia et al., 2010).

*Angiostrongylus mackerrasae* is known from the right ventricle and pulmonary arteries of two indigenous rat species in Australia, the bush rat, *Rattus fuscipes*, in Queensland and New South Wales and the swamp rat, *R. lutreolus*, in Tasmania (Bhaibulaya, 1968; Procvic et al., 2000; Stokes et al., 2007). It also occurs in the introduced *R. norvegicus* and in mixed infections with *A. cantonensis* in this host in Queensland, but has not been reported in *R. rattus* (Bhaibulaya, 1968). The classic work by Mackerras and Sanders (1955) on the neurotropic behaviour of *A. cantonensis* in rats was, in fact, *A. mackerrasae* (see Bhaibulaya, 1975). Their status as distinct species was tested in a series of hybridization experiments (Bhaibulaya, 1974). Male F1 hybrids were sterile, but females were fertile. Although the author suggested that the species may cross-breed in nature, there has been no evidence forthcoming to date. Mackie et al. (2013) provided the first report of a patent infection of a species of *Angiostrongylus* in a non-murid host in Australia and the first report of *A. mackerrasae* in an accidental host, the black flying fox, *Pteropus alecto*. Taiwan monkeys (*Macaca cyclopis*) experimentally infected with *A. mackerrasae* showed no symptoms of infection and at necropsy no parasites or pathologic changes attributable to infection were observed (Cross, 1979b). Adult *A. mackerrasae* were recovered from the lungs of rat controls killed after several months. Despite its close similarity in morphology and life cycle to *A. cantonensis*, there is no evidence to date that this species is zoonotic.

*Angiostrongylus malaysiensis* was known originally as the Malaysian strain of *A. cantonensis* because of its difference from other strains of *A. cantonensis* when tested experimentally in Taiwan monkeys (Cross, 1979b). The Malaysian strain was capable of migrating to the central nervous system in monkeys in small numbers, causing some disease symptoms, but not death. In addition, the strain was able to immunise monkeys against the lethal effects of high numbers of larvae of geographic strains of *A. cantonensis* which were demonstrably pathogenic to monkeys (Cross, 1979b). Development of acquired immunity in rats to the Malaysian strain was minimal. It was subsequently described as a new species, *A. malaysiensis*, by Bhaibulaya and Cross (1971). Cross-breeding experiments by Cross and Bhaibulaya (1974) between *A. cantonensis* and *A. malaysiensis*, demonstrated that F1 hybrids developed to the adult stage but males were sterile, proving that *A. malaysiensis* was a valid species. It has been reported from the right ventricle and pulmonary arteries of *Rattus tiomanicus* (syn. *jalorensis*), *R. rattus diardii*, *R. exulans*, *R. argentiventer*, *R. norvegicus*, *R. muelleri*, *R. bowersi*, *R. surifer*, *R. annandalei*, *R. cremoriventer*, *R. whiteheadi*, *R. sabanus*,

*Suncus murinus* and *Tupaia glis* in Malaysia (Lim and Ramachandran, 1979a), in *R. tiomanicus*, *R. exulans* and *R. rattus diardii* in Indonesia (Bhaibulaya and Cross, 1971; Carney and Stafford, 1979a; Lim and Ramachandran, 1979a) and in *R. norvegicus*, *R. rattus* and the snail, *Achatina fulica*, in Thailand (Bhaibulaya and Techasophonmani, 1972; Pipitgool et al., 1997). Mixed infections with *A. cantonensis* occurred in *R. norvegicus* and *R. rattus* in Bangkok (Bhaibulaya and Techasophonmani, 1972). Lim and Ramachandran (1979a) list a variety of terrestrial slugs and terrestrial and aquatic snails as natural intermediate hosts of *A. malaysiensis* in eight habitats in Malaysia. The high prevalence and widespread distribution of *A. malaysiensis* in rodents in Malaysia and development of a monoclonal antibody-ELISA system sensitive to detecting *A. malaysiensis* adult worm antigens have led to an assumption that this species is the causative agent of angiostrongyliasis in that country (Ambu et al., 1997). However, as with the previous species and despite the close similarity in morphology and life cycle of *A. malaysiensis* and *A. cantonensis*, unequivocal evidence that *A. malaysiensis* is zoonotic has not been forthcoming to date.

*Angiostrongylus schmidtii* was described by Kinsella (1971) from the pulmonary artery and its branches of the rice rat, *Oryzomys palustris*, trapped in fresh water and saltwater marshes in Florida. He described the pathology associated with infection and subsequently described the complete life cycle and host specificity of *A. schmidtii* (Kinsella, 1971, 1987).

*Angiostrongylus siamensis* was described from the mesenteric arteries of *Rattus sabanus* northeast of Bangkok, Thailand, and was the first mesenteric species of *Angiostrongylus* to be recorded from Eurasia (Ohbayashi et al., 1979). Subsequent investigations added *R. berdmorei*, *R. rattus*, *R. surifer*, *Bandicota savilei* and *B. indica* as natural definitive hosts (Kamiya et al., 1980; Ohbayashi et al., 1983). A suspected case was reported in a crab-eating monkey, *Macaca fascicularis*, imported to Japan from Malaysia (Oku et al., 1983).

*Angiostrongylus vasorum* was found in the right ventricle and pulmonary arteries of the dog in Toulouse, France by Serres (1854) and was subsequently described by Baillet (1866). It is now known from a wide spectrum of canid hosts in different parts of the world including red foxes (*Vulpes vulpes*) in Europe (Bolt et al., 1994), the Basque Country of the Iberian Peninsula (Gerrikagoitia et al., 2010), Great Britain (Morgan et al., 2008) and Newfoundland, Canada (Jeffery et al., 2004); pampas foxes (*Pseudalopex gymnocerus*) in Bolivia (Fiorello et al., 2006); hoary foxes (*Pseudalopex vetulus*) and crab-eating foxes (*Cerdocyon thous*) in Brazil (Lima et al., 1994); wolves (*Canis lupus*) in Spain (Segovia et al., 2001; Torres et al., 2001) and Italy (Eleni et al., 2014); coyotes (*Canis latrans*) in Newfoundland and Labrador (Bourque et al., 2005); and badgers (*Meles meles*) in Spain (Miquel et al., 1993; Torres et al., 2001). Experimental infection of cats demonstrated that they are permissive rather than susceptible to infection and first-stage larvae were never passed in faeces of cats with adult female worms containing eggs (Guilhon and Cens, 1970; Dias et al., 2008).

#### 4. Life cycles

There are two modalities of infection of the gastropod intermediate host, either first-stage larvae are ingested while the snails or slugs are feeding on the faeces from an infected definitive host, or the first-stage larvae penetrate the foot of the gastropod while it crawls across substrate.

Similarly, there are two forms of transmission to the definitive host, either infective third-stage larvae are ingested when the definitive host eats the gastropod intermediate host or third-stage larvae emerge spontaneously from the gastropod and are subsequently ingested. The latter has been proposed as one mechanism of transmission of *A. cantonensis* to humans on improperly washed vegetables such as lettuce (Heyneman and Lim, 1967). These authors

demonstrated that infective larvae pass spontaneously from the slug, *Microparmarion malayanus*, the most common intermediate host of *A. cantonensis* (*A. malaysiensis*) in Malaya, while it is feeding. They remain viable for at least 72 hours embedded in the mucus trail of the slug. Barcante et al. (2003) experimentally infected *Biomphalaria glabrata* with first-stage larvae of *A. vasorum* and subjected them to four stimulus treatments to assess the emergence of third-stage larvae and then tested their infectivity in dogs. Most larvae emerged from snails in a water bath at 37 °C for 24 hours and from snails exposed to a 60W light bulb for 24 hours. Two dogs were infected demonstrating, rather artificially, that infection of dogs could occur without ingestion of infected gastropods. Brandao et al. (1998) experimentally infected veronicellid slugs of the genus *Phylocaulis*, described the kinetics of elimination of third-stage larvae in the mucus secretions of three species and confirmed the importance of *P. variegatus* as an intermediate host of *A. costaricensis*.

Transmission of at least one species of *Angiostrongylus* may involve paratenic hosts, hosts which ingest infected gastropods but in which no further larval development occurs. Land crabs, shrimp, frogs and monitor lizards may serve as paratenic hosts of *A. cantonensis* and are thought to be one of the major sources of human infection (Fig. 1). Ingestion of raw or undercooked meat of the invasive freshwater golden apple snail, *Pomacea canaliculata*, imported from South America as a food source, has become the major source of human infection in Taiwan, mainland China and possibly Japan, whereas ingestion of raw snails of the genus *Pila* is the major source of human infection in Thailand (Wang et al., 2008). In an experiment with surprising results, Bolt et al. (1993) exposed the common frog, *Rana temporaria*, to first-stage larvae; they developed to the infective stage in 30 days and were infective to a fox. Third-stage larvae of *A. vasorum* given to frogs remained viable for at least two weeks and these also were infective to a fox, demonstrating that *R. temporaria* could serve as both an intermediate and a paratenic host of this species.

The basic pattern of development in the definitive host is as follows. Hosts become infected by ingesting gastropods or a paratenic host and migrate, or are carried in the vascular system to a site where they undergo two moults from the third to the fourth and from the fourth to the fifth or sub-adult stage. Further movement may occur to a site where females lay eggs. The eggs become trapped in the arterioles of the lungs or the lower intestine and colon, hatch, and the first-stage larvae either emerge into the airways, move up the respiratory tree, are swallowed and pass out with faeces or escape into the intestinal lumen and pass out in faeces. Five types of development in definitive hosts are distinguished by the location of the third and fourth moults, where adult worms mature, and where first-stage larvae emerge from tissues.

#### 4.1. Type I

Two moults occur in the lungs where adults deposit eggs; first-stage larvae emerge, move up the airways, are swallowed and pass into the faeces. This developmental pathway is exemplified by *A. andersoni*, *A. dujardini* and *A. schmidtii*, parasites of rodents.

Larval development of *A. andersoni* occurs in experimentally infected aquatic snails, *Limnea stagnalis* and *Planorbis cornuus* (Petter, 1974; Petter and Cassone, 1975). Larvae developed equally well in these hosts and in the terrestrial snail *Helix aspersa*, but not in *Physa acuta* and *Arion hortensis*. Infection of aquatic snails was by ingestion. Larvae reached the third stage after 15 days, and occurred in nodules in the connective tissue and muscles throughout the body of the snails. Ingested third-stage larvae reached the liver of the definitive host in 14 hours, implying use of the hepatic portal system rather than direct migration through the peritoneal cavity. The majority of larvae were found in the lungs at 24 hours, again suggesting use of the circulatory system. Larvae moulted to fourth-stage

between days 2 and 3 and to young adults between days 5 and 6 after infection. Eggs underwent development in the lung parenchyma and first-stage larvae were passed in the faeces of infected rodents 24 days after infection.

A variety of aquatic snails collected from the habitat of rodents infected with *A. dujardini* served as suitable experimental intermediate hosts as well as *B. glabrata* (Doby and Drózdź, 1971). Terrestrial gastropods were either less suitable or unsuitable hosts. Natural infections with third-stage larvae were not found in gastropods collected from the habitat of infected hosts (Doby and Drózdź, 1971; Drózdź et al., 1971). Drózdź and Doby (1970b) examined the development in five species of wild and three species of laboratory definitive hosts and showed that there was no obligatory period of development in the central nervous system. Rather, larvae of *A. dujardini* penetrated the intestine of *A. sylvaticus* and *C. glareolus*, reached the liver and were in the lungs as early as 28 hours post infection. Development in the lungs was rapid with the third moult at day 3 and young adults at day 7. Unsegmented eggs occurred in the lungs at 16 days and larvae in the faeces at 24–26 days post infection. *Pitymys subterraneus*, hamsters and white mice were receptive to experimental infection but surprisingly, laboratory rats were not, despite development occurring experimentally in three rodent families, Cricetidae, Muridae and Muridae.

Kinsella (1987) used land snails, *Polygyra septemvolva* and the aquatic snail, *B. glabrata*, as experimental intermediate hosts of *A. schmidtii*. Third-stage infective larvae were recovered 26–28 days later and used to infect marsh rice rats (*Oryzomys palustris*), cotton rats (*Sigmodon hispidus*), white-footed deer mice (*Peromyscus leucopus*), *Mus musculus*, *Rattus norvegicus*, gerbils (*Meriones unguiculatus*) and golden hamsters (*Mesocricetus auratus*). At 12 hours after infection, 50% of larvae were recovered from the lungs and 43% from the liver of *O. palustris*, implying migration via the hepatic portal system, although the small size of the hosts does not preclude an alternative route. At 24 hours, 80% of larvae were recovered from the lungs. Eggs were first seen in the lungs at day 26 and the first larvae were observed in the faeces at day 31. The number of larvae recovered from rice rats in comparison with the number dosed was low (9–30%), implying a degree of resistance and perhaps the reason for lack of mortality in this natural host. *Peromyscus leucopus* were refractory to infection; all white mice, and hamsters died from infection, although worms developed to adult in the lungs. Larvae appeared in the lungs of gerbils but the hosts died prior to larvae appearing in the faeces. Patent infections were established in rice rats, cotton rats and white rats, with the first larvae appearing in the faeces at days 30–31. However, none of the 86 wild cotton rats, many trapped in the same sites as infected wild rice rats, were infected (Kinsella, 1971, 1974).

#### 4.2. Type II

Two moults occur in the visceral lymph nodes; sub-adults move via the venous system to the right ventricle and pulmonary arteries. Eggs hatch in the lungs and larvae emerge, pass up the airways, are swallowed and passed in the faeces. This developmental pathway is exemplified by *Angiostrongylus vasorum*, parasitic in canids.

Guilhon (1960, 1963) demonstrated that *Arion ater* and *A. rufus* were natural intermediate hosts of *A. vasorum* in France and infected dogs by forcing them to consume infected slugs. Rosen et al. (1970) conducted a number of experiments using aquatic and terrestrial gastropods. The slug, *L. alte*, contained large numbers of infective larvae, but there were relatively few in the other gastropods. Infective larvae were recovered from *B. glabrata* at 16 days. These migrated to the visceral lymph nodes of dogs where the third and fourth moults occurred at 4–5 days. Subadult worms then migrated via the hepatic portal vein, the liver and the caudal vena cava to reach the right ventricle and pulmonary arteries at days 9–10

after infection, where they matured. The prepatent period in experimentally infected dogs averaged 45 days. Guilhon and Cens (1973) confirmed the life cycle as reported by Rosen et al. (1970) and provided morphological descriptions of the various life stages. Of 17 terrestrial molluscs tested, 11 proved suitable intermediate hosts as well as the aquatic snails *B. glabrata* and *Physa* sp.

#### 4.3. Type III

Two moults occur in the neural parenchyma of the central nervous system (primarily the brain); sub-adults relocate to the right heart and pulmonary arteries, eggs are filtered out in the lungs, hatch and larvae emerge, pass up the airways, are swallowed and passed in the faeces. This developmental pathway is exemplified by *A. cantonensis*, *A. mackerrasae* and *A. malaysiensis*, parasitic in rodents (Fig. 1).

The slug *Deroceras laevis* (= *Agriolimax laevis*) and an indigenous snail, *Helicarion* sp. have been used as experimental intermediate hosts for *A. cantonensis* and *A. mackerrasae* (Mackerras and Sandars, 1955; Bhaibulaya, 1974, 1975). The latter author reported the first moult of *A. cantonensis* and *A. mackerrasae* in snails at 7–10 days and the second at 12–16 days. At both moults, larvae retained the sheaths of the previous stage. Using a PCR-based detection assay, Teem et al. (2013) demonstrated that introduced apple snails, *Pomacea maculata*, were infected with *A. cantonensis* in Louisiana but not in Texas, Mississippi and Florida. However, the introduced giant African snail, *Ac. fulica*, was found infected in Florida, indicating that the parasite is now established in Florida as well as Louisiana. *Angiostrongylus cantonensis* developed to infective third-stage larvae in a broad range of aquatic and terrestrial gastropods in the southeastern USA (Richards and Merritt, 1967; Campbell and Little, 1988).

The aquatic snail, *Lymnea rubiginosa*, was used as an experimental intermediate host for *A. malaysiensis* and natural infections occurred primarily in the slugs *Microparmarion malayanus*, *L. alte* and *Girasia peguensis*; the terrestrial snails *Macrochlamys resplendens* and *Ac. Fulica*; and the aquatic snails of rice fields, *Pila sututu*, *Bellamyia ingalisiana*, *Indoplanorbis exustus* and *L. rubiginosa* (Lim and Ramachandran, 1979a). These authors recorded the first moult in experimentally infected snails at 5–7 days and the second at 9–12 days. Following ingestion by laboratory rats of infective third-stage larvae of *A. cantonensis*, *A. mackerrasae* and *A. malaysiensis*, most larvae penetrated the stomach and entered the hepatic portal and mesenteric lymphatic system carrying them to the heart and lungs (Bhaibulaya, 1975; Lim and Ramachandran, 1979a). They entered alveoli, invaded the pulmonary veins, were returned to the left heart and then distributed around the body in the arterial circulation. Larvae reached the central nervous system, primarily the cerebrum, 2–3 days post-infection where growth and both moults occurred in the neural parenchyma. Young adults invaded the sub-arachnoid space where they resided for 2 weeks before entering the cerebral vein and being carried to the right heart and pulmonary arteries where they matured. Oviposition occurred in the lungs and first-stage larvae occurred in the faeces. The following minor differences occurred in the respective life cycles: (i) the third moult in the definitive host occurred at the same time in *A. cantonensis* and *A. malaysiensis* at 4–6 days and a few days earlier than in *A. mackerrasae* at 6–10 days; (ii) the fourth moult occurred earlier in *A. cantonensis* at 7–9 days than in *A. malaysiensis* at 8–12 days and *A. mackerrasae* at 10–11 days; (iii) *A. malaysiensis* reached the pulmonary arteries at days 24–28, *A. mackerrasae* at days 25–26 and *A. cantonensis* at days 26–29; (iv) the prepatent period was 32 days in *A. malaysiensis*, 40–42 days in *A. mackerrasae* and 42–45 days in *A. cantonensis* (Bhaibulaya, 1979a). There were no differences in the migratory patterns of infective larvae in experimentally infected definitive hosts.

In addition to a period of larval development in terrestrial or aquatic gastropods, the life cycle of *A. cantonensis* may involve a range of paratenic hosts (freshwater prawns, land crabs, planarians, frogs, lizards) which feed on gastropods (Fig. 1). Human infection frequently involves these paratenic hosts which are eaten raw or the juices are used in the preparation of local dishes. Infective larvae may survive several days in fresh water and Heyneman and Lim (1967) have shown that larvae may leave molluscs and contaminate vegetables. The use of paratenic hosts has not been determined in *A. mackerrasae* and *A. malaysiensis*.

#### 4.4. Type IV

Two moults occur in the mesenteric lymph nodes and vessels; sub-adults relocate to the arterioles of the colon and mesentery, adults occur in the mesenteric arteries of the lower small intestine and colon, eggs are lodged in the capillaries, first-stage larvae escape into the intestinal lumen and are passed in the faeces. This developmental pathway is exemplified by *A. siamensis*, parasitic in rodents.

Kamiya et al. (1980) examined 278 small mammals from six localities in Thailand for *A. siamensis*, noting infection in *Rattus berdmorei*, *R. rattus*, *R. sabanus* and *R. surifer*. Intestinal wall containing first-stage larvae was fed to *B. glabrata*. Third-stage larvae were recovered 25 days later and fed to rats, cotton rats and Mongolian gerbils. First stage larvae were shed in the faeces of cotton rats and rats after 29 and 34 days, respectively. Two gerbils died at 21 and 25 days and contained adult worms, but larvae were not shed in faeces. Kudo et al. (1983) maintained *A. siamensis* in the laboratory using *B. glabrata* as the intermediate host and mice, laboratory rats, cotton rats and Mongolian gerbils as definitive hosts. They traced the development and migration route of the parasite in white mice. Third-stage larvae entered the wall of the colon and caecum, and migrated to the marginal and intermedial sinuses of the mesenteric lymph nodes and vessels where the third moult occurred between 30 and 72 hours and the fourth moult between 4 and 7 days post infection. Young adults moved from the lymphatic vessels to arterioles of the colon and mesentery, then reached the mesenteric arteries and branches supplying the lower small intestine and caecum. Oviposition commenced 22 days post infection. Eggs released into the blood lodged in the capillaries of the lower small intestine, caecum and colon. Larvae escaped into the lumen of the intestine and appeared in the faeces 31 days post infection.

#### 4.5. Type V

Infective larvae undergo primarily a lymphatic/venous-arterial pathway and secondarily a venous portal pathway. In the former, one moult occurs in the abdominal lymphatic system and another in the arteries of the caecum and large intestine, subadults and adults occur in the arterial vessels of these organs, eggs are lodged in the arterioles, first-stage larvae escape into the intestinal lumen and are passed in the faeces. In the secondary pathway, two moults occur in venous intra-hepatic vessels; eggs laid here by females embolise, adults migrate to the mesenteric veins, first-stage larvae escape into the intestinal lumen and are passed in the faeces. This developmental pathway is exemplified by *A. costaricensis*, parasitic in rodents.

The first-stage larvae of *A. costaricensis* gain the molluscan intermediate host simultaneously by an oral and percutaneous route (Morera, 1973; Mendonça et al., 1999). Veronicellid slugs are the main intermediate hosts (Morera and Ash, 1970; Morera, 1973; Morera et al., 1988); however, the limacid slugs, *Limax maximus* and *L. flavus*, and *Bradybaena similaris* are also suitable intermediate hosts in nature (Graeff-Teixeira et al., 1993). I am not aware of a study of developmental stages and times in the slug intermediate host. Development in the definitive host was reported by Morera (1973) and

Mota and Lenzi (1995, 2005). Following ingestion by mice or the natural definitive host, *Sigmodon hispidus*, infective larvae underwent two migratory routes, a lymphatic/venous-arterial pathway and a venous portal pathway, the former considered the principal one. In this pathway, larvae entered lymphatic vessels of the stomach, large intestine, mesentery and mesenteric lymph nodes where they were found from 3 hours to 11 days, preferentially in the vessels of the submucosa. The fourth moult occurred in the abdominal lymphatic system about day 5, and fourth-stage larvae were found in the arteries of the caecum and large intestine from day 6 onwards. Parasites moulted to subadult in the arterial vessels about day 7 and most were in the definitive site in arterial vessels of the caecum, large intestine and mesentery by day 11. Oviposition commenced 15 days post infection; first-stage larvae escaped into the lumen of the intestine and the prepatent period was 24 days. In the second pathway, development and maturation of *A. costaricensis* occurred in the liver together and independently of the parasites present in the lymphatic or arterial circulation. Third-stage larvae were found in venous intra-hepatic vessels 3 hours after infection; both moults occurred in this system and females laid eggs here, but these and first-stage larvae became embolised in intrahepatic venous vessels. Adults that developed in this pathway subsequently migrated to the mesenteric veins and first-stage larvae escaped into the lumen of the intestine.

## 5. Geographic distribution and epidemiology

The dearth of reports in the literature of many species of *Angiostrongylus* occurring in wildlife, *A. andersoni*, *A. chabaudi*, *A. daskalovi*, *A. felineus*, *A. gubernaculatus*, *A. lenzii*, *A. morerai*, *A. petrovi*, *A. raillieti*, *A. ryjikovi*, *A. sandarsae*, *A. schmidtii*, *A. sciuri*, *A. siamensis* and *A. tateronae*, suggests that they may have a rather limited geographic distribution. Alternatively, it may reflect lack of opportunity or interest in examining non-urban and non-agricultural hosts. Others species, *A. cantonensis*, *A. costaricensis*, *A. dujardini*, *A. mackerrasae*, *A. malaysiensis*, and *A. vasorum* are widespread, either globally or regionally. These species appear to be species on the move, spreading into regions where previously they did not occur (Mészáros, 1972; Campbell and Little, 1988; Procriv and Carlisle, 2001; Kim et al., 2002; Morgan et al., 2005; Miller et al., 2006; Stokes et al., 2007; Jefferies et al., 2010; Simin et al., 2014 and references therein). This is epitomised by the global movement of *A. cantonensis* from China through Asia to the Pacific region and Australia, and thence to the western hemisphere and the Americas under the aegis either of transport of infected *Rattus norvegicus* on ships or of intermediate hosts. For example, the giant African snail, *Ac. fulica*, long known as a suitable intermediate host of *A. cantonensis*, was recently introduced to Brazil as an alternative for *Helix aspersa*, providing the escargot for traditional French cuisine (Teles et al., 1997). When some of these snail farms collapsed, *Ac. fulica* spread into the wild and is thought to be partially responsible for the spread of *A. cantonensis* into some parts of Brazil. Cowie (2013) presents a detailed picture of the recent geographic distribution of *A. cantonensis*.

## 6. Impacts on hosts – pathology and pathogenesis

Experimental infections of natural and aberrant definitive hosts with *A. dujardini* indicated that small doses of infective larvae (ca. 20) were tolerated while large doses (50–1500) were not and often resulted in clinical signs and/or death (Drózdź and Doby, 1970b), a feature which may be general across species of *Angiostrongylus*. Nonetheless, studies of the routes taken by *A. cantonensis* and *A. mackerrasae* to the brain of rats (Bhaibulaya, 1975) and of *A. costaricensis* to the mesenteric arteries of cotton rats (Mota and Lenzi, 2005) have relied on large doses in the hope that some larvae would be found at examination of the various tissues post mortem.

Mackerras and Sandars (1955) described swollen lobes with mottled appearance and a firm pleural covering in lungs of rats infected with *A. mackerrasae* (as *A. cantonensis*, see Bhaibulaya, 1975). The cut surface revealed normal alveoli between masses of developing larvae with no sign of reaction around them while the intervening tissue was emphysematous with an infiltration of leucocytes into the surrounding tissues. Arteries containing worms became hypertrophied to accommodate the increasing bulk. A similar macroscopic picture was described by Alicata (1968) for *A. sandarsae*. Microscopically, lung parenchyma in affected lobes was replaced by nodules containing eggs or hatched larvae and consisting of fibrous tissue arranged concentrically and containing multinuclear giant cells and histiocytes (Alicata, 1968). Some arteries were extremely dilated but the walls did not show hypertrophy, thrombosis or degeneration of the musculature. The adventitia of infected and uninfected arteries was infiltrated primarily by plasma cells. Okano et al. (2014) reported *A. cantonensis* in Ryukyu Islands tree rats, *Diplothrix legata*, noted that pathological observations were similar to those reported by Mackerras and Sandars (1955) for *A. mackerrasae* and suggested that they might be lethal in this rat species. Lung lobes of rice rats infected with *A. schmidtii* were as described by Mackerras and Sandars (1955) for *A. mackerrasae* and by Alicata (1968) for *A. sandarsae*, i.e. swollen, mottled and firm to touch (Kinsella, 1971). The parenchyma of infected lobes was largely replaced by developing eggs and first-stage larvae. There was almost complete obliteration of the lumen of smaller arteries due to proliferation of the intima.

Natural infection with *A. cantonensis* in the USA, including deaths, has been reported in non-human primates (Gardiner et al., 1990), a miniature horse (Costa et al., 2000), a lemur (*Varencia variegata rubra*), wood rat (*Neotoma floridanus*) and opossums (*Didelphis virginiana*) (Kim et al., 2002). *Angiostrongylus cantonensis* has been reported from domestic animals, mammalian and avian wildlife and humans in eastern Australia (Table 2, Figs. 2 and 3). Some of these records and others from elsewhere in the world come from animals associated with zoos and nature parks where rat control, invariably, is a major issue.

The clinical signs of neck stiffness, headache, vomiting, paresis, paralysis and sometimes death in domestic animals, wildlife and humans infected with *A. cantonensis* are induced as a consequence of its obligatory period of development, two moults and maturation in the parenchyma, and the meninges of the central nervous system. Young adults invade and reside in the subarachnoid space of the brain before moving to the right heart and pulmonary arteries via the cerebral vein. Most of the paresis and paralysis observed in aberrant wildlife hosts in Australia occurs when the nematodes are still in the central nervous system and are late third-, fourth- or young adult stage (Spratt, 2005a, 2005b) (Table 2) (Figs. 2 and 3).

Robles et al. (2012) described thrombosis of the pulmonary artery and complete obliteration of the lumen in *Akodon dolores* infected with *A. morerai*. Macroscopic lesions of verminous pneumonia in the lungs were similar to those described for *A. mackerrasae* by Mackerras and Sandars (1955) and *A. sandarsae* by Alicata (1968). Histopathological examination revealed nodules formed as a result of larvae being surrounded by granulocytes and mononuclear cells.

Tesh et al. (1973) reported little or no inflammatory reaction to adults and eggs of *A. costaricensis* in moderately parasitised *S. hispidus*, *L. adpersus*, *O. fulvescens* and *R. rattus*. They noted that a mild inflammatory reaction with plasma cells and pigment-laden macrophages may occur and occasionally acute or granulomatous inflammation occurs around degenerating eggs or larvae. In severely infected individuals, regional lymph nodes were replaced by eosinophilic fibrogranulomatous tissue. In contrast to other infected rodent species, only 3 of 104 *Z. microtinus* were infected with *A. costaricensis*, few eggs were present in the caecum, those present

**Table 2**  
Records of *Angiostrongylus cantonensis* in abnormal vertebrate hosts in Australia.

Host: common name	Host: specific name	References
<i>Eutheria</i>		
Human	<i>Homo sapiens</i>	Gutteridge et al., 1972; Saltos, 1975; Cassar 1979; Heaton & Gutteridge 1980; Procriv & Tiernan, 1987; Procriv, 1999; Cooke-Yarborough et al., 1999 <sup>a</sup> (N4422) <sup>b</sup> ; Senanayake et al., 2003; Blair et al., 2013; Morton et al., 2013.
Dog	<i>Canis lupus familiaris</i>	Mason et al., 1976 (N250); Mason, 1987; Collins et al., 1992 (N3433); Lunn et al., 2012.
Horse	<i>Equus caballus</i>	Wright et al., 1991 (N3123)
Alpaca	<i>Vicugna pacos</i>	Hooper & Spratt, 1997 pers. obs. (N5231; P142)
Barbary sheep	<i>Ammotragus lervia</i>	Rose & Spratt, 2000 pers. obs.
Grey-headed flying fox	<i>Pteropus poliocephalus</i>	Reddacliff et al., 1999 (N4468); Barrett et al., 2002
Black flying fox	<i>Pteropus alecto</i>	Barrett et al., 2002
Tamarins	<i>Sanguinus</i> spp	Carlisle et al., 1998
	<i>Sanguinus oedipus</i>	Rose & Spratt, 2002 pers. obs. (N5248)
Squirrel monkey	<i>Saimiri sciureus</i>	Rose & Spratt, 2011 pers. obs. (N5236)
<i>Marsupialia</i>		
Bilby	<i>Macrotis lagotis</i>	Rose & Spratt, 2005 pers. obs.
Rufous bettong	<i>Aepyprymnus rufescens</i>	Higgins et al., 1997 (N4347)
Purple-necked rock wallaby	<i>Petrogale purpureicollis</i>	Rose & Spratt, 2001 pers. obs. (N5233)
Parma wallaby	<i>Macropus parma/eugenii</i> (hybrid)	Rose & Spratt, 2001 pers. obs. (N5235)
Bennett's wallaby	<i>Macropus rufogriseus</i>	McKenzie et al., 1978 (N395)
Western grey kangaroo	<i>Macropus fuliginosus</i>	Rose & Spratt, 2003 pers. obs. (N5315)
Common ringtail possum	<i>Pseudocheirus peregrinus</i>	Procriv pers. obs.
Brushtail possum	<i>Trichosurus vulpecula</i>	Rose, 1999 pers. obs.; Spratt, 2001 pers. obs.; Ma et al., 2013.
<i>Aves</i>		
Yellow-tailed black cockatoo	<i>Calyptorhynchus funereus</i>	Monks et al., 2005
Tawny frogmouth	<i>Podargus strigoides</i>	Rose & Spratt, 2000, 2001, 2002 pers. obs. (N5116, P139; N5210, P143); Monks et al., 2005; Gelis et al., 2011; Ma et al., 2013.
Brolga	<i>Grus rubicunda</i>	Rose & Walker, 2001 pers. obs.
Channel-billed cuckoo	<i>Scythrops novaehollandiae</i>	Rose, 2006 pers. obs.

<sup>a</sup> First identification in humans based on nematodes recovered from brains and lungs.

<sup>b</sup> Specimens held in Wildlife Parasite (N) and Wildlife Pathology (P) Collections, Australian National Wildlife Collection CSIRO Canberra.

were undeveloped and tissues surrounding eggs contained numerous eosinophils and multinucleated giant cells; some eggs were undergoing mineralisation (Tesh et al., 1973). Additional aberrant hosts of the parasite were the carnivorous coatimundi, *Nasua narica*, and the marmoset, *Saguinus mystax* (Monge et al., 1978). Ubelaker and Hall, 1979 reported *A. costaricensis* in two cotton rats from Texas which stood as the only endemic record of the parasite in the United States until Miller et al., (2006) reported it in a siamang, *Hylobates syndactylus*, born at the Miami MetroZoo; two Ma's night monkeys, *Aotus nancymae*, from the DuMond Conservancy at Monkey Jungle in Miami; four wild raccoons, *Procyon lotor*, trapped near the Metro Zoo; and an opossum, *Didelphis virginiana*, trapped at the Zoo. The primates were zoo-born, the raccoons and opossum native, indicating that the parasite is now endemic at two sites. Postulated sources of introduction of the parasite include (i) infected primates introduced to the zoo and subsequently infecting endemic molluscs and thus racoons and opossums; (ii) infected *Rattus* spp. introduced through the Miami seaport; (iii) third-stage larvae from molluscs contaminating imported food supplies fed to the primates.

Mota and Lenzi (2005), using doses of 100 to 500 larvae, reported inflammatory reactions in the abdominal lymphatic circulation of experimentally infected cotton rats to the presence of larval *A. costaricensis*. From day 9 onwards, larvae in the arterial system were accompanied by increasing eosinophil and macrophage infiltration and fibrinoid necrosis of the muscular layer with microhaemorrhages in the arterial wall. Immature and embryonated eggs carried by the blood lodged in the mucosal layer of the small and large intestine and caecum. By day 27, eggs and first-stage larvae were present in all layers of the intestinal and gastric wall surrounded by an inflammatory reaction. They also found eggs and first-stage larvae embolised in intra-hepatic venous vessels.

Ohbayashi et al. (1979) reported granulomatous thickening of the upper colon and granulomatous reactions against larval *A. siamensis* in infected *R. sabanus*.

## 7. Biodiversity and conservation issues

A major conservation issue with species of *Angiostrongylus* pertains primarily to the potentially devastating role *A. cantonensis* may play in and around zoos and fauna parks where control of *Rattus* spp. is invariably a problem (Table 2). It is potentially an important issue for wildlife rehabilitators and in the captive rearing and release of endangered species, programmes often associated with zoos and fauna parks. The reports of debilitating infection with *A. cantonensis* in tawny frogmouths, *Podargus strigoides* (Monks et al., 2005; Spratt, 2005b); yellow-tailed black cockatoos, *Calyptorhynchus funereus* (Monks et al., 2005); gang gang cockatoos, *Callocephalon fimbriatum* (Reece et al., 2013); and brushtail possums, *Trichosurus vulpecula* (Ma et al., 2013), in Brisbane and Sydney, Australia, serve as a further reminder that this nematode is well established in some parts of these capital cities and that neuro-angiostrongyliasis can be expected in aberrant species (Figs. 2 and 3). These include domestic, captive and free-living mammals and birds, and humans, especially children who deliberately or accidentally ingest snails or slugs containing infective larvae (Procriv and Tiernan, 1987; Procriv, 1999; Morton et al., 2013) or foolish young adults who do so for a bet (Senanayake et al., 2003; Blair et al., 2013). Tawny frogmouths, *P. strigoides*, and subadult brushtail possums, *T. vulpecula*, infected with *A. cantonensis* exhibit conspicuous neurological signs. They have been identified as potential biosentinels in the Sydney region (Spratt, 2005a, 2005b; Ma et al., 2013) (Figs. 2 and 3) and these hosts may be useful in monitoring the continuing southward spread of *A. cantonensis* in eastern Australia (Stokes et al., 2007).

## 8. Species in need of further investigation

The life cycles of *A. cantonensis*, *A. mackerrasae* and *A. malaysiensis* are extremely similar; all require a developmental phase, moults and growth in the central nervous system of the definitive host.



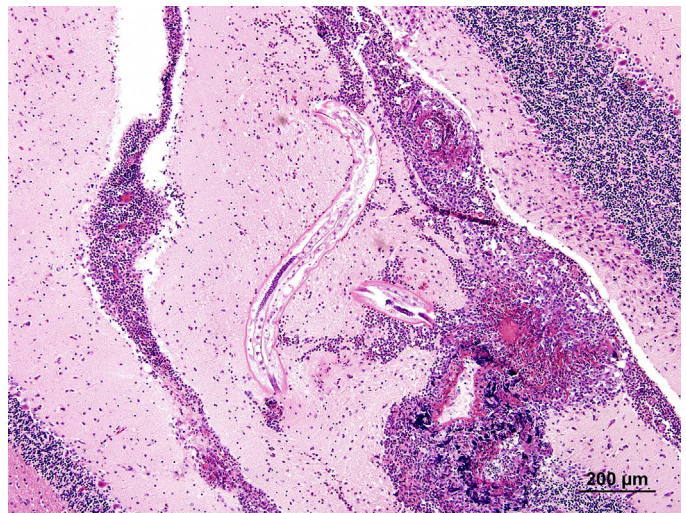
*Angiostrongylus mackerrasae* occurs in two native rats in Australia, *R. fuscipes* and *R. lutreolus*, and in co-infections with *A. cantonensis* in *R. norvegicus* but not in *R. rattus* (Mackerras and Sandars, 1955; Bhaibulaya, 1968; Prociw et al., 2000). Its zoonotic potential is unknown. This is similar to *A. malaysiensis* occurring in many native rodent species in Malaysia, Indonesia and Central Thailand, as well as in *R. norvegicus* and *R. rattus* and co-occurring with *A. cantonensis* in some rodent species (Bhaibulaya and Cross, 1971; Bhaibulaya, 1979a; Carney and Stafford, 1979a; Lim and Ramachandran, 1979a). *Angiostrongylus malaysiensis* has not been incriminated definitively in human infection but causes neural disease in experimentally infected monkeys (Cross, 1979b). It occurs more commonly than *A. cantonensis* in rats in Malaysia where the incidence of human angiostrongyliasis is relatively high (Lim and Ramachandran, 1979a). Close attention must be paid to the zoonotic potential of *A. mackerrasae* and *A. malaysiensis*. Oku et al. (1981) suggested that *A. siamensis* and *A. costaricensis* were closely related because they occupy the same niche in the definitive host, have similar life cycles and because F1 hybrids could be produced experimentally from both of them. Here again, the zoonotic predilection of *A. costaricensis* demands focus on the potential of *A. siamensis* to occur as a zoonosis.

## 9. Conclusions

Twenty one species of *Angiostrongylus* and *Angiostrongylus* sp. are reported here from wildlife around the world, thirteen of them with no further details concerning intermediate and definitive host, geographic range, pathogenesis nor life cycle. *Angiostrongylus cantonensis*, *A. costaricensis*, *A. dujardini*, *A. mackerrasae*, *A. malaysiensis* and *A. vasorum* appear to be species on the move, spreading into regions where previously they did not occur. The life cycles, pathogenesis and geographic distributions of the two zoonotic species, *A. cantonensis* and *A. costaricensis*, have been studied in detail. The zoonotic potential of other species with complex migratory pathways in definitive hosts, like these three species, i.e. *A. mackerrasae*, *A. malaysiensis* and *A. siamensis*, are deserving of further study. It is surprising, given the increasing occurrence and debilitating effects of *A. cantonensis* in mammalian and avian wildlife in Australia, that



**Fig. 2.** Tawny frogmouth, *Podargus strigoides*, with severe posterior paresis and unable to right itself due to infection with *Angiostrongylus cantonensis*.



**Fig. 3.** Immature *Angiostrongylus cantonensis* in the cerebellum of a brushtail possum, *Trichosurus vulpecula*, with extensive granulomatous and eosinophilic meningoencephalitis and malacia (adapted from Ma et al., 2013, fig. 7).

the same is not happening in wildlife species elsewhere in the world, or is it a case of such occurrences simply going undetected?

## Acknowledgements

The author expresses his thanks to Professor Ian Beveridge and an anonymous reviewer for critical evaluation of an earlier draft of the manuscript, to Dr. Crystal Kelehear for preparation of the Graphical abstract, to Drs. Richard Montali and Karrie Rose for provision of Fig. 2, and to Gemma Ma for provision of Fig. 3. Fig. 1 is adapted from The Lancet Infectious Diseases Vol. 8, Wang, Q-P, Lai, D-H, Zhu, X-Q, Chen, X-G, Lun, Z-R. Human angiostrongyliasis, pp. 621–630, October 2008, with permission from Elsevier, License number 3511700383518.

## References

- Aguiar, P.H., Morera, P., Pascual, J.E., 1981. First record of *Angiostrongylus cantonensis* in Cuba. *Am. J. Trop. Med. Hyg.* 30, 963–965.
- Alicata, J.E., 1968. *Angiostrongylus sandarsae* sp. n. (Nematoda: Metastrongyloidea), a lungworm of rodents in Mozambique, East Africa. *J. Parasitol.* 54, 896–899.
- Alicata, J.E., 1988. *Angiostrongylus cantonensis* (eosinophilic meningitis): historical events in its recognition as a new parasitic disease of man. *J. Wash. Acad. Sci.* 78, 38–46.
- Alicata, J.E., Jindrak, K., 1970. *Angiostrongylosis in the Pacific and Southeast Asia*. Charles C. Thomas Publisher, New York.
- Ambu, S., Noor Rain, A., Mak, J.W., Maslah, D., Maidah, S., 1997. Detection of *Angiostrongylus malaysiensis* circulating antigen using monoclonal antibody-based enzyme-linked immunosorbent assay (Mab-ELISA). *Southeast Asian J. Trop. Med. Public Health* 28 (Suppl. 1), 143–147.
- Andersen, E., Gubler, D.J., Sorenson, K., Beddard, J., Ash, L.R., 1986. First report of *Angiostrongylus cantonensis* in Puerto Rico. *Am. J. Trop. Med. Hyg.* 35, 319–322.
- Anderson, R.C.A., 1968. The pathogenesis and transmission of neurotropic and accidental nematode parasites of the central nervous system of mammals and birds. *Helm. Abs.* 37, 191–210.
- Anderson, R.C.A., 1978. Keys to genera of the superfamily Metastrongyloidea. In: Anderson, R.C., Chabaud, A.G., Willmott, S. (Eds.), *C.I.H. Keys to the Nematode Parasites of Vertebrates*, vol. 5. Commonwealth Agricultural Bureaux, Farnham Royal, Bucks, England.
- Anderson, R.C.A., 1992. *Nematode Parasites of Vertebrates. Their development and Transmission*. CAB International, Wallingford U.K.
- Baillet, C.C., 1866. Strongyle des vaisseaux et du coeur du chien. *Strongylus vasorum* (Nobis). *Nouveau Dictionnaire Pratique de Médecine, de Chirurgie et d'Hygiène vétérinaire*, v. 8, pp. 587–588.
- Barcante, T.A., Barcante, J.M., Dias, S.R., Lima Wdos, S., 2003. *Angiostrongylus vasorum* (Bailliet, 1866) Kamensky, 1905: emergence of third-stage larvae from infected *Biomphalaria glabrata* snails. *Parasitol. Res.* 91, 471–475.
- Barrett, J.L., Carlisle, M.S., Prociw, P., 2002. Neuro-angiostrongylosis in wild black and grey-headed flying foxes (*Pteropus* spp. Aust. Vet. J. 80, 554–558.

- Baylis, H.A., 1928. On a collection of nematodes from Nigerian mammals, chiefly rodents. *Parasitology* 20, 280–304.
- Bhaibulaya, M., 1968. A new species of *Angiostrongylus* in an Australian rat, *Rattus fuscipes*. *Parasitology* 58, 789–799.
- Bhaibulaya, M., 1974. Experimental hybridization of *Angiostrongylus mackerrasae* Bhaibulaya, 1968 and *Angiostrongylus cantonensis* (Chen, 1935). *Int. J. Parasitol.* 4, 567–573.
- Bhaibulaya, M., 1975. Comparative studies of the life history of *Angiostrongylus mackerrasae* Bhaibulaya, 1968 and *A. cantonensis* (Chen, 1935). *Int. J. Parasitol.* 5, 7–20.
- Bhaibulaya, M., 1979a. Morphology and taxonomy of major *Angiostrongylus* species of Eastern Asia and Australia. In: Cross, J.H. (Ed.), *Studies on Angiostrongyliasis in Eastern Asia and Australia*. Taipei, Taiwan, pp. 4–13. NAMRU-2 Special Publication No. 44.
- Bhaibulaya, M., 1979b. Geographical distribution of *Angiostrongylus* and angiostrongyliasis in Thailand, Indo-China and Australia. In: Cross, J.H. (Ed.), *Studies on Angiostrongyliasis in Eastern Asia and Australia*. Taipei, Taiwan, pp. 49–52. NAMRU-2 Special Publication No. 44.
- Bhaibulaya, M., Cross, J.H., 1971. *Angiostrongylus malaysiensis* (Nematoda: Metastrongylidae), a new species of rat lung-worm from Malaysia. *Southeast Asian J. Trop. Med. Public Health* 2, 527–533.
- Bhaibulaya, M., Techasophonmani, V., 1972. Mixed infections of *Angiostrongylus* spp. in rats. *Southeast Asian J. Trop. Med. Public Health* 3, 451.
- Biocca, E., 1957. *Angiostrongylus chabaudi* n. sp. parassita del Cuore e dei vasi polmonari del gatto selvatico (*Felis silvestris*). *Atti. Accad. Naz. Lincei R. C.* 22, 526–532.
- Blair, N.F., Orr, C.F., Delaney, A.P., Herkes, G.K., 2013. *Angiostrongylus meningoencephalitis*: survival from minimally conscious state to rehabilitation. *Med. J. Aust.* 198, 440–442.
- Bolt, C., Monrad, J., Frandsen, F., Henriksen, P., Dietz, H.H., 1993. The common frog (*Rana temporaria*) as a potential paratenic and intermediate host for *Angiostrongylus vasorum*. *Parasitol. Res.* 79, 428–430.
- Bolt, G., Monrad, J., Koch, J., Jensen, A.L., 1994. Canine angiostrongylosis: a review. *Vet. Rec.* 135, 447–452.
- Bourque, A., Whitney, H., Conboy, G., 2005. *Angiostrongylus vasorum* infection in coyote (*Canis latrans*) from Newfoundland and Labrador. *Can. J. Wildl. Dis.* 41, 816–819.
- Brandao, V.C., Bonetti, D.O., Graeff-Teixeira, C., 1998. *Angiostrongylus costaricensis* and the intermediate hosts: observations on elimination of L3 in the mucus and inoculation of L1 through the tegument of molluscs. *Rev. Soc. Bras. Med. Trop.* 31, 289–294.
- Campbell, B.G., Little, M.D., 1988. The finding of *Angiostrongylus cantonensis* in rats in New Orleans. *Am. J. Trop. Med. Hyg.* 38, 568–573.
- Carlisle, M.S., Prociw, P., Grennan, J., Pass, M.A., Campbell, G.A., Mudie, A., 1998. Cerebrospinal angiostrongyliasis in five captive tamarins (*Sanguinus* spp.). *Aust. Vet. J.* 76, 167–170.
- Carney, W.P., Stafford, E.E., 1979a. Angiostrongyliasis in Indonesia – a review. In: Cross, J.H. (Ed.), *Studies on Angiostrongyliasis in Eastern Asia and Australia*. Taipei, Taiwan, pp. 14–25. NAMRU-2 Special Publication No. 44.
- Cassar, E.J., 1979. Eosinophilic meningitis. *Aust. N. Z. J. Med.* 9, 600–603.
- Chabaud, A.G., 1965. Superfamille des Metastrongyloidea. In: Grassé, P.P. (Ed.), *Traité de Zoologie*. Masson et Cie, Paris, pp. 921–931.
- Chabaud, A.G., 1972. Description de *Stefanskostrongylus dubosti* n. sp. parasite de *Potomagale* et essai de classification des Nématodes Angiostrongyliinae. *Ann. Parasitol. Hum. Comp.* 47, 735–744.
- Chen, H.T., 1935. A new pulmonary nematode of rats, *Pulmonema cantonensis* n. sp. n. sp from Canton. *Ann. Parasitol. Hum. Comp.* 13, 312–317.
- Collins, G.H., Rothwell, T.L.W., Malik, R., Church, D.B., Dowden, M.K., 1992. Angiostrongylosis in dogs in Sydney. *Aust. Vet. J.* 69, 170–171.
- Cooke-Yarborough, C.M., Kornberg, A.J., Hogg, G.G., Spratt, D.M., Forsyth, J.R.L., 1999. A fatal case of angiostrongyliasis in an 11 month old infant. *Med. J. Aust.* 170, 541–543.
- Costa, J.O., de Araujo Costa, H.M., Guimaraes, M.P., 2003. Redescription of *Angiostrongylus vasorum* (Baillet, 1866) and systematic revision of species assigned to the genera *Angiostrongylus* Kamensky, 1905 and *Angiocaulus* Schulz, 1951. *Revue Méd. Vét.* 154, 9–16.
- Costa, L.R.R., McClure, J.J., Snider, T.G., III, Stewart, T.B., 2000. Verminous meningoencephalitis due to *Angiostrongylus cantonensis* in an American miniature horse. *Eq. Vet. Edu.* 12, 2–6.
- Cowie, R.H., 2013. Biology, systematics, life cycle and distribution of *Angiostrongylus cantonensis*, the cause of rat lungworm disease. *Hawaii J. Med. Public Health* 72, 6–9.
- Cross, J.H. (Ed.), 1979a. *Studies on Angiostrongyliasis in Eastern Asia and Australia*. US Naval Medical Research Unit, Taipei, Taiwan. NAMRU-2 Special Publication No. 44.
- Cross, J.H., 1979b. Experimental studies of *Angiostrongylus* species and strains in monkeys and laboratory animals. In: Cross, J.H. (Ed.), *Studies on Angiostrongyliasis in Eastern Asia and Australia*. US Naval Medical Research Unit, Taipei, Taiwan, pp. 118–137. NAMRU-2 Special Publication No. 44.
- Cross, J.H., Bhaibulaya, M., 1974. Validity of *Angiostrongylus malaysiensis* Bhaibulaya and Cross, 1971. *Southeast Asian J. Trop. Med. Public Health* 5, 374–378.
- Dias, S.R.C., Oliveira, E.L., Viana, M.H., Lima, W.S., 2008. Permissivity of the domestic cat (*Felis catus*) to infection by *Angiostrongylus vasorum* (Nematoda: Protostrongylidae). *Revue Méd. Vét.* 159, 87–90.
- Doby, J.M., Drózdź, J., 1971. Cycle évolutif de *Angiostrongylus (Parastrongylus) dujardini* Drózdź et Doby, 1970 (Nematoda: Metastrongyloidea). *C.R. Acad. Sci. Paris* 272, 604–607.
- Doby, J.M., Piedade-Guerreiro, J., Drózdź, J., 1971. Répartition géographique de *Angiostrongylus (Parastrongylus) dujardini* Drózdź et Doby, 1970 nématode parasite des petits rongeurs sauvages. Présence au Portugal. *An. Esc. Nac. Saude Publ. Med. Trop. (Lisboa)* 5, 59–60.
- Dougherty, E.C., 1946. The genus *Aelurostrongylus* Cameron, 1927 (Nematoda: Metastrongylidae), and its relatives; with descriptions of *Parafilaroides* gen. nov., and *Angiostrongylus gubernaculatus* sp. nov. *Proc. Helm. Soc. Wash.* 13, 16–26.
- Drózdź, J., 1970. Révision de la systématique du genre *Angiostrongylus* Kamensky, 1905 (Nematoda: Metastrongyloidea). *Ann. Parasitol. Hum. Comp.* 45, 597–603.
- Drózdź, J., Doby, J.M., 1970a. *Angiostrongylus dujardini* sp. n. (Nematoda: Metastrongyloidea) parasite de *Apodemus sylvaticus* et *Clethrionomys glareolus*. *Bull. Soc. Zool. Fr.* 95, 659–668.
- Drózdź, J., Doby, J.M., 1970b. Evolution, morphologique, migrations et chronologie du cycle de *Angiostrongylus (Parastrongylus) dujardini* Drózdź et Doby, 1970 (Nematoda: Metastrongyloidea) chez ses hôtes définitifs. *Bull. Soc. Scient. Bretagne* 45, 229–239.
- Drózdź, J., Doby, J.M., Mandahl-Barth, G., 1971. Étude des morphologie et evolution larvaires de *Angiostrongylus (Parastrongylus) dujardini* Drózdź et Doby, 1970 (Nematoda: Metastrongyloidea). Infestation des mollusques hôtes intermédiaires. *Ann. Parasitol. Hum. Comp.* 46, 265–276.
- Eleni, C., De Liberato, C., Azam, D., Morgan, E.R., Traversa, D., 2014. *Angiostrongylus vasorum* in wolves in Italy. *Int. J. Parasitol. Parasites Wildl.* 3, 12–14.
- Erchardová, B., 1960. K vospozoru gelmintofaunú musevidnúh grúzunov v Albanii. *Ceskoslov. Parasitol.* 7, 91–96.
- Faulkner, C.T., Patton, S., Munson, L., Johnson, E.M., Coonan, T.J., 2001. *Angiocaulus gubernaculatus* in the Island fox (*Urocyon littoralis*) from the California Channel Islands and comments on the diagnosis of Angiostrongylidae nematodes in canid and mustelid hosts. *J. Parasitol.* 87, 1174–1176.
- Fiorello, C.V., Robbins, R.G., Maffei, L., Wade, S.E., 2006. Parasites of free-ranging small canids and felids in Bolivian Chaco. *J. Zoo Wildl. Med.* 37, 130–134.
- Gardiner, C.H., Wells, S., Gutter, A.E., Fitzgerald, L., Anderson, D.C., Harris, R.K., et al., 1990. Eosinophilic meningoencephalitis due to *Angiostrongylus cantonensis* as the cause of death in captive non-human primates. *Am. J. Trop. Med. Hyg.* 42, 70–74.
- Gelis, S., Spratt, D.M., Raidal, S.R., 2011. Neuroangiostrongyliasis and other parasites in Tawny Frogmouths (*Podargus strigoides*) in south-eastern Queensland. *Aust. Vet. J.* 89, 47–50.
- Gerrikagoitia, X., Barral, M., Juste, R.A., 2010. *Angiostrongylus* species in wild carnivores in the Iberian Peninsula. *Vet. Parasitol.* 174, 175–180.
- Gonçalves, P.C., 1961. *Angiostrongylus vasorum* (Baillet, 1866), novo parasite do cao no Rio Grande do Sul (Brazil). (Nematoda: Metastrongyloidea). *Rev. Fac. Agron. Vet. Univ. Rio Grande do Sul, Porto Alegre* 4, 35–40.
- Graeff-Teixeira, C., Thiengo, S.C., Thomé, J.W., Medeiros, A.B., Camillo-Coura, L., Agostini, A.A., 1993. On the diversity of mollusc intermediate hosts of *Angiostrongylus costaricensis* Morera & Cespedes, 1971 in southern Brazil. *Mem. Inst. Oswaldo Cruz* 88, 487–489.
- Graeff-Teixeira, C.L., De Avila-Pires, F.D., Machado, R.C.C., Camillo-Coura, L., Lenzi, L., 1990. Identificação de roedores silvestres como hospedeiros de *Angiostrongylus costaricensis* no sul do Brasil. *Rev. Inst. Med. Trop. Sao Paulo* 32, 147–150.
- Grisi, L., 1971. Ocorrência de *Angiocaulus railletii* (Travassos, 1927) comb. n. em *Canis familiaris* L. Nematoda, Protostrongylidae. *Revta. Bras. Biol.* 31, 27–32.
- Guilhon, J., 1960. Rôle des limacides dans le cycle évolutif d'*Angiostrongylus vasorum* (Baillet, 1866). *C.R. Acad. Sci.* 251, 2252–2253.
- Guilhon, J., 1963. Recherches sur le cycle évolutif du strongyle des vaisseaux du chien. *Bull. Acad. Vét. Fr.* 36, 431–442.
- Guilhon, J., Cens, B., 1970. Essais de transmission d'*Angiostrongylus vasorum* (Baillet, 1866) du chat. *C.R. Acad. Sci.* 271, 936–939.
- Guilhon, J., Cens, B., 1973. *Angiostrongylus vasorum* (Baillet, 1866): Étude biologique et morphologique. *Ann. Parasitol. Hum. Comp.* 48, 567–596.
- Gutteridge, B.H., Bhaibulaya, M., Findlater, C., 1972. Human larval meningitis possibly following lettuce ingestion in Brisbane. *Pathology* 4, 63–64.
- Heaton, D.C., Gutteridge, B.H., 1980. Angiostrongyliasis in Australia. *Aust. N. Z. J. Med.* 10, 255–256.
- Heyneman, D., Lim, B.L., 1967. *Angiostrongylus cantonensis*: proof of direct transmission with its epidemiological implications. *Science* 158, 1057–1058.
- Higgins, D.P., Carlisle-Nowak, M.S., Mackie, J., 1997. Neural angiostrongylosis in three captive rufous bettongs (*Aepyprymnus rufescens*). *Aust. Vet. J.* 75, 564–566.
- Jefferies, R., Shaw, S.E., Viney, M.E., Morgan, E.R., 2009. *Angiostrongylus vasorum* from South America and Europe represent distinct lineages. *Parasitology* 136, 107–115.
- Jefferies, R., Shaw, S.E., Willeesen, J., Viney, M.E., Morgan, E.R., 2010. Elucidating the spread of the emerging canid nematode *Angiostrongylus vasorum* between Palaearctic and Nearctic ecozones. *Infect. Genet. Evol.* 10, 561–568.
- Jeffery, R.A., Lankester, M.W., McGrath, M.J., Whitney, H.G., 2004. *Angiostrongylus vasorum* and *Crenosoma vulpis* in red foxes (*Vulpes vulpes*) in Newfoundland, Canada. *Can. J. Zool.* 82, 66–74.
- Jindrak, K., 1968. Early migration and pathogenicity of *Angiostrongylus cantonensis* in laboratory rats. *Ann. Trop. Med. Parasitol.* 62, 505–517.
- Jushkov, V.F., 1971. *Angiocaulus ryjikovi* sp. n. (Nematoda: Strongylata), a parasite of the northern redbacked vole (*Clethrionomys rutilus* Pallas) from northern Ural. *Parazitologiya* 4, 344–346.
- Kamiya, M., Fukumoto, S., 1988. *Angiostrongylus sandarsae* Alicata, 1968 (Nematoda: Metastrongyloidea) from *Praomys natalensis* in Kenya. *Jpn. J. Vet. Res.* 36, 47–52.
- Kamiya, M., Oku, Y., Kamiya, H., Ohbayashi, M., Abe, H., Suzuki, H., et al., 1980. Report on the prevalence and experimental infections of *Angiostrongylus siamensis*

- Ohbayashi, Kamiya et Bhaibulaya, 1979, parasitic in the mesenteric arteries of rodents in Thailand. *Jpn. J. Vet. Res.* 28, 114–121.
- Kim, D.Y., Stewart, T.B., Bauer, R.W., Mitchell, M., 2002. *Parastrongylus* (= *Angiostrongylus*) *cantonensis* now endemic in Louisiana wildlife. *J. Parasitol.* 88, 1024–1026.
- Kinsella, J.M., 1971. *Angiostrongylus schmidtii* sp. n. (Nematoda: Metastrongyloidea) from the rice rat, *Oryzomys palustris*, in Florida, with a key to the species of *Angiostrongylus* Kamensky, 1905. *J. Parasitol.* 57, 494–497.
- Kinsella, J.M., 1974. Comparison of helminth parasites of the cotton rat, *Sigmodon hispidus*, from several habitats in Florida. *Amer. Mus. Novitat.* 2540, 1–12.
- Kinsella, J.M., 1987. Studies on the life cycle and host specificity of *Parastrongylus schmidtii* (Nematoda: Angiostrongylidae). *Proc. Helm. Soc. Wash.* 54, 245–248.
- Kontrimavichus, V.L., Delyamure, S.L., 1979. *Osnovy Nematodologii*, Tom. XXIX, Filyaroididy Domashnikh i Dikikh Zhivotnykh. [Filaroids of domestic and wild animals]. Nauka Publishers, Moscow. Fundamentals of nematology volume 29. Published for the U.S. Department of Agriculture and the National Science Foundation, Washington, D.C., by Amerind Publishing Co. Pvt. Ltd., New Delhi, India, 1985, 183 p.
- Kudo, N., Oku, Y., Kamiya, M., Ohbayashi, M., 1983. Development and migration route of *Angiostrongylus siamensis* in mice. *Jpn. J. Vet. Res.* 31, 151–163.
- Lim, B.L., Ramachandran, C.P., 1979a. Ecological studies on *Angiostrongylus malaysiensis* (Nematoda: Metastrongylidae) in Malaysia. In: Cross, J.H. (Ed.), *Studies on Angiostrongyliasis in Eastern Asia and Australia*. Taipei, Taiwan, pp. 26–48. NAMRU-2 Special Publication No. 44.
- Lima, W.S., Guimaraes, M.P., Lemos, I.S., 1994. Occurrence of *Angiostrongylus vasorum* in the lungs of the Brazilian fox *Dusicyon vetulus*. *J. Helminthol.* 68, 87.
- Lindo, J., Waugh, C., Hall, J., Cunningham-Myrrie, C., Ashley, D., Eberhard, M., et al., 2002. Zoonotic *Angiostrongylus cantonensis* in rats and snails after outbreak of human eosinophilic meningitis in Jamaica. *Emerg. Infect. Dis.* 8, 324–326.
- Lunn, J.A., Lee, R., Smaller, J., MacKay, B.M., King, T., Hunt, G.B., et al., 2012. Twenty two cases of canine neural angiostrongyliosis in eastern Australia (2002–2005) and a review of the literature. *Parasit. Vectors* 5, 70. doi:10.1186/1756-3305-5-70; [Apr 5, 2012]. Published online.
- Ma, G., Dennis, M., Rose, K., Spratt, D., Spielman, D., 2013. Tawny frogmouths and brushtail possums as sentinels for *Angiostrongylus cantonensis*, the rat lungworm. *Vet. Parasitol.* 192, 158–165.
- Mackerras, M.J., Sandars, D.F., 1955. The life history of the rat lung-worm *Angiostrongylus cantonensis* (Chen) (Nematoda: Metastrongylidae). *Aust. J. Zool.* 3, 1–21.
- Mackie, J.T., Lacasse, C., Spratt, D.M., 2013. Patent *Angiostrongylus mackerrasae* infection in a black flying fox (Pteropus alecto). *Aust. Vet. J.* 91, 366–367.
- Mason, K.V., 1987. Canine neural angiostrongyliosis: the clinical and therapeutic features of 55 natural cases. *Aust. Vet. J.* 64, 201–203.
- Mason, K.V., Prescott, C.W., Kelly, W.R., Waddell, A.H., 1976. Granulomatous encephalomyelitis of puppies due to *Angiostrongylus cantonensis*. *Aust. Vet. J.* 52, 295.
- McKenzie, R.A., Green, P.E., Wood, A.D., 1978. *Angiostrongylus cantonensis* infection of the brain of a captive Bennett's wallaby (*Macropus rufogriseus*). *Aust. Vet. J.* 54, 86–88.
- Mészáros, F., 1972. The occurrence of *Angiostrongylus (P.) dujardini* Drozdz et Doby, 1970 (Nematoda) in rodents in Hungary. *Parasit. Hung.* 5, 163–176.
- Mendonça, C.L.G.F., Carvalho, O.S., Mota, E.M., Pelajo-Machado, M., Caputo, L.F.G., Lenzi, H.L., 1999. Penetration sites and migratory routes of *Angiostrongylus costaricensis* in the experimental intermediate host (*Sarasinula marginata*). *Mem. Inst. Oswaldo Cruz* 94, 549–556.
- Merdivenci, A., 1964. A new lungworm, *Angiostrongylus sciuri* n. sp. parasitising in the venae pulmonales of the squirrel, *Sciurus vulgaris*. *Istanb. Univ. Fen. Fak. Meim.* 29, 155–158.
- Miller, C.L., Kinsella, J.M., Garner, M.M., Evans, S., Gullett, P.A., Schmidt, R.E., 2006. Endemic infections of *Parastrongylus* (= *Angiostrongylus*) *costaricensis* in two species of nonhuman primates, raccoons, and an opossum from Miami, Florida. *J. Parasitol.* 92, 406–408.
- Miquel, J., Feliú, C., Torres, J., Casanova, J.C., 1993. Nematode species parasitic in wild carnivores of Catalonia (NE Iberian Peninsula). *Misc. Zool.* 17, 49–57.
- Monge, E., Arroyo, R., Solano, E., 1978. A new definitive natural host of *Angiostrongylus costaricensis* (Morera and Céspedes, 1971). *J. Parasitol.* 64, 34.
- Monks, D.J., Carlisle, M.S., Carrigan, M., Rose, K., Spratt, D.M., Gallagher, A., et al., 2005. *Angiostrongylus cantonensis* as a cause of cerebrospinal disease in a yellow-tailed black cockatoo (*Calyptorhynchus funereus*) and two tawny frogmouths (*Podargus strigoides*). *J. Avian Med. Surg.* 19, 289–293.
- Morera, P., 1973. Life history and redescription of *Angiostrongylus costaricensis* Morera and Céspedes, 1971. *Am. J. Trop. Med. Hyg.* 22, 613–621.
- Morera, P., 1978. Definitive and intermediate hosts of *Angiostrongylus costaricensis*. 4th International Congress of Parasitology 19–26 August 1978, Warsaw.
- Morera, P., 1985. Abdominal angiostrongyliasis: a problem of public health. *Parasitol. Today* 1, 173–175.
- Morera, P., Ash, L.R., 1970. Investigación del huésped intermediario de *Angiostrongylus costaricensis* (Morera y Céspedes, 1971). *Bol. Chil. Parasitol.* 25, 135.
- Morera, P., Céspedes, R., 1971. *Angiostrongylus costaricensis* n. sp. (Nematoda: Metastrongyloidea), a new lungworm occurring in man in Costa Rica. *Rev. Biol. Trop.* 18, 173–185.
- Morera, P., Lazo, R., Urquiza, J., Llaguno, M., 1983. First record of *Angiostrongylus costaricensis* Morera and Céspedes, 1971 in Ecuador. *Am. J. Trop. Med. Hyg.* 32, 1460–1461.
- Morera, P., Andrews, K.L., Rueda, A.D., 1988. The intermediate host of *Angiostrongylus costaricensis* in Honduras. *Rev. Biol. Trop.* 36, 575–576.
- Morgan, E.R., Shaw, S.E., Brennan, S.F., De Waal, T.D., Jones, B.R., Mulcahy, G., 2005. *Angiostrongylus vasorum*: a real heartbreaker. *Trends Parasitol.* 21, 49–51.
- Morgan, E.R., Tomlinson, A., Hunter, S., Nichols, T., Roberts, E., Fox, M.T., et al., 2008. *Angiostrongylus vasorum* and *Eucoleus aerophilus* in foxes (*Vulpes vulpes*) in Great Britain. *Vet. Parasitol.* 154, 48–57.
- Morton, N.J., Britton, P., Palasanthiran, P., Bye, A., Sugo, E., Keeson, A., 2013. Severe haemorrhagic meningoencephalitis due to *Angiostrongylus cantonensis* among young children in Sydney, Australia. *Clin. Infect. Dis.* 57, 1158–1161.
- Mota, E.M., Lenzi, H.L., 1995. *Angiostrongylus costaricensis* life cycle: a new proposal. *Mem. Inst. Oswaldo Cruz* 90, 707–709.
- Mota, E.M., Lenzi, H.L., 2005. *Angiostrongylus costaricensis*: complete redescription of the migratory pathways based on experimental *Sigmodon hispidus* infection. *Mem. Inst. Oswaldo Cruz* 100, 407–420.
- Ohbayashi, M., Kamiya, M., Bhaibulaya, M., 1979. Studies on the parasite fauna of Thailand I. Two new metastrongylid nematodes, *Angiostrongylus siamensis* sp. n. and *Thaistrongylus harinasutai* gen. et sp. n. (Metastrongyloidea; Angiostrongylidae) from wild rats. *Jpn. J. Vet. Res.* 27, 5–10.
- Ohbayashi, M., Machida, M., Kamiya, H., Yuzaburo, O., Abe, H., Klongkamnuankarn, K., 1983. Incidence of *Angiostrongylus siamensis* in small mammals at Nakorn Nayok, Thailand. *Jpn. J. Vet. Res.* 31, 49–50.
- Okano, T., Haga, A., Mizuno, E., Onuma, M., Nakaya, Y., Nagamine, T., 2014. *Angiostrongylus cantonensis* (Nematoda: Metastrongylidae) in the Ryukyu Islands tree rat (*Diplothrix legata*). *J. Wildl. Dis.* 50, 322–325.
- Oku, Y., Kudo, N., Kamiya, M., 1981. Experimental hybridization of *Angiostrongylus costaricensis* and *Angiostrongylus siamensis*. *Jpn. J. Parasitol.* 30 (Suppl.), 35 (in Japanese).
- Oku, Y., Kudo, N., Ohbayashi, M., Narama, I., Umemura, T., 1983. A case of abdominal angiostrongyliasis in a monkey. *Jpn. J. Vet. Res.* 31, 71–75.
- Petter, A.J., 1972. Description d'une nouvelle espèce d'*Aelurostrongylus* parasite de rongeur africain. *Ann. Parasitol. Hum. Comp.* 47, 131–137.
- Petter, A.J., 1974. Le cycle évolutif de *Morerastrongylus andersoni* (Petter, 1972). *Ann. Parasitol. Hum. Comp.* 49, 69–82.
- Petter, A.J., Cassone, J., 1975. Mode de pénétration et localisation des larves de *Morerastrongylus andersoni* (Petter, 1972) (Metastrongyloidea, Nematoda) chez l'hôte intermédiaire. *Ann. Parasitol. Hum. Comp.* 50, 469–475.
- Pipitgool, V., Sithithaworn, P., Pongmuttasaya, P., Hinz, E., 1997. *Angiostrongylus* infections in rats and snails in northeast Thailand. *Southeast Asian J. Trop. Med. Public Health* 28 (Suppl. 1), 190–193.
- Prociw, P., 1999. Parasitic meningitis. Crossing paths with the rat lungworm (*Angiostrongylus cantonensis*). *Med. J. Aust.* 170, 517–518.
- Prociw, P., Carlisle, M.S., 2001. The spread of *Angiostrongylus cantonensis* in Australia. *Southeast Asian J. Trop. Med. Public Health* 32 (Suppl. 2), 126–128.
- Prociw, P., Tiernan, J.R., 1987. Eosinophilic meningoencephalitis with permanent sequelae. *Med. J. Aust.* 147, 294–295.
- Prociw, P., Spratt, D.M., Carlisle, M.S., 2000. Neuro-angiostrongyliasis: unresolved issues. *Int. J. Parasitol.* 30, 1295–1303.
- Raccurt, C., Blaise, J., Durette-Desset, M., 2003. Présence d'*Angiostrongylus cantonensis* en Haïti. *Trop. Med. Int. Health* 8, 423–426.
- Railliet, A., Henry, A.C.L., 1907. Sur les variations des strongyles de l'appareil respiratoire des mammifères. *C. R. Soc. Biol.* 63 (38), 751–753.
- Reddcliff, L.A., Bellamy, T.A., Hartley, W.J., 1999. *Angiostrongylus cantonensis* infection in grey-headed fruit bats (*Pteropus poliocephalus*). *Aust. Vet. J.* 77, 466–468.
- Reece, R.L., Perry, R.A., Spratt, D.M., 2013. Neuroangiostrongyliasis due to *Angiostrongylus cantonensis* in gang-gang cockatoos (*Callocephalon fimbriatum*). *Aust. Vet. J.* 91, 477–481.
- Richards, C.S., Merritt, J.W., 1967. Studies on *Angiostrongylus cantonensis* in molluscan intermediate hosts. *J. Parasitol.* 53, 382–388.
- Robles, M.R., Navone, G.T., Kinsella, J.M., 2008. A new angiostrongylid (Nematoda) species from the pulmonary arteries of *Akodon azarae* (Rodentia: Cricetidae) in Argentina. *J. Parasitol.* 94, 515–519.
- Robles, M.R., Perfumo, C., Kinsella, J.M., Navone, G.T., 2012. Histopathology associated with angiostrongyliosis in *Akodon* species (Rodentia: Sigmodontinae) from Sierra de la Ventana, Buenos Aires, Argentina. *J. Parasitol.* 98, 1133–1138.
- Rosen, L., Ash, L.R., Wallace, G.D., 1970. Life history of the canine lungworm *Angiostrongylus vasorum* (Bailliet). *Am. J. Vet. Res.* 31, 131–143.
- Saltos, N., 1975. Eosinophilic meningitis (Angiostrongyliosis): a probable case. *Med. J. Aust.* 1, 561–562.
- Schulz, R.E., 1951. [Phylogeneses of strongylid nematodes and reconstruction of the Metastrongyloidea]. *Dokl. Akad. Nauk SSSR* 80, 293–296. (in Russian).
- Segovia, J.M., Torres, J., Miquel, J., Llana, L., Felie, C., 2001. Helminths in the wolf, *Canis lupus*, from north-western Spain. *J. Helminthol.* 75, 183–192.
- Senanayake, S.N., Pryor, D.S., Walker, J., Konecny, P., 2003. First case of human angiostrongyliasis acquired in Sydney. *Med. J. Aust.* 179, 430–431.
- Seres, E., 1854. Entozoaires trouvés dans l'oreille droite, le ventricule correspondant et l'artère pulmonaire d'un chien. *J. Vét. du Midi* 7, 72–73.
- Simin, S., Koscic, L.S., Kuruca, L., Pavlovic, I., Savovic, M., Lalošević, V., 2014. Moving the boundaries to the South-East: first record of autochthonous *Angiostrongylus vasorum* infection in a dog in Vojvodina province, northern Serbia. *Parasit. Vectors* 7, 396–402.
- Simões, R.O., Souza, J.G.R., Malconado, A., Jr., Luque, J.L., 2011. Variation in the helminth community structure of three sympatric sigmodontine rodents from the coastal Atlantic forest of Rio de Janeiro, Brazil. *J. Helminthol.* 85, 171–178.

- Smales, L.R., Heinrich, B., McKillup, S.C., 2004. The helminth parasites of *Melomys cervinipes* (Rodentia: Muridae: Hydromyinae). *Aust. J. Zool.* 52, 65–80.
- Souza, J.G.R., Simoés, R.O., Thiengo, S.A.R.C., Lima, W.S., Mota, E.M., Rodrigues-Silva, R., et al., 2009. A new metastrongylid species (Nematoda: Metastrongylidae): a lungworm from *Akodon montensis* (Rodentia: Sigmodontinae) in Brazil. *J. Parasitol.* 95, 1507–1511.
- Spratt, D.M., 2005a. Australian ecosystems, capricious food chains and parasitic consequences for people. *Int. J. Parasitol.* 35, 717–724.
- Spratt, D.M., 2005b. Neuroangiostrongyliasis: disease in wildlife and humans. *Microbiol. Aust.* 64–65.
- Stokes, V.L., Spratt, D.M., Banks, P.B., Pech, R.P., Williams, R., 2007. Occurrence of species of *Angiostrongylus* (Nematoda) in populations of *Rattus rattus* and *Rattus fuscipes* in coastal forests of south-eastern Australia. *Aust. J. Zool.* 55, 177–184.
- Tarzhimanova, R.A., Chertkova, A.N., 1969. *Rattostrongylus petrovi* (spelt *petrowi* in text) n. sp., a new nematode from *Dryomys nitedula*. *Trudy Azerb. Nauch.-issled. Inst. Medit. Parazit. Trop. Medit. SM Kirova* 7, 307–310.
- Teem, J.L., Qvarnstrom, Y., Bishop, H.S., Alexandre, J., da Silva, B.S., Carter, J., et al., 2013. The occurrence of the rat lungworm, *Angiostrongylus cantonensis*, in nonindigenous snails in the Gulf of Mexico Region of the United States. *Hawaii J. Med. Public Health* 72, 11–14.
- Teles, H.M.S., Vaz, J.F., Fontes, L.R., Domingos, M.F., 1997. Registro de *Achatina fulica* Bowdich, 1822 (Mollusca, Gastropoda) no Brasil: caramujo hospedeiro intermediário da angiostrongilíase. *Rev. Saude Pública* 31, 310–312.
- Tenora, F., Henttonen, H., Haukisalmi, V., 1983. On helminths of rodents in Finland. *Ann. Zool. Fennici* 20, 37–45.
- Tesh, R.B., Ackerman, L.J., Dietz, W.H., Williams, J.A., 1973. *Angiostrongylus costaricensis* in Panama. Prevalence and pathologic findings in wild rodents infected with the parasite. *Am. J. Trop. Med. Hyg.* 22, 348–356.
- Torres, J., Miquel, J., Motjé, M., 2001. Helminth parasites of the Eurasian badger (*Meles meles* L.) in Spain: a biogeographic approach. *Parasitol. Res.* 87, 259–263.
- Travassos, L., 1927. Nematódeos novos. *Bol. Biolog. São Paulo* 6, 52–61.
- Ubelaker, J.E., 1986. Systematics of species referred to the genus *Angiostrongylus*. *J. Parasitol.* 72, 237–244.
- Ubelaker, J.E., Hall, N.M., 1979. First report of *Angiostrongylus costaricensis* Morera and Céspedes, 1971 in the United States. *J. Parasitol.* 65, 307.
- Vieira, F.M., Luque, J.L., Muniz-Pereira, L.C., 2008. Checklist of helminth parasites in wild carnivore mammals from Brazil. *Zootaxa* 1721, 1–23.
- Vieira, F.M., Muniz-Pereira, L.C., Lima, S.S., Moraes Neto, A.H.A., Guimãraes, E.V., Luque, J.L., 2013. A new metastrongyloidean species (Nematoda) parasitizing pulmonary arteries of *Puma (Herpailurus) yagouaroundi* (É. Geoffroy, 1803) (Carnivora: Felidae) from Brazil. *J. Parasitol.* 99, 327–331.
- Wallace, G.D., Rosen, L., 1969. Studies on eosinophilic meningitis. VI. Experimental infection of rats and other homiothermic vertebrates with *Angiostrongylus cantonensis*. *Am. J. Epid.* 89, 331–344.
- Wang, Q.-P., Lai, D.-H., Zhu, X.-Q., Chen, X.-G., Lun, Z.-R., 2008. Human angiostrongyliasis. *Lancet Infect. Dis.* 8, 621–630.
- Wright, J.D., Kelly, W.R., Wadell, A.H., Hamilton, J., 1991. Equine neural angiostrongylosis. *Aust. Vet. J.* 68, 58–60.
- Yamaguti, S., 1941. Studies on the helminth fauna of Japan. Part 35. Mammalian nematodes II. *Jap. J. Zool.* 9, 400–439.
- Yamaguti, S., 1961. *Systema Helminthum* Vol III. The Nematodes of Vertebrates. Pt. 1. Intersci. Publ. Inc, New York, p. 679.
- Yanchev, J., Genov, T., 1988. *Angiostrongylus daskalovi* (Nematoda: Filaroididae) from Mustelidae in Bulgaria. *Helminthologia* 25, 81–88.