

BRIEF REPORT

Open Access

Granulicatella adiacens, an unusual causative agent in chronic dacryocystitis

Cristy A Ku¹, Blake Forcina², Paul Rocco LaSala³ and John Nguyen^{2*}

Abstract

Background: *Granulicatella adiacens*, a recent taxonomic addition, is a commensal organism of the oral, gastrointestinal, and urogenital tracts and is rarely encountered in the orbit and eye.

Findings: We present a 46-year-old Caucasian woman with chronic dacryocystitis who underwent an external dacryocystorhinostomy and was found to have *G. adiacens*.

Conclusions: This is an unusual causative organism isolated in the nasolacrimal system and, to our knowledge, the first reported case of chronic dacryocystitis associated with *G. adiacens*.

Keywords: *Granulicatella adiacens*; Chronic; Dacryocystitis; Dacryocystorhinostomy; Nasolacrimal duct obstruction

Findings

Introduction

Acquired nasolacrimal duct obstruction (NLDO), a common cause of epiphora and dacryocystitis, is typically managed with dacryocystorhinostomy (DCR). Even in cases without signs of infection, positive bacterial cultures are often obtained from the lacrimal sac [1]. Gram-positive bacteria - *Staphylococcus epidermidis*, *Staphylococcus aureus*, and *Streptococcus pneumoniae* - are most frequently identified [1]. We herein describe a rare case of *Granulicatella adiacens*, isolated from a patient with chronic dacryocystitis.

Case report

A 46-year-old Caucasian woman complained of constant right eye tearing for 6 months, and it had worsened to cause blurry vision and interfered with wearing contact lens. She had intermittent pressure pain in the right medial canthus that improved after treatment with tobramycin-dexamethasone drops. Past history included deviated septum, anxiety, mitral valve prolapse, and venous insufficiency of the legs, and her medications were calcium and multi-vitamins. Visual acuity was 20/20 in each eye. Confrontation visual fields, extraocular motility, and pupillary exam were normal. The intraocular

pressure was 15 mmHg in each eye. Pooling of clear tears was noted on a normal-appearing right lower lid without an enlarged, erythematous, or tender lacrimal sac. Nasolacrimal dilation and irrigation revealed complete reflux of clear saline, and the remainder of the ocular exam was unremarkable.

The patient underwent an uneventful external dacryocystorhinostomy with placement of Crawford stent. Milky purulent material, found upon entering the lacrimal sac, was sent for Gram stain and culture. The Gram stain showed Gram-positive cocci in pairs and clusters and pleomorphic coccobacilli (Figure 1A). The patient was discharged with oral cephalexin 250 mg four times daily for 5 days along with erythromycin ointment and tobramycin-dexamethasone drops. Routine cultures initially revealed suspected *Granulicatella/Abiotrophia* species based on biochemical phenotype, good growth on chocolate agar, and colony satellitosis on sheep blood agar within beta-hemolysis zones of co-inoculated *Staphylococcus aureus* (Figure 1B,C,D). The isolate was subsequently identified as *G. adiacens* with intermediate susceptibility to penicillin (MIC = 0.25 mcg/mL). The patient had an unremarkable postoperative course with resolution of tearing and pain symptoms, and the stent was removed at 3 months follow-up.

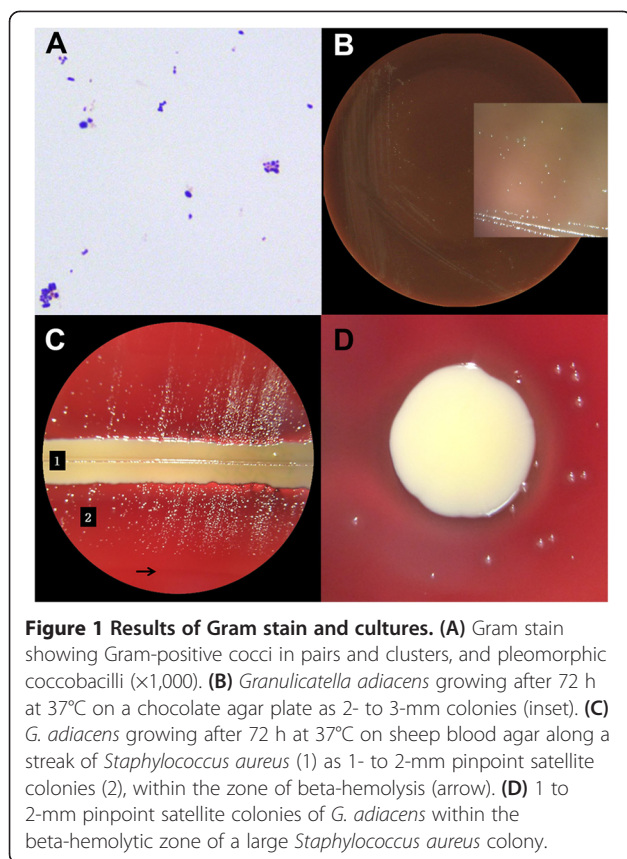
Discussion

Common isolates from dacryocystitis include Gram-positive bacteria (*Staphylococcus aureus* and *Streptococcus*

* Correspondence: nguyenj@wvuhealthcare.com

²Department of Ophthalmology, West Virginia University Eye Institute, One Stadium Drive, Morgantown, WV 26505, USA

Full list of author information is available at the end of the article



pneumoniae) and Gram-negative bacteria (*Haemophilus influenzae*, *Serratia marcescens*, and *Pseudomonas aeruginosa*) [2]. Anaerobic organisms have also been reported in as much as 16% of isolates, with the most common as *Bacteroides*, as well as *Peptostreptococcus*, *Propionibacterium*, *Prevotella*, and *Fusobacterium*. Furthermore, polymicrobial infection was seen in 45% of cases [2]. Our case was unique due to the presence of a single nutritionally variant streptococcal species.

Granulicatella adiacens, *Granulicatella elegans*, *Granulicatella balaenopterae*, and *Abiotrophia defectiva* are nutritionally variant streptococcal (NVS) species, first described and termed in the early 1960s due to their fastidious growth requirements with a streptococcal morphology. Since then, NVS species were found to share less than 10% homology to other streptococcal species [3]. Additionally, although first described as streptococci, these Gram-positive bacteria are pleomorphic with morphologies ranging from cocci, coccobacilli, to rod-shaped cells, depending on the growth medium. The distinct phylogenetics and nutritional requirements of these bacteria relative to *Streptococcus* species led to the creation of the *Abiotrophia* genus, which was later further subdivided into the two genera *Granulicatella* and *Abiotrophia* [3]. *G. adiacens* are alpha- or gamma-

hemolytic, catalase-negative, facultative anaerobic, nutritionally complex Gram-positive bacteria and typically require pyridoxal- or L-cysteine-supplemented chocolate or blood agar, or may also grow in satellite colonies around other Gram-positive and Gram-negative bacteria that secrete pyridoxal [3].

G. adiacens is part of the normal oral, gastrointestinal, and urogenital tract flora [3]. Clinically, *G. adiacens* is associated with up to 2.3% of cases of streptococcal bacteremia and up to 5% of cases of streptococcal endocarditis. *G. adiacens* is more common than *A. defectiva* and much more common than *G. elegans*, as an etiologic agent of bacterial endocarditis [3]. In the eye and orbit, *G. adiacens* has been sporadically isolated in a case of orbital abscess secondary to trauma [4] and in several cases of infectious crystalline keratopathies and corneal ulcers following penetrating keratoplasty [3,5]. *A. defectiva* has also been implicated in cases of keratitis and ulcers following penetrating keratoplasty and post-cataract surgery endophthalmitis [3,6]. To our knowledge, there has been no report case of chronic dacryocystitis involving *G. adiacens* or other NVS.

The unusual finding of *G. adiacens* in our patient may explain the chronicity of the symptoms. While *G. adiacens* is typically non-virulent, the use of topical corticosteroid-antibiotic combinations may alter the bacterial flora of the lacrimal sac, resulting in susceptibility to infection, as seen in cases of infectious crystalline keratopathies [3,5]. Co-infection with *Staphylococcus aureus* or other streptococcal species has also been speculated to contribute to the growth of *G. adiacens* in vivo [3]; however, we did not find other organisms in our case. Most NVS are moderately susceptible to penicillins, clindamycin, chloramphenicol, erythromycin, rifampin, and vancomycin and variably susceptible to cephalosporins [7]. While these antimicrobial agents provide adequate coverage for common isolates of dacryocystitis, a combination therapy of penicillins and aminoglycoside is recommended for serious *G. adiacens* systemic infection.

Consent

Written informed consent was obtained from the patient for the publication of this report and any accompanying images.

Abbreviations

DCR: dacryocystorhinostomy; NLDO: nasolacrimal duct obstruction; NVS: nutritionally variant streptococcal.

Competing interests

The authors declare that they have no competing interests.

Authors' contributions

CK reviewed the case, performed literature search, and drafted the manuscript. BF participated in the design and coordination and helped to draft and to review the manuscript. PRL performed the microbiologic study and helped to draft the manuscript. JN conceived the study, participated in

its design and coordination, and reviewed the manuscript. All authors read and approved the final manuscript.

Acknowledgements

The authors would like to acknowledge the Research to Prevent Blindness Foundation for providing an Unrestricted Grant to the Department of Ophthalmology at the West Virginia University.

Author details

¹Robert C. Byrd Health Sciences Center, West Virginia University School of Medicine, Morgantown, WV 26505, USA. ²Department of Ophthalmology, West Virginia University Eye Institute, One Stadium Drive, Morgantown, WV 26505, USA. ³Department of Pathology, West Virginia University, Morgantown, WV 26505, USA.

Received: 19 December 2014 Accepted: 23 March 2015

Published online: 14 April 2015

References

1. Hartikainen J, Lehtonen OP, Saari KM (1997) Bacteriology of lacrimal duct obstruction in adults. *Br J Ophthalmol* 81:37–40
2. Pinar-Sueiro S, Sota M, Lerchundi TX, Gibelalde A, Berasategui B, Vilar B, Hernandez JL (2012) Dacryocystitis: systematic approach to diagnosis and therapy. *Curr Infect Dis Rep* 14:137–146
3. Christensen JJ, Facklam RR (2001) Granulicatella and Abiotrophia species from human clinical specimens. *J Clin Microbiol* 39:3520–3523
4. Teo L, Looi A, Seah LL (2011) An unusual causative agent for an orbital abscess: *Granulicatella adiacens*. *Orbit* 30:162–164
5. Ormerod LD, Ruoff KL, Meisler DM, Wasson PJ, Kintner JC, Dunn SP, Lass JH, van de Rijn I (1991) Infectious crystalline keratopathy. Role of nutritionally variant streptococci and other bacterial factors. *Ophthalmology* 98:159–169
6. Paulus YM, Cockerham GC (2013) Abiotrophia defectiva causing infectious crystalline keratopathy and corneal ulcer after penetrating keratoplasty: a case report. *J Ophthalmic Inflamm Infect* 3:20
7. Ruoff KL (1991) Nutritionally variant streptococci. *Clin Microbiol Rev* 4:184–190

Submit your manuscript to a SpringerOpen[®] journal and benefit from:

- Convenient online submission
- Rigorous peer review
- Immediate publication on acceptance
- Open access: articles freely available online
- High visibility within the field
- Retaining the copyright to your article

Submit your next manuscript at ► springeropen.com
