

RAPID COMMUNICATION

Assessment of hepatic fibrosis in pediatric cases with hepatitis C virus in Egypt

Manal A El-Hawary, Mona S El-Raziky, Gamal Esmat, Hanan Soliman, Amr Abouzied, Maissa El-Raziky, Wafaa El-Akel, Rokaya El-Sayed, Fatma Shebl, Abdel Aziz Shaheen, Hanaa El-Karakasy

Manal A El-Hawary, Department of Pediatrics, Fayoum University, Egypt

Mona S El-Raziky, Rokaya El-Sayed, Hanaa El-Karakasy, Department of Pediatrics, Cairo University, Egypt

Gamal Esmat, Maissa El-Raziky, Wafaa El-Akel, Department of Tropical Medicine, Cairo University, Egypt

Hanan Soliman, Department of Pathology, Cairo University, Egypt

Amr Abouzied, Abdel Aziz Shaheen, Department of Tropical Medicine, Hepatitis C Project, Egypt

Fatma Shebl, Department of Public Health, National Liver Institute, Egypt

Correspondence to: Manal A EL-Hawary, MD, Associate Professor of Pediatrics, Faculty of Medicine-Fayoum University, Postal address: 3 Mossadak street, Dokki, Cairo,

Egypt. manalelhawary@yahoo.com

Telephone: +20-2-7600350 Fax: +20-10-1584525
Received: 2007-02-01 Accepted: 2007-03-01

Key words: Children; Egypt; Fibrosis; Hepatitis C virus; Liver

El-Hawary MA, El-Raziky MS, Esmat G, Soliman H, Abouzied A, El-Raziky M, El-Akel W, El-Sayed R, Shebl F, Shaheen AA, El-Karakasy H. Assessment of hepatic fibrosis in pediatric cases with hepatitis C virus in Egypt. *World J Gastroenterol* 2007; 13(20): 2846-2851

<http://www.wjgnet.com/1007-9327/13/2846.asp>

Abstract

AIM: To assess hepatic fibrosis and factors associated with its progression in children with HCV infection.

METHODS: At the Hepatology Unit, Cairo University Children's Hospital, a single liver biopsy was performed to 43 children with HCV infection after an informed consent between 1998-2004. Their mean age at liver biopsy was 8.67 ± 4.3 years.

RESULTS: Among the 43 patients' biopsies, 12 (27.9%) were having no fibrosis, 20 (46.5%) mild fibrosis and 11 (25.6%) moderate to severe fibrosis. The median time for development of fibrosis was estimated to be 5.5 years. Developing fibrosis was significantly associated with shorter duration from first detected ALT elevation to biopsy (12 mo vs 1.2 mo, $P = 0.015$) and having higher levels of direct serum bilirubin (0.3 mg/dL vs 0.5 mg/dL, $P = 0.048$). No association was found between fibrosis stage and the presence of co-morbid conditions ($P = 0.33$).

CONCLUSION: Hepatic fibrosis was present in 72.1% of children with HCV infection. The development of fibrosis was associated with higher levels of direct serum bilirubin. There was no significant association between fibrosis and age, duration of infection, risk factors, co-morbid conditions and most biochemical parameters.

INTRODUCTION

Egypt has the highest prevalence of hepatitis C virus (HCV) infection in the world, averaging 12%-24% in the general population^[1]. HCV Genotype 4 is the prevailing genotype in Egypt (90%)^[2].

Worldwide, the major clinical consequence of chronic hepatitis C infection is the progression to cirrhosis and its potential complications: hemorrhage, hepatic insufficiency, and primary liver cancer^[3]. The current understanding of HCV infection has been advanced by the concept of liver fibrosis progression^[4].

A main characteristic of HCV infection is the highly variable course of its natural history^[5]. A major challenge is to distinguish the disease progression in patients according to those possessing specific risk factors^[6]. Higher risk of disease progression is associated with older age, male gender, excessive alcohol consumption, overweight and immunodeficiency^[7]. The role of the liver biopsy in chronic hepatitis C would seem, at first, to be unquestioned. After all, a liver biopsy provides much information in such a small package. It provides confirmation of the diagnosis, exclusion of other liver diseases, and assessment of the grade and stage of the disease^[8]. Furthermore, the usefulness of the liver biopsy in chronic hepatitis C has received the endorsement of several national and international consensus conferences on the diagnosis and treatment of hepatitis C^[9,10].

The outcome of HCV infection acquired in childhood is uncertain as a result of the variation of clinical course of infection and disease in children^[11]. HCV infection is not always benign in the childhood period, a recent study in Egypt showed that, ALT levels were elevated in half of the subjects and histological abnormalities were detected in three quarters of HCV-RNA positive cases^[12]. Because of the major long-term complications of chronic HCV, and

the development of cirrhosis and end-stage liver disease, the degree of fibrosis on liver biopsy would seem to be an appropriate surrogate marker^[13]. Liver biopsy remains the gold standard in assessing the stage and progression of HCV infection^[14].

The aim of this work was to assess hepatic fibrosis and identify factors associated with its progression in liver biopsies from a group of Egyptian children with HCV infection. To achieve this goal, we studied factors related to HCV acquisition, co-morbid conditions, demographic factors and biochemical variables related to disease course and finally findings of liver biopsy.

MATERIALS AND METHODS

The study was carried out at the Pediatric Hepatology Unit, Cairo University Children's Hospital, Egypt, between 1998 and 2004. HCV genotype in Egypt is mostly (> 90%) genotype 4^[2]. Among a total of 105 HCV infected children, on regular follow-up every 3 mo, 43 cases were fit and consented to do liver biopsy. Twenty children had blood diseases; 18 thalassemics, 1 sickle cell anemia and 1 pure red cell aplasia. Seven were treated in the past for malignancies; 4 Hodgkin lymphoma and 3 acute lymphocytic leukemia (ALL). None of the children received any therapy for HCV.

Study population

Inclusion criteria: Age below 18 years, both sexes included, HCV antibody and HCV-RNA positive, elevation of ALT, at least 1.5 folds, at least once throughout the disease course, informed consent signed by the parent of each patient.

Exclusion criteria: Co-infection with HBV or HIV, coagulopathy, or thrombocytopenia, to a degree which precludes the safe performance of a percutaneous biopsy, therapy for HCV infection, biopsies less than 10 mm long, biopsies including less than 5 portal tracts.

All parents completed a survey regarding possible risk factors for HCV acquisition.

Biochemical assessment of liver function tests (total and direct serum bilirubin, AST, ALT, albumin and prothrombin time and concentration) was done on the same day of liver biopsy which was performed only once for each patient, in addition to a complete blood count. No fresh frozen plasma or blood transfusion was offered to correct these tests prior to biopsy.

Percutaneous liver biopsy was obtained with the Menghini technique using a secure cut biopsy needle 1.6-mm-diameter needle [Hospital Service S.p.A. Via Naro, 81-00040 Pomezia (RM) Italia.

Histological evaluation

Percutaneous liver biopsies were fixed in formalin, embedded in paraffin and cut at 4 microns thickness and stained with haematoxylin and eosin and mason trichrome. Liver sections were evaluated by a single pathologist who was blinded of the patient's clinical and laboratory data. The grade of activity and stage of fibrosis were scored according to Knodell *et al.*^[15]. The HAI system scores necroinflammatory activity from 0 to 18 assessing periportal necrosis and inflammation (0 to 10), lobular necrosis and

inflammation (0 to 4), and portal inflammation (0 to 4). Fibrosis is staged as 0, 1, 3, or 4, with 1 indicating portal fibrosis only (mild), 3 indicating bridging fibrosis (moderate), and 4 cirrhosis (extensive). The discontinuous scale allows for clear separation of mild (1+) from extensive (3+). The HAI system is simple and has been widely used. We considered moderate and extensive fibrosis as one group because of their small numbers. Liver iron deposition was evaluated by using the scale developed by Deugnier *et al.*^[16]. This scoring system was defined as the sum of three scores: hepatocytic iron score (0-36), sinusoidal iron score (0-12), and portal iron score (0-12). The sum of these scores defines the total iron score (TIS; range: 0-60). According to Halonen *et al.*^[17], liver TIS is classified into mild iron overload (TIS 0-14), moderate iron overload (TIS 15-29) and severe iron overload (TIS 30-60). Steatosis was graded based on percent of hepatocytes involved; mild (< 33%), moderate (33%-66%) and severe (> 66%)^[18].

Statistical analysis

Frequency analysis of categorical variables was presented as numbers and percentages. Chi square or Fischer's exact tests were used to assess the association between hepatic fibrosis and various categorical factors. Descriptive analysis of continuous variables was presented by median and range. Kruskal Wallis test was used to compare groups of no, moderate and marked fibrosis. Kendall's tau test was used to assess the correlation between fibrosis stage and other continuous variables. Cumulative hazard function for developing fibrosis among patients was done. In all tests, $P < 0.05$ was considered significant.

RESULTS

The present study included 43 HCV infected infants and children (24 boys and 19 girls); their mean age at liver biopsy was 8.67 ± 4.3 years (median age 9 years, range 2 mo-18 years). The estimated median duration of infection was 36 mo.

Twelve biopsies showed no fibrosis, 20 showed mild fibrosis and 11 had moderate to severe fibrosis. Iron staining was not detected in 19 cases, 15 had mild TIS, 9 had moderate TIS and no cases had severe TIS. Steatosis was absent in 30 cases, mild in 5 cases, moderate in 6 cases and severe in 2 cases.

According to the parents' responses to a survey regarding risk factors for HCV acquisition, risk factors were identified in 39 cases (90.7%). Risk factors included blood transfusion (37 cases), injections (11 cases), surgical procedures (8 cases) and (1 case) household contact infected with HCV. Among the 39 patients with known risk factors, a reliable estimate of the duration of infection was possible in only 29 cases.

Analysis of factors that could be associated with development of fibrosis in these patients was performed. Development of fibrosis was not associated with gender, elevated ALT and AST, blood transfusion, injections, surgical procedures, having a family member with HCV or having blood disease. The analysis revealed that all 7 cases that had past malignant disease had fibrosis in their liver

Table 1 Characteristic features of studied patients $n = 43$

	No Fibrosis ($n = 12$)	Fibrosis ($n = 31$)	<i>P</i> value
Sex			
Boys	8	16	0.37 (NS)
Girls	4	15	
High ALT ($n = 28$)	7	21	0.72 (NS)
Injections ($n = 11$)	2	9	0.41 (NS)
Blood transfusion ($n = 37$)	12	25	0.10 (NS)
Frequency of transfusion			
Once	2	6	0.61 (NS)
Multiple	10	19	
Surgical procedures ($n = 8$)	4	4	0.19 (NS)
Household contact infected with HCV ($n = 1$)	0	1	0.53 (NS)
No risk factor ($n = 4$)	1	3	0.86 (NS)
Blood disease ($n = 20$)			
Red cell aplasia	1	0	0.14 (NS)
Sickle cell anemia	0	1	
Thalassemia	8	10	
Malignancy ($n = 7$)			
ALL	0	3	NA
Lymphoma	0	4	

NA: not applicable (as *P* value cannot be calculated).

biopsies (Table 1).

The higher grade of fibrosis was associated with shorter duration from first detected ALT elevation to biopsy ($P = 0.015$) and higher levels of direct bilirubin ($P = 0.048$) (Table 2).

There was no association between the fibrosis stage and the presence of co-morbid condition (having blood disease or previous malignancies) ($P = 0.33$) (Table 3).

The risk for development of fibrosis, from the time of exposure to infection to the time of biopsy, was estimated in only 29 cases with a reliable duration of infection (1-10 years) and was expressed in a hazard function curve. Accordingly, liver biopsy was performed in 9 patients after an estimated duration of infection of one year. 8 of them had fibrosis, which was extensive in 3 patients. Similarly, when 6 of the 29 patients had liver biopsy ten years after exposure to infection, 4 of them had fibrosis (which was extensive in 3 cases, mild in one) and two had no fibrosis. The median time for fibrosis development in liver biopsy was estimated to be 63.7 mo (5.5 years) (Figure 1).

DISCUSSION

This is one of few studies to assess factors associated with fibrosis progression using liver biopsies from HCV infected children. The purpose of the study was to determine whether any baseline demographic, clinical, biochemical or histological factors could be associated with fibrosis stage.

Seventy-two percent of our cases showed some degree of fibrosis, 47% mild fibrosis and 25% moderate to extensive. Guido *et al*^[19] reported a similar proportion of fibrosis in their HCV infected children.

Analysis of the risk factors for acquisition of HCV revealed no association with fibrosis. El-Shorbagy *et al*^[20] reported that liver fibrosis progression is related to the mechanism of transmission. In contrast, Kage *et al*^[21] and Vogt *et al*^[22] described a relatively benign course for trans-

fusion associated hepatitis C. Although the studies presented earlier may suggest that the route of transmission may be a contributing factor in the course (mother-to-infant *vs* transfusional), it is not known which patients are most likely to develop end-stage liver disease.

Although we noticed that there was a steady increase in age with increasing fibrosis, the difference did not reach statistical significance. Similar results were reported by Marcellin *et al*^[7] where age was not a statistically significant feature associated with progression of fibrosis in patients with chronic HCV. Alternatively, some studies reported age to be an important factor in prediction of fibrosis but were predominantly reported in adults^[4,23].

Only three cases had cirrhosis in our study. These results are similar to those reported by Guido *et al*^[24] and Badizadegan *et al*^[25]. However, 44% of the cases in the latter study had moderate to severe fibrosis as compared to 25% in our series. This might be explained by the older mean age of their cases compared to ours (11.4 *vs* 8.7 years). Kage *et al*^[21] reported that 97% of their cases had mild fibrosis and none had cirrhosis. The mean age of their patients was 3.7 years.

Although the hazard of development of fibrosis increased with the duration of the disease (Figure 1), a longer duration of infection does not necessarily mean more extensive fibrosis. Overall, it is thought that hepatic inflammation drives the progression of fibrosis to cirrhosis in a relatively linear manner. However, progression is not linear in all patients^[26]. In historical studies, approximately 20% of patients who developed post-transfusion non-A non-B hepatitis, now known to have been HCV, developed cirrhosis within 20 years of infection^[27], but these data may have been skewed by selection of those with more severe disease at presentation. More recently large cross-sectional studies have assessed the rate of progression of HCV related hepatic fibrosis retrospectively using a ratio of the stage of hepatic fibrosis to the estimated duration of infection, such as the time from initial exposure to intravenous drugs or from transfusion^[4,28]. A median time to cirrhosis of 30 years was observed^[4]. However this finding obscured the observation that the median time to cirrhosis was 13 years in those infected over the age of 40. These had consumed alcohol to excess, while those infected at an earlier age and did not abuse alcohol had a median time to cirrhosis of 42 years. Notably, 32% were thought unlikely to develop progressive disease. These findings were based on a single liver biopsy and the rate of fibrosis was calculated assuming a uniform rate of progression, although no data exists to indicate whether progression occurs in a linear fashion or more erratically^[29]. Poynard *et al*^[30] observed that fibrosis progression was not normally distributed. The distribution suggested at least 3 populations: "rapid fibrosers", "intermediate fibrosers" and "slow fibrosers".

Male gender was not associated with fibrosis in this study. In adults, male gender seems to be associated with fibrosis, particularly in those above 40 years of age who had history of drinking > 50 g alcohol/day^[4]. Other studies failed to demonstrate the association of male gender with fibrosis stage^[31].

Our observation determined that direct serum bilirubin

Table 2 Analysis of data among patients with no, mild and moderate to extensive fibrosis (Kruskal Wallis test)

	No fibrosis (n = 12) Median (min-max)	Mild fibrosis (n = 20) Median (min-max)	Moderate to extensive fibrosis (n = 11) Median (min-max)	P
Age at biopsy	9 (3.5 yr-13 yr)	7.3 (1 yr-19 yr)	11 (2 mo-18 yr)	0.394 (NS)
Duration from exposure to biopsy (mo) (n = 29)	43.8 (12-144)	36 (12-120)	12 (2.4-144)	0.627 (NS)
Duration from first detected ALT elevation to biopsy (mo)	12 (0-24)	6 (0-24)	1.2 (0-7.2)	0.015 (S)
Duration from exposure to first detected ALT elevation (mo) (n = 29)	30 (12-132)	18 (0-119)	12 (1.2-141)	0.411 (NS)
Total bilirubin (mg/dL)	1.65 (0.-5.2)	0.8 (0.3-4.3)	1.5 (0.4-11)	0.270 (NS)
Direct bilirubin (mg/dL)	0.3 (0.1-2.5)	0.2 (0.1-1.3)	0.5 (0.1-10)	0.048 (S)
ALT (IU/L)	77 (17-367)	88 (16-432)	97 (30-1200)	0.649 (NS)
AST (IU/L)	69 (27-273)	84 (28-415)	96 (26-927)	0.912 (NS)
Albumin (mg/dL)	3.6 (2.9-4.7)	4.2 (3.1-5.3)	3.1 (2.8-4.7)	0.119 (NS)
Prothrombin Concentration (%)	80 (66-100)	87 (60-100)	80 (55-97)	0.458 (NS)
Platelets count (thousands/mm ³)	333 (110-284)	266 (138-396)	306 (95-302)	0.329 (NS)
HAI	5 (0-11)	5 (0-10)	4 (0-9)	0.574 (NS)
TIS	9 (0-27)	3 (0-18)	9 (0-18)	0.49 (NS)
Steatosis	n = 12	n = 20	n = 11	
None (n = 30)	10	13	7	0.61 (NS)
Mild (n = 5)	0	4	1	
Moderate (n = 6)	2	2	2	
Severe (n = 2)	0	1	1	

Table 3 Association of fibrosis stage with co-morbid condition

	Fibrosis groups			Total
	No fibrosis n = 12	Minimal fibrosis n = 20	Extensive fibrosis n = 11	
Without co-morbid condition	3	7	6	16
With co-morbid condition	9	13	5	27

P = 0.33 (NS).

correlated significantly with higher grades of fibrosis as was also reported by Ghany *et al*^[13].

The relationship between serum ALT and liver disease progression remains controversial. Although the mean value of ALT appeared to increase hand in hand with degree of fibrosis, yet the results did not reach statistical significance (Table 2). Ghany *et al*^[13] found that the magnitude of elevated ALT and AST levels were most predictive of more rapid fibrosis progression. In cross-sectional studies, serum ALT levels have correlated weakly with disease activity and little or not at all with hepatic fibrosis^[7]. Recent reports state that it is recognized that even patients with normal ALT do not necessarily have inactive disease by histopathological evaluations. This confirms the value of liver biopsy prior to initiation of antiviral therapy to identify those who will benefit from therapy^[10].

What was interesting in our results was the duration

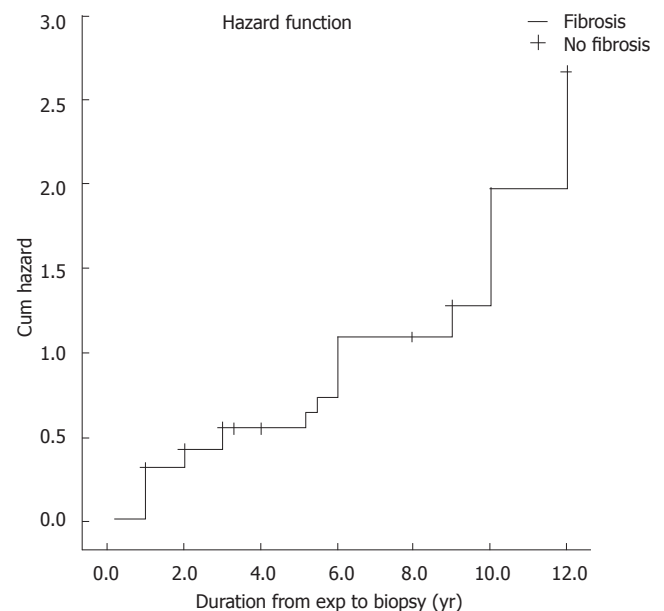


Figure 1 Cumulative hazard of fibrosis development.

from 1st detected ALT elevation to development of fibrosis. This duration was significantly shorter in those developing moderate to extensive fibrosis. This signifies that the earlier the ALT elevation in the course of hepatitis C, the more extensive fibrosis will be. This indirectly points to the importance of ALT elevation in association

with fibrosis. In addition, liver fibrosis was reported to be considerably slower in HCV-infected patients with normal, as compared with elevated, ALT levels^[32,33].

In the present study, we could not find an association between fibrosis and necro-inflammation. Similarly, other studies did not show an association between inflammation and fibrosis progression^[34,35]. On a single liver biopsy, there is little or no correlation between severity of the necroinflammatory activity and degree of fibrosis^[4,36]. In a cohort of 123 patients, Ghany *et al*^[13] identified age, ALT, and periportal inflammation as independent predictors of fibrosis progression from a dataset that included viral, demographic, biochemical, and histologic factors.

Poynard *et al*^[30] found that although fibrosis stage and inflammatory grade were correlated, however, there was discordance in 36% of their patients. Accordingly, they reported that activity grade, which represents necrosis is not a good predictor of fibrosis progression, but fibrosis alone is the best marker of ongoing fibrogenesis.

We reported positive iron staining in 55% of our cases. Iron accumulation was less frequently reported by Badizadegan *et al*^[25] and Guido *et al*^[24] (22% and 8.7% respectively). Forty percent of our cases were thalassemics which explains the high incidence of iron staining in our study. The role of hepatic iron stores in hepatic damage caused by HCV infection is unclear. Transfusional hemosiderosis has been recognized to play a significant role in the development of chronic liver disease, as liver fibrosis and cirrhosis are well-known complications in thalassemia and sickle cell anemia^[37]. Among our studied cases, mean TIS showed no statistically significant difference between the various fibrosis groups as previously reported by Haque *et al*^[38] and Boucher *et al*^[39].

Steatosis was present in nearly one-third of our cases, but was severe in only 2 cases one with mild and the other with moderate to extensive fibrosis. Steatosis is a frequent finding in chronic hepatitis C, with between 40% and 70% (mean 55.9%) of such biopsies showing some degree of fibrosis^[8,40,41]. It was suggested that the concurrence of steatosis and chronic HCV may be synergistic in causing hepatic fibrosis^[7]. Perumalswami *et al*^[42] reported that initial hepatic steatosis did not predict the degree of fibrosis progression on follow up.

Presence of co-morbid condition (blood disease or malignancy) did not affect the grade of fibrosis. Although during treatment of malignancies patients are exposed to periods of immune deficiency, the most pronounced immune deficient state that was reported to be associated with fibrosis progression was co-infection with HIV^[4,43] and liver transplant recipients^[44,45]. None of our patients was HIV positive.

In conclusion, 72.1% of children with HCV infection have hepatic fibrosis. The development of fibrosis was associated with higher levels of direct serum bilirubin. There was no significant association between fibrosis and age, duration of infection, risk factors, co-morbid conditions and most biochemical parameters.

REFERENCES

- 1 Abdel-Wahab MF, Zakaria S, Kamel M, Abdel-Khalik MK, Mabrouk MA, Salama H, Esmat G, Thomas DL, Strickland GT. High seroprevalence of hepatitis C infection among risk groups in Egypt. *Am J Trop Med Hyg* 1994; **51**: 563-567
- 2 Chamberlain RW, Adams N, Saeed AA, Simmonds P, Elliott RM. Complete nucleotide sequence of a type 4 hepatitis C virus variant, the predominant genotype in the Middle East. *J Gen Virol* 1997; **78**: 1341-1347
- 3 WHO. Hepatitis C: global prevalence. *Wkly Epidemiol Rec* 1997; **72**: 341-344
- 4 Poynard T, Bedossa P, Opolon P. Natural history of liver fibrosis progression in patients with chronic hepatitis C. The OBSVIRC, METAVIR, CLINIVIR, and DOSVIRC groups. *Lancet* 1997; **349**: 825-832
- 5 Seeff LB. Natural history of hepatitis C. *Hepatology* 1997; **26**: 21S-28S
- 6 Danta M, Dore GJ, Hennessy L, Li Y, Vickers CR, Harley H, Ngu M, Reed W, Desmond PV, Sievert W, Farrell GC, Kaldor JM, Batey RG. Factors associated with severity of hepatic fibrosis in people with chronic hepatitis C infection. *Med J Aust* 2002; **177**: 240-245
- 7 Marcellin P, Asselah T, Boyer N. Fibrosis and disease progression in hepatitis C. *Hepatology* 2002; **36**: S47-S56
- 8 Kleiner DE. The liver biopsy in chronic hepatitis C: a view from the other side of the microscope. *Semin Liver Dis* 2005; **25**: 52-64
- 9 National Institutes of Health Consensus Development Conference Panel statement Management of hepatitis C. *Hepatology* 1997; **26**: 2S-10S
- 10 National Institutes of Health Consensus Development Conference Statement Management of Hepatitis C--June10-12, 2002. *Hepatology* 2002; **36**: S3-S20
- 11 Jara P, Resti M, Hierro L, Giacchino R, Barbera C, Zancan L, Crivellaro C, Sokal E, Azzari C, Guido M, Bortolotti F. Chronic hepatitis C virus infection in childhood: clinical patterns and evolution in 224 white children. *Clin Infect Dis* 2003; **36**: 275-280
- 12 El-Raziky MS, El-Hawary M, El-Koofy N, Okasha S, Kotb M, Salama K, Esmat G, El-Raziky M, Abouzied AM, El-Karaksy H. Hepatitis C virus infection in Egyptian children: single centre experience. *J Viral Hepat* 2004; **11**: 471-476
- 13 Ghany MG, Kleiner DE, Alter H, Doo E, Khokar F, Promrat K, Herion D, Park Y, Liang TJ, Hoofnagle JH. Progression of fibrosis in chronic hepatitis C. *Gastroenterology* 2003; **124**: 97-104
- 14 Bedossa P. Morphological aspects of the normal and pathological liver. *Pathol Biol (Paris)* 1999; **47**: 879-885
- 15 Knodell RG, Ishak KG, Black WC, Chen TS, Craig R, Kaplowitz N, Kiernan TW, Wollman J. Formulation and application of a numerical scoring system for assessing histological activity in asymptomatic chronic active hepatitis. *Hepatology* 1981; **1**: 431-435
- 16 Deugnier YM, Loréal O, Turlin B, Guyader D, Jouanolle H, Moirand R, Jacquelinet C, Brissot P. Liver pathology in genetic hemochromatosis: a review of 135 homozygous cases and their biochemical correlations. *Gastroenterology* 1992; **102**: 2050-2059
- 17 Halonen P, Mattila J, Suominen P, Ruuska T, Salo MK, Mäkiperna A. Iron overload in children who are treated for acute lymphoblastic leukemia estimated by liver siderosis and serum iron parameters. *Pediatrics* 2003; **111**: 91-96
- 18 Brunt EM, Janney CG, Di Bisceglie AM, Neuschwander-Tetri BA, Bacon BR. Nonalcoholic steatohepatitis: a proposal for grading and staging the histological lesions. *Am J Gastroenterol* 1999; **94**: 2467-2474
- 19 Guido M, Bortolotti F, Leandro G, Jara P, Hierro L, Larrauri J, Barbera C, Giacchino R, Zancan L, Balli F, Crivellaro C, Cristina E, Pucci A, Ruge M. Fibrosis in chronic hepatitis C acquired in infancy: is it only a matter of time? *Am J Gastroenterol* 2003; **98**: 660-663
- 20 El-Shorbagy E, Afefy AF, Ibrahim IA, Mangoud AM, Eissa MH, Sabee EI, Mahrous S, Abdel-Monem A, Ismail A, Morsy TA, Etewa S, Nor Edin E, Mostafa Y, Abouel-Magd Y, el-Sedawy M, Ragab H, el-Tokhy H, Hassan MI, Lakouz K, Abdel-Aziz K, el-Hady G, Saber M. Non-invasive markers and predictors of severity of hepatic fibrosis in HCV patients

- at Sharkia Governorate, Egypt. *J Egypt Soc Parasitol* 2004; **34**: 459-478
- 21 **Kage M**, Fujisawa T, Shiraki K, Tanaka T, Fujisawa T, Kimura A, Shimamatsu K, Nakashima E, Kojiro M, Koike M, Tazawa Y, Abukawa D, Okaniwa M, Takita H, Matsui A, Hayashi T, Etou T, Terasawa S, Sugiyama K, Tajiri H, Yoden A, Kajiwara Y, Sata M, Uchimura Y. Pathology of chronic hepatitis C in children. Child Liver Study Group of Japan. *Hepatology* 1997; **26**: 771-775
 - 22 **Vogt M**, Lang T, Frösner G, Klingler C, Sendl AF, Zeller A, Wiebecke B, Langer B, Meisner H, Hess J. Prevalence and clinical outcome of hepatitis C infection in children who underwent cardiac surgery before the implementation of blood-donor screening. *N Engl J Med* 1999; **341**: 866-870
 - 23 **Bain VG**, Bonacini M, Govindarajan S, Ma M, Sherman M, Gibas A, Cotler SJ, Deschenes M, Kaita K, Jhangri GS. A multicentre study of the usefulness of liver biopsy in hepatitis C. *J Viral Hepat* 2004; **11**: 375-382
 - 24 **Guido M**, Ruge M, Jara P, Hierro L, Giacchino R, Larrauri J, Zancan L, Leandro G, Marino CE, Balli F, Bagni A, Timitilli A, Bortolotti F. Chronic hepatitis C in children: the pathological and clinical spectrum. *Gastroenterology* 1998; **115**: 1525-1529
 - 25 **Badizadegan K**, Jonas MM, Ott MJ, Nelson SP, Perez-Atayde AR. Histopathology of the liver in children with chronic hepatitis C viral infection. *Hepatology* 1998; **28**: 1416-1423
 - 26 **Afdhal NH**. The natural history of hepatitis C. *Semin Liver Dis* 2004; **24** Suppl 2: 3-8
 - 27 **Di Bisceglie AM**, Goodman ZD, Ishak KG, Hoofnagle JH, Melpolder JJ, Alter HJ. Long-term clinical and histopathological follow-up of chronic posttransfusion hepatitis. *Hepatology* 1991; **14**: 969-974
 - 28 **Roudot-Thoraval F**, Bastie A, Pawlotsky JM, Dhumeaux D. Epidemiological factors affecting the severity of hepatitis C virus-related liver disease: a French survey of 6,664 patients. The Study Group for the Prevalence and the Epidemiology of Hepatitis C Virus. *Hepatology* 1997; **26**: 485-490
 - 29 **Collier JD**, Woodall T, Wight DG, Shore S, Gimson AE, Alexander GJ. Predicting progressive hepatic fibrosis stage on subsequent liver biopsy in chronic hepatitis C virus infection. *J Viral Hepat* 2005; **12**: 74-80
 - 30 **Poynard T**, Ratziu V, Benmanov Y, Di Martino V, Bedossa P, Opolon P. Fibrosis in patients with chronic hepatitis C: detection and significance. *Semin Liver Dis* 2000; **20**: 47-55
 - 31 **Wong V**, Caronia S, Wight D, Palmer CR, Petrik J, Britton P, Alexander GJ. Importance of age in chronic hepatitis C virus infection. *J Viral Hepat* 1997; **4**: 255-264
 - 32 **Mathurin P**, Moussalli J, Cadranel JF, Thibault V, Charlotte F, Dumouchel P, Cazier A, Hureau JM, Devergie B, Vidaud M, Opolon P, Poynard T. Slow progression rate of fibrosis in hepatitis C virus patients with persistently normal alanine transaminase activity. *Hepatology* 1998; **27**: 868-872
 - 33 **Shiffman ML**, Stewart CA, Hofmann CM, Contos MJ, Luketic VA, Sterling RK, Sanyal AJ. Chronic infection with hepatitis C virus in patients with elevated or persistently normal serum alanine aminotransferase levels: comparison of hepatic histology and response to interferon therapy. *J Infect Dis* 2000; **182**: 1595-1601
 - 34 **Zarski JP**, Mc Hutchison J, Bronowicki JP, Sturm N, Garcia-Kennedy R, Hodaj E, Truta B, Wright T, Gish R. Rate of natural disease progression in patients with chronic hepatitis C. *J Hepatol* 2003; **38**: 307-314
 - 35 **Ryder SD**, Irving WL, Jones DA, Neal KR, Underwood JC. Progression of hepatic fibrosis in patients with hepatitis C: a prospective repeat liver biopsy study. *Gut* 2004; **53**: 451-455
 - 36 **Poynard T**, Ratziu V, Charlotte F, Goodman Z, McHutchison J, Albrecht J. Rates and risk factors of liver fibrosis progression in patients with chronic hepatitis c. *J Hepatol* 2001; **34**: 730-739
 - 37 **Angelucci E**, Muretto P, Nicolucci A, Baronciani D, Erer B, Gaziev J, Ripalti M, Sodani P, Tomassoni S, Visani G, Lucarelli G. Effects of iron overload and hepatitis C virus positivity in determining progression of liver fibrosis in thalassemia following bone marrow transplantation. *Blood* 2002; **100**: 17-21
 - 38 **Haque S**, Chandra B, Gerber MA, Lok AS. Iron overload in patients with chronic hepatitis C: a clinicopathologic study. *Hum Pathol* 1996; **27**: 1277-1281
 - 39 **Boucher E**, Bourienne A, Adams P, Turlin B, Brissot P, Deugnier Y. Liver iron concentration and distribution in chronic hepatitis C before and after interferon treatment. *Gut* 1997; **41**: 115-120
 - 40 **Brunt EM**, Ramrakhiani S, Cordes BG, Neuschwander-Tetri BA, Janney CG, Bacon BR, Di Bisceglie AM. Concurrence of histologic features of steatohepatitis with other forms of chronic liver disease. *Mod Pathol* 2003; **16**: 49-56
 - 41 **Sanyal AJ**, Contos MJ, Sterling RK, Luketic VA, Shiffman ML, Stravitz RT, Mills AS. Nonalcoholic fatty liver disease in patients with hepatitis C is associated with features of the metabolic syndrome. *Am J Gastroenterol* 2003; **98**: 2064-2071
 - 42 **Perumalswami P**, Kleiner D, Lutchman G, et al. Hepatitis C infection and hepatic steatosis; Fibrosis is not forged in the flame of fat. *Gastroenterology* 2004; **126** (suppl 2): A-672 (Abstract 176)
 - 43 **Sulkowski MS**, Mast EE, Seeff LB, Thomas DL. Hepatitis C virus infection as an opportunistic disease in persons infected with human immunodeficiency virus. *Clin Infect Dis* 2000; **30** Suppl 1: S77-S84
 - 44 **Prieto M**, Berenguer M, Rayón JM, Córdoba J, Argüello L, Carrasco D, García-Herola A, Olaso V, De Juan M, Gobernado M, Mir J, Berenguer J. High incidence of allograft cirrhosis in hepatitis C virus genotype 1b infection following transplantation: relationship with rejection episodes. *Hepatology* 1999; **29**: 250-256
 - 45 **Berenguer M**, Ferrell L, Watson J, Prieto M, Kim M, Rayon M, Córdoba J, Herola A, Ascher N, Mir J, Berenguer J, Wright TL. HCV-related fibrosis progression following liver transplantation: increase in recent years. *J Hepatol* 2000; **32**: 673-684

S- Editor Wang J L- Editor Li M E- Editor Liu Y