

• BRIEF REPORTS •

Effect of oral erythromycin on gastric and small bowel transit time of capsule endoscopy

Wai K Leung, Francis KL Chan, Sara SL Fung, Mei-Yin Wong, Joseph JY Sung

Wai K Leung, Francis KL Chan, Sara SL Fung, Mei-Yin Wong, Joseph JY Sung, Digestive Diseases Center, The Chinese University of Hong Kong, Prince of Wales Hospital, Shatin, Hong Kong, China
Correspondence to: Dr. Wai K Leung, Department of Medicine and Therapeutics, Prince of Wales Hospital, 30-32 Ngan Shing Street, Shatin, Hong Kong, China. wkleung@cuhk.edu.hk
Telephone: +852-2632-3140 Fax: +852-2637-3852
Received: 2004-12-10 Accepted: 2005-01-05

Abstract

AIM: To determine the effect of oral erythromycin on gastric and small bowel transit time of capsule endoscopy.

METHODS: Consecutive patients who underwent capsule endoscopy during the 16-mo study period were either given 250 mg oral erythromycin, 1 h prior to swallowing the capsule endoscope or nothing. The gastric and small bowel transit time, and the small bowel image quality were compared.

RESULTS: Twenty-four patients received oral erythromycin whereas 14 patients were not given any prokinetic agent. Patients who received erythromycin had a significantly lower gastric transit time than control (16 min vs 70 min, $P = 0.005$), whereas the small bowel transit time was comparable between the two groups (227 min vs 183 min, $P = 0.18$). Incomplete small bowel examination was found in three patients of the control group and in one patient of the erythromycin group. There was no significant difference in the overall quality of small bowel images between the two groups. A marked reduction in gastric transit time was noted in two patients who had repeat capsule endoscopy after oral erythromycin.

CONCLUSION: Use of oral erythromycin significantly reduces the gastric transit time of capsule endoscopy.

© 2005 The WJG Press and Elsevier Inc. All rights reserved.

Key words: Capsule endoscopy; Erythromycin; Prokinetic

Leung WK, Chan FKL, Fung SSL, Wong MY, Sung JY. Effect of oral erythromycin on gastric and small bowel transit time of capsule endoscopy. *World J Gastroenterol* 2005; 11(31): 4865-4868

<http://www.wjgnet.com/1007-9327/11/4865.asp>

INTRODUCTION

The introduction of wireless capsule endoscopy, which

has made direct visualization of the small bowel possible, has opened up a new chapter on small bowel imaging. Initial comparative studies showed that wireless capsule endoscopy is superior to push enteroscopy^[1-4] or conventional radiological imaging^[5]. The wireless capsule endoscopy is approved by the Food and Drug Administration of USA and is particularly useful for the diagnosis of obscure gastrointestinal bleeding.

With the limited battery life, the current capsule endoscope could take images for up to 8 h. Any delay in gastric transit may inadvertently result in incomplete small bowel examination. Whilst the capsule endoscope is passively propelled by peristalsis down the intestinal lumen, it is impossible to predict the time required for the capsule endoscope to navigate through the stomach. Although the use of prokinetic agents may potentially speed up the gastric emptying time, the effect of prokinetic agents on the outcome of wireless capsule endoscopy remains undetermined. Among various prokinetic agents, erythromycin, a motilin agonist, has been used to speed up gastric emptying in patients with gastroparesis^[6-8]. Moreover, the use of intravenous erythromycin has been shown to improve the quality of upper gastro-intestinal endoscopy in patients with upper gastro-intestinal bleeding, possibly via emptying of the blood contents within the stomach^[9]. Here, we determined the effects of oral erythromycin on the gastric and small bowel transit time of the capsule endoscope as well as the quality of small bowel images in patients undergoing capsule endoscopy.

MATERIALS AND METHODS

Patients

Consecutive patients who underwent capsule endoscopy in the Prince of Wales Hospital of Hong Kong between December 2002 and March 2004 were included. The use of prokinetic agents in these patients was based on the date of the procedure. All patients who had this examination after October 2003 received oral erythromycin (250 mg) 1 h prior to swallowing the capsule endoscope. In contrast, patients who had capsule endoscopy before October 2003 did not receive any prokinetic agent and were used as controls. Exclusion criteria included patients with swallowing difficulties, previous gastric or small bowel surgery, allergic to erythromycin, use of other prokinetic agents, and known or suspected bowel obstruction. All patients gave informed consent for undergoing the procedure.

A total of 38 patients had capsule endoscopy during the 16-mo study period. There were 17 males and 21 females with a mean age of 60.3 (SD 18.1) years. Twenty-four

(63%) patients were given oral erythromycin (250 mg) prior to swallowing the capsule endoscope (erythromycin group) whereas 14 (37%) patients did not receive any prokinetic agent (control group). None of the patients in the erythromycin group experienced any abdominal discomfort or gastrointestinal upset.

The indications of capsule endoscopy were as follows: unexplained iron deficiency anemia in 11, obscure gastro-intestinal bleeding in 20, recurrent abdominal pain in 6, and Crohn's disease in 1. Ten patients had diabetes mellitus and none of them was taking medications that would alter the gastric or intestinal motility. There was no significant difference in the demographic data, body build, history of diabetes or thyroid disease, and indications of capsule endoscopy between the two groups of patients (Table 1).

Table 1 Baseline characteristics of patients

	Erythromycin (n = 24)	Control (n = 14)
Mean age±SD (yr)	62.7±17.8	56.3±18.6
Male (%)	9 (37.5)	8 (57.1)
Mean body mass index (±SD)	22.9±3.8	22.3±3.2
Diabetes mellitus (%)	7 (29.2)	3 (21.4)
Indication		
Iron deficiency anemia (%)	6 (25)	5 (36)
Obscure gastro-intestinal bleeding (%)	12 (50)	8 (57)
Recurrent abdominal pain (%)	5 (21)	1 (7)
Crohn's disease (%)	1 (4)	0 (0)

Capsule endoscopy

Capsule endoscopy was performed after 12 h of fasting. Eight aeriels, which were connected to a battery-powered portable data recorder, were attached to the chest and abdominal wall of the patients prior to the procedure. Patients were asked to swallow the M2A[®] capsule endoscope (Given Imaging, Yoqneam, Israel) with plenty of water mixed with simethicone to eliminate small bubbles in the gastrointestinal tract. No bowel cleansing agent was used. Patients were allowed to resume clear fluid diet, 4 h after swallowing the capsule endoscope. The sensor array and recorder were removed from the patients after 8 h of recording. The recorded images were then downloaded to the workstation and viewed by the RAPID software (Given Imaging). Patients were monitored for any abdominal discomfort and pain during and after the examination. The time of spontaneous passage of the capsule endoscope was recorded. Patients who were uncertain of the natural passage of the capsule endoscope were called back for abdominal x-ray to check for possible retention of the capsule endoscope.

Gastric and small bowel transit time

All capsule images were independently viewed by two endoscopists who were unaware of the use of prokinetic agents. Gastric transit time was defined as the time taken from the first gastric image to the first duodenal image. Due to the potential difficulty in accurately identifying the

ileo-cecal valve, small bowel transit time was defined as the time taken between the first duodenal image and the first cecal image. Cases having capsules passed to the cecum were considered to be complete small bowel examination. The overall quality of small bowel images was graded as satisfactory or unsatisfactory by the viewers according to the percentage of good and clear images that were not obscured by food particles or bile. Satisfactory image was defined when more than 90% of the images were optimal and clear. All discrepant findings between the two viewers were resolved on discussion.

Statistical analysis

Categorical data were analyzed by Pearson χ^2 test whereas numerical data were analyzed by Student's *t*-test. All statistical analyses were made by the statistical software SPSS version 11.5 (SPSS Inc., Chicago, IL, USA). A two-sided *P* value of less than 0.05 was considered statistically significant.

RESULTS

Effects of erythromycin on gastric transit time

There was no retention of the capsule endoscope in these 38 examinations. The mean gastric and small intestinal transit time in all patients was 35.9 and 218 min respectively. Notably, the gastric transit time was significantly lower in the erythromycin group. The mean gastric transit was 15.8 min (range <1-60 min) in the erythromycin group and 70.2 min (range 1-298 min) in the control group (*P* = 0.005). While the longest gastric transit time in the erythromycin group was 60 min, five (36%) patients in the control group had gastric transit time of more than 1 h. On the other hand, there was no significant difference in the gastric transit time between diabetic and non-diabetic patients (mean 34.2 *vs* 36.4 min, *P* = 0.92). There was also no significant association between gastric transit time and age (*P* = 0.88), gender (*P* = 0.73), or body mass index (*P* = 0.22) of the patients.

Effects of erythromycin on small bowel examination

One (4%) patient in the erythromycin group had incomplete small bowel examination due to the prolonged small bowel transit time of more than 7 h. In contrast, 3 (21%) patients in the control group had incomplete small bowel examination (*P* = 0.13 *vs* erythromycin group). The reasons were the prolonged gastric and small bowel transit time in two and technical failure in one. For those who had complete small bowel examination, the small bowel transit time was comparable in the erythromycin (mean 227 min, range 85-446 min) and control groups (183 min, range 117-401 min; *P* = 0.18, Table 2). Unsatisfactory images were obtained in 46% patients of the erythromycin group and in 36% of patients of the control group (*P* = 0.74).

Effects of erythromycin on repeat capsule endoscopy

Four patients had repeat capsule endoscopy due to incomplete or sub-optimal examination. The minimal interval between the two examinations was 4 d. Two patients received erythromycin only on the second examination while the other two patients received erythromycin in both

examinations. As shown in Figure 1, there was a marked reduction in gastric transit time of the two patients who were given erythromycin in the second examination. In contrast, there was no apparent change in gastric transit time of the two patients who were given erythromycin in both examinations. The gastric transit time was less than 50 min in all examinations pre-treated with oral erythromycin.

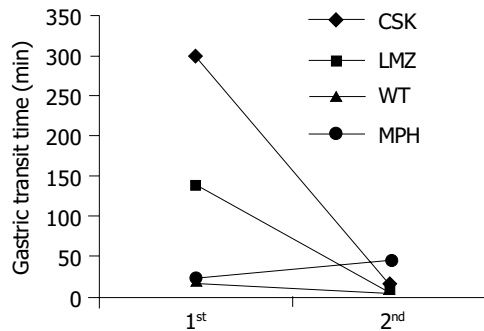


Figure 1 Changes in gastric transit time in patients undergoing repeated capsule endoscopy. Four patients had repeat capsule endoscopy examinations. Two patients (CSK and LMZ), as shown by the black lines, received only erythromycin on the second examination and there was a marked reduction in gastric transit time in the second examination after the use of oral erythromycin. The other patients (WT and MPH), as illustrated by the dotted lines, received erythromycin in both examinations and the gastric emptying time was less than 50 min in both examinations.

Table 2 Gastric and small bowel transit of capsule endoscopy in two groups of patients (mean±SD)

	Erythromycin (n = 24)	Control (n = 14)	P
Gastric transit time (min)	15.8±16.8	70.3±88.1	0.005
Small bowel transit time (min)	226.5±84.0	183.0±91.2	0.18
Incomplete small bowel examination (%)	1 (4)	3 (21)	0.13
Image quality (%)			
Satisfactory	13 (54)	9 (64)	0.74
Unsatisfactory	11 (46)	5 (36)	

DISCUSSION

As gastric and small bowel transit time shows considerable inter-individual variations and the prime interest of the capsule endoscopy is to examine the small bowel only, ways to enhance gastric transit time without compromising small bowel examination would potentially improve the outcome of this investigation. However, the effect of prokinetic agent on this relatively new examination remains elusive. In this study, we specifically addressed the effect of oral erythromycin on gastric and small bowel transit time in patients undergoing capsule endoscopy.

Erythromycin promotes gastric emptying by binding to motilin receptors and acts as a motilin agonist. The use of low dose intravenous erythromycin has been shown to improve gastric emptying in patients with diabetic gastroparesis^[7]. Moreover, erythromycin infusion prior to endoscopy in patients with recent hematemesis has been shown to make endoscopy easier, and reduces the need for a repeat procedure by enhancing the emptying of blood

within the stomach^[9]. Results from this study showed that the use of low dose oral erythromycin could enhance gastric transit time of the wireless capsule endoscopy. The gastric transit time in the 24 patients who received erythromycin was all within 60 min. In contrast, 5 (36%) patients in the control group had gastric transit time of more than 1 h. In a previous volunteer study, it was noted that the mean gastric transit time of capsule endoscopy is 63 min (range 10-319 min)^[10]. This result is comparable to the findings in our control group. To further support our findings, there was a marked reduction in gastric transit time in the two patients who used oral erythromycin on the second examination only.

Other than speeding up the gastric transit time, the use of erythromycin was not associated with any significant changes in small bowel transit time. On the other hand, patients receiving erythromycin tended to have a higher rate of complete small bowel examination. This is probably due to the shortened gastric transit time instead of alterations in small bowel passage by the use of erythromycin. More importantly, the use of erythromycin did not appear to alter the overall quality of small bowel images. The percentage of “unsatisfactory” small bowel images reported in this study was relatively high, which may be related to the use of very stringent criteria for satisfactory images, i.e., >90% clear and optimal images. Moreover, we did not use any bowel cleansing agent in this study, which may further improve the quality of small bowel images^[11]. It was shown in a small uncontrolled study that the use of polyethylene glycol may also shorten the transit time of the capsule endoscopy through the stomach and small bowel^[12]. It remains to be determined whether the combined use of prokinetic agents and bowel cleansing agent has synergistic effect on small bowel transit time.

Erythromycin is a safe and cheap antibiotic, which can be conveniently given via oral route. It is also relatively free of adverse reactions including drug sensitivity. Although most published data used an intravenous preparation of erythromycin, we found that the use of oral dosage was also effective for this purpose. Apart from erythromycin, there are several other prokinetic agents that may be used in reducing gastric transit time during capsule endoscopy. Cisapride, which was previously used as a gastric prokinetic agent, is associated with fatal arrhythmia in susceptible individuals^[13,14] and has been withdrawn by the Food and Drug Administration in 1999^[15]. Domperidone and metoclopramide are also used in treating symptomatic patients with gastroparesis. However, the latter is not infrequently associated with extra-pyramidal side effects. Recently, the 5-HT₄ receptor partial agonist, tegaserod, is found to accelerate gastric emptying and gastro-intestinal transit time in healthy male subjects^[16]. Whether these drugs can also be used as prokinetic agents for capsule endoscopy remains to be determined and it is interesting to compare the effects of different prokinetic agents in future studies.

Although this was a non-randomized study, most of the potential confounding factors were comparable in the two groups. All demographic and clinical details of the two groups were matched. Moreover, all viewers were blinded to the clinical information of the patients. With the shortened

gastric transit time, it is not difficult to anticipate that the time spent by the examiners on reviewing the images would be reduced accordingly. This may be another advantage of using prokinetic agents in this rather time-consuming examination.

In summary, erythromycin given orally prior to swallowing capsule endoscope significantly reduces the gastric emptying time without compromising small bowel transit time and image quality. Further randomized study is necessary to evaluate the role of various prokinetic agents in the performance of capsule endoscopy.

REFERENCES

- 1 **Ell C**, Remke S, May A, Helou L, Henrich R, Mayer G. The first prospective controlled trial comparing wireless capsule endoscopy with push enteroscopy in chronic gastrointestinal bleeding. *Endoscopy* 2002; **34**: 685-689
- 2 **Costamagna G**, Shah SK, Riccioni ME, Foschia F, Mutignani M, Perri V, Vecchioli A, Brizi MG, Piccicocchi A, Marano P. A prospective trial comparing small bowel radiographs and video capsule endoscopy for suspected small bowel disease. *Gastroenterology* 2002; **123**: 999-1005
- 3 **Mylonaki M**, Fritscher-Ravens A, Swain P. Wireless capsule endoscopy: a comparison with push enteroscopy in patients with gastroscopy and colonoscopy negative gastrointestinal bleeding. *Gut* 2003; **52**: 1122-1126
- 4 **Pennazio M**, Santucci R, Rondonotti E, Abbiati C, Beccari G, Rossini FP, De Franchis R. Outcome of patients with obscure gastrointestinal bleeding after capsule endoscopy: Report of 100 consecutive cases. *Gastroenterology* 2004; **126**: 643-653
- 5 **Hara AK**, Leighton JA, Sharma VK, Fleischer DE. Small Bowel: Preliminary Comparison of Capsule Endoscopy with Barium Study and CT. *Radiology* 2004; **230**: 260-265
- 6 **Minocha A**, Katragadda R, Rahal PS, Ries A. Erythromycin shortens oro-caecal transit time in diabetic male subjects: a double-blind placebo-controlled study. *Aliment Pharmacol Ther* 1995; **9**: 529-533
- 7 **Janssens J**, Peeters TL, Vantrappen G, Tack J, Urbain JL, De Roo M, Muls E, Bouillon R. Improvement of gastric emptying in diabetic gastroparesis by erythromycin. Preliminary studies. *N Engl J Med* 1990; **322**: 1028-1031
- 8 **Maganti K**, Onyemere K, Jones MP. Oral erythromycin and symptomatic relief of gastroparesis: a systematic review. *Am J Gastroenterol* 2003; **98**: 259-263
- 9 **Frossard JL**, Spahr L, Queneau PE, Giostra E, Burckhardt B, Ory G, De Saussure P, Armenian B, De Peyer R, Hadengue A. Erythromycin intravenous bolus infusion in acute upper gastrointestinal bleeding: a randomized, controlled, double-blind trial. *Gastroenterology* 2002; **123**: 17-23
- 10 **Appleyard MN**, Glukhovskiy A, Jacob J, Gat D, Lewkowicz S, Swain P. Transit times of the wireless capsule endoscope. *Gastrointest Endosc* 2001; **53**: AB122
- 11 **Viazis N**, Sgouros S, Papaxoinis K, Vlachogiannakos J, Bergele C, Sklavos P, Panani A, Avgerinos A. Bowel preparation increases the diagnostic yield of capsule endoscopy: A prospective, randomized, controlled study. *Gastrointest Endosc* 2004; **60**: 534-538
- 12 **Fireman Z**, Kopelman Y, Fish L, Sternberg A, Scapa E, Mahaina E. Effect of oral purgatives on gastric and small bowel transit time in capsule endoscopy. *Isr Med Assoc J* 2004; **6**: 521-523
- 13 **Bran S**, Murray WA, Hirsch IB, Palmer JP. Long QT syndrome during high-dose cisapride. *Arch Intern Med* 1995; **155**: 765-768
- 14 **Wysowski DK**, Bacsanyi J. Cisapride and fatal arrhythmia. *N Engl J Med* 1996; **335**: 290-291
- 15 **Wysowski DK**, Corken A, Gallo-Torres H, Talarico L, Rodriguez EM. Postmarketing reports of QT prolongation and ventricular arrhythmia in association with cisapride and Food and Drug Administration regulatory actions. *Am J Gastroenterol* 2001; **96**: 1698-1703
- 16 **Degen L**, Matzinger D, Merz M, Appel-Dingemanse S, Osborne S, Luchinger S, Bertold R, Maecke H, Beglinger C. Tegaserod, a 5-HT₄ receptor partial agonist, accelerates gastric emptying and gastrointestinal transit in healthy male subjects. *Aliment Pharmacol Ther* 2001; **15**: 1745-1751

Science Editor Wang XL and Guo SY Language Editor Elsevier HK