

# Macular thickness measurements using Copernicus Spectral Domain Optical Coherence Tomography



Laxmi Gella<sup>a,b</sup>, Rajiv Raman<sup>c,\*</sup>, Tarun Sharma<sup>c</sup>

## Abstract

**Purpose:** To provide normal macular thickness measurements using Spectral Domain Optical Coherence Tomography (SDOCT, Copernicus, Optopol Technologies, Zawierci, Poland).

**Methods:** Fifty-eight eyes of 58 healthy subjects were included in this prospective study. All subjects had comprehensive ophthalmic examination including best-corrected visual acuity (BCVA). All the subjects underwent Copernicus SDOCT. Central foveal thickness (CFT) and photoreceptor layer (PRL) thickness were measured and expressed as mean and standard deviation. Mean retinal thickness for each of the 9 regions defined in the Early Treatment Diabetic Retinopathy Study was reported. The data were compared with published literature in Indians using Stratus and Spectralis OCTs to assess variation in instrument measurements.

**Results:** The mean CFT in the study sample was  $173.8 \pm 18.16$  microns (131–215 microns) and the mean PRL thickness was  $65.48 \pm 4.23$  microns (56–74 microns). No significant difference ( $p = 0.148$ ) was found between CFT measured automated ( $179.28 \pm 22$  microns) and manually ( $173.83 \pm 18.1$  microns). CFT was significantly lower in women ( $167.62 \pm 16.36$  microns) compared to men ( $180.03 \pm 18$  microns) ( $p = 0.008$ ). Mean retinal thickness reported in this study was significantly different from published literature using Stratus OCT and Spectralis OCT.

**Conclusion:** We report the normal mean retinal thickness in central 1 mm area to be between 138 and 242 microns in Indian population using Copernicus SDOCT. We suggest that different OCT instruments cannot be used interchangeably for the measurement of macular thickness as they vary in segmentation algorithms.

**Keywords:** Spectral Domain Optical Coherence Tomography, Retina, Foveal thickness, Photoreceptor layer thickness, Retinal thickness

© 2014 The Authors. Production and hosting by Elsevier B.V. on behalf of Saudi Ophthalmological Society, King Saud University. This is an open access article under the CC BY-NC-ND license (<http://creativecommons.org/licenses/by-nc-nd/3.0/>).  
<http://dx.doi.org/10.1016/j.sjopt.2014.10.003>

## Introduction

The major development in ophthalmic imaging was the introduction of optical coherence tomography (OCT) in 1991 by Huang et al.<sup>1</sup> Ophthalmoscopy, fundus photography and fluorescein angiography are the common tools to diagnose diabetic retinopathy (DR) and diabetic macular edema (DME). Due to the non-invasive nature of the OCT technique

it might replace or add as a complementary to fluorescein angiography. Spectral Domain OCT (SDOCT) is an advanced modification of traditional time domain OCT. The main advantages of the SDOCT are speed and sensitivity,<sup>2,3</sup> which have helped in conducting advanced clinical and research oriented studies. There is an increasing demand for high-resolution imaging of the ocular tissue to improve the diagnosis and management of various retinal diseases.

Received 8 March 2014; received in revised form 17 September 2014; accepted 12 October 2014; available online 18 October 2014.

<sup>a</sup> Elite School of Optometry, No. 8, G.S.T. Road, St. Thomas Mount, Chennai 600 016, Tamil Nadu, India

<sup>b</sup> Birla Institute of Technology and Science, Pilani, India

<sup>c</sup> Shri Bhagwan Mahavir Vitreoretinal Services, 18, College Road, Sankara Nethralaya, Chennai 600 006, Tamil Nadu, India

\* Corresponding author. Tel.: +91 44 28271616.  
e-mail address: [rajivpgraman@gmail.com](mailto:rajivpgraman@gmail.com) (R. Raman).

Retinal thickness is defined as the distance between the vitreoretinal interface and the inner border of retinal pigment epithelium (RPE). Various SDOCTs are commercially available but the segmentation software of these instruments identifies different hyperreflective structures in each cross-sectional image. All instruments in common identify the vitreoretinal interface as inner retinal border. The segmentation of outer retinal border identified by different instruments varies significantly. Stratus OCT considers Photoreceptor-RPE complex as the outer retinal border. Copernicus SDOCT, Spectral OCT/SLO and RTVue-100 identify the inner border of RPE as the outer retinal border. Cirrus HD-OCT measures retinal thickness up to the outer band of the RPE, whereas the Spectralis OCT includes Bruch's membrane in the retinal thickness measurement.

Studies have reported normative data of macular thickness using various commercially available SDOCTs.<sup>4-12</sup> The macular thickness measurement for diagnostic function may differ with the population which is used as a database as well as the instrument which is being used. So it is required that the retinal thickness measurements of normal subjects be as close as possible to the population for which the instrument is to be used. To the best of our knowledge there is no normative database available for Indians using Copernicus SDOCT. The present study provides retinal thickness measurements using Copernicus SDOCT in subjects without any known retinal diseases to establish a normative data for clinical use.

## Materials and methods

Fifty-eight eyes of 58 healthy volunteers were included in this prospective study. One eye of each subject was selected randomly by generating random numbers in excel. The study was approved by the organization's Institutional Review Board, and informed consent was obtained from the subjects in accordance with the Helsinki Declaration. Demographic data and detailed medical and ocular history were obtained from the subjects. All subjects underwent comprehensive ophthalmic examination which included refraction, assessment of intraocular pressure, anterior and posterior segment evaluation including cup disk ratio measurement. Subjects with any ocular pathology or with glaucomatous changes or glaucoma suspects and those with history of any ocular surgeries were excluded. Normal eyes were defined as those that had best correct visual acuity of 20/20 or better. Refractive errors within  $\pm 3.0$ D sphere and less than or equal to  $\pm 1.0$ D cylinder were included. And subjects with significant media opacities which could lead to poor quality scans on SDOCT were excluded. All included subjects underwent Spectral Domain Optical Coherence Tomography (Copernicus, SDOCT, Optopol Technologies, Zawierci, Poland) by a single operator.

SDOCT scans were performed through a dilated pupil while monitoring the reconstructed video image of the central retina. The programs used for the present study were asterisk scan and 3D scan protocols. We can vary the scan length from 4 to 10 mm and also the number of A-scans and B-scans. For the purpose of this study we used a scan length of 7 mm with 6 B-scans and 3000 A-scans per B-scans through the center of the fovea for the asterisk scan protocol. The scan acquisition time was 0.8 s. 3D scan protocol was used with 7 mm scan length with 50 B-scans and 1000

A-scans per B-scan with the time acquisition of 2.4 s. All the measurements were calculated in microns.

The following parameters were noted on SDOCT:

1. *Central foveal thickness (CFT)* was defined as the distance between the vitreoretinal interface and the anterior surface of the RPE and this was measured manually and also automated using measurement software in SDOCT and this was measured in the B-scan where a hyperreflective echo was noted which represents the center of the fovea. This was acquired from asterisk scan protocol.
2. *Mean retinal thickness (MRT)* was noted at the central 1 mm, middle 3 mm and the outer 6 mm ring, in the superior, inferior, nasal and temporal quadrants. These measurements are given by the automated software. This measurement was acquired from 3D scan protocol.
3. *Photoreceptor layer (PRL)* thickness was measured at the central fovea (defined above) from asterisk scan, which was defined as the distance between the external limiting membrane which appears as a thin hyperreflective line on SDOCT and the anterior surface of the retinal pigment epithelium (RPE).

Intra-observer and inter-observer repeatability was determined for the manual measurement of OCT thickness parameters from a pilot study. Intra-observer repeatability was found to be good in measuring the SDOCT outcomes with intraclass correlation of 0.99 for CFT, 0.63 for PRL thickness. For the inter-observer repeatability the mean difference in the CFT measurements was  $6.7 \mu\text{m}$  with limits of agreement ranging from  $-19.4$  to  $32.8 \mu\text{m}$ . The mean difference in the PRL thickness was  $8 \mu\text{m}$  with 95% limits of agreement between  $-7.4$  and  $23.4 \mu\text{m}$ .

Statistical analyses were performed using SPSS (Statistical Package for Social Sciences, version 15.0, Chicago, IL, USA). The results were expressed as mean  $\pm$  SD. Independent *t*-test was used for comparing the parameters between the groups. The level of statistical significance for *P*-value was  $<0.05$ .

## Results

Mean age of the subjects was  $36 \pm 12$  years (range: 21–76 years). There was no significant difference in age between men and women ( $p = 0.28$ ). The mean central foveal thickness in the study sample was  $173.8 \pm 18.16$  microns (131–215 microns) and the mean photoreceptor layer thickness was  $65.48 \pm 4.23$  microns (56–74 microns). No significant difference ( $p = 0.148$ ) was found between CFT measured automated ( $179.28 \pm 22$  microns) and manually ( $173.83 \pm 18.1$  microns). Fig. 1 shows the mean retinal thickness in 9 ETDRS subfields. Temporal quadrant of 6 mm radius was the thinnest in relation to nasal, superior and inferior quadrants.

Table 1 shows the comparison of thickness parameters between men and women. CFT was significantly lower in women ( $167.62 \pm 16.36$  microns) compared to men ( $180.03 \pm 18$  microns) ( $p = 0.008$ ). Women showed significantly decreased retinal thickness in all ETDRS subfields except for the nasal quadrant in 3 mm radius, superior and temporal quadrants of 6 mm radius which did not show any significant difference.

Table 2 shows comparison of mean retinal thickness assessed using OCT in healthy individuals given by various

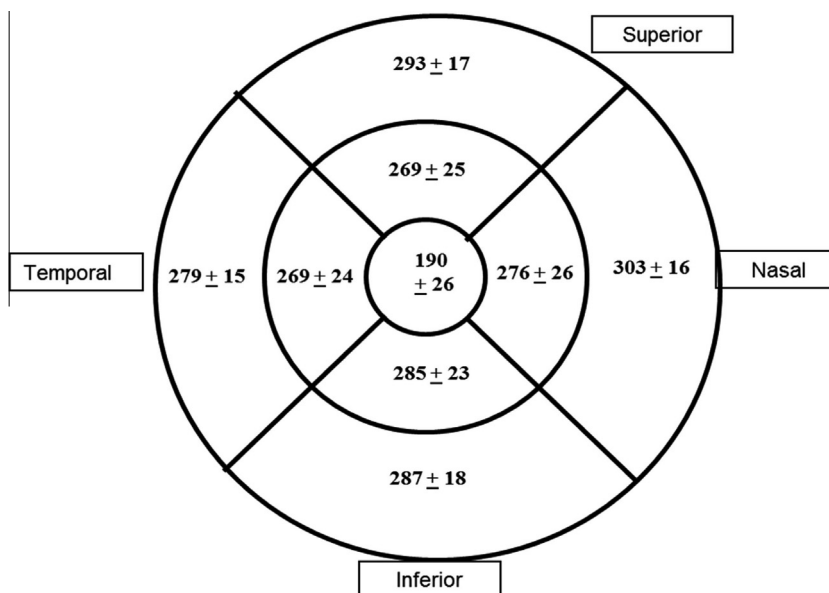


Figure 1. Macular thickness (μm) of study sample in 9 subfields as defined by ETDRS (mean ± SD).

Table 1. Comparison of thickness parameters among men and women.

Variables	Mean ± SD		p
	Men (n = 29)	Women (n = 29)	
Age	37.9 ± 13	34.5 ± 10.3	0.28
Central foveal thickness	180.03 ± 18	167.62 ± 16.36	<b>0.008</b>
Photoreceptor layer thickness	65.96 ± 4.47	65 ± 4	0.39
Mean retinal thickness (1 mm)	202.31 ± 21.2	178.1 ± 26	<b>&lt;0.001</b>
3 mm radius			
Superior	277.07 ± 24	261.8 ± 25	<b>0.02</b>
Inferior	291 ± 20.48	279.3 ± 24.03	<b>0.05</b>
Temporal	279 ± 19.40	260 ± 24	<b>0.002</b>
Nasal	283 ± 21	270 ± 30	0.06
6 mm radius			
Superior	296 ± 14.59	289.03 ± 18.11	0.114
Inferior	293.48 ± 17	281.10 ± 16.35	<b>0.006</b>
Temporal	282 ± 13.33	276.14 ± 17.14	0.161
Nasal	310 ± 13.25	297 ± 16.58	<b>0.002</b>

p < 0.05 is statistically significant.

studies. It shows that there was a significant variation in mean retinal thickness measured by different SDOCT instruments in different population.

Normative data of this study using Copernicus SDOCT were compared to the normative data of Indian population published using Stratus OCT and Spectralis OCT in Table 3. There was a significant difference in mean retinal thickness measurement in all ETDRS subfields among the three studies.

### Discussion

Nasal quadrant of 6 mm radius was significantly thicker compared to other quadrants' mean retinal thickness which could be explained by the anatomical relationship of the converging retinal nerve fibers with optic disk.<sup>13</sup> The observed

macular thickness was thinnest at the fovea and increased towards parafoveal area which is consistent with the normal anatomical contour. Using the criteria of mean ± 2 SDs, which includes 95% of the population, we suggest the normal mean retinal thickness in central 1 mm area to be between 138 and 242 microns in Indian population using Copernicus SDOCT. This range of central retinal thickness was significantly more compared to the study done by Tewari et al.<sup>4</sup> and less compared to that suggested by the Appukuttan et al.<sup>5</sup> which could be due to the different instruments used in the present study.

Women had a significantly lower CFT and also reduced thickness in all ETDRS quadrants except for the nasal quadrant in 3 mm radius and superior and temporal quadrants of 6 mm radius. These findings are in support with those in previous reports, confirming the impact of sex on central retinal thickness measurements.<sup>13-15</sup> Reduced central foveal thickness is compatible with the observation that women have higher risk of developing macular holes.<sup>16,17</sup>

Table 2 shows that there was a significant variation in mean retinal thickness among various studies using different OCT instruments. This could be explained by the difference in the study methodologies and the sample population.

Mean retinal thickness values in Indian population were significantly different in all ETDRS subfields when our study results were compared with the normative data published by other studies in India using Stratus<sup>4</sup> and Spectralis OCT.<sup>5</sup> It is attributed by the fact that the retinal layer segmentation was significantly varied between the instruments.<sup>18</sup> Stratus OCT considers the inner segment outer segment junction of photoreceptors as the outer retinal border for the retinal thickness measurement and Spectralis OCT considers outer border of retinal pigment epithelium as the outer retinal border. Thus the decreased mean retinal thickness in the current study could be due to the exclusion of retinal pigment epithelial thickness which was included in Spectralis OCT.

In summary we provide the normative values of retinal thickness in Indian sample using Copernicus SDOCT. We

**Table 2.** Comparison of mean retinal thickness in other studies and present study.

S No.	Study	Year	Sample	OCT instrument	Mean retinal thickness (1 mm)	Scan protocol	A-scan/B-scan	Refractive error
1	Tewari HK (India) <sup>4</sup>	2004	170	Stratus	181.15 ± 18.42	Radial scan	NA	(-8 to +5.8D)
2	Appukuttan B (India) <sup>5</sup>	2013	105	Spectralis	260.1 ± 18	Cube scan	49 B scans, 40,000 A/B	Within ±5D
3	Choovuthayakorn J (Thailand) <sup>6</sup>	2012	368	Spectralis	259.18 ± 19.08	Raster scan	NA	NA
4	Adhi M (Pakistan) <sup>7</sup>	2012	220	3D OCT, Topcon	229 ± 20.46	Raster scan	256 × 256	Within -5D
5	Mitkova-Hristova VT (Bulgaria) <sup>8</sup>	2011	163	Optovue	248.9 ± 17.9	Retinal map	NA	Within ±5D
6	Legarreta JE (Florida) <sup>9</sup>	2008	50	Cirrus HD-OCT	258.2 ± 23.5	Macular cube	200 × 200	NA
7	Grover S (Florida) <sup>10</sup>	2009	50	Spectralis	270.2 ± 22.5	Radial scans	NA	Within ±6D
8	Sabates FN (Missouri) <sup>11</sup>	2011	169	Spectral OCT/SLO	254 ± 27	NA	200 × 200	3 to -10
9	Wolf-Schnurrbusch UE <sup>18</sup>	2009	20	Stratus OCT	213 ± 19	Fast macula	6 B scans, 128 A/B	1 to -2
				Spectralis	288 ± 16	Volume scan	512 × 49	
				Spectral OCT/SLO	243 ± 25	3D retinal topography	512 × 64	
				Cirrus HD-OCT	276 ± 17	Macular cube	512 × 128	
				SOCT	246 ± 23	3D scan	673 × 50	
				Copernicus				
				RTVue-100	245 ± 28	Macular map	512 × 101	
10	Kakinoki M (Japan) <sup>19</sup>	2008	50	Stratus OCT	197.2 ± 17.8	Fast macula	6 B scans, 128 A/B	NA
				Cirrus HD-OCT	257.6 ± 19.6	Macular cube	200 × 200	
11	Leung CK (Hong Kong) <sup>20</sup>	2008	35	Stratus OCT	195.6 ± 17.2	Fast macula	6 B scans, 128 A/B	From +3 to -6D
				3D OCT, Topcon	216.4 ± 18	Raster scan	256 × 256	
12	Present study	2014	58	SOCT Copernicus	190	3D scan	50 B scans, 1000A/B	Within ±3D

**Table 3.** Comparison with Indian normative data of other studies.

Thickness parameters	OCT considering IS/OS RPE junction as outer retinal border (1) Stratus <sup>4</sup>	OCT considering outer RPE surface as outer retinal border (2) Spectralis <sup>5</sup>	OCT considering inner RPE surface as outer retinal border (3) Copernicus (current study)	p	1 vs 2	1 vs 3	2 vs 3
Central foveal thickness	149.16 ± 21.15	220.96 ± 13.76	173.83 ± 18.16	<0.0001	<0.0001	<0.0001	<0.0001
Mean retinal thickness (1 mm)	181.15 ± 18.42	260.10 ± 18.19	190.21 ± 26.31	<0.0001	<0.0001	<0.0001	<0.0001
3 mm radius							
Superior	254.65 ± 20.99	337.95 ± 17.46	269.47 ± 25.22	<0.0001	<0.0001	<0.0001	<0.0001
Inferior	256.19 ± 18.83	335.53 ± 17.87	285.03 ± 22.85	<0.0001	<0.0001	<0.0001	<0.0001
Temporal	223.69 ± 25.05	324.90 ± 16.35	269.19 ± 23.65	<0.0001	<0.0001	<0.0001	<0.0001
Nasal	257.90 ± 20.54	338.88 ± 18.17	276.29 ± 26.07	<0.0001	<0.0001	<0.0001	<0.0001
6 mm radius							
Superior	228.08 ± 15.72	295.62 ± 14.71	292.50 ± 16.67	<0.0001	<0.0001	<0.0001	0.192
Inferior	217.86 ± 15.19	283.46 ± 15.25	287.29 ± 17.53	<0.0001	<0.0001	<0.0001	0.094
Temporal	209.48 ± 16.88	281.60 ± 14.21	279.00 ± 15.49	<0.0001	<0.0001	<0.0001	0.16
Nasal	245.09 ± 16.75	312.23 ± 17.08	303.29 ± 16.29	<0.0001	<0.0001	<0.0001	0.001

p < 0.05 is statistically significant.

found that the mean retinal thickness given by the three different OCT instruments in Indian sample were significantly different. These discrepancies were probably due to the segmentation algorithms used by different OCT instruments. Furthermore, as the segmentation algorithms are different among OCT devices, the outer boundary used for the thickness measurement may strongly depend on the OCT system used. These data imply that different OCT instruments cannot be used interchangeably for the measurement of macular thickness.

**Conflict of interest**

The authors declared that there is no conflict of interest.

**References**

- Huang D, Swanson EA, Lin CP, Schuman JS, Stinson WG, Chang W, et al. Optical coherence tomography. *Science* 1991;254:1178-81.
- Szkulmowska Anna, Cyganek Marta, Targowski Piotr, Kowalczyk Jakub J, Kaluzny Jakub J, Wojtkowski Maciej, et al. Standard

- resolution spectral domain optical coherence tomography in clinical ophthalmic imaging. *Proc SPIE* 2005;**5688**:69.
3. Sayeram Sunita, Izatt Joseph. High-resolution SDOCT imaging cutting-edge technology for clinical and research applications. *Photonik Int Online* 2008;**November**.
  4. Tewari HK, Wagh VB, Sony P, Venkatesh P, Singh R. Macular thickness evaluation using the optical coherence tomography in normal Indian eyes. *Indian J Ophthalmol* 2004;**52**:199–204.
  5. Appukuttan B, Giridhar A, Gopalakrishnan M, Sivaprasad S. Normative spectral domain optical coherence tomography data on macular and retinal nerve fiber layer thickness in Indians. *Indian J Ophthalmol* 2014;**62**:316–21.
  6. Choovuthayakorn J, Watanachai N, Chaikitmongkol V, Patikulasila D, Kunavisarut P, Ittipunkul N. Macular thickness measured by spectral-domain optical coherence tomography in healthy Thai eyes. *Jpn J Ophthalmol* 2012;**56**:569–76.
  7. Adhi M, Aziz S, Muhammad K, Adhi MI. Macular thickness by age and gender in healthy eyes using spectral domain optical coherence tomography. *PLoS One* 2012;**7**:e37638.
  8. Mitkova-Hristova VT, Konareva-Kostyaneva MI. Macular thickness measurements in healthy eyes using spectral optical coherence tomography. *Folia Med (Plovdiv)* 2011;**53**:28–33.
  9. Legarreta JE, Gregori G, Punjabi OS, Knighton RW, Lalwani GA, Puliafito CA. Macular thickness measurements in normal eyes using spectral domain optical coherence tomography. *Ophthalmic Surg Lasers Imaging* 2008;**39**(4 Suppl.):S43–9.
  10. Grover S, Murthy RK, Brar VS, Chalam KV. Normative data for macular thickness by high-definition spectral-domain optical coherence tomography (spectralis). *Am J Ophthalmol* 2009;**148**:266–71.
  11. Sabates FN, Vincent RD, Koulen P, Sabates NR, Gallimore G. Normative data set identifying properties of the macula across age groups: integration of visual function and retinal structure with microperimetry and spectral-domain optical coherence tomography. *Retina* 2011;**31**:1294–302.
  12. Grover S, Murthy RK, Brar VS, Chalam KV. Comparison of retinal thickness in normal eyes using Stratus and Spectralis optical coherence tomography. *Invest Ophthalmol Vis Sci* 2010;**51**:2644–7.
  13. Hee MR, Puliafito CA, Duker JS, Reichel E, Coker JG, Wilkins JR, et al. Topography of diabetic macular edema with optical coherence tomography. *Ophthalmology* 1998;**105**:360–70.
  14. Song WK, Lee SC, Lee ES, Kim CY, Kim SS. Macular thickness variations with sex, age, and axial length in healthy subjects: a spectral domain-optical coherence tomography study. *Invest Ophthalmol Vis Sci* 2010;**51**:3913–8.
  15. Wong AC, Chan CW, Hui SP. Relationship of gender, body mass index, and axial length with central retinal thickness using optical coherence tomography. *Eye* 2005;**19**:292–7.
  16. Evans JR, Schwartz SD, McHugh JD, Thamby-Rajah Y, Hodgson SA, Wormald RP, et al. Systemic risk factors for idiopathic macular holes: a case-control study. *Eye* 1998;**12**:256–9.
  17. Anonymous. The Eye Disease Case-Control Study Group. Risk factors for idiopathic macular holes. *Am J Ophthalmol* 1994;**118**:754–61.
  18. Wolf-Schnurrbusch UE, Ceklic L, Brinkmann CK, Iliev ME, Frey M, Rothenbuehler SP, et al. Macular thickness measurements in healthy eyes using six different optical coherence tomography instruments. *Invest Ophthalmol Vis Sci* 2009;**50**:3432–7.
  19. Kakinoki M, Sawada O, Sawada T, Kawamura H, Ohji M. Comparison of macular thickness between cirrus HD-OCT and stratus OCT. *Ophthalmic Surg Lasers Imaging* 2009;**40**:135–40.
  20. Leung CK, Cheung CY, Weinreb RN, Lee G, Lin D, Pang CP, et al. Comparison of macular thickness measurements between time domain and spectral domain optical coherence tomography. *Invest Ophthalmol Vis Sci* 2008;**49**:4893–7.