

SIMPLIFIED TYPE 3 IMPLANT PLACEMENT, AFTER ALVEOLAR RIDGE PRESERVATION: A CASE STUDY

F. CECCHETTI, F. GERMANO, F.N. BARTULI, L. ARCURI, M. SPUNTARELLI

Periodontology Department, University of Rome "Tor Vergata", Isola Tiberina Fatebenefratelli, Rome, Italy

Alveolar ridge, after tooth extraction, could reduce its volume up to 50% in buccal-lingual width in the first twelve months and residual dimensions could interfere with correct three dimensional placement of implants and influence negatively treatment outcomes with regard to function and aesthetic aspects.

Over the last decades, several approaches have been proposed and tested in order to prevent ridge volumetric contraction and provide maximum bone availability for implant procedure.

This article presents a case study with a single anterior tooth replacement, illustrating socket seal technique followed by a type 3 timing implant placement.

Immediately after tooth extraction, residual socket was grafted using Deproteinized Bovine Bone Mineral and a free gingival punch harvested from palate. After 3 months, a root-form titanium implant was inserted without additional regenerative procedures. Follow-up examination revealed favourable preservation of soft tissue width and height in the aesthetic area.

Socket seal approach maximizes soft tissue healing, preserving ridge envelope and the subsequent implant placement, furthermore, results simplified, as any augmentation techniques are required.

Clinical advantages of this method include predictable preservation of the soft tissues, favourable healing features, easy handling of graft materials and a positive benefit-cost ratio.

Key words: socket preservation, ridge preservation, gbr.

Introduction

Following tooth extraction, the residual alveolar ridge goes into a three dimensional remodelling process with an high rate of bone resorption, while bone formation takes place within residual socket.

Tan et al. (1) demonstrated that after tooth extraction, horizontal bone loss is larger than the vertical one and they found mean reductions in width of 3.8 mm and of 1.24 mm in height after 6 months. They confirmed the greater pattern of resorption of buccal aspect compared to palatal one. Similar results were showed by Van der Veijden et al. (2) in their review.

After this remodelling process following tooth extraction, residual alveolar ridge dimensions

could interfere with correct prosthetic driven implant placement and influence negatively functional and aesthetic outcomes (3).

Dietrich (4) suggested that alveolar bone width should be 1 to 1.5 mm wider than the diameter of the implant either on the buccal and on the lingual side.

Further, an implant should not be placed too facially for potential risks for soft tissue recession while implant positioned too palatally could have emergence problems. Incorrect mesiodistal implant position could have a deep impact on the determination of interproximal papillary support as well as on the osseous crest of the adjacent natural tooth (5). Main aesthetic goals of modern implant therapy are characterized by "the achievement of a harmonious gingival margin without abrupt changes in tissue height, main-

taining intact papillae, and obtaining or preserving a convex contour of the alveolar crest” (6). Thickness and height of the facial bone wall are strategic elements for long-term stability of harmonious gingival margins around implants and the height of the alveolar bone at interproximal area (5).

Over the last decades, several methods have been presented with the aim of preventing alveolar ridge volumetric contraction, ranging from socket grafting to immediate implant placement; today are called Ridge Preservation techniques, defined as “any therapeutic approach carried out after tooth extraction aimed to preserve the alveolar socket architecture and to provide the maximum bone availability for implant placement” (7). In other words, the goal is to reduce vertical and horizontal ridge volumetric alterations in postextraction sites and maximize bone formation within the socket (3, 5).

Several recent reviews and meta-analyses underlined that ridge preservation techniques may reduce bone loss after tooth extraction but this resorption/remodelling process could not be prevented at all (7-9).

Autogenous soft tissue grafting to seal extraction socket was proposed in order to improve the healing of soft tissue before implant placement. Jung et al. (10) codified the soft tissue punch technique. It involves socket grafting with xenograft, covered with free gingival graft harvested from palatal mucosa; thus achieving soft tissue closure at the extraction site. The aim of this technique is to reduce soft tissue shrinkage after tooth extraction and optimize delayed implant insertion.

In this paper is presented a case study with a single anterior tooth rehabilitation, performing socket seal technique before a type 3 timing implant placement.

Materials and methods

A healthy 56-year-old woman presented with a severe mobility of the maxillary left central incisor. The tooth, previously restored with a metal ceramic crown, revealed a probing depth extended

to the apex, a Class III mobility with a hopeless prognosis (Fig. 1).

At the radiographic evaluation it showed a chronic periapical infection with an extended demineralization of the bone around the root, mostly at the distal aspect (Fig. 2).

The surgical case, analyzed in accordance with SAC Classification Protocol (11), was classified

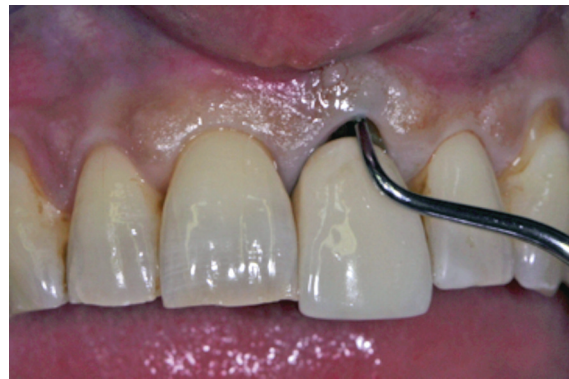

Figure 1
Tooth #2.1 needs to be extracted.

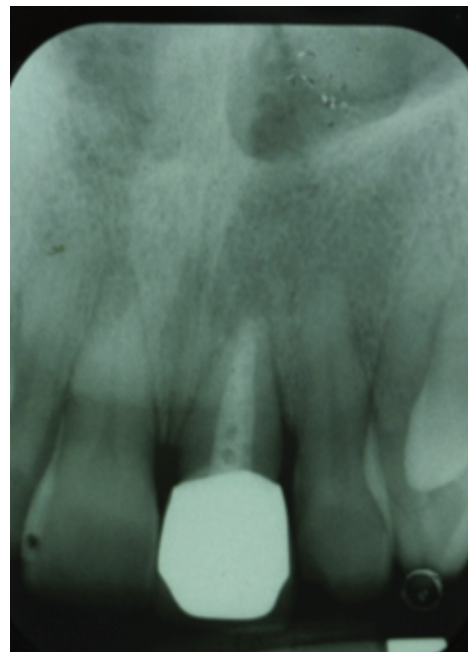

Figure 2
Radiographic evaluation at the time of extraction.

as Advanced, with an adjunctive soft tissue graft as additional procedure required.

A type 3 timing implant was selected to rehabilitate the site.

Tooth extraction and socket graft were realized at the same time. The extraction socket was grafted using DBBM and a free gingival punch harvested from palate, according to the Soft Tissue Punch Technique (10). After 3 months, a titanium implant was inserted in preserved ridge and a conventional loading protocol was applied.

The patient provided written informed consent regarding surgical procedures.

Antibiotic (875mg+ 125mg tablet Augmentin, GlaxoSmithKline) and analgesic (600mg Brufen tablet, Abbott) were given to the patient 1 hour before surgery. A 1 minute rins with 0.2% CHX solution was performed by the patient at the beginning of the procedure.

After local anesthesia (Arthocain, Septanest), #2.1 tooth was gently extracted using syndesmotome and finally with a forceps.

The socket was debrided with curettes and alveolar spoons; the granulation tissue was carefully removed. The absence of buccal wall was revealed by inspection with periodontal probe (Hu- Friedy PCP UNC 15). To eliminate epithelium from socket tissue walls and gingival sulcus a #15C surgical blade was used (Fig. 3).

Mesio-Distal and Buccal-Lingual diameters were measured with periodontal probe and an elliptical aluminium foil chip with same dimen-

sions was realized, cutting it from a sheet previously autoclaved. The donor site was in the area between first and second premolar, 5 mm from gingival margin (Fig. 4).

The chip was placed on palatal mucosa and used as a guide to get a free gingival graft with surgical blade #15c. It was 2-3 mm thick and 1 mm wider than socket dimensions. The donor site was covered by collagen (Smith&nephew Condress Collagen Tab), and stabilized with interrupted sutures (Ethicon Coated VICRYL™ RAPIDE 5-0).

The socket was grafted with DBBM (Small Geistlich Bio-Oss® granules 0.25 - 1 mm). Bone substitute was gently condensed, leaving coronally a 2 mm free space (Fig. 5).

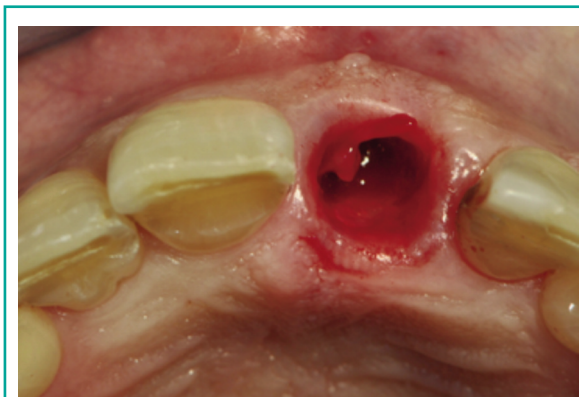


Figure 3
Residual socket after gentle extraction.

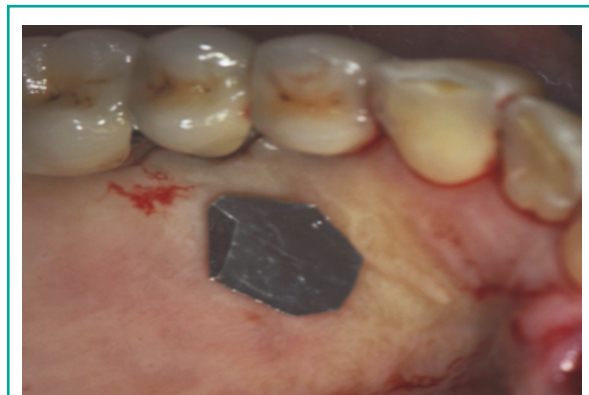

Figure 4
Aluminium foil chip with socket dimensions at the donor site.

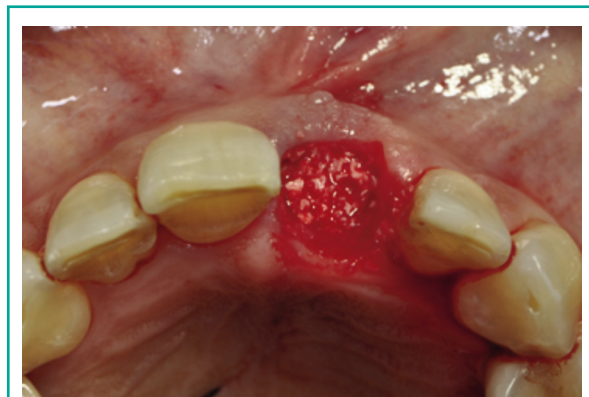

Figure 5
DBBM is applied into the socket.

The free gingival graft was placed on the top and stabilized to the gingival margin with several interrupted sutures (Ethicon Coated VICRYL™ RAPIDE 5-0) (Fig. 6).

A provisional resin bonded bridge was cemented to adjacent teeth without any compression to soft tissues below.

After surgery, antibiotics (twice a day for six days, 875mg+ 125mg tablet Augmentin, Glaxo-SmithKline) and analgesic (twice a day for two days, 600mg Brufen tablet, Abbott) were recommended. The patient was instructed to not brush at the surgical area for three weeks and to rinse for 1 minute with 0.2% chlorexidine twice a day for the same time. Sutures were removed 14 days after surgery.

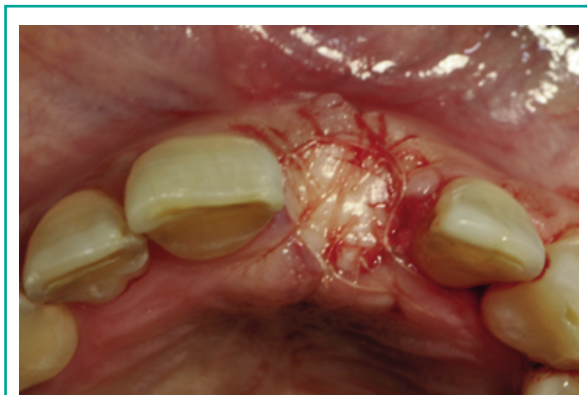

Figure 6
Soft tissue punch is sutured to the gingival margin.

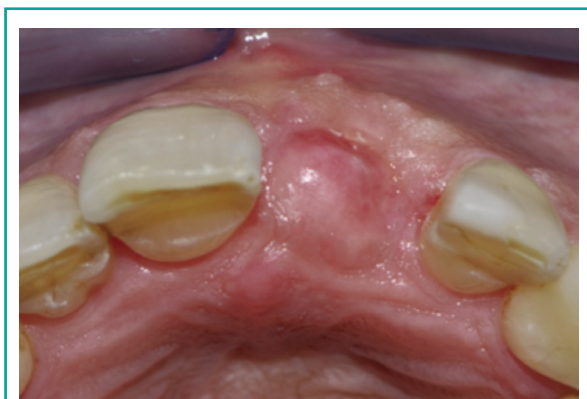

Figure 7
Clinical situation after three months.

Three months after tooth extraction, was planned the implant placement with a submerged approach (Fig. 7).

Radiographic evaluations on Tc scans showed an adequate bone volume in height and in width, allowing a prosthetic driven implant placement (Figs. 8 and 9).

The same preoperative medication regimen was applied.

After local anesthesia (Arthicaid, Septanest), a crestal incision going to mesial aspect of 2.2 to distal aspect of 1.1 was realized by a #15 c surgical blade. The incision continued intrasulcularly at distal aspect of 1.1 and at mesial aspect of 2.2. both buccally and palatally.

A full-thickness flap was elevated and according to manufacturer drilling guidelines, a titanium implant was inserted (Straumann Bone Level SLA-Ø3.3 mm-8 mm). After a cover screw placement, flap was sutured to achieve primary closure (Ethicon Coated VICRYL™ RAPIDE 5-0) (Fig. 10).

Chlorexidine mouthwash, oral hygiene recommendations, antibiotics and analgesic were pre-

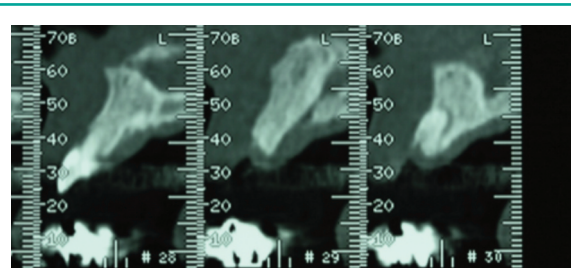


Figure 8
Evaluation of preserved ridge dimensions on TC scans.

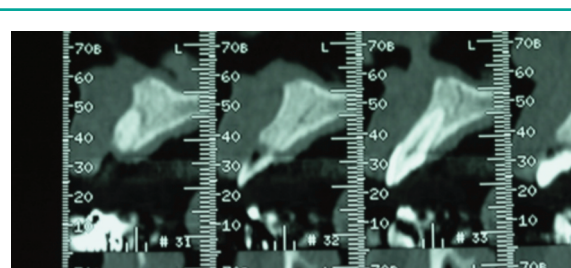


Figure 9
Evaluation of preserved ridge dimensions on TC scans.

scribed with the same protocol used after socket grafting. Sutures were removed after two weeks. According to Grutter's (12) consensus statement, conventional loading protocol was applied. After three months, implant uncovering was realized. A provisional fixed restoration was placed two weeks later (Fig. 11). A Zirconia based ceramic crown was cemented 6 months after implant placement (Fig. 12).

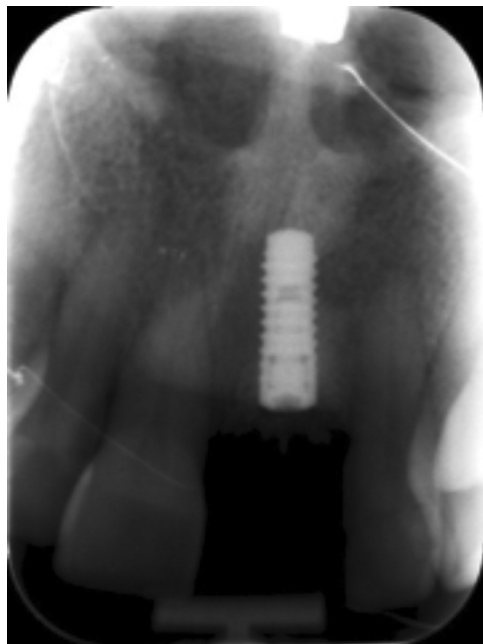

Figure 10
Implant placement after 3 months of extraction.

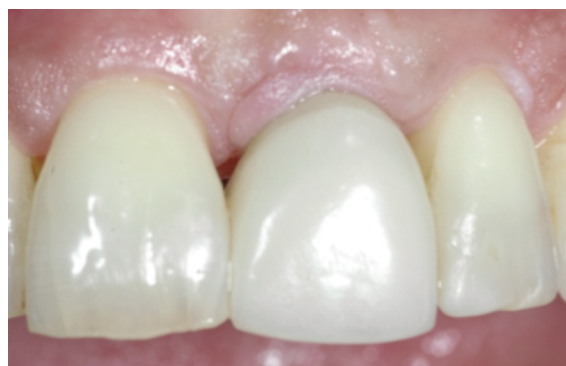

Figure 11
Provisional crown cemented 90 days after implant procedure.

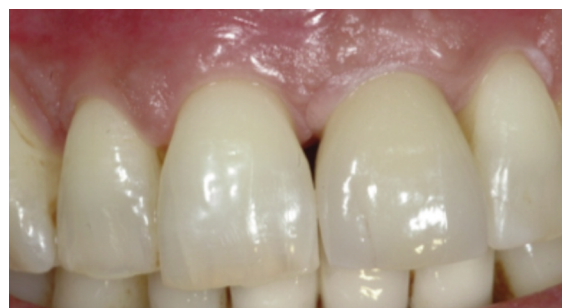

Figure 12
Zirconia based ceramic crown positioned 6 months later implant placement.

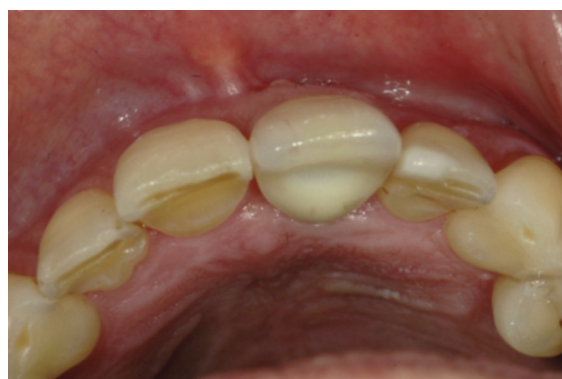

Figure 13
Occlusal aspect at 6 months after implant procedure.

Control appointments were scheduled at 4 months intervals. Follow-up examination revealed favourable preservation of soft tissues width and height in the aesthetic area (Fig. 13).

Discussion

Schropp et al. (13) found a reduction up to 50% in buccal-lingual width of the residual alveolar ridge in the first twelve months after the extraction; two thirds of these changes takes place in the first twelve weeks.

In a recent Consensus Report by Hammerle et al. (14) was stressed the difference between Ridge Preservation and Ridge Augmentation. The first one preserves

ridge volume within the envelope at the time of extraction, while the second one has the object to enlarge ridge volume existing at the time of extraction. Most important indication for ridge preservation is if an implant is to be placed more than eight weeks after tooth extraction. Alveolar Ridge Preservation (ARP) treatments involve placement of different grafting materials often in conjunction with the use of membranes.

Bone grafting alone, membrane alone and membrane in conjunction with grafting are the most frequent ARP approaches reported in literature (5). Furthermore there is no evidence to draw guidelines or to identify a perfect technique and the best material (5, 7).

Socket seal technique was presented with the aim to preserve the envelope, with a well maintained ridge volume for improving functional and aesthetic outcomes and to simplify delayed implant procedures (10). Most important goal of this method is the development of a “good soft tissue volume for an earlier time point implant” (14).

In this case study, a well maintained alveolar ridge volume allowed a simplified implant insertion which didn't require any regenerative additional procedure.



Conclusions

Socket seal approach maximizes soft tissue healing preserving ridge envelope and simplifies the subsequent implant placement, as any augmentation techniques are required.

Clinical advantages of this approach include predictable preservation of the soft tissues, favourable healing features, easy handling of graft materials and a positive benefit-cost ratio.



References

1. Tan WL, Wong TLT, Wong MCM, Lang NP. A systematic review of post-extraction alveolar hard and soft tissue dimensional changes in humans. *Clin Oral Impl Res.* 2012;23(Suppl. 5):1-21.
2. Van der Weijden F, Dell'Acqua F, Slot DE. Alveolar

bone dimensional changes of post-extraction sockets in humans: a systematic review. *J Clin Periodontol.* 2009;36:1048-1058.

3. Darby I, Chen S, De Poi R. Ridge preservation: What is it and when should it be considered? *Aust Dent J.* 2008;53:11-21.
4. Dietrich U, Lippold R, Dirmeier T, Behneke N, Wagner W. Statistische Ergebnisse zur Implantatprognose am Beispiel von 2017 IMZ-Implantaten unterschiedlicher Indikationen der letzten 13 Jahre. *Zeitschrift für Zahnärztliche Implantologie.* 1993;9:9-18.
5. Darby I, Chen S, Buser D. Ridge Preservation Techniques for Implant Therapy. *Int J Oral Maxillofac Implants.* 2009;24:260-271.
6. Buser D, Martin W, Belser UC. Optimizing Esthetics for Implant Restorations in the Anterior Maxilla: Anatomic and Surgical Considerations. *Int J Oral Maxillofac Implants.* 2004;19:43-61.
7. Vignoletti F, Matesanz P, Rodrigo D, Figuero E, Martin C, Sanz M. Surgical protocols for ridge preservation after tooth extraction: a systematic review. *Clin Oral Implants Res.* 2012;23(Suppl 5):22-38.
8. Ten Heggeler JM, Slot DE, Van der Weijden GA. Effect of socket preservation therapies following tooth extraction in non-molar regions in humans: a systematic review. *Clin Oral Implants Res.* 2011;22:779-788.
9. Avila-Ortiz G, Elangovan S, Kramer KWO, Blanchette D, Dawson DV. Effect of Alveolar Ridge Preservation after Tooth Extraction: A Systematic Review and Meta-analysis. *J Dent Res.* 2014;93(10):950-958.
10. Jung RE, Siegenthaler DW, Hammerle CHF. Postextraction tissue management: A soft tissue punch technique. *Int J Periodontics Restorative Dent.* 2004;24:545-553.
11. Dawson A, Chen S, Buser D, Cordaro L, Martin W, Belser U. The SAC classification in implant dentistry. 2009. Quintessence Publishing Co.
12. Grütter L, Belser UC. Implant loading protocols for the partially edentulous esthetic zone. *Int J Oral Maxillofac Implants.* 2009;24 (suppl):169-179.
13. Schropp L, Wenzel A, Kostopoulos L, Karring T. Bone healing and soft tissue contour changes following single-tooth extraction: a clinical and radiographic 12-month prospective study. *Int J Periodontics Restorative Dent.* 2003;23:313-323.
14. Hammerle CHF, Araujo MG, Simion M, On Behalf of the Osteology Consensus Group 2011. Evidence-based knowledge on the biology and treatment of extraction sockets. *Clin Oral Impl Res.* 2012;23(Suppl. 5):80-82.

Correspondence to:

Francesco Cecchetti
 Periodontology Department
 University of Rome “Tor Vergata”
 Isola Tiberina Fatebenefratelli
 Rome, Italy
 E-mail: francesco.cecchetti@tin.it