

# Laser Tattoo Removal: A Clinical Update

Stephanie GY Ho, Chee Leok Goh

Department of Dermatology, National Skin Centre, Singapore

Address for correspondence: Dr. Chee Leok Goh, National Skin Centre, 1 Mandalay Road, Singapore. E-mail: clgoh@nsc.gov.sg

## ABSTRACT

Techniques for tattoo removal have evolved significantly over the years. The commonly used Quality-switched (QS) ruby, alexandrite, and Nd:YAG lasers are the traditional workhorses for tattoo removal. Newer strategies using combination laser treatments, multi-pass treatments, and picosecond lasers offer promising results. The tattoo color and skin type of the patient are important considerations when choosing the appropriate laser. Standard protocols can be developed for the effective and safe treatment of tattoos.

**KEYWORDS:** Tattoo removal, Quality-switch lasers, Picosecond lasers

## INTRODUCTION

Tattoos have fascinated mankind from all cultures and strata of society for centuries. From the ancient Egyptian, Greek, and Roman cultures to the modern society we have today, skin markings have been used to enhance beauty, demonstrate uniqueness, signify belonging, and sometimes to identify, shame, or punish. It has been estimated that up to a quarter of young to middle-aged adults in the United States have at least one tattoo.<sup>[1]</sup> Results from an online survey group, Harris Interactive, reported a rise in US adult tattoo prevalence from 16% in 2003 to 21% in 2012.<sup>[2]</sup> As more tattoos are being acquired, increasing numbers of people are also seeking their removal. The American Society of Dermatologic Surgery reported carrying out 100,000 tattoo removal procedures in 2011, up from 86,000 in 2010.<sup>[3]</sup> Motivation for tattoo removal includes new jobs or careers, the need to portray a certain image at work or in new social circles, and new, negative feelings towards old tattoos.<sup>[4]</sup> Unfortunately, the removal of tattoos is generally more costly and time consuming than acquiring them.

## TYPES OF TATTOOS

Tattoos are created by the introduction of exogenous pigment into the dermal skin layer and can be placed

with intent, or be the result of accidents and trauma. Tattoos can broadly be divided into professional, amateur, cosmetic, traumatic, or medical tattoos. Professional tattoos are applied with a tattoo machine into the deeper layer of the dermis, and are applied to be permanent in nature. They generally require repeated treatments to remove.

Amateur tattoos are usually smaller, lighter in color and applied more superficially using handheld needles or homemade machines, which render them easier to remove.<sup>[5]</sup> Cosmetic tattoos are often referred to as permanent makeup, and are increasingly popular. Permanent eyeliners, eyebrows, and lip liners are commonly applied using the process of micropigmentation to save time and enhance facial features. However, the inks used often contains pigments that are red, brown, white, or flesh colored; inks containing titanium dioxide and iron oxide<sup>[6]</sup> are difficult to remove. Traumatic tattoos are deposited in the skin following abrasion, laceration, or explosive injuries. Such pressurized penetration of dark particles into the deep dermis gives rise to black or blue tattoos, depending on the depth of the pigment.<sup>[7]</sup> Tattoos have also been used in the field of medicine, from corneal tattooing, radiotherapy field marking, to medical alert tattoos, where tattoos etched into the skin replaces medical alert jewellery for the purpose of alerting medical personnel during emergency situations.<sup>[8]</sup>

## TATTOO REMOVAL

Historically, the removal of undesired tattoos included destructive techniques such as dermabrasion, salabrasion, chemical destruction, cryosurgery, electrosurgery, and surgical excision.<sup>[9-11]</sup> Such non-selective destructive

Access this article online	
<p>Quick Response Code:</p> 	<p>Website: www.jcasonline.com</p> <hr/> <p>DOI: 10.4103/0974-2077.155066</p>

modalities often result in incomplete removal, and varying degrees of scarring and dyspigmentation. Advances in laser and light-based technology have revolutionized tattoo removal, using various wavelengths to target different colored pigments with relative ease and fewer complications than before.

Quality-switched (QS) lasers have long been the traditional workhorse for the removal of tattoos. The laser treatment of tattoos is based on the concept of selective photothermolysis, where laser light of different wavelengths is preferentially absorbed by different chromophores. If the target chromophore is heated for no longer than its thermal relaxation time (time required for target to lose 50% of its heat), selective destruction of these chromophores can be achieved.<sup>[12]</sup> In the case of tattoos, the chromophore is exogenously-placed ink, which is found in membrane-bound granules in macrophages, fibroblasts, or mast cells.<sup>[13]</sup> Such tattoo pigment is very small, and can reach its thermal relaxation time very quickly. Rapid heating with very short pulse durations, in the nanosecond or picosecond range, is therefore required to cause photoacoustic injury and rupture of these pigment-containing cells. Phagocytosis is subsequently triggered and the tattoo fragments are packaged for lymphatic drainage and further scavenged by dermal macrophages, fibroblasts, and mast cells, leading to lightening of the tattoo.

**Patient evaluation and pre-treatment concerns**

A thorough history and examination are essential in establishing the type of tattoo and the skin type of patient prior to treatment. Previous isotretinoin treatment, systemic gold therapy, herpes infection, keloidal tendencies, and sun exposure habits should be considered, as additional precautionary measures may be needed. Standardized digital photography is helpful in recording the baseline appearance, and any subsequent improvement. The patient’s treatment objective and expectation should be counseled, and treatment options, expected outcome, potential risks, downtime, and postoperative care should be discussed. There should be adequate opportunity for patients to have all their questions answered. Obtaining informed consent with a clear outline of risks and benefits prior to tattoo removal

is essential, and protects both the clinician and patient. Establishing realistic patient expectations through good rapport is helpful in achieving a satisfactory outcome.

Multiple laser treatments are usually required to remove a tattoo via selective photothermolysis, with an average number of 7-10 treatments are often needed. Kirby *et al.* published a scale [Table 1] to better help clinicians estimate the number of treatment sessions needed, which can be a useful aid during patient counselling.<sup>[14]</sup> In the scale, numerical values are assigned to six parameters: Fitzpatrick skin phototype, location, color, amount of ink used in tattoo, scarring or tissue change, and ink layering. Parameter scores can then be added up to give a combined score that will show the approximate number of treatment sessions needed for successful tattoo removal, plus or minus 2.5.

**Potential complications**

In addition to establishing a realistic number of treatment sessions needed, it is important to highlight to patients the potential side effects of tattoo removal.

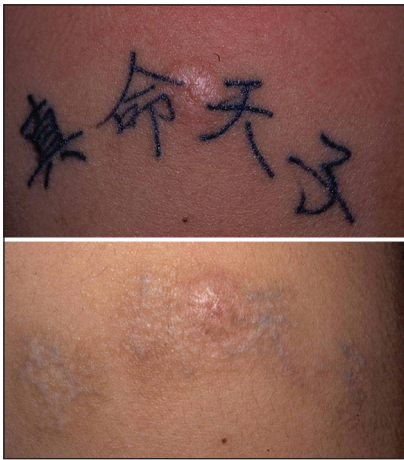Patients should be counseled that tattoo clearance is often incomplete and a residual tattoo outline and textural changes may be seen [Figure 1]. An online questionnaire with 157 participants post tattoo removal showed that only 38% achieved complete tattoo removal. Local reactions following tattoo removal occurred in 97% of participants, and include blistering, edema, crusting, erythema, and pain. Permanent side effects can occur, and include scarring, hyper- or hypopigmentation [Figure 2], and color change of tattoo pigment. Patients with darker skin type are at a higher risk of complications.<sup>[15]</sup> Skin textural changes are not uncommon and follow multiple laser treatments post treatment [Figure 1].

Strict sun protection measures must be emphasized to all patients. Melanin in the epidermis can compete for the absorption of laser light intended for tattoo removal. This can cause destruction of the melanin containing cells and manifest as dyspigmentation, blistering or scarring. The use of longer wavelengths such as the QS Nd:YAG (1064 nm) in patients with a tan or patients with darker skin types can reduce such

**Table 1: Kirby Desai scale for estimating number of treatment sessions needed for tattoo removal\***

Phototype	Location	Color	Ink amount	Scarring	Layering
I-1 point	Head and neck-1 point	Black only-1 point	Amateur-1 point	No scar-0 points	None-0 points
II-2 points	Upper trunk-2 points	Mostly black with some red-2 points	Minimal-2 points	Minimal-1 point	Layering-2 points
III-3 points	Lower trunk-3 points	Mostly black and red with some other colors-3 points	Moderate-3 points	Moderate-3 points	
IV-4 points	Proximal extremity-4 points	Multiple colors-4 points	Significant-4 points	Significant-5 points	
V-5 points	Distal extremity-5 points				
VI-6 points					

\*The points for each column can be added up for individual tattoos to arrive at the estimated number of treatment sessions needed for laser removal, plus or minus 2.5



**Figure 1:** Showing good resolution of dark blue tattoo using the QS Nd:YAG laser after 5 treatment. Noticed textural changes and mild post inflammatory hyperpigmentation and silhouette of old tattoo (Photographs-courtesy of National Skin Centre, Singapore)

absorption by epidermal melanin and reduce the risk of complications.

### Patient preparation

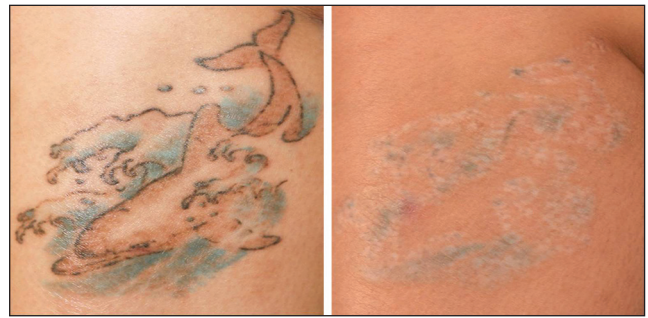
The area to be treated should be cleansed thoroughly and free from any residual cosmetics or skin care products. Avoid using potentially flammable cleansing agents such as isopropyl alcohol. As removal of tattoos can be painful for the patient, topical anesthetics such as 5% lidocaine cream (LMX-5) and 2.5% lidocaine/2.5% prilocaine (EMLA) are often applied under occlusion for 45-60 minutes. The anesthetic should be completely removed prior to treatment. Other methods of reducing discomfort for the patient include the use of cool air during treatment, local infiltration of lidocaine, regional nerve block, or a combination of these modalities.

All medical personnel must wear wavelength-specific protective goggles during the laser procedure. The patient must also be provided with protective goggles or external metal eyeshields. If the area treated is on the eyelid or near the orbit, intraocular metal eyeshields should be placed for the patient.

In darkly pigmented patients, test spots can be carried out and evaluated at 4-6 weeks for efficacy and side effects. Test spots should also be considered for cosmetic tattoos where paradoxical darkening is likely to be encountered.<sup>[6]</sup>

### Laser treatment

The desired endpoint of QS laser treatment (Nd:YAG, alexandrite, and ruby) is immediate tissue whitening, although this may not occur if the tattoo has faded significantly. Such whitening can last approximately



**Figure 2:** A multicolored tattoo treated with multiple QS alexandrite laser. Note persistence of pigment and hypopigmentation which is a complication of multiple treatment in skin of color (Photographs-courtesy of National Skin Centre, Singapore)

20 minutes, and is a result of rapid heating of the chromophore leading to gas formation.<sup>[16]</sup> The optimal fluence is the lowest possible setting that elicits this endpoint in order to minimize the risk of thermal injury, such as blister formation and scarring. A low starting fluence should be used to attain this desired endpoint during initial tattoo treatment especially when the tattoo pigment density is very dark [Figure 3]. The fluence can be increased as the tattoo becomes lighter. Different wavelengths of laser can be used, depending on the tattoo color treated, previous response to laser treatment, and also skin phototype of the patient. Laser spots (3-4 mm spot sizes are used usually) are applied with approximately 10-20% overlap, aiming for immediate whitening, and minimizing pinpoint bleeding. Laser treatments can be repeated approximately every 8 weeks.

Generally, black and dark blue pigment respond best to Nd:YAG and alexandrite lasers. QS ruby laser tends to be associated with hypopigmentation in dark skin individuals. Colored pigments are generally less responsive to treatment Figure 4. Green pigment may respond to the alexandrite lasers but is recalcitrant to Nd:YAG lasers [Figure 5].

### Post-treatment concerns

Patients should be appropriately advised to look after the treated area post-tattoo removal. Immediately after treatment, patients should expect the treated area to become red and swollen. Cold compresses can be used to minimise any discomfort. Antibiotic ointment or simple ointment-based emollients can be applied for 10-14 days after. Patients should be counseled that blisters and crusting might occur. If large blisters occur, these can be pricked with a sterile needle and dressed. Possible longer-term adverse effects such as scarring, hyper- or hypopigmentation [Figure 3], and color change of tattoo pigment should also be discussed with patients.



### Types of lasers

The QS ruby laser (694 nm) was the first commercially available QS laser for tattoo removal in 1983,<sup>[17]</sup> followed by the QS Nd:YAG laser (532 nm, 1064 nm) and the QS alexandrite laser (755 nm). These are all still used today in dermatology practices. The tattoo color and patient skin type should be taken into consideration when choosing the appropriate laser for tattoo removal. A summary of the different lasers used for treating different tattoo colors are shown in Table 2.

### Blue or black tattoos

Darkly pigmented black or blue tattoos can be effectively treated by QS ruby, QS Nd:YAG (1064 nm) [Figure 1] or QS alexandrite laser.<sup>[18,19]</sup> Leuenberger *et al.* compared the three different lasers and found that QS ruby laser showed more significant tattoo clearing after 4-6 treatments compared to the QS Nd:YAG and QS alexandrite lasers. The authors attributed it to the use of a larger spot size in the QS ruby laser, which would afford greater depth of thermal injury to the targeted chromophore. The smaller spot sizes used in the QS Nd:YAG and QS alexandrite lasers may have led to more scatter and more rapid decrease in fluence, and, hence, less effectiveness. Treatment with QS ruby laser however resulted in the highest incidence of hypopigmentation (38% for ruby, 0% for Nd:YAG and 2% for alexandrite respectively). This is due to increased absorption by epidermal melanin at this shorter wavelength, and their resultant destruction. Treatment with the longer 1064 nm wavelength results in minimal absorption by epidermal melanin and allows light to penetrate greater than 2mm in the skin, making it ideal for the treatment of dermal chromophores such as tattoo pigments.<sup>[18]</sup> In darker skin types where there is heavy epidermal melanin content, QS Nd:YAG laser is the laser of choice to reduce the risks of post-inflammatory hyper- and hypopigmentation post tattoo removal.<sup>[20]</sup> The importance of a homogenous beam profile and large spot size in attaining better tattoo removal was further highlighted in another study by Karsai *et al.*<sup>[21]</sup>

Jones *et al.* carried out a study on eight skin type VI patients with 15 amateur tattoos treated with the 1064 nm QS Nd:YAG laser at 8 week intervals. After an average of 3-4 treatments, 8 of the 15 tattoos were rated as 75-95% cleared and 5 tattoos rated 50% cleared. Only 2 of the tattoos were associated with slight lightening of the skin. None of the other tattoos had any pigmentary or textural changes.<sup>[22]</sup>

Table 2: Tattoo pigment response to different laser wavelengths (tick indicate positive response)

QS Laser	Black	Blue	Green	Red	Orange	Purple
Ruby 694 nm	✓	✓	✓			✓
Alexandrite 755 nm	✓	✓	✓			
Nd:YAG 1064 nm	✓	✓				
Nd:YAG 532 nm				✓	✓	

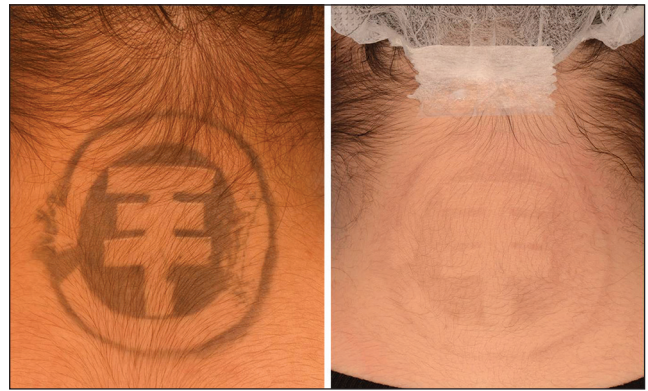

Figure 3: Black amateur tattoo on nape of neck before and after 2 treatments with 1064 nm QS Nd:YAG laser (Photographs courtesy of National Skin Centre, Singapore)

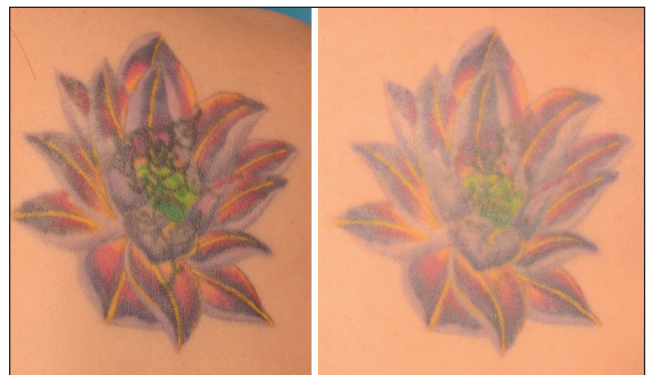

Figure 4: Difficult to treat multi-colored tattoo on the back, before and after 4 treatments with 755 nm QS Alexandrite laser (Photographs courtesy of National Skin Centre, Singapore)

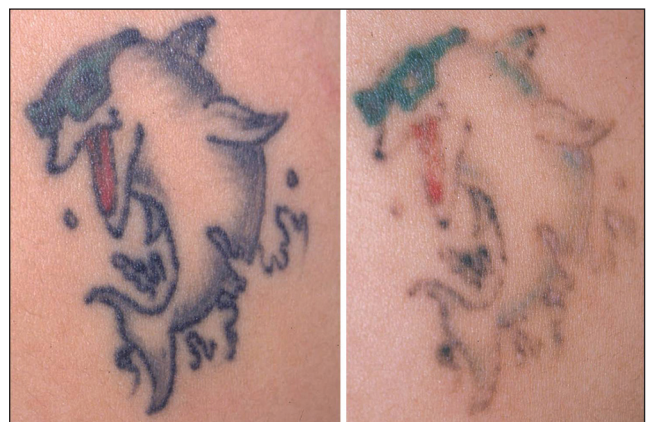

Figure 5: Show multicolored tattoo partially removed with the QS Nd:YAG laser. Note persistence of green pigment which are generally unresponsive to Nd:YAG laser. (Photograph courtesy of National Skin Centre, Singapore)

Lapidoth *et al.* treated 404 Ethiopian patients (skin types V and VI) with blue/black tattoos with the 1064 nm QS Nd:YAG (380 patients) or QS ruby laser (24 patients), and reported a clearance of 75-100% in 92% of patients after 3-6 laser treatments (average 3.6) at intervals of at

least 8 weeks. Most of these tattoos were carbon-based and located on the face or neck. Mild hyperpigmentation [Figure 1] lasting 2-4 months was noted in 44% of patients, and mild textural changes in 2 patients. There were no cases of scarring or permanent pigmentary changes.<sup>[23]</sup>

QS alexandrite laser has also been found to be safe and effective for tattoo removal in darker skin types. Burkhari *et al.* treated 20 Arabic women with skin type III-IV and achieved more than 95% lightening in 5 patients, and more than 75% lightening in 10 patients. These patients were given 3-6 treatments at 6-12 week intervals. Pinpoint bleeding was observed in one case but no pigmentary alteration or scarring was seen.<sup>[24]</sup>

### Red tattoos

The light emitted from the 1064nm QS Nd:YAG laser may be doubled in frequency to produce light with a wavelength of 532 nm. Red, orange, and red-brown pigments respond well to this wavelength.<sup>[19,25]</sup> Studies comparing the QS 532 nm Nd:YAG have also found it to be superior to the QS ruby and QS 1064 nm Nd:YAG in the removal of red colors in professional tattoos.<sup>[26,27]</sup>

### Green tattoos

Both the QS alexandrite and QS ruby laser are effective for the treatment of green tattoos, although the QS alexandrite laser is considered the modality of choice.<sup>[19,25]</sup> QS alexandrite can therefore be used effectively for the treatment of black, blue or green tattoos [Figure 2]. In addition to black, blue, and green tattoos, QS Ruby also works well for purple and violet pigments.<sup>[19]</sup>

### Light colored tattoos

Cosmetic tattoos or pale-colored tattoos can be more difficult to treat as they often contain red, brown, flesh-colored, and white inks containing iron oxides and titanium dioxide, which may irreversibly turn black after QS laser irradiation.<sup>[28]</sup> Chemical reduction of ferric to ferrous oxide is thought to be responsible for such phenomenon. Such paradoxical darkening has been successfully treated with further QS laser treatments, sometimes requiring up to 20 sessions.<sup>[29,30]</sup> Ablative laser resurfacing with pulsed CO<sub>2</sub> and erbium-doped YAG lasers have also been successfully used in cosmetic tattoos.<sup>[31,32]</sup>

## NEW STRATEGIES IN TATTOO REMOVAL

### Combination laser treatment

Non-ablative or ablative fractional resurfacing has been reported to be effective for tattoo removal, either when combined with QS ruby laser treatment or as monotherapy.<sup>[33,34]</sup> It appears to enhance pigment clearance, prevent blistering, shorten recovery and diminish treatment-induced hypopigmentation.<sup>[33]</sup> It has

also been reported to be effective for the treatment of traumatic, allergic, and multicolored tattoos.<sup>[34,35]</sup> Animal models with cosmetic tattoos treated with non-ablative and ablative fractional lasers have demonstrated tattoo pigments in the microscopic coagulation zones migrating to the epidermis and becoming part of the microscopic exudative necrotic debris that can be exfoliated after 5 days.<sup>[36,37]</sup> Such fractional resurfacing can be combined with the traditional QS lasers for a synergistic effect.

### Multi-pass treatments

The use of multi-pass treatments to reduce the number of treatment sessions has been explored. Kossida *et al.* first described the R20 method of tattoo removal, where accelerated lightening can be achieved by using four laser passes in one treatment session, with an interval of 20 min between the passes.<sup>[38]</sup> The 20 minutes waiting time allows for the post-laser immediate whitening to resolve completely before a second pass is given. The authors hypothesize that such repeated passes allow for treatment of pigment in successively deeper layers of the dermis. One patient developed transient hypopigmentation. Reddy *et al.* then demonstrated that application of topical perfluorodecalin prior to QS laser treatment allows for immediate treatment of the tattoo with repeated passes, thereby improving results while decreasing overall treatment time (R0 method).<sup>[39]</sup> Topical perfluorodecalin is a highly gas soluble liquid fluorocarbon that can resolve the whitening reaction within seconds. These studies reported superior tattoo clearance with both the R20 and R0 methods, compared to traditional single pass laser treatment.

### Picosecond lasers

Picosecond lasers, with pulse duration of 10<sup>-12</sup> seconds, are the newest lasers promising fast and efficacious tattoo removal. Ross *et al.* first compared the use of nanosecond and picosecond lasers for the treatment of black tattoos in human patients, all other parameters being equal, and reported tattoo removal to be more effective with the picosecond pulse duration. As the common tattoo pigment is around 40nm in diameter, with thermal relaxation times of around 1 ns, the shorter picosecond pulse duration can better target the tattoo pigment with increased photomechanical breakup of the pigment.<sup>[40]</sup> These findings were further supported by Izikson *et al.*, who also found the picosecond laser was able to deliver better results than the QS alexandrite laser during tattoo removal in a pig study.<sup>[41]</sup>

The first commercially available picosecond laser was launched in 2013 and recently published studies have confirmed its efficacy. Saedi *et al.* reported 12 patients with darkly pigmented tattoos who completed treatment with the 755 nm picosecond alexandrite laser obtaining greater than 75% clearance. 9 of the patients obtained



75% clearance after just 2 to 4 treatments.<sup>[42]</sup> Brauer *et al.* also reported rapid and successful treatment with the picosecond alexandrite laser for multicolored or recalcitrant tattoos. 75% clearance of 12 blue or green tattoos was obtained after 1 or 2 treatments, with more than two thirds of these tattoos approaching 100% clearance.<sup>[43]</sup>

A recently presented, but unpublished, study by Tanghetti demonstrated significant tattoo clearing in 17 patients using the picosecond 755 nm alexandrite laser at fluences in the 1.3-2.0 J/cm<sup>2</sup> range. Gradual dose escalation of fluence based on previous responses, skin type, tanning, and melanin index increased safety by minimizing downtime and blistering. They noted that blue and green inks are often eliminated in one treatment.<sup>[44]</sup> Kilmer and Custis treated 26 tattoos with a picosecond laser, treating each half with R20 or single pass treatment. After one session, the multi-pass R20 method showed a 3.4 fold improvement from baseline, compared to 2.1 fold improvement with the single pass treatment. They concluded that the R20 method may further improve the efficacy of the new picosecond laser technology.<sup>[45]</sup>

### Microencapsulated tattoo ink

Kitzman previously presented his unpublished data on microencapsulated tattoo ink. Such designer inks are made by microencapsulation of water soluble dye in polymethylmethacrylate beads. Removal can then be accomplished by targeting the encapsulating shell instead of more extensive disruption of the entire pigment particle. Preclinical studies in hairless rats and guinea pigs showed significantly increased ease of removal. One laser treatment effectively removed 80% of tattoo intensity, while only 20% of conventional ink was removed in a single identical laser treatment.<sup>[46]</sup> Further studies are needed to establish the safety and efficacy of such microencapsulated tattoo inks in human clinical studies.

### SUMMARY

As the trend for tattoo acquisition increases, the demand for tattoo removal will similarly rise. The QS ruby, alexandrite and Nd:YAG lasers are established technologies against blue, black, red and green tattoos, with varying degrees of effectiveness. Other colors can be challenging to treat, although outcomes using fractional resurfacing and picosecond lasers are promising. Multi-pass treatments and picosecond technology are new strategies for faster and more effective removal of tattoo pigments. Better regulation of tattoo inks and pigments can help ensure safe application and ease of removal, but it is currently lacking.

### REFERENCES

1. Laumann AE, Derick AJ. Tattoos and body piercings in the United States: A national data set. *J Am Acad Dermatol* 2006;55:413-21.
2. One in five US adults now has a tattoo. Harris Interactive Website. Available from: <http://www.harrisinteractive.com/NewsRoom/HarrisPolls/tabid/447/ctl/ReadCustom%20Default/mid/1508/ArticleId/970/Default.aspx>. [Last accessed on 2014 Aug 15].
3. Unwanted tattoos. ASDS website. Available from: <https://www.asds.net/TattooRemovalInformation.aspx>. [Last accessed on 2014 Aug 15].
4. Armstrong ML, Roberts AE, Koch JR, Saunders JC, Owen DC, Anderson RR. Motivation for contemporary tattoo removal: A shift in identity. *Arch Dermatol* 2008;144:879-84.
5. Alster SA. Q-switched alexandrite laser treatment (755 nm) of professional and amateur tattoos. *J Am Acad Dermatol* 1995;33:69-73.
6. Ortiz AE, Alster TS. Rising concern over cosmetic tattoos. *Dermatol Surg* 2012;38:424-9.
7. Moreno-Arias GA, Casals-Andreu M, Camps-Fresneda A. Use of Q-switched alexandrite laser (755 nm, 100 nsec) for removal of traumatic tattoo of different origins. *Lasers Surg Med* 1999;25:445-50.
8. Kluger N, Aldasouqi S. A new purpose for tattoos: Medical alert tattoos. *Presse Med* 2013;42:134-7.
9. McDowell F. Plastic surgery: Removal of commercial tattoos of the skin. *West J Med* 1976;125:143.
10. Dvir E, Hirshowitz B. Tattoo removal by cryosurgery. *Plast Reconstr Surg* 1980;66:373-9.
11. Groot DW, Arlette JP, Johnston PA. Comparison of the infrared coagulator and the carbon dioxide laser in the removal of decorative tattoos. *J Am Acad Dermatol* 1986;15:518-22.
12. Anderson R, Parrish J. Selective photothermolysis: Precise microsurgery by selective absorption of pulsed radiation. *Science* 1983;220:524-7.
13. Taylor CR, Anderson RR, Gange RW, Michaud NA, Flotte TJ. Light and electron microscopic analysis of tattoos by Q-switched ruby laser. *J Invest Dermatol* 1991;97:131-6.
14. Kirby W, Desai A, Desai T, Kartono F, Geeta P. The Kirby-Desai scale: A proposed scale to assess tattoo-removal treatments. *J Clin Aesthet Dermatol* 2009;2:32-7.
15. Klein A, Rittmann I, Hiller KA, Landthaler M, Bäuml W. An internet-based survey on characteristics of laser tattoo removal and associated side effects. *Lasers Med Sci* 2014;29:729-38.
16. Taylor CR, Gange RW, Dover JS, Flotte TJ, Gonzalez E, Michaud N, *et al.* Treatment of tattoos by Q-switched ruby laser. A dose-response study. *Arch Dermatol* 1990;126:893-9.
17. Reid WH, McLeod PJ, Ritchie A, Ferguson-Pell M. Q-switched Ruby laser treatment of black tattoos. *Br J Plast Surg* 1983;36:455-9.
18. Leuenberger ML, Mulas MW, Hata TR, Goldman MP, Fitzpatrick RE, Grevelink JM. Comparison of the Q-switched alexandrite, Nd:YAG, and ruby laser in treating blue-black tattoos. *Dermatol Surg* 1999;25:10-4.
19. Zelickson BD, Mehregan DA, Zarrin AA, Coles C, Hartwig P, Olson S, *et al.* Clinical, histologic, and ultrastructural evaluation of tattoos treated with three laser systems. *Lasers Surg Med* 1994;15:364-72.
20. Jones A, Roddey P, Orengo I, Rosen T. The Q-switched Nd:YAG laser effectively treats tattoos in darkly pigmented skin. *Dermatol Surg* 1996;22:999-1001.
21. Karsai S, Pffirmann G, Hammes S, Raulin C. Treatment of resistant tattoos using a new generation Q-switched Nd:YAG laser: Influence of beam profile and spot size on clearance success. *Lasers Surg Med* 2008;40:139-45.
22. Jones A, Roddey P, Orengo I, Rosen T. The Q-switched Nd:YAG laser effectively treats tattoos in darkly pigmented skin. *Dermatol Surg* 1996;22:999-1001.
23. Lapidoth M, Aharonowitz G. Tattoo removal among Ethiopian Jews in Israel: Tradition faces technology. *J Am Acad Dermatol* 2004;51:906-9.

24. Bukhari IA. Removal of amateur blue-black tattoos in Arabic women of skin type (III-IV) with Q-switched alexandrite laser. *J Cosmet Dermatol* 2005;4:107-10.
25. Guedes R, Leite L. Removal of orange eyebrow tattoo in a single session with the Q-switched Nd:YAG 532-nm laser. *Lasers Med Sci* 2010;25:465-6.
26. Levine VJ, Geronemus RG. Tattoo removal with the Q-switched ruby laser and the Q-switched Nd:YAG laser: A comparative study. *Cutis* 1995;55:291-6.
27. Ferguson JE, August PJ. Evaluation of the Nd:YAG laser for treatment of amateur and professional tattoos. *Br J Dermatol* 1996;135:586-91.
28. Anderson RR, Geronemus R, Kilmer SL, Farinelli W, Fitzpatrick RE. Cosmetic tattoo ink darkening. A complication of Q-switched and pulsed-laser treatment. *Arch Dermatol* 1993;129:1010-4.
29. Fitzpatrick RE, Lupton JR. Successful treatment of treatment-resistant laser-induced pigment darkening of a cosmetic tattoo. *Lasers Surg Med* 2000;27:358-61.
30. Kirby W, Kaur RR, Desai A. Paradoxical darkening and removal of pink tattoo ink. *J Cosmet Dermatol* 2010;9:149-51.
31. Mafong EA, Kauvar AN, Geronemus RG. Surgical pearl: Removal of cosmetic lip-liner tattoo with the pulsed carbon dioxide laser. *J Am Acad Dermatol* 2003;48:271-2.
32. Wang CC, Huang CL, Yang AH, Chen CK, Lee SC, Leu FJ. Comparison of two Q-switched lasers and a short-pulse erbium-doped yttrium aluminum garnet laser for treatment of cosmetic tattoos containing titanium and iron in an animal model. *Dermatol Surg* 2010;36:1656-63.
33. Weiss ET, Geronemus RG. Combining fractional resurfacing and Q-switched ruby laser for tattoo removal. *Dermatol Surg* 2011;37:97-9.
34. Seitz AT, Grunewald S, Wagner JA, Simon JC, Paasch U. Fractional CO<sub>2</sub> laser are as effective as Q-switched-ruby-laser for the initial treatment of a traumatic tattoo. *J Cosmet Laser Ther* 2014;16:303-5.
35. Ibrahim OA, Syed Z, Sakamoto FH, Avram MM, Anderson RR. Treatment of tattoo allergy with ablative fractional resurfacing: A novel paradigm for tattoo removal. *J Am Acad Dermatol* 2011;64:1111-4.
36. Wang CC, Huang CL, Lee SC, Sue YM, Leu FJ. Treatment of cosmetic tattoos with nonablative fractional laser in an animal model: A novel method with histopathologic evidence. *Lasers Surg Med* 2013;45:116-22.
37. Wang CC, Huang CL, Sue YM, Lee SC, Leu FJ. Treatment of cosmetic tattoos using carbon dioxide ablative fractional resurfacing in an animal model: A novel method confirmed histopathologically. *Dermatol Surg* 2013;39:571-7.
38. Kossida T, Rigopoulos D, Katsambas A, Anderson RR. Optimal tattoo removal in a single laser session based on the method of repeated exposures. *J Am Acad Dermatol* 2012;66:271-7.
39. Reddy KK, Brauer JA, Anolik R, Bernstein L, Brightman L, Hale E, *et al.* Topical perfluorodecalin resolves immediate whitening reactions and allows rapid effective multiple pass treatment of tattoos. *Lasers Surg Med* 2013;45:76-80.
40. Ross V, Naseef G, Lin G, Kelly M, Michaud N, Flotte TJ, *et al.* Comparison of responses of tattoos to picosecond and nanosecond Q-switched neodymium: YAG lasers. *Arch Dermatol* 1998;134:167-71.
41. Izikson L, Farinelli W, Sakamoto F, Tannous Z, Anderson RR. Safety and effectiveness of black tattoo clearance in a pig model after a single treatment with a novel 758 nm 500 picosecond laser: A pilot study. *Lasers Surg Med* 2010;42:640-6.
42. Saedi N, Metelitsa A, Petrell K, Arndt KA, Dover JS. Treatment of tattoos with a picosecond alexandrite laser: A prospective trial. *Arch Dermatol* 2012;148:1360-3.
43. Brauer JA, Reddy KK, Anolik R, Weiss ET, Karen JK, Hale EK, *et al.* Successful and rapid treatment of blue and green tattoo pigment with a novel picosecond laser. *Arch Dermatol* 2012;148:820-3.
44. Tanghetti EA, Tanghetti M. Dose optimization with a picosecond 755 nm alexandrite laser for tattoo removal. 34<sup>th</sup> American Society for Laser Medicine and Surgery (ASLMS) annual conference. Phoenix Arizona, 2014.
45. Kilmer S, Custis T. Single vs repeat exposure tattoo removal during single sessions with picosecond pulse duration laser technology. 34<sup>th</sup> American Society for Laser Medicine and Surgery (ASLMS) annual conference. Phoenix Arizona, 2014.
46. Klitzman B. Development of permanent but removable tattoos. First international conference on tattoo safety. BfR-Symposium. Berlin. 2013. p. 23.

**How to cite this article:** Ho SG, Goh CL. Laser tattoo removal: A clinical update. *J Cutan Aesthet Surg* 2015;8:9-15.

**Source of Support:** Nil. **Conflict of Interest:** None declared.