

Laboratory Investigation

Correlation of the Beta-Trace Protein and Inflammatory Cytokines with Magnetic Resonance Imaging in Chronic Subdural Hematomas : A Prospective Study

Ki-Su Park, M.D., Seong-Hyun Park, M.D., Sung-Kyoo Hwang, M.D., Chaekyung Kim, M.S., Jeong-Hyun Hwang, M.D.

Department of Neurosurgery, Kyungpook National University School of Medicine, Daegu, Korea

Objective : Magnetic resonance imaging (MRI) of chronic subdural hematoma (CSDH) detects various patterns, which can be attributed to many factors. The purpose of this study was to measure the level of interleukin-6 (IL-6), interleukin-8 (IL-8), and highly specific protein [beta-trace protein (β TP)] for cerebrospinal fluid (CSF) in CSDHs, and correlate the levels of these markers with the MRI findings.

Methods : Thirty one patients, treated surgically for CSDH, were divided on the basis of MRI findings into hyperintense and non-hyperintense groups. The concentrations of IL-6, IL-8, and β TP in the subdural fluid and serum were measured. The β TP was considered to indicate an admixture of CSF to the subdural fluid if β TP in the subdural fluid (β TP_{SF})/ β TP in the serum (β TP_{SER}) >2.

Results : The mean concentrations of IL-6 and IL-8 of the hyperintense group (n=17) of T1-WI MRI were 3975.1±1040.8 pg/mL and 6873.2±6365.4 pg/mL, whereas them of the non-hyperintense group (n=14) were 2173.5±1042.1 pg/mL and 2851.2±6267.5 pg/mL ($p<0.001$ and $p=0.004$). The mean concentrations of β TP_{SF} and the ratio of β TP_{SF}/ β TP_{SER} of the hyperintense group (n=13) of T2-WI MRI were 7.3±2.9 mg/L and 12.6±5.4, whereas them of the non-hyperintense group (n=18) were 4.3±2.3 mg/L and 7.5±3.9 ($p=0.011$ and $p=0.011$).

Conclusion : The hyperintense group on T1-WI MRI of CSDHs exhibited higher concentrations of IL-6 and IL-8 than non-hyperintense group. And, the hyperintense group on T2-WI MRI exhibited higher concentrations of β TP_{SF} and the ratio of β TP_{SF}/ β TP_{SER} than non-hyperintense group. These findings appear to be associated with rebleeding and CSF admixture in the CSDHs.

Key Words : Chronic subdural hematoma · Interleukin · Beta-trace protein · Magnetic resonance imaging.

INTRODUCTION

The complex mechanism of pathogenesis for chronic subdural hematoma (CSDH) involves repetitive microhemorrhages from the neomembranes, inflammatory processes in the neomembranes, local hyperfibrinolysis, and cerebrospinal fluid (CSF) leakage into the subdural space^{6,9,15,17,22,27,30,33}. As a result, many coagulofibrinolytic factors, inflammatory cytokines, angiogenic growth factors, and highly specific proteins for CSF [beta-trace protein (β TP)] have been associated with CSDHs^{5,10,12,17,25,34}, and some studies have suggested that various types of CSDHs, as observed on CT, are associated with coagulofibrinolytic factors, inflammatory cytokines, and angiogenic growth factors^{5,12,19,23-26}.

MRI of CSDHs provides more precise information about the localization, extent, and mass effect of a hematoma on adjacent structures. And, MRI findings of CSDHs are attributed to many

factors including the age of the hematoma, the presences of rehemorrhage, and the hematocrit status in CSDHs¹¹). However, there have been no reports to date on correlations between MRI findings and biomolecules in the CSDH.

The purpose of this study was to measure the levels of interleukin-6 (IL-6) and interleukin-8 (IL-8), as typical inflammatory cytokines in patients with a CSDH and correlate these markers with MRI signal intensity. In addition, we measured the concentration of β TP in the subdural hematoma and investigated whether CSF admixture to the CSDHs influenced MRI findings.

MATERIALS AND METHODS

Patient selection

Between January and December 2013, 48 consecutive patients had been admitted to our institute for surgical manage-

• Received : November 12, 2014 • Revised : January 6, 2015 • Accepted : February 13, 2015

• Address for reprints : Jeong-Hyun Hwang, M.D.

Department of Neurosurgery, Kyungpook National University Hospital, 130 Dongdeok-ro, Jung-gu, Daegu 700-721, Korea
Tel : +82-53-200-5647, Fax : +82-53-423-0504, E-mail : jhwang@knu.ac.kr

• This is an Open Access article distributed under the terms of the Creative Commons Attribution Non-Commercial License (<http://creativecommons.org/licenses/by-nc/3.0>) which permits unrestricted non-commercial use, distribution, and reproduction in any medium, provided the original work is properly cited.

ment of CSDH. Of these, 17 patients with the following risk factors were excluded from this study : long-term use of thrombolytics, anticoagulants, or anti-inflammatroy therapy or hemodialysis (n=12); concomitant infection, inflammatory, hematological or neoplastic disorders, liver dysfunction, dementia, coagulopathy, or diabetes mellitus (n=2); presence of a ventriculoperitoneal shunt for hydrocephalus (n=3). The remaining 31 patients were enrolled in this prospective study and provided written informed consent to participate in the study.

Radiological imaging

Imaging was performed on high spiral CT systems and on 1.5 Tesla MR scanners before burr hole drainage. On the basis of CT scanning, the CSDHs were classified into 2 groups, a homogenous group and a heterogenous group, according to the classification system suggested by Park et al.²⁵⁾ (Fig. 1). MRI of the CSDHs was classified into 4 groups, according to signal intensity suggested by Senturk et al.²⁹⁾ : low, iso, high signal, and mixed intensity. Then we subdivided the four groups into two different groups : a hyperintense group and a non-hyperintense

group (Fig. 2).

Measurement of IL-6 and IL-8 by ELISA

Samples of the subdural hematoma and venous blood were obtained at burr hole drainage. The subdural hematoma sample was obtained through the dura mater with a disposable plastic syringe via a burr hole before the dural incision. Peripheral venous blood samples were also taken from the patients. All samples were collected into siliconized vaccum tubes containing protamine sulfate and ethylenediamine tetraacetic acid and were immediately centrifuged at 2500 to 3000 rpm for 10 minutes. The supernatants were stored in sealed polypropylene tubes at -70°C until analysis. Concentrations of IL-6 and IL-8 in the subdural fluid and venous blood were measured with an ELISA kit (R&D System Co, Minneapolis, MN, USA; dilution 1 : 100) using monoclonal antibodies.

Measurement of β TP

The β TP is a marker highly specific for CSF, and more than 99% of the β TP is produced by the choroid plexus in the central nervous system, and is obtained in the CSF. The β TP concentration in CSF is 32 to 35 times higher than the β TP concentration in the serum (β TP_{SER})^{1,28)}. Samples of subdural fluid with a β TP concentration in the subdural fluid (β TP_{SF}) at least twice as high as the β TP_{SER} (β TP_{SF}/ β TP_{SER}>2, corresponding to a rate of at least 5% CSF in the subdural fluid) were considered indicative of the presence of CSF in the subdural fluid. If the ratio of β TP_{SF}/ β TP_{SER} in the subdural fluid was <2, a CSF admixture to the subdural fluid was not considered to be present¹³⁾. In addition, the concentration of β TP reflected the amount of CSF present in the CSDH¹⁷⁾.

Levels of β TP in the subdural fluid and serum were measured with an ELISA kit [Cayman Chemical, Ann Arbor, MI, USA, dilution 1 : 100 (subdural flu-

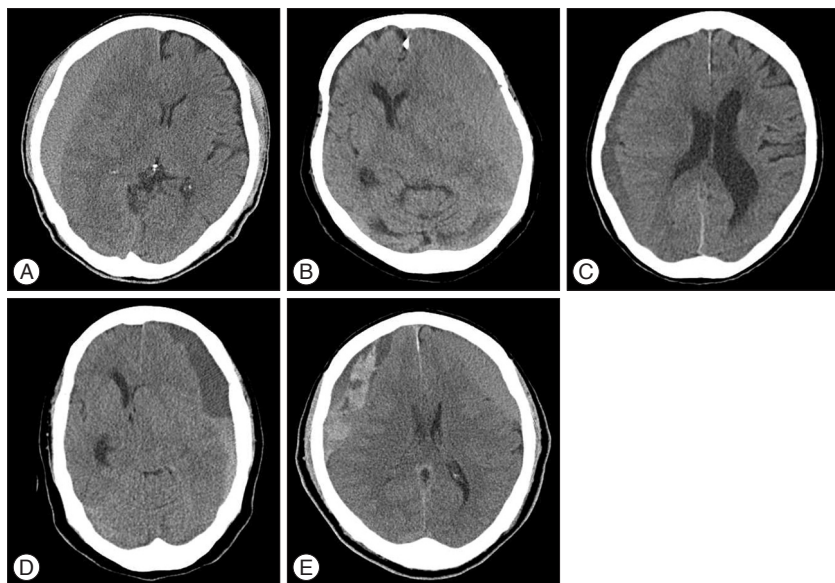


Fig. 1. Axial computed tomography scans revealing a homogenous group, with high density (A), isodensity (B), and low density types (C) and a heterogenous group, with the layering (D) and mixed density types (E).

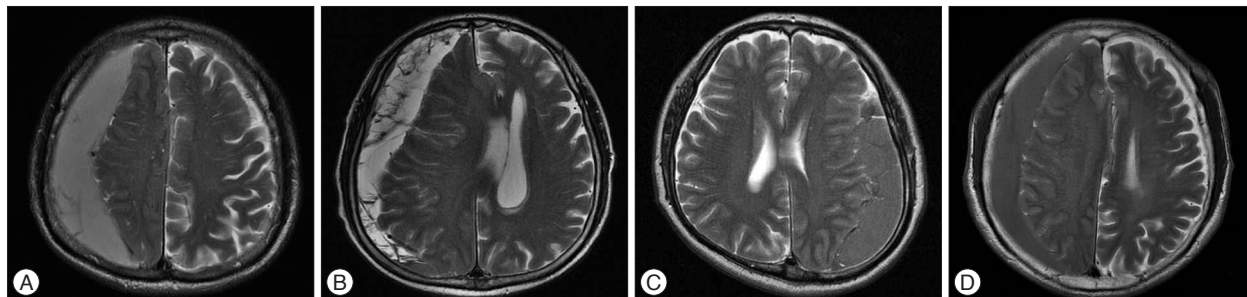


Fig. 2. Axial T2-weighted magnetic resonance imaging showing a hyperintense group, with homogenous (A) and mixed types (B) and a non-hyperintense group, with isointense (C) and hypointense types (D).

id), 1 : 10 (serum)] using monoclonal antibodies.

Statistical analysis

The levels of IL-6, IL-8, and β TP in the CSDHs were compared between two groups on CT and MRI, respectively. Statistical analysis was performed using the chi-square test and Mann-Whitney test. Data are presented as the mean \pm standard deviation. All analyses were performed using SPSS 14.0 for Windows (SPSS Inc., Chicago, IL, USA). A p -value $<$ 0.05 was accepted as the threshold for statistical significance.

RESULTS

Clinical and radiological data

Thirty one patients were enrolled in the study and their main characteristics are summarized in Table 1. There were 23 men

and 8 women, with ages ranging from 38 to 86 (average, 67.6 years). Head trauma during the week preceding admission was reported by 24 (77%) patients. The time interval between head injury and operation date ranged from 19 to 64 days (average, 40.3 days). All of the CSDH cases underwent burr hole drainage. The removal of the subdural hematomas resulted in a good recovery in all cases. Three (9.7%) patients underwent re-operation on the same side due to the recurrence of the CSDH. There were no statistically significant differences between a hyperintense group and a non-hyperintense group in terms of demographic characteristics, history of head injury, the time interval between trauma and operation, and recurrence.

The distribution of hematomas according to their CT and MRI characteristics is shown in Table 1 and 2. CT and MRI showed bilaterality of CSDH in 3 patients (9.6%), and mean CSDH thickness ranged from 8 mm to 36 mm (average, 20.9

Table 1. Patients' characteristics and radiologic findings

Case No.	Age/sex	History of trauma	Days from trauma	Recurrence	Thickness (mm)	Bilateral CSDH	MRI intensity		CT density
							T1-WI	T2-WI	
1	75/M	Yes	38	No	36	No	High	Low	Homogenous
2	58/M	Yes	64	No	29	No	High	Low	Heterogenous
3	80/F	No	None	No	35	No	High	Low	Heterogenous
4	40/M	Yes	45	No	13	No	High	High	Homogenous
5	66/M	Yes	40	No	18	No	Low	Low	Homogenous
6	58/F	No	None	Yes	20	No	Low	High	Heterogenous
7	62/F	Yes	58	No	22	No	Low	High	Heterogenous
8	59/M	Yes	30	No	20	No	High	Low	Heterogenous
9	68/M	No	None	No	21	No	High	High	Heterogenous
10	74/M	Yes	30	No	22	No	Low	Low	Homogenous
11	73/M	Yes	25	No	16	No	High	High	Heterogenous
12	74/M	Yes	37	No	15	No	High	High	Heterogenous
13	50/M	Yes	62	No	23	No	High	Low	Heterogenous
14	80/F	No	None	No	33	No	High	Low	Heterogenous
15	77/M	Yes	32	No	20	No	High	Low	Homogenous
16	80/M	Yes	19	No	18	Yes	High	Low	Heterogenous
17	82/F	Yes	21	No	31	No	Iso	Low	Homogenous
18	86/M	Yes	30	No	10	No	High	High	Heterogenous
19	71/M	No	None	No	19	No	Low	High	Homogenous
20	38/M	Yes	60	No	17	No	Iso	High	Homogenous
21	76/M	No	None	No	24	No	High	Low	Heterogenous
22	72/M	Yes	32	No	20	No	High	High	Homogenous
23	74/F	Yes	30	No	21	No	High	Low	Heterogenous
24	72/M	Yes	42	No	20	No	Low	Low	Heterogenous
25	72/F	No	None	No	19	No	Iso	Low	Heterogenous
26	80/F	Yes	45	No	8	No	Low	High	Homogenous
27	57/M	Yes	64	No	9	Yes	Iso	Low	Homogenous
28	57/M	Yes	44	No	27	No	Iso	High	Homogenous
29	64/M	Yes	57	No	26	No	High	Iso	Heterogenous
30	71/M	Yes	30	Yes	22	No	Low	Low	Homogenous
31	73/M	Yes	31	Yes	13	Yes	Low	High	Heterogenous

M : male, F : female, CSDH : chronic subdural hematoma, MRI : magnetic resonance imaging, WI : weighted image, CT : computed tomography

Table 2. Distributions of hematomas according to characteristics of CT density and MRI intensity

CT	T1-WI MRI		T2-WI MRI	
	Hyperintense	Non-hyperintense	Hyperintense	Non-hyperintense
Homogenous (13)	4	9	6	7
Heterogenous (18)	13	5	7	11

CT : computed tomography, WI : weighted image, MRI : magnetic resonance imaging

mm). Thirteen hematomas (42%) were homogenous and 18 (58%) were heterogenous on CT scans. According to the MRI, 17 (55%) of hematomas were hyperintense on T1-weighted image and 14 hematomas (45%) were hyperintense on T2-WI. There was no statistically significant difference between a hyperintense group and a non-hyperintense group in terms of bilaterality and thickness of CSDH, and no correlation between MRI and CT.

Laboratory findings

All concentrations of IL-6, IL-8, and β TP from the CSDHs were higher than in the peripheral venous blood. The ratio of β TP_{SF}/ β TP_{SER} was >2 in 100% of the patients with a CSDH. We compared the concentrations and ratio between the groups for CT and MRI, respectively (Table 3).

In the T1-WI MRI, the mean concentrations of IL-6 and IL-8 for the hyperintense group (n=18) were 3975.1±1040.8 pg/mL and 6873.2±6365.4 pg/mL, respectively, whereas those for the non-hyperintense group (n=13) were 2173.5±1042.1 pg/mL and 2851.2±6267.5 pg/mL. For T1-WI MRI, the mean concentrations of IL-6 and IL-8 for the hyperintense group were significantly higher than the non-hyperintense group, respectively ($p<0.001$ and $p=0.004$).

For T2-WI MRI, the mean concentrations of β TP_{SF} and the ratio of β TP_{SF}/ β TP_{SER} for the hyperintense group (n=13) were 7.3±2.9 mg/L and 12.6±5.4, whereas those for the non-hyperintense group (n=18) were 4.3±2.3 mg/L and 7.5±3.9. In T2-WI MRI, the mean concentration of β TP_{SF} and the ratio of β TP_{SF}/ β TP_{SER} for the hyperintense group were significantly higher than the non-hyperintense group, respectively ($p=0.011$ and $p=0.011$).

In the CT scan, the concentration of IL-6 in the heterogenous group (3680.6±1238.6 pg/mL) was significantly higher than the homogenous group (2697.2±1355.9 pg/mL) ($p=0.035$). However, there were no significant differences between mean concentrations of IL-8, β TP_{SF} and the ratio of β TP_{SF}/ β TP_{SER} from CSDHs observed between the two groups ($p=0.135$ and $p=0.679$).

DISCUSSION

The pathogeneses of CSDHs remain unclear. However, the inflammatory and angiogenic process of the neomembrane, along with the cycle of rebleeding, coagulation, and fibrinolysis are hypothesized to be at the center of the development and progression of CSDHs^{6,9,15,17,22,27,30,33}. As a result, many molecular markers for CSDHs have been demonstrated, and they can be classified as follows : 1) tissue plasminogen activator, plasmin-

plasmin inhibitor complex, thrombomodulin, fibrinogen and D-dimer in relation with coagulation and fibrinolytic activity^{12,19,23,25,26}; 2) IL-6, IL-8, IL-10 and tumor necrosis factor- α in relation with inflammatory process in the neomembrane^{5,10,12}; and 3) vascular endothelial growth factor, basic fibroblast growth factor and platelet-derived growth factor in relation with angiogenic activity of the neomembrane^{10,33,34}. And, Kristof et al.¹⁷ recently reported the presence of the β TP in the subdural hematoma, and suggested that CSF leakage into the subdural space is present in the vast majority of patients (94%) with CSDH, and CSF leakage could be involved in the pathogenesis of CSDH.

Some studies have suggested that there were significant differences between molecular markers according to the various types of CSDHs, as identified on CT scans. Frati et al.⁵ reported that in the trabecular and layering types of CSDHs, the concentrations of IL-6 and IL-8 were increased. Nomura et al.²³ and Park et al.²⁵ described higher fibrinogen and higher D-dimer levels in the layering and mixed density types. However, the relationship between biomolecules in CSDHs and MRI has not yet been reported, despite the more precise information this would give. In our study, we found higher levels of IL-6 and IL-8 in the T1-WI MRI hyperintense group of CSDHs and higher levels of β TP in the T2-WI MRI hyperintense group of CSDHs, and described the association between levels of these markers and findings on MRI.

CSDHs seem to present the typical features of chronic inflammatory processes. The outer membrane of a CSDH is a source of some cytokines, and IL-6 and IL-8 were demonstrated in the subdural hematoma. IL-6 increases vascular permeability through the enlargement of gaps between endothelial cells, and IL-8 contributes to the growth of immature capillaries with fibrinolytic activity^{14,21}. Frati et al.⁵ reported that the concentrations of IL-6 and IL-8 were increased in the heterogenous groups of CSDHs on CT scans, and suggested that these findings on CT may be associated with rebleeding of CSDHs.

On MRI, the hematocrit, methemoglobin and free Fe³⁺ levels are major factors causing prominent shortening in relaxation times, thus showing hyperintensity on T1-WI³. Hyperintensity on T1-WI generally represents methemoglobin, a typical component of a subacute hematoma^{7,8}. CSDHs may be slightly hypointense to isointense relative to grey matter on T1-WI. Fobben et al.⁴ postulated that these signal intensity changes result from a decrease in free methemoglobin concentration, either by dilution, absorption and/or degradation. However, the persistence of hyperintensity beyond its expected time interval, typical

Table 3. The levels of IL-6, IL-8, β TP, and the ratio of β TP_{SF}/ β TP_{SER} in chronic subdural hematoma and peripheral venous blood by classification of CT and MRI pattern

	T1-WI MRI			T2-WI MRI			CT	
	High (n=17)	Non-high (n=14)	p value	High (n=13)	Non-high (n=18)	p value	Homogenous (n=13)	Heterogenous (n=18)
IL-6								
Subdural fluid (pg/mL)	3975.1±1040.8	2173.5±1042.1	<0.001*	3285.1±1300.3	3231.0±1445.3	0.902	2697.2±1355.9	3680.6±1238.6
Serum	4.4±4.4	5.7±8.9	0.658	6.1±8.1	3.7±2.9	0.927	2.9±2.6	5.9±6.9
IL-8								
Subdural fluid (pg/mL)	6873.2±6365.4	2851.2±6267.5	0.004*	7528.6±8380.2	3495.1±4316.5	0.242	3694.2±6328.8	6264.4±5673.4
Serum	4.5±4.0	3.1±2.1	0.134	3.0±1.6	4.6±4.2	0.325	3.1±2.0	4.5±4.1
β -trace protein								
Subdural fluid (mg/L)	5.0±3.1	6.2±2.7	0.211	7.3±2.9	4.3±2.3	0.011*	5.2±2.8	5.8±3.1
Serum	0.6±0.2	0.6±0.2	0.594	0.6±0.1	0.6±0.2	0.798	0.6±0.1	0.6±0.2
β TP _{SF} / β TP _{SER} ratio	8.6±5.6	10.9±4.6	0.125	12.6±5.4	7.5±3.9	0.011*	9.0±4.3	10.0±5.9

Value represents mean±standard deviation. *Significant difference ($p < 0.05$) between groups by Mann-Whitney U test. IL : interleukin, β TP : β -trace protein, CT : computed tomography, WI : weighted image, MRI : magnetic resonance imaging, SF : subdural fluid, SER : serum

of the subacute intracranial hematoma, is a common observation, which is probably due to repeated hemorrhage²⁹). Our data showed significantly high IL-6 and IL-8 levels in CSDHs, with hyperintensity on T1-WI MRI. And, this finding is similar with the high IL-6 level in the heterogenous group on CT scans. Therefore, high IL-6 and IL-8 levels in CSDHs may be a marker for the hyperintense group on T1-WI MRI, corresponding to a likely probability of recent rebleeding.

The β TP (prostaglandin-D2-synthase) is an ideal marker to identify a CSF admixture into the subdural fluid. More than 99% of β TP is contained within the CSF, and it is synthesized mainly by the choroid plexus of the CNS, whereas a very small amount of β TP is synthesized outside the CNS, mainly in the heart and blood. The β TP concentration is 32–34 times higher in the CSF (8–40 mg/L) compared to the serum (0.3–0.76 mg/L)^{1,28}).

Kristof et al.¹⁷) suggested that β TP_{SF}/ β TP_{SER}>2 corresponded to a rate of at least 5% CSF in the subdural fluid, and that this was considered indicative of the presence of CSF in the subdural fluid. And, they reported that CSF was present in the subdural fluid in the vast majority (62 of 67 patients; 93%) of patients with CSDH, and that the concentration of β TP reflected the amount of CSF present. Although the mechanism of CSF leakage (and its component β TP) into the subdural space in CSDHs remains unknown, two hypotheses were suggested in the literature : 1) CSF (and its component β TP) enters the subdural space of CSDH through the arachnoid tear that acts as a valve^{2,18,31,32}) and 2) CSF (and its component β TP) crosses the inner membrane of the CSDH into the subdural space by diffusion/exudation^{6,20}).

In the majority of cases, a CSDH appears hyperintense on T2-WI because blood degradation products, especially methemoglobin, appear hyperintense on such images¹⁶). However, our study demonstrated that the mean concentration of β TP_{SF} and the ratio of β TP_{SF}/ β TP_{SER} in the T2-WI MRI hyperintense group were significantly higher than in the non-hyperintense group, and indicated more CSF admixture to the CSDHs in the T2-WI MRI hyperintense group. Therefore, the higher subdural concentrations of β TP and the higher ratio of β TP_{SF}/ β TP_{SER} may provide good markers for CSDHs for the hyperintense group on T2-WI MRI, and CSF admixture to the CSDHs may provide another possibility for the T2-WI MRI hyperintensity for CSDHs.

In the present study, we did not conduct a comparative study between patients with and without a recurrence, because the recurrent cases (9.7%) were fairly low. In future, a prospective study is needed to evaluate the relationship between prognostic markers and the recurrence rate based on the MRI findings.

CONCLUSION

In this paper, the subdural concentrations of IL-6 and IL-8 in CSDHs were relatively higher in the T1-WI MRI hyperintense group compared to the non-hyperintense group, and we suggested that the subdural concentrations of IL-6 and IL-8 in CS-

DHs may be a marker for the hyperintense group on T1-WI MRI, corresponding to a likely probability of recent rebleeding. Additionally, the subdural concentration of $\beta\text{TTP}_{\text{SF}}$ and the ratio of $\beta\text{TTP}_{\text{SF}}/\beta\text{TTP}_{\text{SER}}$ in CSDHs were relatively higher in the T2-WI MRI hyperintense group compared to the non-hyperintense group, and reflected more CSF admixture to the CSDH. Therefore, CSF admixture to the CSDHs may provide another possibility for the T2-WI MRI hyperintensity for CSDHs.

• **Acknowledgements**

We thank Wade Martin of Medical Research International for his critical review of this manuscript.

This work was supported by a Biomedical Research Institute grant, Kyungpook National University Hospital (2014).

References

1. Bachmann G, Peteret H, Djenabi U, Michel O : Predictive values of beta-trace protein (prostaglandin D synthase) by use of laser-nephelometry assay for the identification of cerebrospinal fluid. **Neurosurgery** 50 : 571-576; discussion 576-577, 2002
2. Baechli H, Nordmann A, Bucher HC, Gratzl O : Demographics and prevalent risk factors of chronic subdural haematoma : results of a large single-center cohort study. **Neurosurg Rev** 27 : 263-266, 2004
3. Bradley WG Jr, Schmidt PG : Effect of methemoglobin formation on the MR appearance of subarachnoid hemorrhage. **Radiology** 156 : 99-103, 1985
4. Fobben ES, Grossman RI, Atlas SW, Hackney DB, Goldberg HI, Zimmerman RA, et al. : MR characteristics of subdural hematomas and hygromas at 1.5 T. **AJR Am J Roentgenol** 153 : 589-595, 1989
5. Frati A, Salvati M, Mainiero F, Ippoliti F, Rocchi G, Raco A, et al. : Inflammation markers and risk factors for recurrence in 35 patients with a posttraumatic chronic subdural hematoma : a prospective study. **J Neurosurg** 100 : 24-32, 2004
6. Fujisawa H, Nomura S, Tsuchida E, Ito H : Serum protein exudation in chronic subdural haematomas : a mechanism for haematoma enlargement? **Acta Neurochir (Wien)** 140 : 161-165; discussion 165-166, 1998
7. Gomori JM, Grossman RI : Mechanisms responsible for the MR appearance and evolution of intracranial hemorrhage. **Radiographics** 8 : 427-440, 1988
8. Gomori JM, Grossman RI, Hackney DB, Goldberg HI, Zimmerman RA, Bilaniuk LT : Variable appearances of subacute intracranial hematomas on high-field spin-echo MR. **AJR Am J Roentgenol** 150 : 171-178, 1988
9. Hirashima Y, Endo S, Hayashi N, Karasawa K, Nojima S, Takaku A : Platelet-activating factor (PAF) and the formation of chronic subdural haematoma. Measurement of plasma PAF levels and anti-PAF immunoglobulin titers. **Acta Neurochir (Wien)** 137 : 15-18, 1995
10. Hong HJ, Kim YJ, Yi HJ, Ko Y, Oh SJ, Kim JM : Role of angiogenic growth factors and inflammatory cytokine on recurrence of chronic subdural hematoma. **Surg Neurol** 71 : 161-165; discussion 165-166, 2009
11. Hosoda K, Tamaki N, Masumura M, Matsumoto S, Maeda F : Magnetic resonance images of chronic subdural hematomas. **J Neurosurg** 67 : 677-683, 1987
12. Kitazono M, Yokota H, Satoh H, Onda H, Matsumoto G, Fuse A, et al. : Measurement of inflammatory cytokines and thrombomodulin in chronic subdural hematoma. **Neurol Med Chir (Tokyo)** 52 : 810-815, 2012
13. Kleine TO, Damm T, Althaus H : Quantification of beta-trace protein and detection of transferrin isoforms in mixtures of cerebrospinal fluid

- and blood serum as models of rhinorrhea and otorrhea diagnosis. **Fre-senius J Anal Chem** 366 : 382-386, 2000
14. Koch AE, Poverini PJ, Kunkel SL, Harlow LA, DiPietro LA, Elnor VM, et al. : Interleukin-8 as a macrophage-derived mediator of angiogenesis. **Science** 258 : 1798-1801, 1992
15. König SA, Schick U, Döhnert J, Goldammer A, Vitzthum HE : Coagulation and outcome in patients with chronic subdural haematoma. **Acta Neurol Scand** 107 : 110-116, 2003
16. Krauss JK, Weigel R : Medical and surgical management of chronic subdural hematomas in Youmans JR, Winn R (eds) : **Youmans Neurological Surgery**, ed 6. Philadelphia : Elsevier Saunders, 2011, pp535-543
17. Kristof RA, Grimm JM, Stoffel-Wagner B : Cerebrospinal fluid leakage into the subdural space : possible influence on the pathogenesis and recurrence frequency of chronic subdural hematoma and subdural hygroma. **J Neurosurg** 108 : 275-280, 2008
18. Lee KS : The pathogenesis and clinical significance of traumatic subdural hygroma. **Brain Inj** 12 : 595-603, 1998
19. Lim DJ, Chung YG, Park YK, Song JH, Lee HK, Lee KC, et al. : Relationship between tissue plasminogen activator, plasminogen activator inhibitor and CT image in chronic subdural hematoma. **J Korean Med Sci** 10 : 373-378, 1995
20. Markwalder TM : Chronic subdural hematomas : a review. **J Neurosurg** 54 : 637-645, 1981
21. Maruo N, Morita I, Shirao M, Murota S : IL-6 increases endothelial permeability in vitro. **Endocrinology** 131 : 710-714, 1992
22. Nakaguchi H, Yoshimasu N, Tanishima T : [Relationship between the natural history of chronic subdural hematoma and enhancement of the inner membrane on post-contrast CT scan]. **No Shinkei Geka** 31 : 157-164, 2003
23. Nomura S, Kashiwagi S, Fujisawa H, Ito H, Nakamura K : Characterization of local hyperfibrinolysis in chronic subdural hematomas by SDS-PAGE and immunoblot. **J Neurosurg** 81 : 910-913, 1994
24. Park HR, Lee KS, Shim JJ, Yoon SM, Bae HG, Doh JW : Multiple densities of the chronic subdural hematoma in CT scans. **J Korean Neurosurg Soc** 54 : 38-41, 2013
25. Park SH, Kang DH, Park J, Hwang JH, Hwang SK, Sung JK, et al. : Fibrinogen and D-dimer analysis of chronic subdural hematomas and computed tomography findings : a prospective study. **Clin Neurol Neurosurg** 113 : 272-276, 2011
26. Saito K, Ito H, Hasegawa T, Yamamoto S : Plasmin-alpha 2-plasmin inhibitor complex and alpha 2-plasmin inhibitor in chronic subdural hematoma. **J Neurosurg** 70 : 68-72, 1989
27. Sajanti J, Majamaa K : High concentrations of procollagen propeptides in chronic subdural haematoma and effusion. **J Neurol Neurosurg Psychiatry** 74 : 522-524, 2003
28. Schnabel C, Di Martino E, Gilsbach JM, Riediger D, Gressner AM, Kunz D : Comparison of beta2-transferrin and beta-trace protein for detection of cerebrospinal fluid in nasal and ear fluids. **Clin Chem** 50 : 661-663, 2004
29. Senturk S, Guzel A, Bilici A, Takmaz I, Guzel E, Aluclu MU, et al. : CT and MR imaging of chronic subdural hematomas : a comparative study. **Swiss Med Wkly** 140 : 335-340, 2010
30. Shono T, Inamura T, Morioka T, Matsumoto K, Suzuki SO, Ikezaki K, et al. : Vascular endothelial growth factor in chronic subdural haematomas. **J Clin Neurosci** 8 : 411-415, 2001
31. So SK, Ogawa T, Gerberg E, Sakimura I, Wright W : Tracer accumulation in a subdural hygroma : case report. **J Nucl Med** 17 : 119-121, 1976
32. Stroobandt G, Fransen P, Thauvoy C, Menard E : Pathogenetic factors in chronic subdural haematoma and causes of recurrence after drainage. **Acta Neurochir (Wien)** 137 : 6-14, 1995
33. Vaquero J, Zurita M, Cincu R : Vascular endothelial growth-permeability factor in granulation tissue of chronic subdural haematomas. **Acta**

- Neurochir (Wien) 144** : 343-346; discussion 347, 2002
34. Weigel R, Schilling L, Schmiedek P : Specific pattern of growth factor distribution in chronic subdural hematoma (CSH) : evidence for an angiogenic disease. **Acta Neurochir (Wien) 143** : 811-818; discussion 819, 2001