

# Acetabular Paralabral Cyst: An Unusual Cause of Femoral Vein Compression



Raj S. Kullar, M.D., Ashley L. Kapron, Ph.D., Daniel Ihnat, M.D., Stephen K. Aoki, M.D., and Travis G. Maak, M.D.

**Abstract:** Acetabular labral tears are a known cause of hip pain in the young, active patient. Labral tears can be due to trauma, femoroacetabular impingement, capsular laxity, dysplasia, and degenerative pathology. Paralabral cysts are relatively common in association with labral tears of the hip, with cysts seen on magnetic resonance imaging studies in as many as 50% to 70% of patients with labral tears. In some cases the cysts can become sizeable and cause neurovascular compression. Nonoperative interventions for the management of paralabral cysts in the shoulder and knee have shown high recurrence rates. In the shoulder and knee, arthroscopic debridement of paralabral cysts has shown good results with lower recurrence rates and resolution of neurovascular function. In the hip there is limited literature regarding surgical management of paralabral cysts. We present a surgical technique for arthroscopic decompression of acetabular paralabral cysts combined with labral repair.

There is a preponderance of literature supporting the role of femoroacetabular impingement as a cause of labral tears in the young athlete.<sup>1,2</sup> However, hip instability as a cause of acute hip pain and a labral tear in the young patient is an under-recognized problem. In small series of patients undergoing hip arthroscopy after a traumatic hip dislocation, a labral tear has been found 80% to 100% of the time.<sup>3-5</sup> In addition, a less traumatic subluxation event in patients with acetabular undercoverage or even borderline dysplasia can also lead to a labral tear and be a significant cause of acute hip pain. The labrum is under increased stress with deficient coverage in patients with dysplasia, and thus the labrum is prone to detachment.<sup>6</sup>

In the setting of a labral tear, the suction seal is lost, and as a result, there is a loss of congruity between the femoral head and acetabulum. It has been speculated that this may lead to increased intra-articular pressure that, theoretically, can force synovial fluid through the area of the labral tear and generate a cyst.<sup>2</sup>

In patients with paralabral cysts, nonoperative treatment options for juxta-articular ganglion cysts include image-guided aspiration with or without steroid injection. Image-guided aspiration of spinoglenoid cysts in the shoulder has shown an 18% failure rate of aspiration and a 48% recurrence rate for those cysts successfully aspirated.<sup>7</sup>

Regarding surgical treatment, debridement of a paralabral cyst in the shoulder followed by labral repair has been shown to be an effective means of cyst decompression that provides satisfactory alleviation of symptoms.<sup>8,9</sup> Similarly, in the knee, surgical treatment with cyst debridement with treatment of meniscal pathology has shown lower recurrence rates than aspiration alone.

There is limited literature available regarding treatment options for paralabral cysts in the hip. A recent small case series has shown effective treatment with arthroscopic decompression of the cyst and labral debridement at 2 years' follow-up.<sup>10</sup> In the hip we believe that paralabral cysts can be adequately treated arthroscopically with cyst decompression and labral repair. We present our technique for arthroscopic treatment of paralabral cysts in the hip ([Video 1](#)).

*From the Department of Orthopaedics (R.S.K., A.L.K., S.K.A., T.G.M.) and Division of Vascular Surgery (D.I.), University of Utah, Salt Lake City, Utah, U.S.A.*

*The authors report the following potential conflict of interest or source of funding: S.K.A. receives support from Pivot Medical, ArthroCare. Educational consultant, product consultant.*

*Received May 31, 2014; accepted October 3, 2014.*

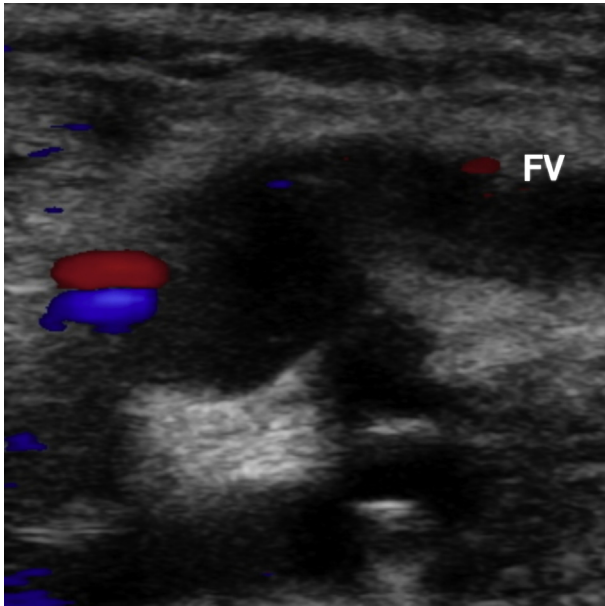
*Address correspondence to Raj S. Kullar, M.D., or Travis G. Maak, M.D., Department of Orthopaedics, University of Utah, 590 Wakara Way, Room A0100, Salt Lake City, UT 84108, U.S.A. E-mail: [rajkullar@gmail.com](mailto:rajkullar@gmail.com) or [travis.maak@hsc.utah.edu](mailto:travis.maak@hsc.utah.edu)*

© 2015 by the Arthroscopy Association of North America. Open access

under CC BY-NC-ND license.

2212-6287/14463

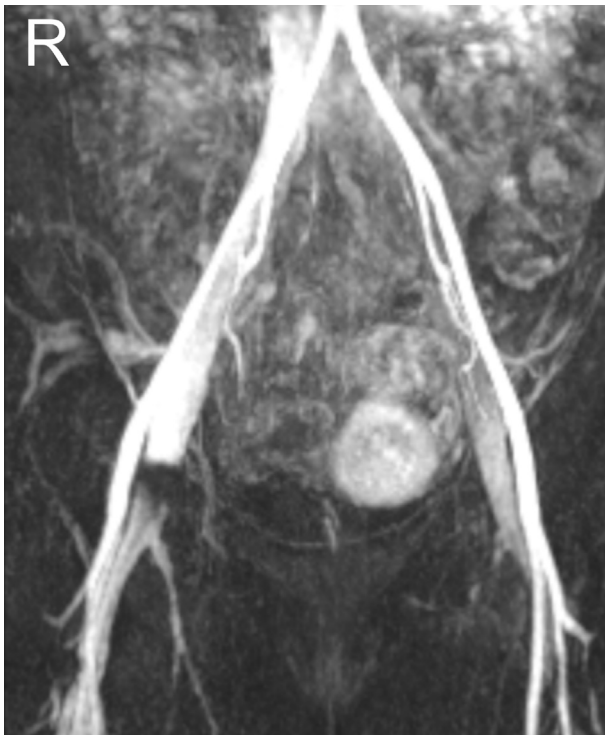<http://dx.doi.org/10.1016/j.eats.2014.10.003>



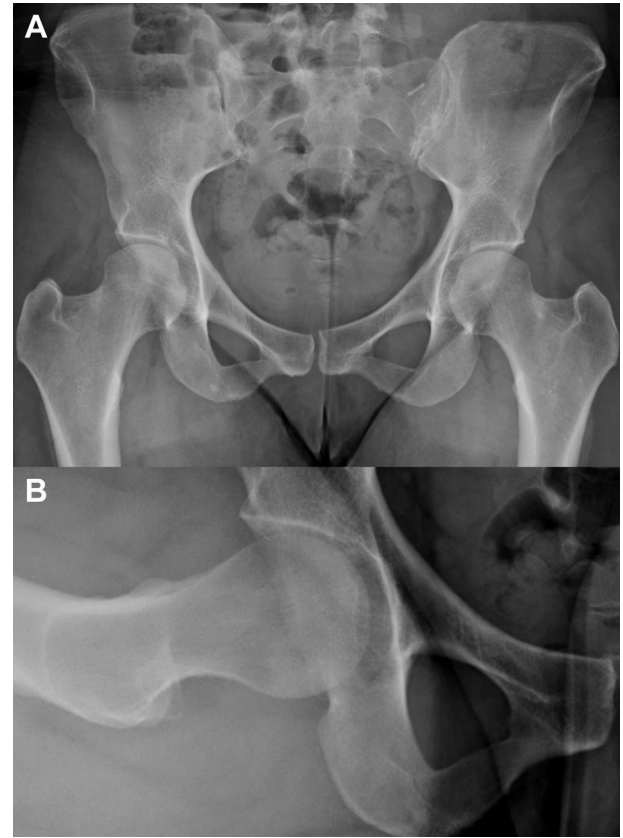
**Fig 1.** Preoperative ultrasound showing common femoral vein (FV) occlusion by extrinsic cystic mass.

### Surgical Technique

Preoperative evaluation of a patient with a labral tear and paralabral cyst should include a thorough history and physical examination, as well as critical evaluation of radiographs and advanced imaging for associated dysplasia, labral tears, or chondral injuries. A



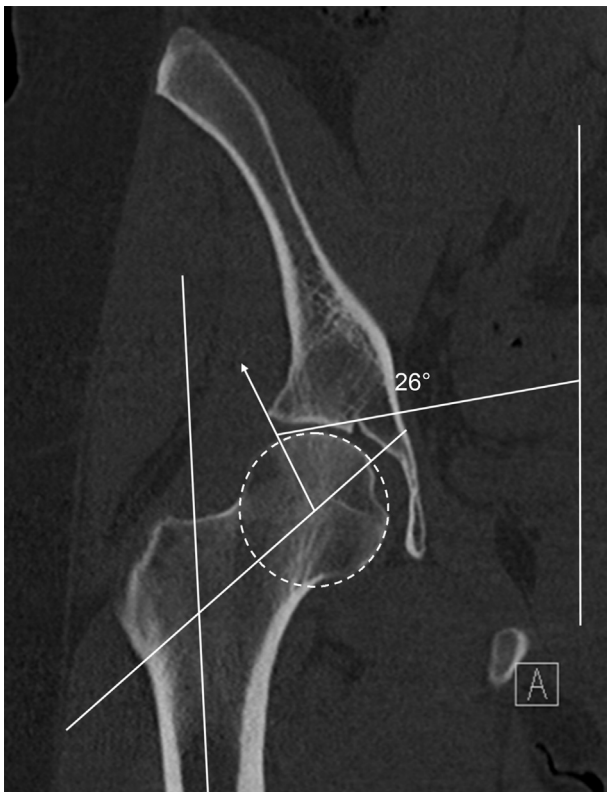
**Fig 2.** Magnetic resonance angiogram showing common femoral vein obstruction on right (R) side.



**Fig 3.** (A) Anteroposterior pelvic radiograph showing a lateral center-edge angle of  $26^\circ$ , a lateral sourcil-edge angle of  $17^\circ$ , and an up-sloping sourcil. (B)  $90^\circ$  Dunn lateral radiograph showing an alpha angle of  $52^\circ$ .

demonstrative case was chosen for presentation of our preferred surgical technique. A young active female patient presented with acute hip pain and refractory lower extremity edema after a subluxation episode. The physical examination findings were significant for anterior apprehension and positive impingement signs. Magnetic resonance imaging (MRI) of the pelvis and ultrasound showed evidence of a cystic mass causing focal adjacent common femoral vein compression (Figs 1 and 2). Plain radiographs and computed tomography (CT) scan showed borderline acetabular undercoverage based on the lateral center-edge angle, as well as version measurements on CT scan (Figs 3 and 4). MRI of the hip confirmed an extrinsic compressive mass from an anterosuperior paralabral cyst with an associated anterior labral tear (Fig 5). A preoperative ultrasound-guided cyst aspiration was unsuccessful at decompressing the cyst or relieving symptoms.

Our preference is to perform hip arthroscopy with the patient in the supine position using a custom traction table (Smith & Nephew, Memphis, TN). A heavily padded perineal post is lateralized to the medial thigh of the operative extremity to help with obtaining distraction and to minimize neurovascular injury. The limb is



**Fig 4.** Preoperative computed tomography scan showing an up-sloping sourcil and lateral center-edge angle of  $26^\circ$ .

placed in  $0^\circ$  of flexion, neutral abduction, and  $15^\circ$  of internal rotation, and axial traction is placed on the operative extremity to facilitate entry.

By use of fluoroscopic guidance, an anterolateral viewing portal is established (Table 1). Arthroscopic evaluation begins with a  $70^\circ$  arthroscope through the anterolateral portal, and an anterior portal is obtained under direct arthroscopic visualization. An interportal capsulotomy may be performed with a Beaver blade (Smith & Nephew). Diagnostic arthroscopic evaluation includes evaluation of the labrum and chondral surfaces for any associated pathology (Table 2).

**Table 1.** Three Primary Portals Used to Address Acetabular Pathology Including Paralabral Cysts Including the External Landmarks Used for Proper Portal Placement

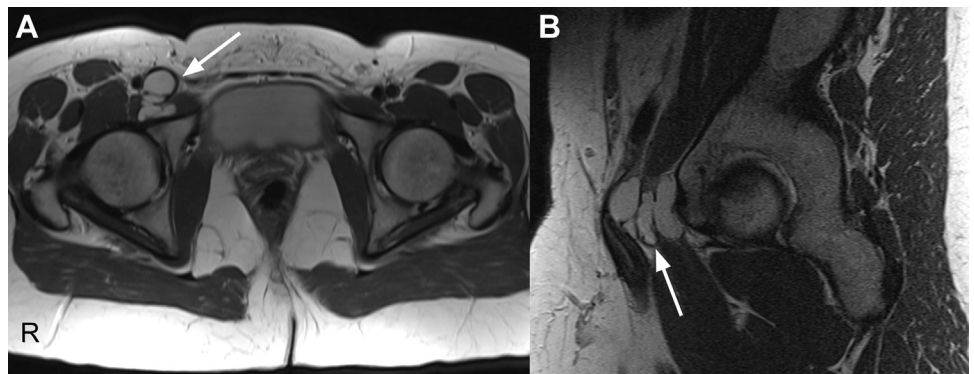
Portal	Landmarks
Anterolateral	Location 2 cm anterior and 2 cm superior to anterosuperior border of greater trochanter Placement parallel to acetabular inclination on fluoroscopy
Anterior	Intersection of sagittal line drawn down from anterior superior iliac spine and superior margin of greater trochanter
Distal anterolateral	3 to 5 cm distal to anterolateral portal, just anterior to femoral shaft

Identification of the labral tear can often help guide localization of the associated paralabral cyst.

Our preferred technique for labral repair includes rim preparation through the anterolateral portal and anchor placement through an accessory distal anterolateral portal. In this particular case, a labral tear was seen extending from the 2:30 to 3:30 clock-face position (Fig 6). The adjacent acetabular rim is prepared at the level of the injury with an ArthroCare radio-frequency ablation wand (ArthroCare Sports Medicine, Austin, TX) and a 5.5-mm full-radius shaver and burr (Arthrex, Naples, FL). Care is taken to avoid rim resection. A third distal anterolateral portal is obtained, as described in Table 1, to allow for an appropriate vector to minimize the risk of intra-articular anchor placement. Two 1.4-mm Nanotack anchors (Pivot Medical, Sunnyvale, CA) are placed at the acetabular rim. The labrum is then repaired with simple suture passage and manual knot tying with a knot pusher.

After the labrum is repaired, the traction is removed and the hip slightly flexed. Dissection proceeds anterior to the rim of the acetabulum toward the psoas tendon sheath. In this particular case, the cyst was encountered medial to the psoas tendon sheath, anterior and medial to the anterior edge of the labrum at the 3:30 clock-face position. Expression of cystic fluid may occur on entry with the arthroscope (Fig 7).

**Fig 5.** Preoperative magnetic resonance images showing a paralabral cyst (arrows) originating from a labral tear in the right (R) hip, causing adjacent femoral vein occlusion: (A) axial magnetic resonance slice and (B) sagittal magnetic resonance slice.



**Table 2.** Spectrum of Intra-articular Pathologies that Can Be Found and Addressed via Arthroscopic Means

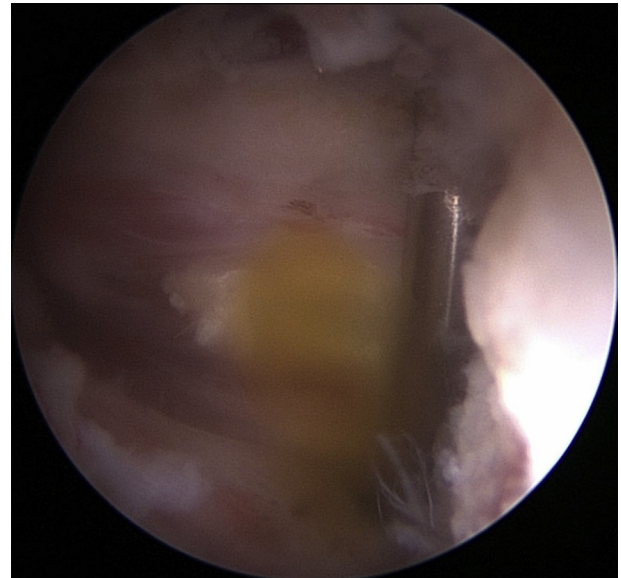
Diagnostic arthroscopic evaluation
Femoral head chondral surface
Focal chondral injuries
Osteonecrosis
Osteoarthritis
Acetabular chondral surface
Delamination
Ligamentum teres tears
Osteoarthritis
Loose bodies
Synovial disorders
Synovitis
Pigmented villonodular synovitis
Synovial chondromatosis
Labrum
Tears
Labral hypertrophy
Paralabral cysts

A 5.5-mm shaver can be used to enter the cyst and decompress loculations that are frequently found with paralabral cysts under direct arthroscopic visualization. After adequate decompression, the interportal capsulotomy can be closed with interrupted high-tensile strength sutures using a suture passage device through the anterior portal.

Postoperatively, patients are instructed to follow touch-down weight-bearing precautions for 4 weeks and begin physical therapy to work on range-of-motion exercises. Return to sports activity is allowed at the 4- to 6-month mark. Postoperative imaging is not routinely obtained, but ultrasound can be used to document cyst resolution in the case of extrinsic neurovascular compression (Fig 8).

### Discussion

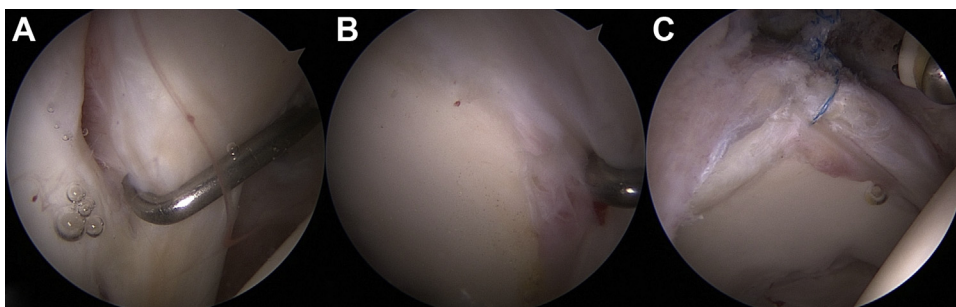
Paralabral cysts of the hip are seen in 50% to 70% of patients with labral tears and in less than 5% of the general population.<sup>11</sup> The cysts are thought to arise from weakened areas of the joint capsule or adjacent labral tissues through a 1-way valve mechanism.<sup>8</sup> In the knee they are seen in 4% to 6% of MRI scans, with 90% of those having an associated meniscus tear.<sup>12</sup> Tung et al.<sup>13</sup> reviewed 2,211 MRI scans of the shoulder

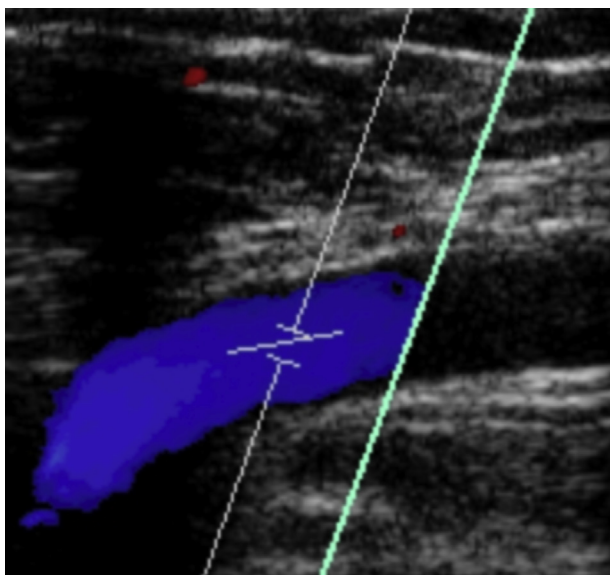
**Fig 7.** Cystic fluid was liberated from the paralabral cyst after it was entered with a shaver.

and found paralabral cysts in 2.3%. Fifty-seven percent of the cysts were adjacent to the posterior labrum, 21% to the anterior labrum, and 14% to the superior labrum. An associated labral tear was present 88% of the time.

Although parameniscal or paralabral cysts are often seen, they are less commonly associated with neurovascular compression. In the shoulder there are several series reporting on suprascapular nerve compression due to a paralabral cyst associated with a posterior or superior labral tear.<sup>8,9,14</sup> Quadrilateral space compression by an adjacent paralabral cyst has also been reported.<sup>15</sup> In the hip there is only 1 report of a paralabral cyst leading to neurovascular compression in a patient with sciatica.<sup>16</sup>

Nonoperative treatment options for juxta-articular ganglion cysts include image-guided aspiration with or without steroid injection. Image-guided aspiration of spinoglenoid cysts in the shoulder has shown an 18% failure rate of aspiration and a 48% recurrence rate for those cysts successfully aspirated.<sup>7</sup> Another smaller series has shown a recurrence rate as high as 75% in 4

**Fig 6.** (A, B) Labral hypertrophy and associated tear between 2:30 and 3:30 clock-face positions. (C) Labrum after repair.



**Fig 8.** Postoperative ultrasound showing normal flow through the common femoral vein without any signs of obstruction within the window of the probe (cyan line).

shoulders.<sup>14</sup> A series of 18 knees that underwent ultrasound-guided aspiration and injection of a lateral parameniscal cyst showed 10 (55%) with complete relief, 2 (11%) with some relief, and a 33% failure rate at 10 months.<sup>17</sup>

Regarding surgical treatment, debridement of a paralabral cyst in the shoulder followed by labral repair has been shown to be an effective means of cyst decompression that provides satisfactory alleviation of symptoms.<sup>8,9</sup> Similarly, in the knee, surgical treatment with cyst debridement with treatment of meniscal pathology has shown lower recurrence rates than aspiration alone. A series of 105 parameniscal cysts treated surgically (91 arthroscopic, 11 open) with cyst debridement and meniscal treatment (104 meniscectomies, 1 meniscal repair) showed a recurrence rate of 10% and good or excellent results in 87% of cases at a mean of 5 years' follow-up.<sup>18</sup> There was no increase in the recurrence rate with arthroscopic versus open treatment.

In patients with neurovascular compression, surgical treatment can be effective at restoring function. In the shoulder, suprascapular nerve compression can be effectively alleviated by cyst decompression and labral repair.<sup>8,9,14</sup> There is less literature available regarding surgical treatment options for paralabral cysts in the hip. A recent small case series has shown effective resolution of symptoms with arthroscopic treatment with decompression of the cyst and labral debridement, with improvement in Harris Hip Scores, Western Ontario and McMaster Universities Osteoarthritis Index scores, and University of California, Los Angeles scores at 2 years' follow-up.<sup>10</sup>

Appropriate treatment of patients with labral tears and paralabral cysts begins with an accurate diagnosis of the specific pathology in an attempt to optimize patient outcome. This includes critical evaluation of radiographs and considering advanced imaging to evaluate for acetabular undercoverage and borderline dysplasia. In patients with hip dysplasia, the anterior labrum is under heightened stress because of undercoverage and is prone to tearing.<sup>19</sup> Mild osseous undercoverage can predispose a patient to atraumatic instability and lead to a labral tear.<sup>20</sup> A study looking at 170 patients with mild to moderate hip dysplasia found a 72% incidence of labral tears, with 93% involving the anterior labrum.<sup>21</sup> Many of these patients will have positive test findings for femoroacetabular impingement as well.<sup>20</sup> In these patients a preoperative CT scan or dynamic fluoroscopic imaging in the operating room can be helpful to clarify the degree of dysplasia and likelihood of hip instability as a cause of acute hip pain.<sup>20</sup> Intraoperatively, careful management of acetabular bone is critical to avoid worsening osseous deficiency and inducing iatrogenic hip instability.

In conclusion, an arthroscopic technique for management of paralabral cysts represents a safe, minimally invasive, efficient means of addressing the labral pathology and decompressing an associated paralabral cyst. It affords a detailed anatomic visualization, which is of paramount importance given the proximity of the adjacent major neurovascular structures. It also allows for a thorough central and peripheral compartment evaluation for associated pathologies when compared with an open technique. Careful evaluation of the hip including a history, physical examination, and diagnostic imaging is crucial to identify the cause of the paralabral cyst and presenting patient symptoms. Cyst aspiration may be considered; however, arthroscopic decompression with labral repair can lead to reproducible symptom relief and excellent patient outcomes.

## References

1. Beaulé PE, O'Neill M, Rakhra K. Acetabular labral tears. *J Bone Joint Surg Am* 2009;91:701-710.
2. Grant AD, Sala D, Davidovitch RI. The labrum: Structure, function, and injury with femoroacetabular impingement. *J Child Orthop* 2012;6:357-372.
3. Ilizaliturri VM Jr, Gonzalez-Gutierrez B, Gonzalez-Ugalde H, Camacho-Galindo J. Hip arthroscopy after traumatic hip dislocation. *Am J Sports Med* 2011;39:50S-57S (suppl).
4. Philippon MJ, Kuppersmith DA, Wolff AB, Briggs KK. Arthroscopic findings following traumatic hip dislocation in 14 professional athletes. *Arthroscopy* 2009;25:169-174.
5. Shindle MK, Kelly BT, Lane CG, Kelley B, Warren RF, Voos JE. Anterior labral tears with posterior hip subluxation or dislocation. *Arthroscopy* 2008;24:e33-e34 (abstr).
6. Lewis CL, Sahrman SA. Acetabular labral tears. *Phys Ther* 2006;86:110-121.

7. Piatt BE, Hawkins RJ, Fritz RC, Ho CP, Wolf E, Schickendantz M. Clinical evaluation and treatment of spinoglenoid notch ganglion cysts. *J Shoulder Elbow Surg* 2002;11:600-604.
8. Chen AL, Ong BC, Rose DJ. Arthroscopic management of spinoglenoid cysts associated with SLAP lesions and suprascapular neuropathy. *Arthroscopy* 2003;19:E15-E21.
9. Westrick RB, Fogarty BT, Johnson MP. Posterior labral tear with a paralabral cyst causing suprascapular nerve compression. *J Orthop Sports Phys Ther* 2013;43:511.
10. Lee KH, Park YS, Lim SJ. Arthroscopic treatment of symptomatic paralabral cysts in the hip. *Orthopedics* 2013;36:e373-e376.
11. Magee T, Hinson G. Association of paralabral cysts with acetabular disorders. *AJR Am J Roentgenol* 2000;174:1381-1384.
12. Helms CA. The meniscus: Recent advances in MR imaging of the knee. *AJR Am J Roentgenol* 2002;179:1115-1122.
13. Tung GA, Entzian D, Stern JB, Green A. MR imaging and MR arthrography of paraglenoid labral cysts. *AJR Am J Roentgenol* 2000;174:1707-1715.
14. Westerheide KJ, Karzel RP. Ganglion cysts of the shoulder: Technique of arthroscopic decompression and fixation of associated type II superior labral anterior to posterior lesions. *Orthop Clin North Am* 2003;34:521-528.
15. Sanders TG, Tirman PF. Paralabral cyst: An unusual cause of quadrilateral space syndrome. *Arthroscopy* 2003;15:632-637.
16. Sherman PM, Matchette MW, Sanders TG, Parsons TW. Acetabular paralabral cyst: An uncommon cause of sciatica. *Skeletal Radiol* 2003;32:90-94.
17. Macmahon PJ, Brennan DD, Duke D, Forde S, Eustace SJ. Ultrasound-guided percutaneous drainage of meniscal cysts: Preliminary clinical experience. *Clin Radiol* 2007;62:683-687.
18. Hulet C, Souquet D, Alexandre P, Locker B, Beguin J, Vielpeau C. Arthroscopic treatment of 105 lateral meniscal cysts with 5-year average follow-up. *Arthroscopy* 2004;20:831-836.
19. Groh MM, Herrera J. A comprehensive review of hip labral tears. *Curr Rev Musculoskelet Med* 2009;2:105-117.
20. Shu B, Safran MR. Hip instability: Anatomic and clinical considerations of traumatic and atraumatic instability. *Clin Sports Med* 2011;30:349-367.
21. McCarthy JC, Lee JA. Acetabular dysplasia: A paradigm of arthroscopic examination of chondral injuries. *Clin Orthop Relat Res* 2002;405:122-128.