

## Clinical Efficacy of Bone Cement Augmented Screw Fixation for the Severe Osteoporotic Spine

Jong Hun Seo, Chang Il Ju, Seok Won Kim, Jong Kyu Kim, Ho Shin

*Department of Neurosurgery, College of Medicine, Chosun University, Gwangju, Korea*

**Objective:** Transpedicular instrumentation of the osteoporotic spine is a challenge for the spine surgeon due to the probability of screw loosening and the potential possibility of nonunion. The purpose of this study was to evaluate the clinical efficacy of bone cement augmented screw fixation in patients with severe osteoporosis.

**Methods:** Between February 2004 and August 2007, 250 patients with severe osteoporosis (T-score on BMD < -3.0) that had screw fixation were included in this study. The patients were divided into two groups (Group I: 157 patients that underwent bone cement augmented screw fixation that had a variety of spine spinal diseases including fractures, and Group II: 93 patients with severe osteoporosis that had screw fixation without bone cement augmentation). The imaging and clinical features were analyzed, including bone cement augmented levels, fusion rate and related complications. The visual analog scale (VAS), Oswestry disability questionnaire (ODI) and modified MacNab's criteria were used for the assessment of pain and functional capacity.

**Results:** In both groups, a significant improvement in the VAS and ODI was achieved. 146 out of 157 patients (93%) in Group I and 83 out of 93 patients (90%) in Group II were graded as an excellent or good result according to the modified MacNab's criteria. None of the patients experienced serious complications. However, there were two cases with neurological deterioration as a result of bone cement extravasation in Group I. For Group II, there were five cases of screw loosening that required re-operation for bone cement augmentation.

**Conclusion:** Whether bone cement augmentation was performed or not, it was possible to achieve satisfactory results in patients with severe osteoporosis. However, if used carefully, bone cement augmented transpedicular screwing can reduce screw loosening and pullout in patients with severe osteoporosis.

**Key Words:** Bone cement • Complication • Severe osteoporosis

### INTRODUCTION

With the rapid increase in the aging of the population, osteoporosis is a common and frequently encountered condition that the spine surgeon encounters. However, in patients with severe osteoporosis, the anchoring effect that holds the screw in place is decreased, and the probability of hardware failure is high. As a result, the possibility of nonunion is increased<sup>15</sup>. Therefore, transpedicular instrumentation is difficult for the spine surgeon to perform on an osteoporotic spine<sup>1</sup>. To overcome these limitations, in the osteoporotic spine, and obtain stability in the contact area of the cancellous bone with screws, many

experimental studies have focused on increasing the effect of the pedicle screw pullout strength and transverse bending stiffness<sup>15,20,21</sup>. Among them, polymethylmethacrylate (PMMA) is becoming very popular due to its simplicity, availability, and cost effectiveness<sup>14,18,19</sup>. However, clinical comparative studies on a large number of patients using bone cement for transpedicular augmentation are limited. The purpose of this study was to examine and compare the safety and efficacy of bone cement augmented screw fixation in the setting of various spine diseases including spinal fractures associated with severe osteoporosis.

### MATERIAL AND METHODS

Between February 2004 and August 2007, 250 consecutive patients, with various spinal diseases, including spinal fractures associated with severe osteoporosis underwent transpedicular screw fixation. Among the 250 individuals, 157 patients had 947 pedicle screws augmented with PMMA (Group I).

• Received: March 20, 2012 • Revised: June 5, 2012

• Accepted: June 25, 2012

Corresponding Author: **Jong Kyu Kim, MD**

Department of Neurosurgery, School of Medicine, Chosun University, 588, Seosuk-dong, Dong-gu, Gwangju-city 501-717, Korea

Tel: +82-62- 220-3126, FAX: +82-62-227-4575

E-mail: karism90@hanmail.net

Group II consisted of 93 patients that underwent screw fixation without bone cement augmentation in spite of severe osteoporosis (458 screws). All patients fulfilled the following inclusion criteria: (1) severe osteoporosis (the lowest T-score on DEXA bone mineral density  $<-3.0$ ), (2) more than 45 years of age, (3) patients that were evaluated for at least 10 months. The exclusion criteria: (1) previous back surgery, (2) instrumented fusion for primary spinal tumors or metastasis. Fusion was considered successful when the evidence showed no radiolucent halo and below  $5^\circ$  on lateral flexion and extension radiographs or plain follow-up X-rays demonstrated clear trabecular bone bridging across the intended fused segments at the final follow-up for interbody fusion. Patients were followed clinically and radiographically for a minimum of 10 months postoperatively. The follow-up period was from the shortest duration of 10 months to the longest 23 months, and the mean time period was 12 months.

### 1. Surgical technique of bone cement augmentation

Under general anesthesia, in the prone position, the lesion was reached by a posterior midline approach. Tapping was performed using just a 5 mm smaller screw than a permanent screw in width and length under the C-arm guide, taking the location in which the bone cement would be injected into consideration. A bone biopsy needle was inserted into the tapping site, located in the anterior one half to one third portion of the vertebral body. Bone cement with a viscosity slightly thinner than that of toothpaste was prepared. Bone cement was injected under the C-arm guide, localized in the vertebral body through a bone biopsy needle. The bone biopsy needle contained approximately 2.4 cc of bone cement, and therefore about 4.8 cc per vertebra was injected. Permanent transpedicular screws were inserted as soon as possible after the injection of bone cement under the guidance of the C-arm (Fig. 1). Bone cement augmented transpedicular screwing was performed in adjacent vertebra using the same method. It took from a few minutes to 10 minutes for the bone cement to become completely hardened; therefore, the rod was connected after at least 10 minutes. For the patients with compression/burst fractures or idiopathic scoliosis without neurological deficits, posterior or posterolateral fusion was performed without decompression. The autogenous bone chips mixed with sufficient allograft bone chips were put on to the decorticated laminae. The sources of bone graft were autogenous local bone chips derived from spinous process and laminae and sufficient allograft bone chips (Fig. 2). For the patients who need interbody fusion for neural decompression, complete neural decompression was followed by discectomy. After discectomy,

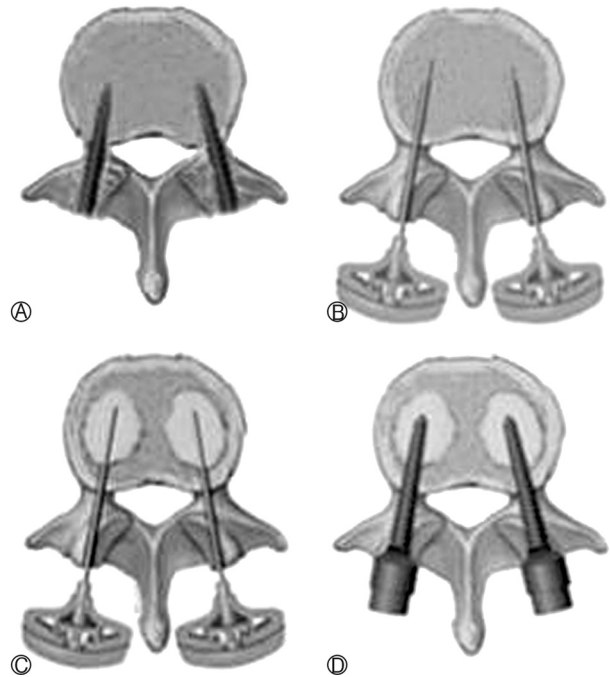


Fig. 1. Diagram of surgical technique. (A) Insertion & removal of preceding tap screws. (B) Insertion of bone biopsy needle. (C) Injection of bone cement. (D) Insertion of transpedicular screws.

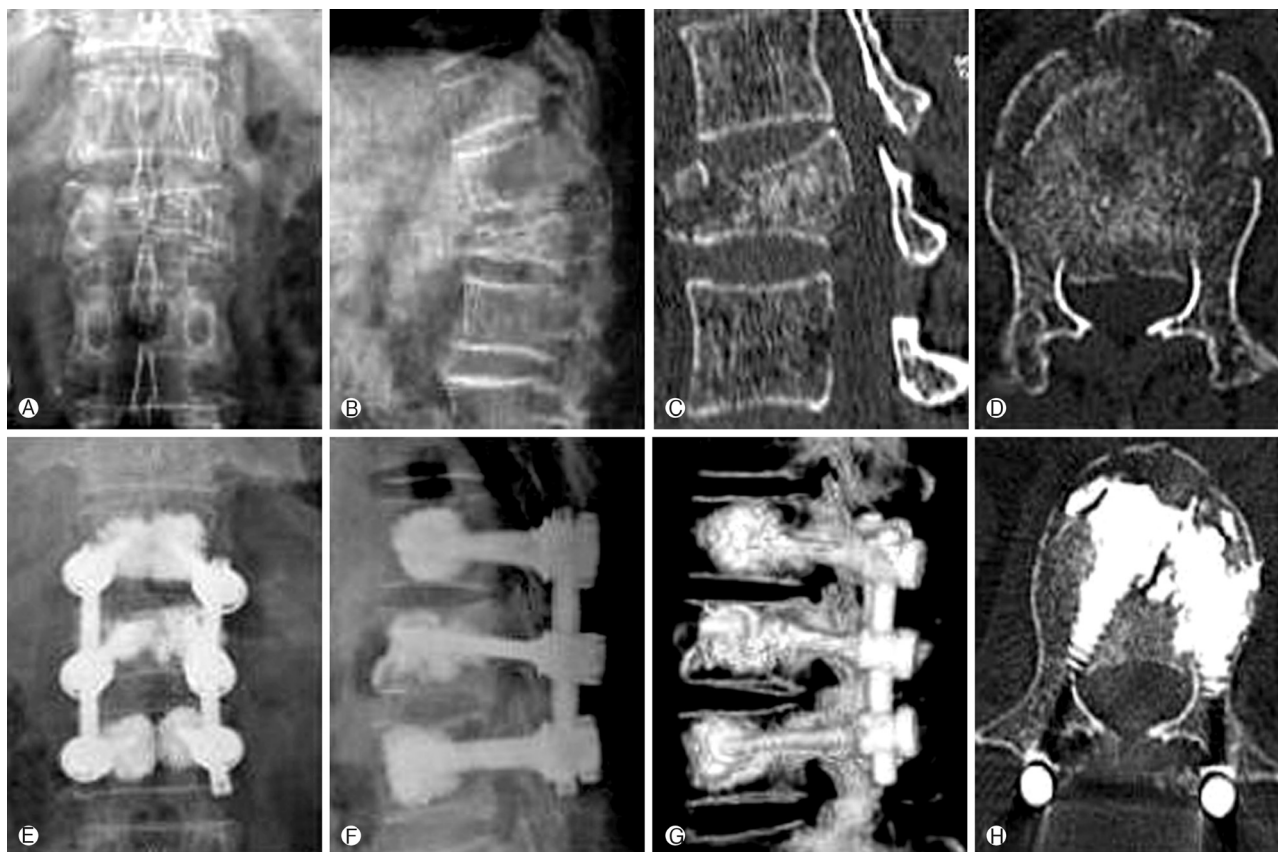
autogenous local bone chips and allograft bone chips were inserted compactly into the disc space. And then 2 cages filled with autologous bone chips were inserted to the disc space.

### 2. Clinical Evaluation

The preoperative and postoperative visual analog scale (VAS) and Oswestry disability questionnaire (ODI) were used for the assessment of pain and functional capacity and analyzed with the paired t test. ANOVA, X<sup>2</sup>, correlation, regression, and subgroup analyses were also conducted. The level of statistical significance was established at a  $p < 0.05$ . Patients were also evaluated according to the modified MacNab's criteria for characterizing clinical outcome after spinal surgery. Postoperative complications were reviewed for instrument loosening or pullout, neurological deterioration due to cement leakage, infection and other procedure or cement related complications.

## RESULTS

The basic characteristics of each Group are summarized in Table 1. Although the mean age of Group II was younger than in Group I, no statistical significant difference was noted between the two groups with respect to age, gender, T-score on the BMD and anatomic distribution. The mean VAS im-



**Fig. 2.** A 59-year-old female patient fell down and sustained an unstable L1 bursting fracture (T-score on BMD:-3.72). (A), (B), (C), (D): Preoperative simple radiographs, computed tomography scans demonstrate about 50% canal encroachment, 26° of kyphotic deformity and 60% loss of anterior vertebral height. (E), (F), (G), (H): Postoperative simple radiographs and 3-dimensional computed tomography scans show improved the canal encroachment and anterior vertebral body height without any cement leakage.

**Table 1.** Basic characteristics of patients (n=250)

	Group I (n=157)	Group II (n=93)
Age	66.5 (49-74)	62.8 (46-69)
BMD (T-score)	-3.89	-3.60
Male : Female	49:108	37:56
Level		
thoracic (T7-T10)	26	24
thoracolumbar (T1-L2)	402	148
lumbar (L3-L5)	418	216
sacrum (S1)	101	70

\* BMD: Bone Marrow Density

proved from 8.5 before surgery to 1.9 after surgery, and the mean Oswestry disability questionnaire scale changed from 76.6% to 40.0% in Group I. The VAS improved from 8.0 to 2.1 and the mean Oswestry disability questionnaire scale improved from 74.6% before surgery to 38.2% after surgery

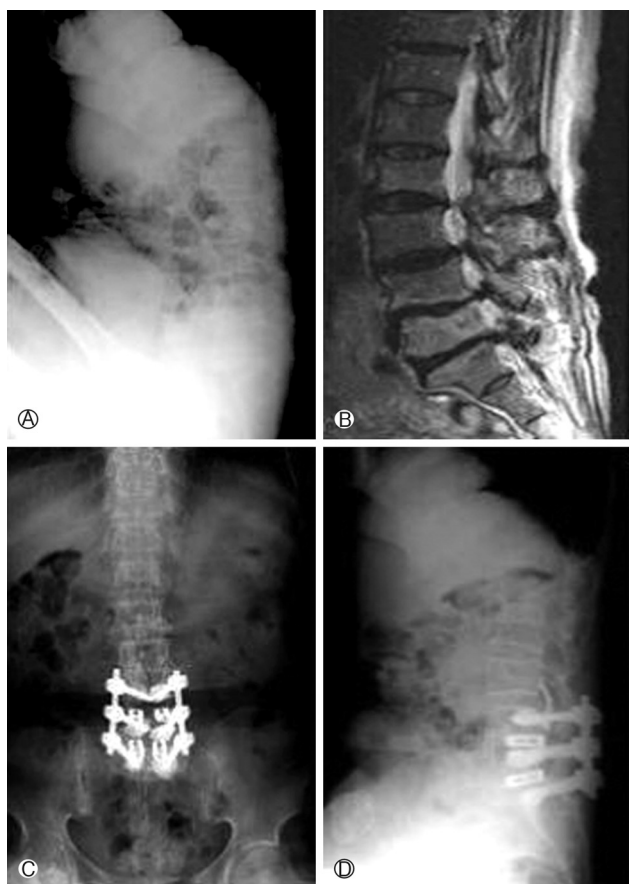
in Group II. In both groups, a significant improvement in the VAS and Oswestry disability questionnaire was achieved ( $p < 0.001$ ) (Table 2). One hundred and forty six patients out of 157 in Group I (93%) and 83 out of 93 patients in Group II (90%) were graded as having excellent or good results according to the modified MacNab's criteria. There were no major complications such as fat embolism, pulmonary embolism and postoperative deaths. All patients in Group I achieved successful bone fusion according to the fusion criteria described above. However, two patients had clinically symptomatic cement extravasation in Group I (Fig. 3). One patient experienced slight motor weakness and the other patient had transient hypoesthesia. However, five patients developed screw loosening that required re-operation with bone cement augmented screw fixation within six months in Group II (Table 3). One patient in Group I and two patients in Group II had deep wound infections with underlying diabetes mellitus. In all patients, a debridement with secondary sutures was necessary and methicillin-resistant staphylococcus aureus grew in the bacterial cultures.

**Table 2.** Functional and pain scoring of patients

Group	Oswestry disability questionnaire scale (%)			VAS Score		
	Preoperation	Postoperation	p-value	Preoperation	Postoperation	p-value
Group I	76.6±18.3	40.0±17.5	<0.001	8.5±1.8	1.9±1.5	<0.001
Group II	74.6±18.5	38.2±15.5	<0.001	8.0±1.5	2.1±1.4	<0.001

Data were presented as mean±standard deviation.

\*VAS: visual analog scale



**Fig. 3.** A 67 year old woman with low back pain and left leg radiating pain (T-score on BMD: -3.89). (A) & (B): Preoperative simple radiograph and T2 sagittal image show degenerative spondylolisthesis and spinal stenosis at L4-L5 and L5-S1 level. (C) & (D): Postoperative simple radiographs show cement extravasation at L3-L4 level.

However, the infections were controlled after intravenous antibiotics treatment for eight weeks without removal of the screws.

## DISCUSSION

Augmentation of pedicle screw fixation with bone cement has been used for many years and experimental studies have demonstrated that various cements such as PMMA, hydrox-

**Table 3.** Complications related to procedures

Complications	Group I	Group II
Cement leakage		
motor weakness	1	-
transient hypoesthesia	1	-
pulmonary embolism	0	-
Screw loosening	0	5
Infection	1	2

yapatite, and calcium sulfate are effective for augmentation of the pedicle screw<sup>2-5,7-9,11,22</sup>. Among them, PMMA has been becoming the most popular material used due to its simplicity, availability, and cost effectiveness. Moreover, some studies have demonstrated that PMMA has a stronger augmentation power than calcium phosphate and calcium sulfate cement for primary screw augmentation<sup>12,13,17</sup>. PMMA has been shown to increase the pull out strength from 96% to 262% and transverse bending stiffness up to 153%<sup>20</sup>. Indeed, we made the bulk of the screw with bone cement by injecting bone cement to the spinal cancellous bone; this prevented the “teeter-totter” motion of screws in the spinal pedicles until bone fusion<sup>17</sup>. However, bone cement can leak into the epidural space, which can cause an associated myelopathy or radiculopathy. The intravertebral space initially created by the tap screw allows placement of more viscous, partially cured, bone cement. Viscous bone cement can be injected using low pressure with this method. When the cement is injected, the only way for cement to flow is from the middle to posterior and/ or anterior vertebral body. In that circumstance, most of the injected cement will stay in the vertebral body and will not easily flow back from the space between needle and pedicle tract. Therefore, cement leakage from the unrecognized breached pedicle into the spinal canal or intervertebral foramen can be avoided. In addition, the inserted depth of the biopsy needle should be in the middle third of the vertebral body. It is presumed that the injected cement will flow from the middle to anterior or posterior part of the vertebral body, and then the pedicle. Finally, the viscosity of bone cement must be considered. If it is too thick, the injection of bone cement can cause problems. If it is too thin, it may leak into the blood vessels or the neural foramen. Furthermore, bone cement might spread too widely

on the vertebral body, and as a result, the fixation strength would be decreased<sup>7,8)</sup>. In addition, systemic complications including fever, infection, hypoxia and pulmonary embolism have been reported with the use of PMMA<sup>6)</sup>. There was one case of methicillin-resistant staphylococcus aureus wound infection in Group I that was well controlled. No surgical death, myocardial infarction, catastrophic pulmonary embolism or fat embolism occurred. MacAfee et al<sup>10)</sup> reported that PMMA augmentation increased the physical interaction of titanium implants with the contact area of cancellous bone. Ultimately, repetitive cyclic loading in the absence of an effective interbody or posterolateral fusion will result in implant and PMMA loosening and progressive bony erosion, a phenomenon familiar to orthopedic surgeons that apply bone cement in hip replacement surgery. Thus, careful attention to a bony arthrodesis is still necessary until a bioactive or osteoinductive bone cement becomes available. Theoretically, bone fusion is almost always necessary for most patients that have spinal instrumentation; except for patients that have tumor metastasis and have a short life expectancy. Once the fusion is achieved, the fixation force of the spinal instrumentation would not be necessary. In that situation, whether the cement is biodegradable, osteoconductive, or has some negative effect on the bone remodeling is no longer important. By contrast, if nonunion of the spinal fusion occurred, the screw would eventually have problems, whatever the initial rigidity of the fixation force<sup>1)</sup>. In order to obtain a solid fusion, there must be adequate fixation to immobilize the fusion area while the bone graft heals to the vertebral segments. In this study, none of the patients in Group I had screw loosening, back-out or breakage after a mean of 12 months of follow-up in contrast to Group II. This result suggests that the PMMA augmentation force can adequately withstand and serve to immobilize while bone fusion has been achieved. The limitations of this study include the following. First, one of the concerns in interpreting the results of this procedure was the difficulty in determining fusion success radiographically due to the short follow-up period. It is generally accepted that a solid fusion cannot be confirmed radiographically until 6 to 9 months after surgery. Pseudoarthrosis may be defined in the lumbar spine as a failure of a solid fusion 1 year after surgery<sup>16)</sup>. It is for that reason that the follow-up period was from the shortest duration of 10 months and the mean time period was 1 year after surgery. However although the clinical results were satisfactory based on the fusion criteria for the follow up period in our study, further investigations including more rigorous selection of patients and long term follow-up are needed. Second, in spite of the successful results, other factors that might depend on screw fixation strength such as screw diameter or insertion techniques were not considered in this study. Moreover, bone cement augmen-

tation may cause serious complications related to cement leakage such as motor weakness and hypoesthesia similar to the patients in this study. Hence, the use of PMMA must be monitored carefully in spite of its advantages.

## CONCLUSION

Whether bone cement augmentation is added or not, it was possible for screw fixation to achieve satisfactory results in patients with severe osteoporosis. However, if used carefully and properly, bone cement augmentation can prevent screw loosening and be an effective treatment in patients with severe osteoporosis.

## REFERENCES

1. Chang MC, Liu CL, Chen TH: Polymethylmethacrylate augmentation of pedicle screw for osteoporotic spinal surgery: a novel technique. *Spine* 33:E317-E324, 2008
2. Cook SD, Salkeld SL, Stanley T, Faciane A, Miller SD: Biomechanical study of pedicle screw fixation in severely osteoporotic bone. *Spine J* 4:402-408, 2004
3. Halvorson TL, Kelley LA, Thomas KA, Whitecloud TS 3rd, Cook SD: Effects of bone mineral density on pedicle screw fixation. *Spine* 19:2415-2420, 1994
4. Hernigou P, Duparc F: Rib graft or cement to enhance screw fixation in anterior vertebral bodies. *J Spinal Disord* 9:322-355, 1996
5. Ignatius AA, Augat P, Ohnmacht M, Pokinskyj P, Kock HJ, Claes LE: A new bioresorbable polymer for screw augmentation in the osteosynthesis of osteoporotic cancellous bone: a biomechanical evaluation. *J Biomed Mater Res* 58:254-260, 2001
6. Jenkins K, Wake PJ: Cement implantation syndrome. *Anaesthesia* 57:416, 2002
7. Kim HS, Park IH, Ryu JK, Kim SW, Shin H: Bone Cement Augmentation of Pedicular Screwing in Severe Osteoporotic Spondylolisthetic Patients. *J Korean Neurosurg Soc* 42:6-10, 2007
8. Kim HS, Park SK, Joy H, Ryu JK, Kim SW, Ju CI: Bone Cement Augmentation of Short Segment Fixation for Unstable Burst Fracture in Severe Osteoporosis. *J Korean Neurosurg Soc* 44:8-14, 2008
9. Lotz JC, Hu SS, Chiu DF, Yu M, Colliou O, Poser RD: Carbonated apatite cement augmentation of pedicle screw fixation in the lumbar spine. *Spine* 22:2716-2723, 1997
10. McAfee PC, Bohlman HH, Ducker T, Eismont FJ: Failure of stabilization of the spine with methylmethacrylate. A retrospective analysis of twenty-four cases. *J Bone Joint Surg Am* 68:1145-1157, 1986
11. Pfeifer BA, Krag MH, Johnson C: Repair of failed transpedicle screw fixation. A biomechanical study comparing polymethylmethacrylate, milled bone, and matchstick bone reconstruc-

- ction. **Spine** 19:350-353, 1994
12. Renner SM, Lim TH, Kim WJ, Katolik L, An HS, Andersson GB: Augmentation of pedicle screw fixation strength using an injectable calcium phosphate cement as a function of injection timing and method. **Spine** 29:E212-E216, 2004
  13. Rohmiller MT, Schwalm D, Glattes RC, Elalayli TG, Spengler DM: Evaluation of calcium sulfate paste for augmentation of lumbar pedicle screw pullout strength. **Spine J** 2:255-260, 2002
  14. Sarzier JS, Evans AJ, Cahill DW: Increased pedicle screw pullout strength with vertebroplasty augmentation in osteoporotic spines. **J Neurosurg (3 Suppl)** 96:309-312, 2002
  15. Soshi S, Shiba R, Kondo H, Murota K: An experimental study on transpedicular screw fixation in relation to osteoporosis of the lumbar spine. **Spine** 16:1335-1341, 1991
  16. Steinmann JC, Herkowitz HN: Pseudarthrosis of the spine. **Clin Orthop** 84:80-90, 1992
  17. Tan JS, Bailey CS, Dvorak MF, Fisher CG, Cripton PA, Oxland TR: Cement augmentation of vertebral screws enhances the interface strength between interbody device and vertebral body. **Spine** 32:334-341, 2007
  18. Turner AW, Gillies RM, Svehla MJ, Saito M, Walsh WR: Hydroxyapatite composite resin cement augmentation of pedicle screw fixation. **Clin Orthop Relat Res** 406:253-261, 2003
  19. Wang HS, Kim HY, Ju CI, Kim SW, Lee SM, Shin H: Bone Cement Augmented Screw Fixation for Severe Osteoporotic Spine: Large Series of Clinical Application. **Korean J Spine** 8(2):106-112, 2011
  20. Wittenberg RH, Lee KS, Shea M, White AA 3rd, Hayes WC: Effect of screw diameter, insertion technique, and bone cement augmentation of pedicular screw fixation strength. **Clin Orthop Relat Res** 296:278-287, 1993
  21. Wuisman PI, Van Dijk M, Staal H, Van Royen BJ: Augmentation of (pedicle) screws with calcium apatite cement in patients with severe progressive osteoporotic spinal deformities: an innovative technique. **Eur Spine J** 9:528-533, 2000
  22. Yerby SA, Toh E, McLain RF: Revision of failed pedicle screws using hydroxyapatite cement. A biomechanical analysis. **Spine** 23:1657-1661, 1998