

Left Sided Hydro-pneumothorax in a Operated Case of Left Diaphragmatic Hernia Repair: A Diagnostic Dilemma

CHANDRAKANT KAMLESH PANCHOLI¹, NARENDRA NARAYAN HOMBALKAR², SANTOSH BHIMRAO DALVI³, PRAKASH DATTATRAY GURAV⁴

ABSTRACT

Diaphragmatic hernia in adults often presents with overlapping respiratory and abdominal symptoms. They may be simple diaphragmatic eventrations or undiagnosed Bochdalek's hernias or may even be of post traumatic variety. Diaphragmatic hernias may be asymptomatic, present only with respiratory symptoms, or may present with obstruction and strangulation of involved bowel loops with faeco-pneumothorax. The index case was operated for open diaphragmatic hernia repair six years back and admitted for breathlessness with absence of abdominal signs and symptoms. Patient subsequently developed hydro-pneumothorax during conservative management. Emergency laparotomy revealed a gastric ulcer which perforated into the left chest giving rise to hydro-pneumothorax. In present study we would like to report how this unusual presentation led to dilemma in diagnosis and surgical intervention thus increasing the morbidity and mortality of the patient at our institute.

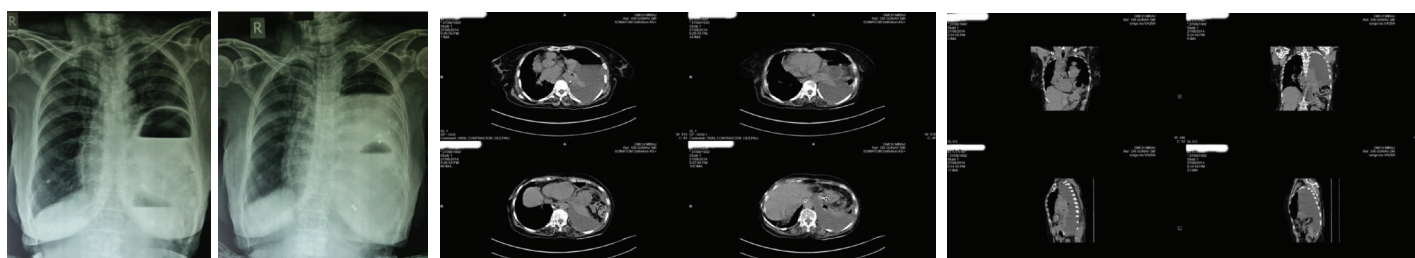
Keywords: Bilious hydro pneumothorax, Gastric ulcer perforation, Recurrent diaphragmatic hernia

CASE REPORT

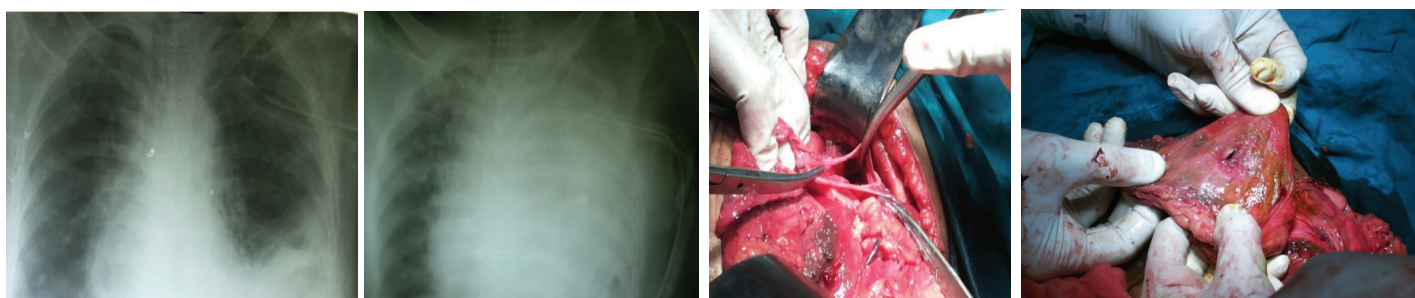
A 65-year-old female patient presented to emergency department with complaints of breathlessness since four days, which was gradually progressive and associated with left sided chest pain and dry cough. There was no history of trauma at the outset that the patient remembers. There was no history of hemoptysis, vomiting, hematemesis, pedal edema, giddiness or unconsciousness. No urinary or bowel complaints were reported. She was not a known case of bronchial asthma, ischemic heart disease, hypertension, diabetes, tuberculosis or tuberculosis contact. Patient was accidentally diagnosed having left-sided diaphragmatic hernia six years back and open abdominal hernia repair with primary closure was performed. On initial examination patient was conscious, afebrile and normotensive, however tachycardia (pulse 100 beats /min) and tachypnea (respiratory rate 36/min) were present. Abdomen was soft and non-tender. On auscultation air entry was decreased on left side with presence of lower zone crepitation. No cardiac murmur or other significant auscultatory findings were noted. Chest X-ray findings on admission

[Table/Fig-1] suggested increased bilateral Broncho-vascular markings with eventration of left hemi-diaphragm. Bilateral CP angles were clear. X-ray erect abdomen and ultrasound findings were also normal. Patient was treated conservatively with oxygen supplementation, naso-gastric decompression and fluid resuscitation. On day three patient became more breathless and hypotensive with absence of air entry on left side. Repeat X-ray [Table/Fig-2] suggested massive left sided hydro-pneumothorax with mediastinal shift. X-ray erect abdomen was normal and no abdominal signs were noted. Contrast CT scan suggested left hydro-pneumothorax with collapse of left lung and mediastinal shift towards right. Diaphragmatic hernia with hernia sac containing proximal stomach, omentum, spleen, splenic flexure of colon and meso-colon was also noted [Table/Fig-3,4].

There was a dilemma over choosing surgical intervention particularly laparotomy even after contrast CT scan [Table/Fig-3,4] because of absence of abdominal signs and symptoms. On clinical judgment left sided intercostal drain (ICD) was put for suspected spontaneous hydro-pneumothorax, which drained 1500 ml of brownish pleural



[Table/Fig-1]: Chest x-ray on admission showing elevated left hemi-diaphragm **[Table/Fig-2]:** Showing chest x-ray on day 3 of conservative treatment showing left sided hydro-pneumothorax **[Table/Fig-3]:** Showing axial cut sections of chest CT showing left sided hydro-pneumothorax with diaphragmatic hernia **[Table/Fig-4]:** Showing sagittal and coronal sections of chest CT showing left sided hydro-pneumothorax with diaphragmatic hernia



[Table/Fig-5]: Showing immediate post-ICD x-ray chest showing adequate expansion of left lung **[Table/Fig-6]:** Showing repeat chest x-ray showing complete white out lung fields on left side **[Table/Fig-7]:** Showing diaphragmatic defect intraoperatively **[Table/Fig-8]:** Showing perforated ulcer on body of stomach intraoperatively.

collection without any solid food particles along with air. Air Column movement in the ICD was brisk and good. Post ICD X-ray [Table/Fig-5] confirmed adequate expansion of lung.

The patient's conditions improved only marginally with decreased breathlessness and chest pain for few hours. A repeat post-ICD chest X-ray [Table/Fig-6] showed complete white-out lung on left-side whereas microscopic examination of pleural fluid revealed abundant polymorphs and few red blood cells with presence of bilirubin (3.9 mg/dl). Emergency exploratory laparotomy was performed for suspected hollow viscous perforation. Intra-operatively a diaphragmatic defect of size approximately 8 cm × 4 cm was noted [Table/Fig-7]. A large hernial sac containing stomach (fundus and body), omentum, spleen and upper part of splenic flexure of colon was noted. A perforated ulcer (1 cm x 1 cm) with punched out edges, suggested it to be pathological was noted on anterior surface of body of stomach. [Table/Fig-8].

ICD tube was also noted in chest cavity high above the diaphragmatic defect and separate from hernial contents. Gastric perforation was closed with omental patch, excess of hernial sac was excised and primary repair of diaphragm was done. Postoperatively patient required invasive positive pressure ventilation. Broad spectrum antibiotic support, fluid resuscitation and naso-gastric decompression were given to patient. Even after all the resuscitative efforts patient did not respond and succumbed on post-operative day three due to chemical pneumonitis and septicemia.

DISCUSSION

Diaphragmatic hernias may be congenital or secondarily acquired due to blunt or penetrating trauma to abdomen. Congenital diaphragmatic hernia, (incidence one in 2000 to one in 5000 live birth) results from failure of closure of pleuro-peritoneal membranes. Among congenital hernia two major types are described posterolateral or Bochdalek's hernia (80% to 90%) and anterior or Morgagni hernia (1% to 6%) [1]. Incidence of traumatic diaphragmatic hernia resulting from severe blunt or penetrating abdominal trauma varies from 0.8% to 5% [2]. Adult Bochdalek's hernias are very rare with less than hundred cases reported in the literature. A retrospective review found 22 patients with incidental, asymptomatic Bochdalek hernias out of 13,138 CT scans, which represents an incidence of 0.17% [3]. In adults this type may be asymptomatic and incidentally diagnosed on chest radiographs, or it may present with dyspnea, recurrent chest infections and gastrointestinal symptoms. Traumatic diaphragmatic hernias may occur due to blunt (68-75%) or penetrating (25-32%) abdominal traumas [4]. Diaphragmatic injuries are more common on left side as right hemi-diaphragm is protected by liver. Traumatic diaphragmatic hernia may have acute presentation in poly-trauma (may even present with hydro-pneumothorax with or without hollow viscous perforation) or they may present many years after initial injury [5]. Diaphragmatic eventration on the other hand is abnormal elevation of intact diaphragm due to congenital muscular hypoplasia or due to phrenic nerve injury. Diaphragmatic eventration is rare (incidence <0.05%), being more common in males. It can be unilateral or bilateral, but it usually involves the left hemi-diaphragm [6]. In Index patient neither past history of trauma was elicited nor past detail medical records available for confirmation. It is difficult to comment whether it was adult Bochdalek's hernia or post traumatic variety for which she was operated six year back and open abdominal

primary diaphragmatic repair was done. Patient developed hydro-pneumothorax on day three of conservative treatment after being admitted for breathlessness without any history of trauma and with absence of abdominal signs and symptoms. Even after contrast CT it was difficult to decide for particular surgical intervention (laparotomy). ICD tube was inserted due to suspected respiratory pathology along with diaphragmatic hernia. Management was delayed due to diagnostic dilemma and false signs of improvement after ICD placement. Cases also have been reported in literature with ICD insertion leading to iatrogenic perforation in patients with undiagnosed diaphragmatic hernia [7]. Our case had unique presentation of gastric ulcer perforating into left chest cavity through recurrent hernial sac giving rise to bilious hydro-pneumothorax. On laparotomy it was found that gastric ulcer was pathological and ICD tube was high above the hernia sac in chest cavity thus ruling out iatrogenic trauma.

CONCLUSION

A diagnosis of an adult diaphragmatic hernia should always be kept in mind in patients with overlapping abdominal and respiratory symptoms with or without history of trauma. Simple chest X-ray with Ryle's tube in-situ may help in diagnosis, however contrast enhanced CT scan and barium studies should be done in patients with doubtful complicated presentation and before planning any surgical intervention (e.g. ICD insertion). More Catastrophic presentation such as obstruction and strangulation of bowel loops including faeco-pneumothorax may be seen in patients with delayed post-traumatic diaphragmatic hernias. Detail history, clinical examination, appropriate radiological investigation and definitive surgical approach help in reducing morbidity and mortality in adult diaphragmatic hernia patients.

REFERENCES

- [1] Ameer K, Vikas M, TS Ramakrishnan, Samaresh S. Caecal perforation with faecal peritonitis – unusual presentation of Bochdalek hernia in an adult: a case report and review of literature. [PubMed Central]. *World J Emerg Surg.* 2009;4:16. [Published online 2009 May 6] Available from <http://www.ncbi.nlm.nih.gov/pmc/articles/PMC2685771>. doi: 10.1186/1749-7922-4-16.
- [2] Shailesh K, Santosh K, Shubhendu B, Sumit M, Priyadarshi D. An undiagnosed left sided traumatic diaphragmatic hernia presenting as small intestinal strangulation: A case report. [PubMed Central] *Int J Surg Case Rep.* 2013;4(5):446-48. [Published online 2013 Feb 24]. Available from <http://www.ncbi.nlm.nih.gov/pmc/articles/PMC3731691>. doi: 10.1016/j.ijscr.2013.02.006
- [3] Hamid KS, Rai SS, Rodriguez JA. Symptomatic Bochdalek Hernia in an Adult. [PubMed Central] *JSLs.* 2010;14(2):279-81. Available from <http://www.ncbi.nlm.nih.gov/pmc/articles/PMC3043584>. doi: 10.4293/108680810X12785289144719.
- [4] Ozkan OV, Semerci E, Yetim I, Davran R, Diner G, Paltaci I. Delayed diagnosis of traumatic diaphragmatic hernia may cause colonic perforation: a case report. [PubMed Central] *Cases J.* 2009;2:6863. [Published online 2009 Aug 19] Available from <http://www.ncbi.nlm.nih.gov/pmc/articles/PMC2769322> doi: 10.4076/1757-1626-2-6863
- [5] Morjaria R, Al-Gailani H, Afzal S, Sabir S, Salman S. Twenty-seven year old man presenting with a strangulated diaphragmatic hernia eight years after the initial injury. [PubMed Central] *BMJ Case Rep.* 2010;2010: bcr09.2009.2288. [Published online 2010 Mar 4.] Available from <http://www.ncbi.nlm.nih.gov/pmc/articles/PMC3028218>. doi: 10.1136/bcr.09.2009.2288
- [6] Aikaterini NV, Andreas M, Paul Z, Nikolaos M, Aikaterini St, Nikolaos K, et al. Video assisted thoracoscopic plication of the left hemidiaphragm in symptomatic eventration in adulthood. [PubMed Central] *J Thorac Dis.* 2012;4(Suppl 1):6-16. Available from <http://www.ncbi.nlm.nih.gov/pmc/articles/PMC3537423> doi: 10.3978/j.issn.2072-1439.2012.s001.
- [7] Wadhwa R, Ahmad Z, Kumar M. Delayed traumatic diaphragmatic hernia mimicking hydro-pneumothorax. [PubMed Central] *Indian J Anaesth.* 2014; 58(2): 186-9. Available from <http://www.ncbi.nlm.nih.gov/pmc/articles/PMC4050937>. doi: 10.4103/0019-5049.130825.

PARTICULARS OF CONTRIBUTORS:

1. Resident, Department of General Surgery, Government Medical College Miraj and P.V.P. Government Hospital, Sangli, Maharashtra, India.
2. Associate Professor, Department of General Surgery, Government Medical College Miraj and P.V.P. Government Hospital, Sangli, Maharashtra, India.
3. Associate Professor, Department of General Surgery, Government Medical College Miraj and P.V.P. Government Hospital, Sangli, Maharashtra, India.
4. Professor and Head, Department of General Surgery, Government Medical College Miraj and P.V.P. Government Hospital, Sangli, Maharashtra, India.

NAME, ADDRESS, E-MAIL ID OF THE CORRESPONDING AUTHOR:

Dr. Chandrakant Kamlesh Pancholi,
Room no 51, I.H.R Hostel, Sangli Civil Hospital, Sangli, Maharashtra 416 416, India.
E-mail: chiragpancholi007@gmail.com

FINANCIAL OR OTHER COMPETING INTERESTS: None.

Date of Submission: Oct 29, 2014
Date of Peer Review: Feb 27, 2015
Date of Acceptance: Mar 02, 2015
Date of Publishing: Apr 01, 2015