

Pulp Revascularization- It's your Future Whether you Know it or Not?

POOJA GUPTA DUDEJA¹, SHIBANI GROVER², DHIRENDRA SRIVASTAVA³, KRISHAN KUMAR DUDEJA⁴, VIVEK SHARMA⁵

ABSTRACT

Pulpal regeneration after tooth injury is not easy to accomplish. In teeth with immature apices and exposed vital pulp tissue, partial or complete pulpotomy is indicated to preserve pulpal function and allow continued root development. In many cases, injury causes loss of pulp vitality and arrested root development leading to a tooth with poor crown root ratio, a root with very thin walls, an open blunderbuss apex and development of apical pathosis.

The ideal treatment in such cases would be to obtain further root development and thickening of dentinal walls by stimulating the regeneration of a functional pulp dentin complex. This outcome has been observed after reimplantation in avulsed immature permanent teeth but has been thought impossible in a necrotic infected tooth.

This case series evaluates the efficacy of revascularization procedure in immature, non vital permanent teeth. Pulp regeneration was attempted in four patients at Department of Conservative Dentistry, ESIC Dental College, New Delhi using blood clotting approach. The cases were treated and followed up regularly at regular intervals ranging from 6 months to 3 years to assess the treatment response clinically and radiographically. The patients remained clinically asymptomatic with three out of four patients even responding positively to pulp responsiveness tests. Radiographic examination also revealed increased root formation and thickening of dentinal walls.

It was concluded that the triad of a disinfected canal, a matrix (blood clot) in to which new tissue could grow and an effective coronal seal produced the desirable environment for successful revascularization.

Keywords: Blood clotting, Immature/open apex, Non-vital teeth, Pulp revascularization

CASE DESCRIPTION

The dental pulp tissue is the most commonly injured and diseased tissue of the body [1]. In a tooth with necrotic pulp and open apex, conventional treatment modalities like nonsurgical endodontic therapy and apexification using Calcium hydroxide or even Mineral Trioxide Aggregate (MTA) are fraught with their own challenges. Fortunately, the dental pulp is also one of the most innervated and vascular tissues in the body with immense potential for regeneration [2]. The ideal outcome for such a tooth would be the regeneration of pulp-dentin complex in the canal space so as to allow continued normal root development. Even though regeneration of pulp tissue in a necrotic and infected tooth was earlier thought impossible, few case reports and case series have been published supporting this claim. Despite published outcomes, clinicians continue to question the predictability of the procedure and are unable to define a single regenerative protocol. Anecdotal evidence suggests moderate success rates and a need for more reliable protocols [3]. This case series is an effort to extend research in the same direction by evaluating the efficacy of revascularization via blood clotting procedure in immature and nonvital permanent teeth clinically as well as radiographically.

Patients in the age group as mentioned below [Table/Fig-1] reported to the Department of Conservative Dentistry, ESIC Dental College, Delhi with varying chief complaints like pain, discoloration of teeth, trauma, swelling etc. Brief history was taken and the patients were examined clinically as well as radiographically. The relevant findings are mentioned in [Table/Fig-1].

In all the cases, since the dentinal walls were very thin and the apex was completely open [Table/Fig-2a-5a], revascularization approach was considered to be better than apexification with $\text{Ca}(\text{OH})_2$ or preparing apical stop with MTA.

The technique adopted is similar to one adopted by Banchs and Trope [4]. Informed consent was taken and access cavity was made in the involved teeth without local anaesthesia and a No. 20 K-file

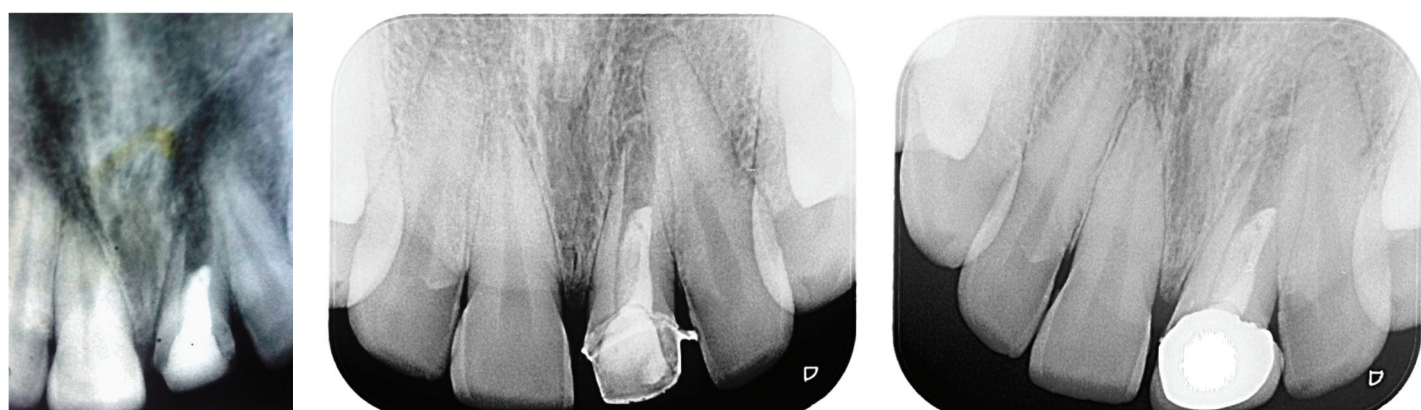
was placed gently into the canal. There was no pain or bleeding thus confirming the necrotic nature of the pulp. In some cases, pain or a sensation was experienced in the canal system suggesting the presence of some residual vital pulp tissue. Minimal instrumentation was done but the approximate length of the canal was estimated.

A needle was placed to within 1 mm of the apex taking care that it was loose inside the canal. The canal was slowly irrigated with 20 ml of 5.25% sodium hypochlorite (NaOCl) and 10 ml of 2% chlorhexidine solution [4,5]. The canal was dried with paper points, and a mixture of ciprofloxacin, minocycline and metronidazole paste as described by Hoshino et al., [6] was prepared by mixing with normal saline into a creamy consistency and placed into the canal with the help of lentulospiral. The access cavity was sealed with at least 4mm thick temporary restorative material (Cavit, ESPE, Seefeld, Germany).

The patients were called after four weeks. They were completely asymptomatic. The access was opened and the canal was again flushed with 10 ml of 5.25% NaOCl. The canal appeared clean with no signs of any inflammatory exudate. An H-file of 30 No. was introduced into the canal until vital tissue was felt into the canal space. The file was used to irritate the tissue gently to create some bleeding into the canal. The file was also carried beyond the apex and periapical tissue was also irritated to cause some bleeding into the canal space. When frank bleeding was evident at the cervical portion of the root canal system, a tight dry cotton pellet was inserted in the pulp chamber extending to a depth of 3-4 mm into the canal and was kept there for 15 min to allow clot formation in the apical two-thirds of the canal [4,7]. After 15 min MTA (DENTSPLY, Tulsa dental, Tulsa, OK) was carefully placed over the blood clot followed by a wet cotton pellet and cavit. The patients were then recalled after two weeks. As they were asymptomatic, the cavit and the cotton pellet were replaced with composite resin restoration. The patients were scheduled for recall appointment at three months, six months, one year, two year and three years for further clinical and radiographic evaluation [Table/Fig-2b,2c,3b-5b].

Case No.	Age/Sex	Chief complaint	Relevant history	Teeth involved	Pulp Responsiveness Tests (before revascularization)*	Intraoral Periapical Radiograph (IOPA) finding
1.	27yrs/ M	Pain and swelling in relation to upper front tooth	H/o trauma in childhood	#21	Both tests non-responsive	Wide open root apex with periradicular radiolucency and very thin lateral dentinal walls in tooth #21[Table/Fig-2a].
2.	17 yrs/M	Pain in upper front teeth. Clinical examination revealed Grade-I mobility in teeth #11, #21 and #22 (Composite resin splinting of upper arch from teeth #13 to #23 was therefore,done).	H/o trauma 2 months back	#21, #11	#21, #11: Both tests non- responsive	Periradicular radiolucency and open apices around roots of teeth #21, #11[Table/Fig-3a].
3.	30 yrs/M	Discoloured upper front tooth.	H/o fall in childhood.	# 21	Both tests non-responsive	Completely open apex, very thin dentinal walls, periradicular radiolucency surrounding #21[Table/Fig-4a].
4.	18 yrs/F	Discoloured upper front tooth following orthodontic treatment.	NA	#22	Both tests non-responsive	an open apex with a large radiolucency involving #22 [Table/Fig-5a].

[Table/Fig-1]: Brief history and clinical and radiographic findings relevant to the cases, *: electric pulp test (EPT) and heat test



[Table/Fig-2a]: Preoperative radiograph of 27-year old male showing wide open root apex and periradicular radiolucency in tooth #21. [Table/Fig-2b]: At 2 years follow up: significant increase in root length as well as increase in the thickness of lateral dentinal walls was observed [Table/Fig-2c]: At 3 years, IOPA Radiograph showed further increase in root length and thickness of lateral dentinal walls and complete resolution of periradicular radiolucency around tooth #21. The tooth responded positively to EPT at 16-20 reading

The clinical parameters recorded were:

- pain
- sinus tract
- periodontal status
- Response to pulp responsiveness tests (EPT and Heat Test).

The radiographic parameters recorded were:

- Apical closure of root
- Increase in the thickness of lateral dentinal walls
- Increase/Decrease in the size/ resolution of radiolucency.

RESULTS

The results can be summarized as under [Table/Fig-6]:

DISCUSSION

The outcome of the regenerative procedures depends on the type and duration of the infection, the state of the pulp at the time the treatment is started, the host and the size of the open apex [8]. Revascularization occurs most predictably in teeth with open apices and case reports largely from teeth with incomplete apical closures support this claim [4,7-11]. It has also been noted that reimplantation of avulsed teeth with an apical opening of approximately 1.1 mm demonstrate a greater likelihood of revascularization [12]. This finding suggests that revascularization of necrotic pulps with fully formed (closed) apices might require instrumentation of the tooth apex to approximately 1 to 2mm apical diameter to allow systemic bleeding into root canal systems [13].

All the cases presented here also involved immature and nonvital permanent teeth that might offer higher regenerative potential. The rich blood supply through the wide open apex can be a factor in

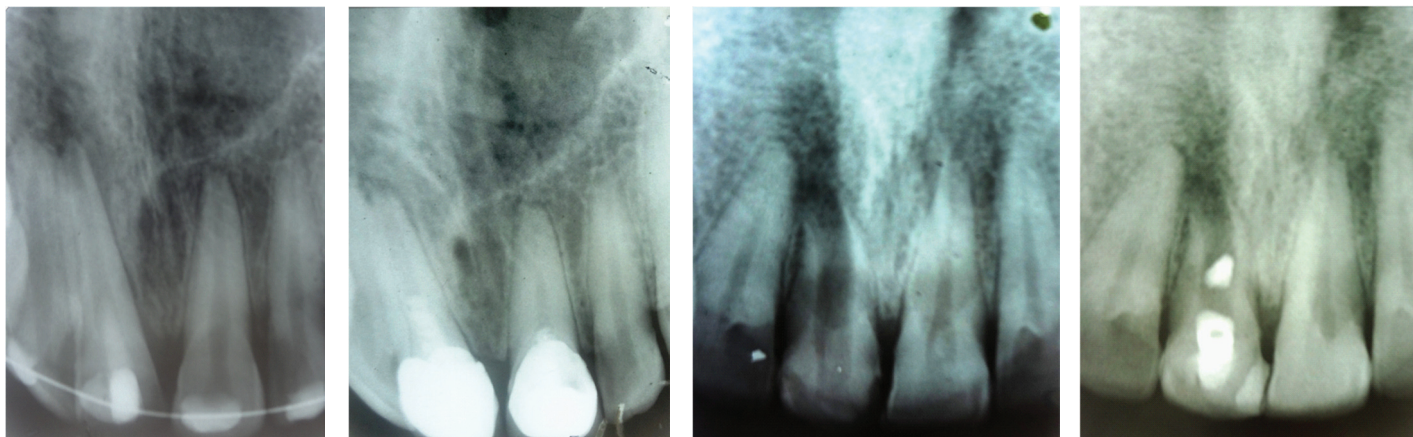
preserving or promoting vital pulp cells. To be precise, the immature (open) apex may facilitate the ingrowth of tissue into the root canal space and may be indicative of a rich source of mesenchymal stem cells of the apical papilla (SCAP) [14,15].

Age of the host may also play a significant role in the success of revascularization procedure, since some studies suggest that younger patients have a greater healing capacity or stem cell regenerative potential [15,16]. Our patients belonged to 17-30 years age group which can be considered favourable for success.

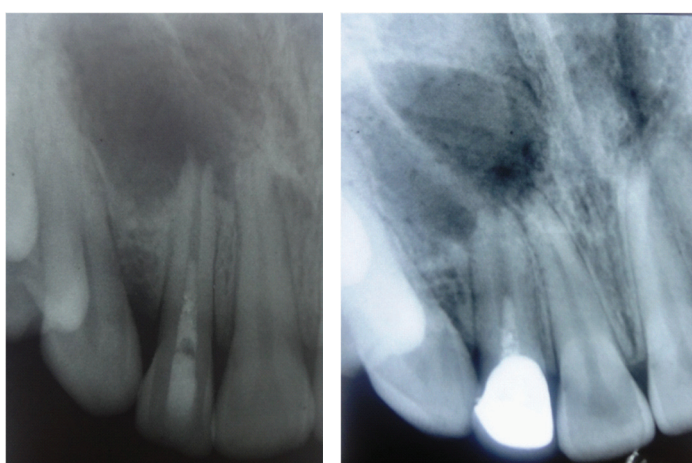
Another consistent feature in every case was the lack of instrumentation of dentinal walls. This was basically to prevent the potential fracture of the thin, incompletely developed roots. It also has the added benefit of avoiding generation of smear layer that could occlude the dentinal walls and tubules.

An important aspect of these cases is the use of intracanal irrigants (sodium hypochlorite and chlorhexidine) with placement of antibiotics (ciprofloxacin, metronidazole and minocycline paste) for few weeks. This combination of antibiotics effectively disinfects root canal systems [6,17,18] and increases revascularization of avulsed and necrotic teeth [19]. Since NaOCl alone cannot render the root surfaces totally clean, so chlorhexidine gluconate is added along with it because of its property of substantivity and antimicrobial effect. In short, canal disinfection is mainly done by chemical disinfection rather than chemomechanical disinfection.

The blood clot can be created by irritating any remaining vital pulp tissue in the canals by using endodontic probe in teeth with incomplete apical closure or by instrumenting the tooth beyond apex to approximately 1-2 mm to allow systemic bleeding into root canal system. The formation of blood clot yields a matrix (e.g. fibrin) that traps cells capable of initiating new tissue formation.



[Table/Fig-3a]: An IOPA radiograph of a 17-year-old male with H/o trauma two months back and Grade-I mobility in teeth # 11, #21, and #22. Note the periradicular radiolucency and open apices around roots of teeth # 21 and #11. Composite resin splinting was done from teeth #13 to # 23 in upper arch. Revascularization was first done in tooth #21 and later on in tooth #11 **[Table/Fig-3b]:** IOPA radiograph at 2 years follow-up shows almost complete resolution of periradicular radiolucency around both the central incisors (#11 and #21) and almost closure of open apices **[Table/Fig-4a]:** Preoperative IOPA Radiograph of a 30-year-old male shows wide open apex and periradicular radiolucency surrounding root of tooth #21. Note the presence of very thin dentinal walls and completely open apex **[Table/Fig-4b]:** Six months recall radiograph shows some evidence of root healing. The tooth responded positively to EPT at 40-45 value



[Table/Fig-5a]: Radiograph of an 18-year-old female after MTA packing in tooth #22. Note the large radiolucency and open apex involving tooth #22 **[Table/Fig-5b):** Six months recall radiograph shows increase in the thickness of lateral dentinal walls in tooth # 22 and decrease in the extent of radiolucency. The tooth also responded positively to heat test

One question that comes to mind is the origin of new pulp tissue. First of all, it is not clear whether the new tissue is pulp or not but case reports published till date do mention continued root development and restoration of the response to pulp testing methods [4]. Our three out of four cases also responded positively to thermal (heat test) and electric pulp tests.

One possibility is that few vital pulp cells remain in the apical portion of root canal even though most of the pulp is non-vital and infected. Cells must have an available supply of oxygen to survive, which is why, perhaps cells in the coronal portion of the root canal system would not survive under hypoxic conditions [13]. The rich blood supply through the wide open apex can be a factor in preserving or promoting vital pulp cells in the apical region. These cells then proliferate and differentiate into odontoblasts under the organizing influence of Hertwig's epithelial root sheath which is quite resistant to destruction even in the presence of inflammation [23]. These odontoblasts can then lay tertiary dentine at the apex and sides of root thus increasing root length and thickness of dentinal walls.

Case No.	Time of recall	Clinical	Radiographic	Response to pulp responsiveness tests
1.	6 months, 1 year, 2 years, 3 years	Asymptomatic	At 2 years : significant increase in root length as well as increase in the thickness of lateral dentinal walls [Table/Fig-2b]. At 3 years: IOPA showed further increase in root length and thickness of lateral dentinal walls and complete resolution of periradicular radiolucency [Table/Fig-2c].	+ve to EPT at 16-20 reading.
2.	6 months, 1 year and 2 years	Asymptomatic	Increasing resolution of periradicular radiolucency and almost closure of open apices [Table/Fig-3b].	--
3.	3 months, 6 months	Asymptomatic	Increase in root length and slight closure of root apex [Table/Fig-4b].	At 6 months recall visit, the tooth responded positively to EPT (though it was at a high value i.e. around 40-45).
4.	3 months, 6 months	Asymptomatic	At 6 months increase in thickness of lateral dentinal walls [Table/Fig-5b].	+ve response to Heat test.

[Table/Fig-6]: Summary of results according to the time of recall and related clinical and radiographic findings

Because revascularization in the form of continued root development and increase in the thickness of dentinal walls has been shown to be successful only in teeth with disinfected root canal systems, an important aspect is to create a bacteria tight coronal seal to inhibit bacterial invasion into the pulp space before revascularization can take place. We used a double seal with MTA that has been demonstrated to have excellent sealing ability to a level below CEJ covered by bonded composite resin in the access opening [20]. The placement of MTA creates a hard barrier at its contact point with the blood clot and also provides signalling molecules for the growth of stem cells [21,22].

The second possibility is that the radiographic evidence of hard tissue deposition may be because of the ingrowth of dentin, cementum or bone [24,25].

There are several advantages of revascularization via blood clotting method. Firstly the technique is simple and can be completed using currently available materials and medicaments (cost effective). Moreover, we can minimise the risk of immune rejection and microbial transmission by using patient's own blood cells instead of tissue engineered constructs to replace pulp [13]. The treatment time is reduced considerably.

However, there are certain shortcomings which warrant that more clinical studies with long term results are required to correctly

understand the potential of this technique. Complete obliteration of the canal is one possibility which can compromise the prognosis of future endodontic treatment, if required. In case, post and core is the final restorative treatment plan, revascularization is not the correct treatment option because the vital tissue in the apical two-thirds of the canal cannot be violated for post placement [22]. Moreover, the fibrin clot rationale behind revascularization is quite unreliable because the concentration and composition of cells trapped in the fibrin clot is unpredictable and tissue engineering is based on the delivery of effective concentration and composition of cells to restore function. It is quite possible that variations in cell concentration and composition especially in older patients (where circulating stem cells may be lower) may lead to variations in treatment outcome [13].

CONCLUSION

The ideal clinical outcome of a regenerative procedure is a non symptomatic tooth that never needs retreatment. Till date, the pulp revascularization has been mainly tried in young patients as they have high stem cell population and teeth with open apices. But for regenerative procedures to be more widely available and more predictable (fibrin clot mechanism is extremely unreliable but still most commonly used), alternative methods of regeneration will have to be considered. These include use of plasma derived fibrin clots as scaffolds; injecting autologous post natal stem cells obtained from multiple tissues like buccal mucosal biopsy, umbilical cord stem cells etc. into disinfected root canal systems after apex is opened etc. However, these alternative methods must be investigated using preclinical in vitro studies, animal studies and finally clinical trials before they can deliver full benefits to mankind.

REFERENCES

- [1] Laino G, d' Aquino R, Graziano A, Lanza V, Carinci F, Naro F, et al. A new population of human adult dental pulp stem cells: a useful source of living autologous fibrous bone tissue (LAB). *J Bone Miner Res.* 2005;20:1394-402.
- [2] Murray PE, Garcia Godoy C, Garcia Godoy F. How is the biocompatibility of dental materials evaluated? *Med Oral Pathol Oral Cir Bucal.* 2007;12:e258-66.
- [3] Todd M Geisler. Clinical Considerations for Regenerative Endodontic Procedures. In: Sami MA Chogle and Harold E. Goodis, ed. *Dent Clin N Am.* 2012;56:603-26.
- [4] Banchs F, Trope M. Revascularization of Immature Permanent Teeth with Apical Periodontitis: New Treatment Protocol? *Journal of Endodontics.* 2004;30(4):196-200.
- [5] Iwaya S, Ikawa M, Kubota M. Revascularization of an immature permanent tooth with apical periodontitis and sinus tract. *Dent Traumatol.* 2001;17:185-87.
- [6] Hoshino E, Kurihara-Ando N, Sato I, Uematsu H, Sato M, Kota K, Iwaku M. In-vitro antibacterial susceptibility of bacteria taken from infected root dentin to a mixture of ciprofloxacin, metronidazole and minocycline. *International Endodontic Journal.* 1996; 29:125-30.
- [7] Shah N, Logani A, Bhaskar U, Aggarwal V. Efficacy of Revascularization to induce Apexification/ Apexogenesis in Infected, Nonvital, Immature teeth: A Pilot Clinical Study. *Journal of Endodontics.* 2008;34(8):919-25.
- [8] Cotti E, Mereu M, Lusso D. Regenerative Treatment of an Immature Traumatized Tooth with Apical Periodontitis: Report of a Case. *Journal of Endodontics.* 2008;34(5):611-16.
- [9] Rule DC, Winter GB. Root growth and apical repair subsequent to pulpal necrosis in children. *British Dental Journal.* 1966;120:586-90.
- [10] Hargreaves KM, Geisler T, Henry M, Wang Y. Regeneration potential of the young permanent tooth: what does the future hold? *J Endod.* 2008;34:S51-56.
- [11] Torabinejad T, Turman M. Revitalization of tooth with necrotic pulp and open apex by using platelet rich plasma: a case report. *J Endod.* 2011;37:265-68.
- [12] Kling M, Cvek M, Mejare I. Rate and predictability of pulp revascularization in therapeutically implanted permanent incisors. *Endod Dent Traumatol.* 1986;2:83-89.
- [13] Murray PE, Godoy GF, Hargreaves KM. Regenerative Endodontics: A Review of Current Status and a Call for Action. *Journal of Endodontics.* 2007;33(4):377-90.
- [14] Huang GT, Sonoyama W, Liu Y, Liu H, Wang S, Shi S. The hidden treasure in apical papilla: the potential role in pulp/ dentin regeneration and bioroot engineering. *J Endod.* 2008;34:645.
- [15] Hargreaves KM, Law AS. Regenerative Endodontics. In: Hargreaves KM and Cohen S, editors. *Pathways of the Pulp*, 10 ed. St. Louis, Missouri: *Mosby*; 2011. 602-19.
- [16] D'ippolito G, Schiller PC, Ricordi C, Roos BA, Howard GA. Age- Related osteogenic potential of mesenchymal stromal stem cells from human vertebral bone marrow. *J Bone Miner Res.* 1999;14:1115.
- [17] Windley W III, Teixeira F, Levin L, Sigurdsson A, Trope M. Disinfection of immature teeth with a triple antibiotic paste. *J Endod.* 2005; 31: 439-43.
- [18] Sato I, Ando-Kurihara N, Kota K, Iwaku M, Hoshino E. Sterilization of infected root-canal dentin by topical application of a mixture of ciprofloxacin, metronidazole and minocycline in situ. *International Endodontic Journal.* 1996; 29:118-24.
- [19] Ritter AL, Ritter AV, Murrah V, Sigurdsson A, Trope M. Pulp revascularization of replanted immature dog teeth after treatment with minocycline and doxycycline assessed by Laser Doppler Flowmetry, radiography, and histology. *Dental Traumatology.* 2004;20:75-84.
- [20] Bates CF, Carnes DL, del Rio CE. Longitudinal sealing ability of mineral trioxide aggregate as a root end filling material. *Journal of Endodontics.* 1996;22:575-78.
- [21] Torabinejad M, Parirokh M. Mineral Trioxide Aggregate: a comprehensive literature review- Part II: leakage and biocompatibility investigations. *J Endod.* 2010;36:196-202.
- [22] Torabinejad M, Abu-Tahun I. Management of teeth with necrotic pulps and open apices. *Endodontic Topics.* 2012;23:105-30.
- [23] Yousef Saad A. Calcium Hydroxide and apexogenesis. *Oral Surgery Oral Medicine Oral Pathology Oral Radiology.* 1988;66:499-501.
- [24] Chueh L-H, Huang GT-J. Immature teeth with periradicular periodontitis or abscess undergoing apexogenesis: a paradigm shift. *Journal of Endodontics.* 2006;32:1205-13.
- [25] Seo BM, Miura M, Gronthos S, Bartold PM, Batouli S, Brahimi J, et al. Investigation of multipotent postnatal stem cells from human periodontal ligament. *Lancet.* 2004;364:149-55.

PARTICULARS OF CONTRIBUTORS:

1. Associate Professor, Department of Conservative Dentistry, ESIC Dental College and Hospital, Sector 15, Rohini, Delhi, India.
2. Professor and Head, Department of Conservative Dentistry, ESIC Dental College and Hospital, Sector 15, Rohini, Delhi, India.
3. Professor and Dean, Department of Oral and Maxillofacial Surgery, ESIC Dental College and Hospital, Sector 15, Rohini, Delhi, India.
4. Formerly Professor, Department of Prosthodontics, Krishna Dental College, Mohan Nagar, Ghaziabad India.
5. Assistant Professor, Department of Conservative Dentistry, ESIC Dental College and Hospital, Sector 15, Rohini, Delhi, India.

NAME, ADDRESS, E-MAIL ID OF THE CORRESPONDING AUTHOR:

Dr Krishan Kumar Dudeja,
A-345, Sector 47, Noida-201303, India.
E-mail : kdudeja@gmail.com

FINANCIAL OR OTHER COMPETING INTERESTS: None.

Date of Submission: **May 30, 2014**
Date of Peer Review: **Aug 27, 2014**
Date of Acceptance: **Sep 18, 2014**
Date of Publishing: **Apr 01, 2015**