

Received: 2014.10.06  
Accepted: 2014.11.10  
Published: 2015.05.11

# Surgical Treatment of Combined Posterior Root Tears of the Lateral Meniscus and ACL Tears

Authors' Contribution:

Study Design A  
Data Collection B  
Statistical Analysis C  
Data Interpretation D  
Manuscript Preparation E  
Literature Search F  
Funds Collection G

**ABEF 1 Fengyu Pan**  
**DF 2 Shan Hua**  
**CD 1 Zhuang Ma**

1 Department of Orthopedics, Chinese People's Liberation Army 107 Hospital, Yantai, Shandong, P.R. China  
2 Department of Radiology, Haigang Hospital, Yantai, Shandong, P.R. China

**Corresponding Author:** Fengyu Pan, e-mail: ytpfyf@163.com  
**Source of support:** Departmental sources

**Background:** The treatment of anterior cruciate ligament (ACL) rupture complicated with posterior lateral meniscus root (PLMR) tears remains controversial. The goal of this study was to evaluate clinical outcomes of PLMR tear re-fixation versus left untreated at the time of reconstruction.


**Material/Methods:** From August 2001 to January 2012, 31 patients who undergone repair of PLMR tears were evaluated and compared with a matched control group with untreated PLMR tears. Clinical evaluation consisted of the Lysholm scale, subjective International Knee Documentation Committee (IKDC) questionnaires, and radiographic evaluation with MRI.

**Results:** Regarding to the Lysholm score and the subjective questionnaire score, there were no statistical difference between the 2 groups. However, patients after operative treatment reach higher functional scores and lower rates of osteoarthritis (normal: group A, 80%, and group B, 48%, respectively) with statistical significance ( $P < 0.05$ ) compared to the matched control group.

**Conclusions:** Surgical and conservative treatment of the PLMR can both effectively improve knee function. However, a tendency towards higher functional scores and lower rates of osteoarthritis for patients with operative treatment was observed.

**MeSH Keywords:** Anterior Cruciate Ligament • Arthroscopes • Knee Injuries • Menisci, Tibial

**Full-text PDF:** <http://www.medscimonit.com/abstract/index/idArt/892661>

 1746

 3

 1

 37



## Background

Meniscus injuries are frequently reported concomitantly with ACL injury [1–3]. A recent study of Matheny et al. [4] revealed 3.5% of posterior lateral meniscus root (PLMR) tear with concomitant ACL rupture. The meniscus roots are the insertions of the anterior and posterior meniscal horns on the tibial plateau [5–7]. A radial tear in the posterior aspect of the lateral meniscus, where the meniscus attaches to the central tibial plateau, is called a “root tear” [3,8–10].

Most studies have reported increased degenerative changes in the knee after meniscus removal. In consideration of the importance of the meniscus, the current trend has been to repair as many meniscal tears as possible to preserve the meniscus. Ode et al. [11] studied the effect of a radial tear of PLMR. Their results indicated that a complete radial tear increased the lateral compartment contact pressure by a mean of 43% and decreased the lateral compartment contact area by a mean of 47%. Most of the published literature [12–15] involving posterior root tears has focused on medial meniscal root tears, not PLMR tears. Few recent reports have shown favorable short-term clinical results of treatment for PLMR tears. Ahn et al. [16] reported the results of all-inside side-to-side repair combined with ACL reconstruction in 25 patients. After a mean follow-up of 18 months, the mean subjective IKDC score and mean Lysholm score increased significantly from 67 and 62 preoperatively to 90 and 93 postoperatively.

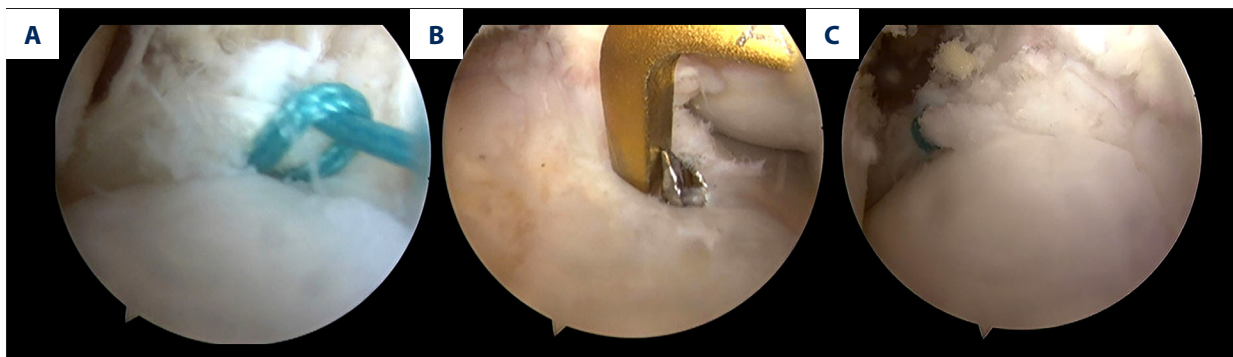
Furthermore, while PLMR tears are usually the result of acute injury at the time of an ACL tear, there is no reliable evidence at present to suggest that refixation of PLMR tears combined with ACL reconstructions could provide long-term clinical improvement. Therefore, we performed this retrospective study to evaluate the clinical outcomes of arthroscopic treatment for ACL injury associated with PLMR tears. We hypothesized that repair of PLMR tears combined with arthroscopic ACL reconstruction would result in satisfactory clinical outcomes.

## Material and Methods

A retrospective analysis was approved by the medical ethics committee of Haigang Hospital. Retrospective analysis from August 2001 to January 2012 showed that 1379 patients (1382 knee) who undergone arthroscopic ACL reconstruction surgery, including 172 patients who had undergone arthroscopic ACL concomitant PLMR tears. All radial tears or longitudinal tears in the root area around the posterior horn associated with ACL injury were included. Patients with medial meniscal tears; those with Outerbridge grade III or IV chondromalacia in any knee compartment; those with less than 2 years of follow-up and those who underwent additional procedures such as microfracture, chondroplasty and synovial shaving were excluded. Finally, there were 103 patients who had PLMR tears. Of the remaining 103 patients, 31 patients (Group A) had repair of the PLMR tears and had greater than 2 years of follow-up. A control group of patients (Group B) who had PLMR tears left untreated. The study group was matched with controls based on age at time of surgery, sex, body mass index (BMI), and time of follow-up after surgery.

The patients were operated on by one surgeon. The ACL reconstruction surgical technique has been described by Nebelung et al. [17]. In case of a PLMR tears, a transtibial pullout suture was performed [4]. PLMR refixation and ACL reconstruction were carried out (Figure 1).

Both the two groups carried out the same postoperative rehabilitation protocol. It was similar to ACL-reconstruction protocol, which included partial weight bearing for 2 weeks and the use of a knee brace. At postoperative weeks 2, medium frequency electric stimulation was used to the neuromuscular recovery two times a week for 20 minutes. The affected knee joint was permitted gradual increase in range of motion, which was initiated with a limited-motion brace, in which at least 90° of flexion was achieved during a 6-week postoperative period. This protocol prohibited severe flexion or squatting until postoperative week 12. Depending on muscle strength of



**Figure 1.** (A) Tensioned double loop suture throughout the medial portal. (B) The tibial tunnel was performed by using a tibial ACL aimer. (C) the lateral meniscus root had been repaired.

**Table 1.** General characteristics of subjects.

Characteristic	Group A	Group B	P value
Case (knee)	31 (31)	31 (31)	0.64
Gender (male/female)	21/10	21/10	0.58
Mean age (years)	28±10	27±11	0.98
Range	18–38	16–38	
Laterality (right/left)	16/15	16/15	0.65
Injury reason (n)			
Traffic accident injury	8	8	
Sprain	21	22	
Unknown	2	1	
follow-up time	3.1±0.8	3.2±0.9	0.71
Preoperative evaluation			
Lysholm scale	59.03±19.17	58.35±18.14	0.87
IKDC score	62.08±19.21	63.27±18.73	0.89

the operated limb, light activities were allowed after 3 months from the operation and then exercise intensity was gradually increased. Finally, sports exercises and heavy labor were permitted after 9 months.

Follow-up visits were performed at 3, 6, 12 and 24 months postoperatively and at the endpoint of follow-up. All patients underwent knee magnetic resonance imaging (MRI) as part of the routine preoperative evaluation. The following several assessment methods were used for evaluation: the Lysholm scale, subjective International Knee Documentation Committee (IKDC) questionnaires, and radiographic evaluation with MRI. In the subjective IKDC questionnaire score, a score of 95–100 was graded excellent, 90–94 was excellent, 80–89 was good, 70–79 was fair, and less than 70 was poor, according to IKDC subjective classification. All radiographs was evaluated by the International Cartilage Repair Society (ICRS) (18) standard classification system.

Statistical analysis was performed with SPSS 19.0 software. Preoperative and postoperative indices for each group were compared by a paired *T* test. Independent-samples *T* tests and Mann-Whitney *U* test were used for group comparison. Chi-square was used on ratio comparison. *P*<0.05 was defined as a significant difference.

## Results

Patient demographics are shown in Table 1. There was no statistically significant difference between two groups, in terms of sex, body mass index (BMI), age, and follow-up time. There were no postoperative superficial wound infections or joint stiffness.

Follow-up data is presented in Tables 2 and 3. At the last follow-up, all patients had a significant improvement in terms of knee function scores, compared to the preoperative status.

### Functional outcomes

In respect of Lysholm scale, no statistically significant differences were found between the groups A and B at 24 months postoperatively (Table 2). There was a significant increase in the IKDC scores between preoperative and postoperative results in both groups. For group A, at 24 months postoperatively, 25 cases were graded excellent, 4 good, 2 fair and the excellent and good rates were 93.5%. For group B, 23 cases were rated excellent, 5 good, 3 fair, and the excellent and good ratio was 93% at 24 months.

### Radiographic evaluation

The ICRS radiographic grading in group A found 25 of 31 (80%) normal, 5 of 31 (16%) mild, 1 (3%) moderate versus 15 (48%) normal, 6 (19%) with mild, 8 (26%) moderate, and 2 (7%) poor changes in the control group. There was significant statistical difference between those with mild or no changes in either A or B group (*P*=0.003).

## Discussion

In the study, we found no significant postoperative differences between both groups for the Lysholm scale or subjective IKDC scores. However, a significant difference in the development of osteoarthritis between both groups was found with MRI. The most important finding of our study was a tendency toward improved outcomes after repair of PLMR.

**Table 2.** The follow-up data of group A and group B (mean ± standard deviation).

	Preoperative	Postoperative (2y)	P value	P value*
Lysholm scale				
Group A	59.03±19.17	92.34±6.32	<0.001	>0.05
Group B	58.35±18.14	87.77±11.99	<0.001	
IKDC score				
Group A	62.08±19.21	90.06±8.59	<0.001	>0.05
Group B	63.27±18.73	86.86±11.47	<0.001	

\* The comparison of outcomes between the two groups postoperatively.

**Table 3.** ICRS of group A and group B.

ICRS classification	Group A	Group B
0	25	15
1	5	6
2	1	8
3	0	2
4	0	0

Posterior lateral meniscus root tears should be more noticed relevant by orthopaedic surgeons because PLMR tears are frequently associated with ACL tears. PLMR tears effectively dysfunction the meniscus as a load-bearing structure by reducing the capacity to resist hoop stresses [19,20]. Several studies suggest that these injuries increase tibiofemoral contact pressure in the lateral compartment by approximately 50% [11,21,22]. Thus, surgical repair of PLMR tears is very important. Non-surgical treatment and arthroscopic repair have been proposed to treat PLMR tears [21,23–27].

For PLMR tears, the best treatment remains still a subject of controversy. Nonoperative treatment may result in similar results compared with surgical treatment. Shelbourne et al. [21] in their study found no statistical difference for the overall IKDC subjective score between patients with combined ACL and PLMR tears with a matched cohort of patients with an isolated ACL tear. The ACL reconstructions were performed in all patients, whereas the PLMRT was left untreated. However, Patients with PLMR tears showed a significantly lower IKDC stiffness score and significantly more joint space narrowing of the lateral compartment.

There are several different treatment options for PLMR tears. The most commonly used operative techniques for repair of PLMRTs are a side-to-side suture technique or a transtibial pull-out suture [4,16,23–25,28–34]. Anderson et al. [24] reported that 24 patients after combined ACL reconstruction and PLMR

repair by side-to-side suture (n=8) or transtibial pullout repair (n=16) resulted in 92% of repairs functioning successfully. In this study, nonoperative treatment was compared with operative treatment to PLMR tears. The results indicated that patients after operative treatment tend to reach a higher functional score and lower rates of osteoarthritis compared to conservative treatment.

The technique of refixation of PLMR in this study was to reattach the meniscus by placing sutures through the meniscus root and pulling them through the tibial ACL tunnel. Bhatia et al. [27] stated several unique disadvantages of this technique, including (a) the need for drilling bone tunnels that may potentially interfere with concomitant ligament reconstruction, (b) an increased risk for suture abrasion within the bony tunnel during knee motion before meniscal healing, and (c) an increased possibility of creep within the suture itself, decreasing the strength of the repair. However, there are also several disadvantages of anchor repair, including anchor pullout with subsequent failure of fixation and technical difficulty associated with the procedure [35]. This study suggested improved outcomes at the last follow up, but long-term outcomes of the particular surgical technique performed in this study for the posterior roots remained unknown. Therefore, there is a clear need for longer term data investigating surgical techniques, and outcomes of repair. Many biomechanical studies have reported that root repair can restore knee biomechanics to normal levels [36,37]. Repair of the PLMR should be attempted whenever possible in order to restore the hoop tension of the lateral meniscus and to prevent premature osteoarthritis.

There were several limitations in this study. First, the inherent limitations of retrospective analysis might have weakened the accuracy of this study. Secondly, the number of patients recruited was small and perhaps the differences between surgery and conservative treatment were minimal so a greater sample was required to detect subtle variations. Finally, the follow up could be considered as being relatively short since it was limited to 2 year. Perhaps, additional improvement in the functional status could be detected with longer periods of follow up.

## Conclusions

Although there was no significant difference between conservative and operative treatment for patients after ACL injury associated with PLMR tears, a tendency towards improved functional scores and lower osteoarthritis rates for patients with operative treatment was observed. In view of several limitations of this study, well-designed randomized controlled studies will be needed for the future.

## References:

1. Bellabarba C, Bush-Joseph CA, Bach BR Jr: Patterns of meniscal injury in the anterior cruciate-deficient knee: a review of the literature. *Am J Orthop (Belle Mead NJ)*, 1997; 26: 18–23
2. Wickiewicz TL: Meniscal injuries in the cruciate-deficient knee. *Clin Sports Med*, 1990; 9: 681–94
3. Petrofsky JS, Laymon M, Lee H: Effect of heat and cold on tendon flexibility and force to flex the human knee. *Med Sci Monit*, 2013; 19: 661–67
4. Forkel P, Petersen W: Posterior root tear fixation of the lateral meniscus combined with arthroscopic ACL double-bundle reconstruction: technical note of a transosseous fixation using the tibial PL tunnel. *Arch Orthop Trauma Surg*, 2012; 132: 387–91
5. Brody JM, Hulstyn MJ, Fleming BC, Tung GA: The meniscal roots: gross anatomic correlation with 3-T MRI findings. *Am J Roentgenol*, 2007; 188: W446–50
6. Johannsen AM, Civitaresse DM, Padalecki JR et al: Qualitative and quantitative anatomic analysis of the posterior root attachments of the medial and lateral menisci. *Am J Sports Med*, 2012; 40: 2342–47
7. Johnson DL, Swenson TM, Livesay GA et al: Insertion-site anatomy of the human menisci: gross, arthroscopic, and topographical anatomy as a basis for meniscal transplantation. *Arthroscopy*, 1995; 11: 386–94
8. Allaire R, Muriuki M, Gilbertson L, Harner CD: Biomechanical consequences of a tear of the posterior root of the medial meniscus. Similar to total meniscectomy. *J Bone Joint Surg Am*, 2008; 90: 1922–31
9. Brody JM, Lin HM, Hulstyn MJ, Tung GA: Lateral meniscus root tear and meniscus extrusion with anterior cruciate ligament tear. *Radiology*, 2006; 239: 805–10
10. Ozkoc G, Circi E, Gonc U et al: Radial tears in the root of the posterior horn of the medial meniscus. *Knee Surg Sports Traumatol Arthrosc*, 2008; 16: 849–54
11. Ode GE, Van Thiel GS, McArthur SA et al: Effects of serial sectioning and repair of radial tears in the lateral meniscus. *Am J Sports Med*, 2012; 40: 1863–70
12. Umans H, Morrison W, DiFelice GS et al: Posterior horn medial meniscal root tear: the prequel. *Skeletal Radiol*, 2014; 43: 775–80
13. Guermazi A, Hayashi D, Jarraya M et al: Medial posterior meniscal root tears are associated with development or worsening of medial tibiofemoral cartilage damage: the multicenter osteoarthritis study. *Radiology*, 2013; 268: 814–21
14. Lee JH, Lim YJ, Kim KB et al: Arthroscopic pullout suture repair of posterior root tear of the medial meniscus: radiographic and clinical results with a 2-year follow-up. *Arthroscopy*, 2009; 25: 951–58
15. Lee YG, Shim JC, Choi YS et al: Magnetic resonance imaging findings of surgically proven medial meniscus root tear: tear configuration and associated knee abnormalities. *J Comput Assist Tomogr*, 2008; 32: 452–57
16. Ahn JH, Lee YS, Yoo JC et al: Results of arthroscopic all-inside repair for lateral meniscus root tear in patients undergoing concomitant anterior cruciate ligament reconstruction. *Arthroscopy*, 2010; 26: 67–75
17. Nebelung W, Becker R, Merkel M, Ropke M: Bone tunnel enlargement after anterior cruciate ligament reconstruction with semitendinosus tendon using Endobutton fixation on the femoral side. *Arthroscopy*, 1998; 14: 810–15
18. Brittberg M, Winalski CS: Evaluation of cartilage injuries and repair. *J Bone Joint Surg Am*, 2003; 85-A(Suppl.2): 58–69
19. Greis PE, Bardana DD, Holmstrom MC, Burks RT: Meniscal injury: I. Basic science and evaluation. *J Am Acad Orthop Surg*, 2002; 10: 168–76
20. Lee H, Petrofsky JS, Daher N et al: Anterior cruciate ligament elasticity and force for flexion during the menstrual cycle. *Med Sci Monit*, 2013; 19: 1080–88
21. Shelbourne KD, Roberson TA, Gray T: Long-term evaluation of posterior lateral meniscus root tears left *in situ* at the time of anterior cruciate ligament reconstruction. *Am J Sports Med*, 2011; 39: 1439–43
22. Wei LC, Gao SG, Xu M et al: A novel hypothesis: the application of platelet-rich plasma can promote the clinical healing of white-white meniscal tears. *Med Sci Monit*, 2012; 18: HY47–50
23. Ahn JH, Lee YS, Chang JY et al: Arthroscopic all inside repair of the lateral meniscus root tear. *Knee*, 2009; 16: 77–80
24. Anderson L, Watts M, Shapter O et al: Repair of radial tears and posterior horn detachments of the lateral meniscus: minimum 2-year follow-up. *Arthroscopy*, 2010; 26: 1625–32
25. Vyas D, Harner CD: Meniscus root repair. *Sports Med Arthrosc*, 2012; 20: 86–94
26. Petersen W, Zantop T: [Avulsion injury to the posterior horn of the lateral meniscus. Technique for arthroscopic refixation]. *Unfallchirurg*, 2006; 109(11): 984–87 [in German]
27. Bhatia S, LaPrade CM, Ellman MB, LaPrade RF: Meniscal Root Tears: Significance, Diagnosis, and Treatment. *Am J Sports Med*, 2014; 42(12): 3016–30
28. Kenny C: Arthroscopic repair of avulsion of the posterior root and body of the lateral meniscus: a twenty-year follow-up. A case report. *J Bone Joint Surg Am*, 2009; 91: 2932–36
29. Nicholas SJ, Golant A, Schachter AK, Lee SJ: A new surgical technique for arthroscopic repair of the meniscus root tear. *Knee Surg Sports Traumatol Arthrosc*, 2009; 17: 1433–36
30. Rosslenbroich SB, Borgmann J, Herbert M et al: Root tear of the meniscus: biomechanical evaluation of an arthroscopic refixation technique. *Arch Orthop Trauma Surg*, 2013; 133: 111–15
31. Shino K, Hamada M, Mitsuoka T et al: Arthroscopic repair for a flap tear of the posterior horn of the lateral meniscus adjacent to its tibial insertion. *Arthroscopy*, 1995; 11: 495–98
32. Mardani-Kivi M, Madadi F, Keyhani S et al: Antero-medial portal vs. trans-tibial techniques for drilling femoral tunnel in ACL reconstruction using 4-strand hamstring tendon: a cross-sectional study with 1-year follow-up. *Med Sci Monit*, 2012; 18(11): CR674–79
33. Cerminara AJ, LaPrade CM, Smith SD et al: Biomechanical Evaluation of a Trans-tibial Pull-out Meniscal Root Repair: Challenging the Bungee Effect. *Am J Sports Med*, 2014; 42(12): 2988–95
34. LaPrade CM, Jansson KS, Dornan G et al: Altered tibiofemoral contact mechanics due to lateral meniscus posterior horn root avulsions and radial tears can be restored with *in situ* pull-out suture repairs. *J Bone Joint Surg Am*, 2014; 96: 471–79
35. Kim JH, Chung JH, Lee DH et al: Arthroscopic suture anchor repair versus pullout suture repair in posterior root tear of the medial meniscus: a prospective comparison study. *Arthroscopy*, 2011; 27: 1644–53
36. Marzo JM, Gurske-DePerio J: Effects of medial meniscus posterior horn avulsion and repair on tibiofemoral contact area and peak contact pressure with clinical implications. *Am J Sports Med*, 2009; 37: 124–29
37. Schillhammer CK, Werner FW, Scuderi MG, Cannizzaro JP: Repair of lateral meniscus posterior horn detachment lesions: a biomechanical evaluation. *Am J Sports Med*, 2012; 40: 2604–9

## Competing interests

The authors declare that they have no competing interests.

## Acknowledgement

We would like to thank Qing Wu for collecting the clinical data.