

A Prospective, Randomized, Double-Blind, Placebo-Controlled Clinical Trial Comparing the Efficacy of Anti-edema Drugs for Edema Control in Orthognathic Surgery Using Digitizer 3-D to Measure Facial Swelling

U. Tozzi · V. Santillo · G. P. Tartaro ·
A. Sellitto · G. R. Gravino · M. Santagata

Received: 26 February 2014 / Accepted: 12 August 2014 / Published online: 4 September 2014
© The Association of Oral and Maxillofacial Surgeons of India 2014

Abstract

Introduction Orthognathic surgery involves making several osteotomies. Any osteotomies leads to varying degrees of post-operative swelling. The aim of this study was to evaluate the effectiveness of anti-edema drugs for the control of edema, using Digitizer 3D™ for measuring soft-tissue thickness, in patients who underwent bimaxillary-orthognathic surgery.

Materials and Methods In this double-blinded, randomized, control trial, 24 patients (study group: 12 patients, control group: 12 patients) in whom bimaxillary orthognathic surgery was indicated, were included in this study. All swelling measurements were expressed as total 3-D area of the landmarks (cm²) in T0 pre-operative, T1 first day after surgery, T2 fourth day after surgery, T3 4 months after surgery. For each patient we compared, by adding left and right area, the increase of swelling between T1–T0, T2–T0 and T1–T3.

Results The differences T0–T1 are highly significant ($p < 0.01$) between group 1 or study group (treated with Venoplant®) and group 2 (control group); the differences T0–T2 are significant ($p < 0.05$) between group 1 (treated with Venoplant®) and group 2 (control group). The

differences T1–T3 are significant ($p < 0.05$) between group 1 (treated with Venoplant®) and group 2 (control group).

Discussion The present study suggests that Venoplant® significantly decreases postoperative edema in orthognathic surgery, thus precluding long-term corticosteroid use.

Keywords Orthognathic surgery · Edema · Anti-edema drugs · Digitizer 3-D

Introduction

Orthognathic surgery involves making several osteotomies in order to reposition the jaw in the right position. Any osteotomy, which involves the reflection of a full thickness mucoperiosteal flap, leads to varying degrees of post-operative swelling. An extensive swelling can compromise the surgical outcome as well as patient recovery and the airway [1].

Several methods have been developed to measure facial soft tissue thickness in cadavers and in live patients [2]. Traditionally, facial soft tissue measurements have been studied using the needle depth probing method on cadavers [3]. Several imaging-based methods for measuring living facial soft-tissue thickness have been reported [4–9].

In the present study a MakerBot® Digitizer 3D™ was used to assess accurate volume measurements.

In maxillofacial surgery, various methods are used to decrease postoperative swelling, including pressure dressings, ice packs, and placement of drains. Another reported method to decrease postoperative edema in orthognathic surgery is using the endoscopic approach for ramus osteotomy [10]. Medical management of swelling in orthognathic surgery is confined mainly to the use of steroids or

U. Tozzi · V. Santillo · G. P. Tartaro · M. Santagata
Multidisciplinary Department of Medical and Dental Specialties,
Oral and Maxillofacial Surgery Unit, AOU – SUN (Second
University of Naples), Naples, Italy

U. Tozzi (✉)
Via P. Riversono, 102, 81031 Aversa, CE, Italy
e-mail: umbtozzi@gmail.com

A. Sellitto · G. R. Gravino
Department of Industrial and Information Engineering, SUN
(Second University of Naples), Aversa, Italy

non-steroidal anti-inflammatory drugs. The use of systemic enzyme therapy (SET) for edema control in orthognathic surgery is not well established in the literature [11].

We used in this study tablets containing active ingredients (Diosmin, Coumarin, Centella: Venoplant[®]) that promote a physiological improvement of microcirculation and trophism of capillary tone after traumatology.

The aim of this study was to evaluate the effectiveness of anti-edema drugs for the control of edema, using Digi-tizer 3D[™] for measuring soft-tissue thickness, in patients who underwent bimaxillary orthognathic surgery.

Materials and Methods

Patients

In this double-blinded, randomized, control trial, 24 patients (study group: 12 patients, control group: 12 patients) in whom bimaxillary orthognathic surgery was indicated, were included.

Before surgery each patient alternatively was randomly included in the study group (treated with Venoplant[®] and corticosteroid) or in the control group (treated with corticosteroid).

This study was in accordance with the ethical standards and all participants signed an informed consent agreement.

Inclusion criteria were as follows: patients selected had no preexisting medical conditions or medications that would influence their ability to undergo surgery or alter their wound healing after surgery.

All cases were diagnosed as skeletal Class III including mandibular prognathism and/or maxillary retrognathism on the basis of a lateral cephalogram analysis and the patients underwent orthognathic surgery.

The study group consisted of 9 men (average age 18–34 years) and 15 women (average age 19–27 years) with Class III malocclusion.

Control groups consisted of 3 men (average age 18–30 years) and 9 women (average age 20–27 years) and without drug assumption.

Tablets

Venoplant[®] tablets (Aesculapius, Brescia, Italy) contains Diosmin 300 mg, Coumarin in sweet clover tit. 25 %, tri-terpenes in Centella tit. 45 %.

Diosmin is a flavanoide used to improve the tone of venous vessels, reduce excessive microvascular permeability decrease the formation of edema.

Coumarin in sweet clover stimulates the action of proteolytic enzymes in macrophages, which are the main cause of edema.

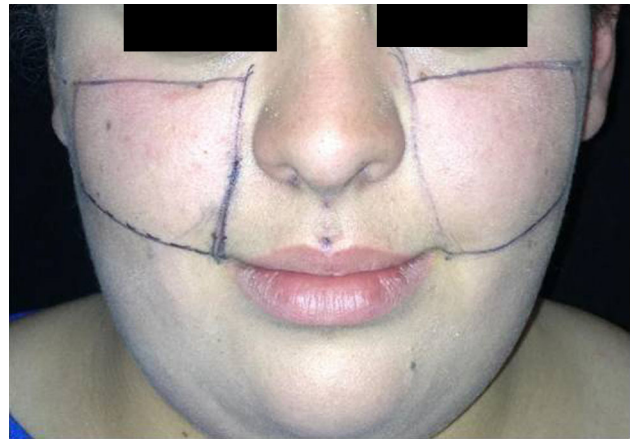


Fig. 1 Area landmarks, frontal view

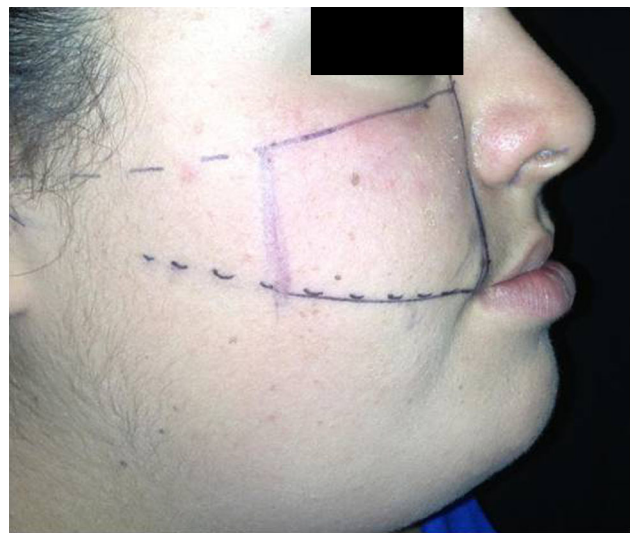

Fig. 2 Area landmarks, lateral view

Centella is a plant with substances that stimulate the connective tissue trophism and control microvascular permeability.

All patients in the 2 groups received corticosteroids for 2 days (betamethasone f 4 mg ev \times 2/day 1, betamethasone f 4 mg ev/day 2). In addition, patients in the study group received Venoplant[®] (1 cpr/die \times 4 days).

Selection of Landmarks

Bilaterally, in each patient the area between four lines: (1) the line passing through the tragus of the ear and the ipsilateral labial commissure; (2) the line passing through 1 cm below the eyelid with the open eye and the tragus ipsilateral; (3) the line perpendicular to the Frankfurt plane and passing through the tail of the eyebrow; (4) the line

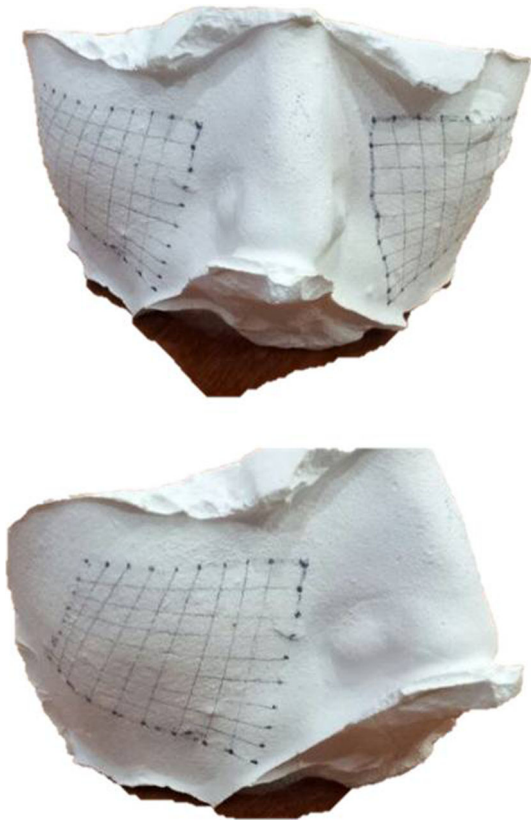
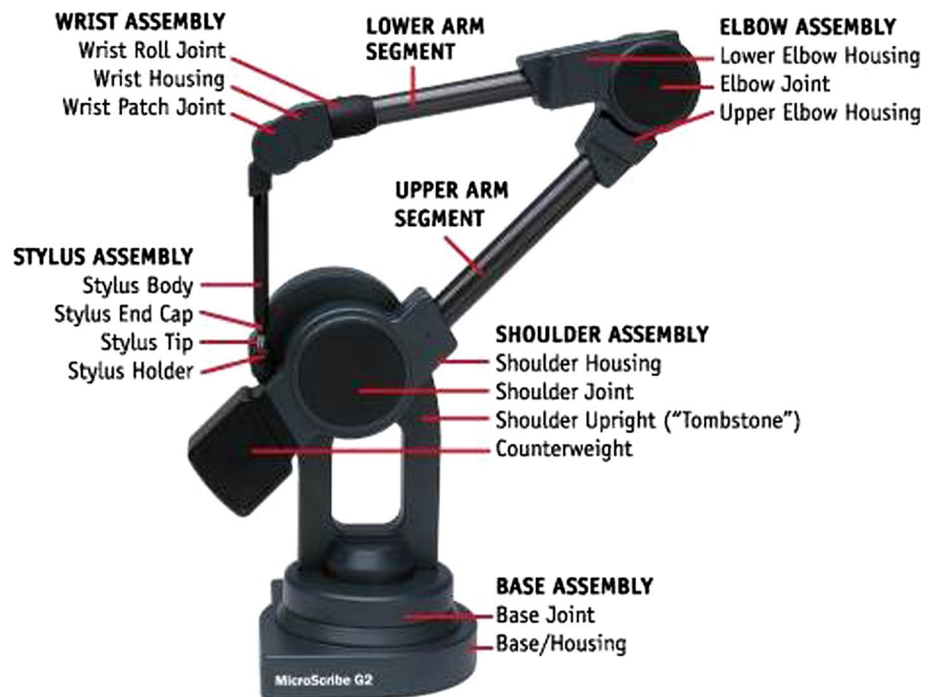

Fig. 3 The mold of the area




Fig. 5 The mold was processed by the program Digitizer 3-D™

Fig. 4 Digitizer 3-D™



passing through the medial canthus and the ipsilateral labial commissure, was selected (Figs. 1, 2).

Measurements

Area After the selection of landmarks a silicone mask with VinylPolysiloxane Impression Material Putty (Express STD Putty, 3 M ESPE, Pioltello, Milan—Italy) for the area

Table 1 Area measurements

	Group 1 (cm ²): study group		Group 2 (cm ²): control group	
	Right area	Left area	Right area	Left area
Pt 1 pre	21.26	20.18	23.60	23.46
1 day-post	26.17	25.43	29.72	29.70
4 day-post	24.60	23.90	29.01	29.12
4 months-post	21.47	21.32	23.98	23.88
Pt 2 pre	16.01	15.58	17.80	16.93
1 day-post	20.90	20.50	23.12	23.03
4 day-post	20.73	20.22	22.67	22.51
4 months-post	17.89	17.42	17.80	17.03
Pt 3 pre	23.28	23.70	16.30	17.12
1 day-post	28.97	29.12	22.18	22.91
4 day-post	28.00	28.50	21.76	21.89
4 months-post	24.21	24.53	18.12	18.36
Pt 4 pre	17.18	18.12	19.41	19.28
1 day-post	21.24	21.90	24.47	24.33
4 day-post	19.83	20.12	23.65	23.61
4 months-post	18.54	18.71	20.00	19.78
Pt 5 pre	19.91	18.06	24.12	23.89
1 day-post	25.12	25.06	30.21	30.11
4 day-post	23.86	23.83	29.33	29.18
4 months-post	20.18	19.87	25.14	25.01
Pt 6 pre	16.25	16.17	21.78	22.14
1 day-post	22.03	21.62	27.12	27.49
4 day-post	20.98	20.50	26.88	27.01
4 months-post	17.00	16.93	22.12	22.18
Pt 7 pre	23.12	23.45	16.15	16.77
1 day-post	27.58	28.04	21.38	21.53
4 day-post	26.02	26.85	18.82	18.84
4 months-post	23.39	23.56	17.89	18.42
Pt 8 pre	21.09	20.98	16.72	17.04
1 day-post	26.15	26.24	22.18	22.81
4 day-post	25.33	25.31	21.87	22.13
4 months-post	23.21	23.02	17.28	17.39
Pt 9 pre	17.21	17.67	21.82	21.53
1 day-post	21.89	22.05	26.99	26.93
4 day-post	21.02	21.63	26.08	26.06
4 months-post	17.69	17.83	21.84	21.75
Pt 10 pre	23.00	23.17	23.71	24.02
1 day-post	28.37	28.42	29.55	30.01
4 day-post	26.80	26.83	28.43	28.58
4 months-post	24.02	24.31	24.78	24.99
Pt 11 pre	24.36	24.12	16.44	16.12
1 day-post	29.85	29.88	21.56	21.69
4 day-post	29.12	29.22	20.84	20.86
4 months-post	25.01	25.00	16.98	16.79
Pt 12 pre	21.76	22.32	18.30	17.91
1 day-post	27.12	26.80	24.12	23.88

Table 1 continued

	Group 1 (cm ²): study group		Group 2 (cm ²): control group	
	Right area	Left area	Right area	Left area
4 day-post	25.15	25.03	23.56	23.06
4 months-post	22.65	23.14	18.90	18.84

of interest was made, then we created a plaster cast to conform to the mask previously formed (Fig. 3). The mold was processed by the program Digitizer 3-D™ (Maker-Bot®) (Fig. 4) of Aerospace Engineering (S.U.N. University of Naples) for the precise measurement of the three-dimensional area (Fig. 5).

Pain Pain scores were assessed using a 10 level visual analogue scale (VAS) of 100 mm, representing all pain sensations from none to maximum; where 0 indicates no pain, 5 moderate pain and 10 worst pain possible. Patients were asked to place a mark along the line that corresponded to the amount of pain they were experiencing.

Trismus Maximal mouth opening was recorded measuring the maximum inter-incisal distance using calipers.

All measurements were performed at four specific time points: T0 pre-operative, T1 directly one day after surgery, T2 fourth day after surgery.

All measurements for area were performed at four specific time points: T0 pre-operative, T1 directly one day after surgery, T2 four day after surgery, T3 4 months after surgery.

All measurements were recorded by a single operator (U.T.) and supervised by a single engineer (A.S.).

Surgical Technique

All patients underwent bimaxillaryorthognathic surgery (Le Fort I osteotomy plus bilateral sagittal split osteotomy plus genioplasty). The duration of surgery and the cheek retraction time were recorded for all patients. As a part of the routine premedication protocol, 1 dose of dexamethasone 6 mg was injected in all patients 30 min before surgery. A dose of dexamethasone 4 mg was repeated after 3 and 6 h in the same day of surgery, dexamethasone 4 mg was repeated first day after surgery, dexamethasone 2 mg was repeated 2 days after surgery. One tablet/die of Venoplant® was assumed 1 day before surgery and 4 days after surgery only by the patients of the study group. No surgical drains were placed and ice packs were given to all patients.

Results

The data were analyzed and compared using the *T* Student test (Table 1, Fig. 6).

Fig. 6 T-Student analysis by Excel (Microsoft®)

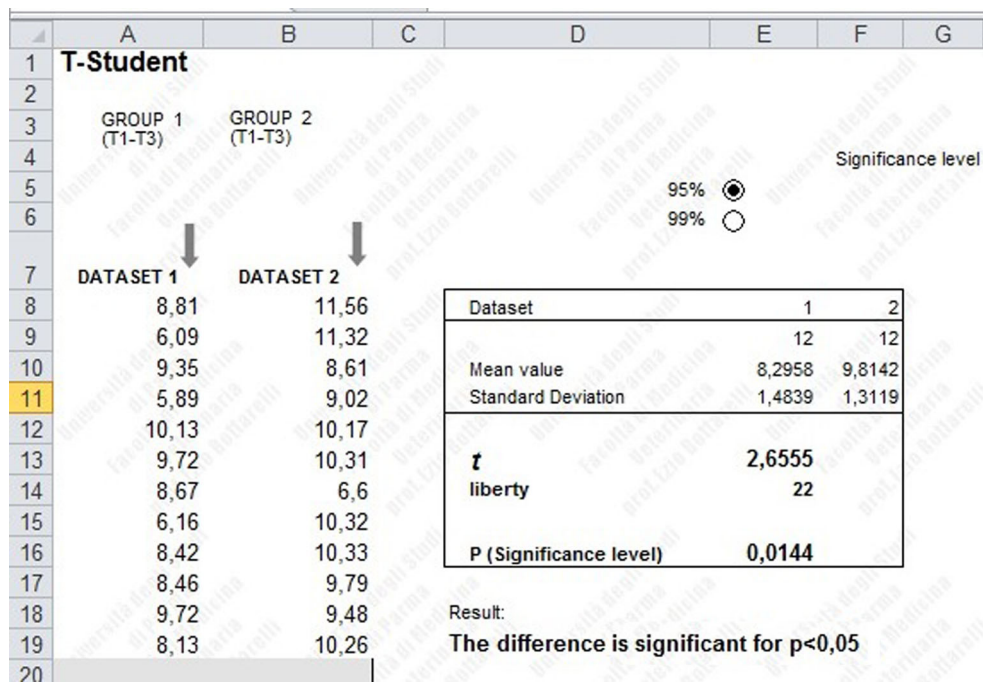


Table 2 Statistical analysis by T Student

	Mean value		SD		p value
	Group 1	Group 2	Group 1	Group 2	
Area T1-T0	10.0267	11.2217	1.1908	0.8066	p < 0.01 99 %
Area T2-T0	7.9775	9.4492	1.7023	1.6698	p < 0.05 95 %
Area T1-T3	8.2958	9.8142	1.4839	1.3119	p < 0.05 95 %

Area All swelling measurements were expressed as total 3-D area of the landmarks (cm²) in T0 pre-operative, T1 first day after surgery, T2 fourth day after surgery, T3 4 months after surgery. For each patient we compared, by adding left and right area, the increase of swelling between T1–T0 and T2–T0 and the differences of the swelling at the peak time and original with the cheek forms four months after the operation. All the differences had a Gaussian distribution. The differences T0–T1 are highly significant (p < 0.01) between group 1 or study group (treated with Venoplant®) and group 2 (control group); the differences T0–T2 are significant (p < 0.05) between group 1 (treated with Venoplant®) and group 2 (control group); the differences T1–T3 are significant (p < 0.05) between group 1 (treated with Venoplant®) and group 2 (control group) (Table 2).

In group 1 (study group) the mean value of the difference between the total/bilateral area 1 day after surgery (T1) and before surgery (T0) was 10.0267 cm², in group 2 (control group) the mean value of the difference between

the total/bilateral area 1 day after surgery (T1) and before surgery (T0) was 11.2217 cm²; in group 1 (study group) the mean value of the difference between the total/bilateral area 4 days after surgery (T2) and before surgery (T0) was 7.9775 cm², in group 2 (control group) the mean value of the difference between the total/bilateral area 4 days after surgery (T2) and before surgery (T0) was 9.4492 cm²; in group 1 (study group) the mean value of the difference between the total/bilateral area 1 day after surgery (T1) and four months after surgery (T3) was 8.2958 cm², in group 2 (control group) the mean value of the difference between the total/bilateral area 1 day after surgery (T1) and 4 months after surgery (T3) was 9.8142 cm².

Pain Comparing the study group and the control group results for pain scores assessed using a 10 level visual analogue scale (VAS) were not significant (p > 0.20) because the main value of VAS in study group was 7,2 at T1 and 6,8 at T2, VAS in control group was 7,3 at T1 and 6,7 at T2.

Trismus Mouth opening values did not differ significantly in both groups and the values were not significant (p > 0.20) because the main value of mouth opening in study group was 2,9 cm at T1 and 3,1 cm at T2, mouth opening in control group was 3 cm at T1 and 3,1 at T2.

Discussion

Some clinical trials have advocated the use of steroids for edema control in orthognathic surgery [12]. In contrast, a

longer use of steroids is associated with multiple problems, such as skin changes, increased serum glucose, adrenal suppression, disturbed wound healing, and impaired immunity [1].

Various non-medical methods also have been used for edema control, each with limitations. The pressure dressing has limited application because of the complex anatomy of the maxillofacial region. Also, excessive pressure in the lower third of face and neck may cause severe discomfort and can compress the airway in some patients. The placement of extraoral drains in such aesthetic procedures is not justified because of residual scar formation. Moreover, intraoral drains are not well tolerated by most patients. The use of ice bags to control edema after a maxillofacial procedure also has limited application [13].

Various methods have been suggested in the literature to measure the amount of tissue edema. Methods for measuring and quantifying such a 3-dimensional phenomenon include 3-dimensional laser scanning and magnetic resonance imaging [14, 15].

In the present study we used Digitizer 3-D™ under standardized conditions for the measurement of the area representative of the entire swelling. It is a simple, safe and accurate method. It is not widely available but we choose it for this study because this method is very accurate and we needed the precise measurement of the area.

There are various parameters that significantly influence the amount of soft-tissue swelling in orthognathic surgery. To decrease the influence of variables, such as type of surgery, extent of dissection, and duration of tissue manipulation, on the extent of swelling, these variables were standardized in the 2 groups. Hence, all patients included in the study underwent bimaxillary orthognathic surgery (Le Fort I osteotomy plus bilateral sagittal split osteotomy plus genioplasty). All surgeries were performed under similar surgical and anesthesia conditions such that the technique, time, and tissue manipulation during surgeries were standardized. Also, all patients were mobilized to a sitting position within 24 h.

All patients in the 2 groups received corticosteroids. In addition, patients in the study group received a 4-day course of Venoplant®. In this study, the authors noted a significant difference in volume between the 2 groups. Thus, a direct correlation was observed between the use of Venoplant® and the decrease in postoperative swelling. In literature the edema of midface is lower than the edema of the mandibular region after orthognathic surgery [11].

However, there are no clinical trials that suggest the possible benefit of this therapy in maxillofacial surgery, in particular orthognathic surgery. The use of Venoplant® is correlated, for the midface region, to a minor post-operative edema and a faster decrease of edema in the 4 days following the surgery.

We achieved that the our values were statistically significant using a T-student analysis by Excel format (Microsoft®) that showed a lower pick increasement of the edema especially the day after surgery and a lower edema 4 days after surgery.

This therapy is usually well tolerated by patients. However, some patients may complain of odorless and colorless feces, a sensation of fullness, flatulence, and occasional episodes of nausea with much higher dosages. These complaints were not noted in the study group of patients.

The present study suggests that Venoplant® significantly decreases postoperative edema in orthognathic surgery, thus precluding long-term corticosteroid use.

Conflict of interest All authors disclose any financial and personal relationships with other people or organisations that could inappropriately influence their work.

References

1. Cheginia S, Dhariwal DK (2012) Review of evidence for the use of steroids in orthognathic surgery. *Br J Oral Maxillofac Surg* 50:97
2. Sahni D, Singh SG, Jit I et al (2008) Facial soft tissue thickness in Northwest Indian adults. *Forensic Sci Int* 179:137
3. Suazo GIC, Cantin LM, Zavando MDA et al (2008) Comparisons in soft-tissue thicknesses on the human face in fresh and embalmed corpses using needle puncture method. *Int J Morphol* 26:165
4. Kim DK, Ruprecht A, Wang G et al (2005) Accuracy of facial soft tissue thickness measurements in personal computer-based multiplanar reconstructed computed tomography images. *Forensic Sci Int* 155:28
5. George RM (1987) The lateral craniographic method of facial reconstruction. *J Forensic Sci* 32:1305
6. Phillips VM, Smuts NA (1996) Facial reconstruction: utilization of computerized tomography to measure facial tissue thickness in a mixed racial population. *Forensic Sci Int* 83:51
7. El-Mehallawi IH, Soliman EM (2011) Ultrasonic assessment of facial soft tissue thicknesses in adult Egyptians. *Forensic Sci Int* 117:99
8. Lam EW, Hannam AG, Wood WW et al (1989) Imaging orofacial tissues by magnetic resonance. *Oral Surg Oral Pathol Oral Radiol Endod* 68:2
9. FourieZ Damstra J, Gerrits PO et al (2010) Accuracy and reliability of facial soft tissue depth measurements using cone beam computer tomography. *Forensic Sci Int* 199:9
10. Williams WB, Abukawa H, Shuster V et al (2003) A comparison of postoperative edema after intraoral vs. endoscopic mandibular ramus osteotomy. *J Oral Maxillofac Surg* 61(8 suppl.): 61a
11. Shetty W, Mohan A (2013) A prospective, randomized, double-blind, placebo-controlled clinical trial comparing the efficacy of systemic enzyme therapy for edema control in orthognathic surgery using ultrasound scan to measure facial swelling. *J Oral Maxillofac Surg* 71:1261–1267
12. Weber CR, Griffin JM (1994) Evaluation of dexamethasone for reducing postoperative oedema and inflammatory response after orthognathic surgery. *J Oral Maxillofac Surg* 52:35

13. Nusair YM (2007) Local application of ice bags did not affect postoperative facial swelling after oral surgery in rabbits. *Br J Oral Maxillofac Surg* 45:48
14. Harrison JA, Nixon MA, Fright WR, Snape L (2004) Use of hand-held laser scanning in the assessment of facial swelling: a preliminary study. *Br J Oral Maxillofac Surg* 42:8
15. Llewelyn J, Ryan M, Santosh C (1996) The use of magnetic resonance imaging to assess swelling after the removal of third molar teeth. *Br J Oral Maxillofac Surg* 34:419