

# Successful Treatment of *Pseudomonas cepacia* Endocarditis with Trimethoprim-Sulfamethoxazole

JOHN HAMILTON, WARNER BURCH, GARFIELD GRIMMETT, KIRBY ORME, DAVID BREWER,  
RICHARD FROST, AND CONRAD FULKERSON

*Departments of Medicine and Surgery, Durham Veterans Administration Hospital, and Duke  
Medical Center, Durham, North Carolina 27705*

Received for publication 23 May 1973

A patient with a history of alcoholism and drug abuse who developed *Pseudomonas cepacia* endocarditis is described. The organism was found to be resistant in vitro to all common antimicrobial agents except chloramphenicol and trimethoprim-sulfamethoxazole. Treatment failed with penicillin and streptomycin and later with chloramphenicol. Orally administered trimethoprim-sulfamethoxazole, however, resulted in sterilization of the patient's blood and aortic valve which was resected 27 days after the start of therapy. A 6-week course of therapy was completed and, to date (6 months after treatment), there has been no recurrence.

More cases of endocarditis due to gram-negative bacilli are reported now than in the past, especially in patients who abuse drugs (5, 9, 14, 15, 19). In addition to the various medical problems encountered, treatment is complicated by the difficulty of achieving a microbiological cure and not suppression. Our report documents endocarditis due to *Pseudomonas cepacia* in a patient with a history of alcoholism and drug abuse who was successfully treated with trimethoprim-sulfamethoxazole (Burroughs Wellcome Co.), followed by aortic valve replacement.

## CASE REPORT

The patient, a 29-year-old man, was admitted January 17, 1973, to the Durham Veterans Administration Hospital with the chief complaint of progressive shortness of breath of several months duration. In 1969, the patient had a pyopneumothorax (unknown organism) requiring open thoractomy, but no cardiac abnormalities were defined by medical history or by physical or laboratory examination. During the ensuing 3 years, he repeatedly, if not continuously, abused both alcohol and intravenous and subcutaneous drugs including heroin. He denied acute illness in the year prior to his admission, but noted increasing dyspnea on exertion, paroxysmal nocturnal dyspnea, weakness, and lethargy over the prior 2- to 3-month period.

On admission, he was cachectic (weight of 136 lb) and febrile to 38.5 C, had a blood pressure of 130/20, a bounding, but regular, pulse of 112/min, and labored respirations at 40/min. He had a single Roth spot and several hemorrhages by fundoscopic examination, many decayed teeth, and rales in both lung bases. His precordium was hyperdynamic with a palpable diastolic thrill, a grade III/VI systolic ejection murmur at the base, a grade II/VI holosystolic murmur at the apex, and a grade V/VI diastolic decrescendo murmur over the entire precordium. An S<sub>3</sub> and S<sub>4</sub> were both palpable and audible. His spleen and liver were both palpable 1 to 2 cm below the left and right costal margins, respectively. He had 3+ pitting edema of both lower extremities. No evidence of "needle tracks" or subcutaneous abscesses were found. Neurological examination revealed slight hyperreflexia and an extensor plantar on his left side.

Laboratory studies revealed a hematocrit of 28 and a white blood cell count of 11,000 with a normal differential; urinalysis showed 10 to 20 red blood cells per high-power field (hpf) and 5 to 10 white blood cells per hpf, and culture was negative. Chest X ray revealed cardiomegaly and electrocardiogram demonstrated left ventricular hypertrophy and strain. Brain scan and electroencephalogram were normal.

His course in the hospital is summarized in Fig. 1.

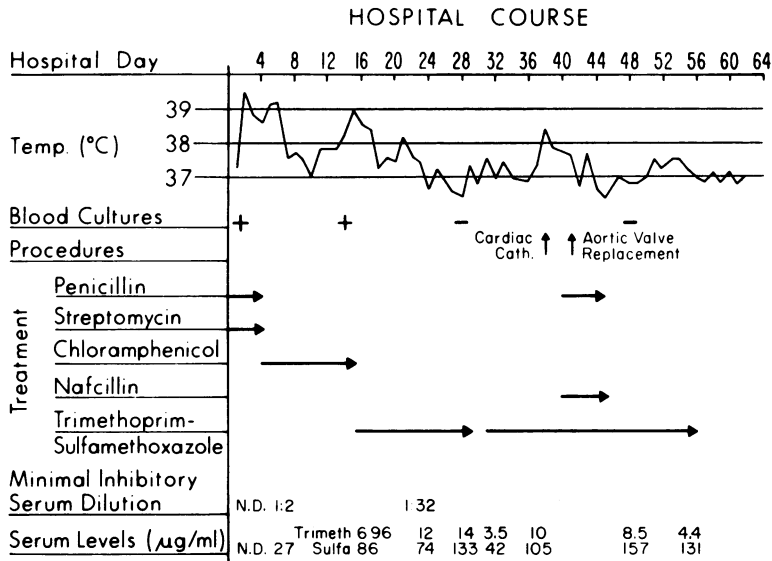


FIG. 1. Successful treatment of *Pseudomonas cepacia* endocarditis with trimethoprim-sulfamethoxazole.

Nine blood cultures were taken before therapy, and then the patient was started on penicillin (24,000,000 U per day) and streptomycin (1 g/day). These were continued for his 1st 4 days of hospitalization without demonstrable benefit in terms of fever, although some benefit was obtained with diuretics for his cardiac failure. No additional blood cultures were taken at this time.

On day 4, the original blood cultures grew *P. cepacia* in all nine sets (identified by the Center for Disease Control). The organism was resistant by a disk method (modification of Bauer-Kirby) to cephalothin, carbenicillin, gentamicin, kanamycin, streptomycin, and Gantrisin. It was sensitive, however, to chloramphenicol. Tube dilution minimal inhibitory concentrations (MIC) confirmed the resistance, and trials with combinations against this organism *in vitro* failed to demonstrate any benefits.

On hospital day 4, chloramphenicol treatment (4.5 g intravenously per day) was initiated. Serum levels of 25 to 28 µg/ml were achieved while the organism had an MIC of 16 µg/ml and a minimum bactericidal concentration of 64 µg/ml. Within 5 days his temperature had returned to normal, and his cardiac failure improved.

On the 14th day of hospitalization, however, his temperature increased, and he demonstrated evidence of bone marrow toxicity with reduced reticulocyte count and elevated serum iron. Three blood cultures taken on this day all grew the same organism with disk and tube dilution sensitivities identical to the original.

Anticipating failure of the above regimen, testing for sensitivity to trimethoprim-sulfamethoxazole had been accomplished at the Wellcome Research Laboratories (S.R.M. Bushby) according to the techniques previously described (3). An MIC to trimethoprim of 0.15 µg/ml and to sulfamethoxazole of 2.8 µg/ml (when tested in combination) suggested that these drugs might prove useful and on the 15th hospital day chloramphenicol was discontinued. Treatment was initiated with trimethoprim, 960 mg/day, and sulfamethoxazole, 4,800 mg/day, which is three times the normal recommended dose. Serum levels, noted in Fig. 1, were performed by microbiological assay for trimethoprim and sulfamethoxazole at the Wellcome Research Laboratories by using a modification of the techniques described by Bushby and Hitchings (4) and Bratton and Marshall (1). Dosages of trimethoprim-sulfamethoxazole were reduced on the 19th day because of suspected toxicity, manifested by nausea and vomiting and interrupted for 2 full days (29 and 30) because of what were considered to be excessive blood levels. These levels were always well in excess of the MIC, and a serum dilution of 1:32 was found to be inhibitory of the patient's own organism.

The patient had an excellent clinical improvement and no evidence of active infection including a normal temperature, unchanging cardiac murmurs, normal white blood count, and two negative blood cultures on the 28th hospital day.

Cardiac catheterization on the 38th hospital

day was performed to evaluate the patient for possible valve replacement. Severe aortic insufficiency and mild mitral insufficiency were documented. Cardiac output was 3.7 liters/min. Because full cardiac compensation with conservative treatment seemed unattainable, valve replacement of at least the aortic valve was recommended.

At surgery, on the 41st hospital day, the noncoronary cusp of the aortic valve was noted to be completely destroyed. The mitral and tricuspid valves were normal by direct vision. The aortic valve was excised and replaced with a no. 10, 2320 Starr-Edwards aortic valve prosthesis. Cultures of the resected aortic valves were sterile, although no attempt was made to grow transitional-phase variants. Histologic examination of the resected valve revealed no organisms. The patient remained on trimethoprim-sulfamethoxazole and was covered additionally for several days with penicillin and sodium nafcillin.

The patient's postoperative course was uncomplicated except by transient atrial arrhythmias which were controlled by combinations of Pronestyl, quinidine, digoxin, and pacing. By the 48th hospital day he was in normal sinus rhythm without evidence of cardiac decompensation. Two additional blood cultures taken at this time were negative.

He was maintained on trimethoprim-sulfamethoxazole for 15 more days (supplemented by leukovorin factor) without evidence of hematologic or other toxicity. After 42 days of total treatment with trimethoprim-sulfamethoxazole, the drug was discontinued. Follow-up examination in the hospital revealed continued improvement and no evidence of infection.

At follow-up in May 1973, the patient continued to do well. He was readmitted in June with arrhythmias and congestive heart failure after stopping digitalis treatment. In August 1973, the patient was readmitted with unexplained erythrocytosis. No evidence of recurrence of infection was found on any of these occasions.

## DISCUSSION

*P. cepacia* as a pathogen has recently been reviewed (8, 11). Four case reports describe endocarditis due to this organism (16-18). In two, the organism was only later definitively identified as *P. cepacia* (16, 17). Two of these patients were treated with trimethoprim-sulfamethoxazole along with a variety of other antimicrobial agents, but only one was treated successfully.

This organism has been found to be uniformly

resistant to many of the commonly employed antimicrobial agents (11, 16-18). In vitro sensitivity to chloramphenicol has also been a consistent finding, however. Also, in those instances where tested in vitro, sensitivity to trimethoprim-sulfamethoxazole was documented (18).

Two other case reports document the use of trimethoprim-sulfamethoxazole in the treatment of endocarditis due to *Escherichia coli* (10) and *Enterobacter aerogenes* (7).

This case report then is of considerable interest in that trimethoprim-sulfamethoxazole alone has been able to effect a microbiological cure. That this could be accomplished with an oral agent in the absence of significant toxicity is an additional feature of interest. We can not be absolutely certain that surgery did not contribute to the microbiological cure, but we have no evidence to support this suggestion.

Certainly physiological cure without valve replacement would have been impossible. The timing of valve replacement in endocarditis has been a subject of great interest and variable opinion (2, 6, 12, 13, 20). In our opinion, the operation is better performed in the absence of infection and, in this case, trimethoprim-sulfamethoxazole seems to have resulted in absence of infection.

## ACKNOWLEDGMENTS

We gratefully recognize the contributions of S. R. M. Bushby, G. Fernandez, and C. Sigel of the Wellcome Research Laboratories, Delores Elliott and Peter Zwadyk of the Durham Veterans Administration Hospital, and the house staff involved in the care of this patient.

## LITERATURE CITED

1. Bratton, A. C., and E. K. Marshall, Jr. 1939. A new coupling component for sulfanilamide determination. *J. Biol. Chem.* **128**:537-550.
2. Buckley, M. J., E. D. Mundth, W. M. Daggett, and W. G. Austen. 1971. Surgical management of complications of sepsis involving aortic valve, aortic root, and ascending aorta. *Ann. Thor. Surg.* **12**:391-399.
3. Bushby, S. R. M. 1969. Combined antibacterial action in vitro of trimethoprim and sulfonamides. *Postgrad. Med. J.* **45**(Suppl. Nov.):10-18.
4. Bushby, S. R. M., and G. H. Hitchings. 1968. Trimethoprim, a sulfonamide potentiator. *Brit. J. Pharmacol. Chemother.* **33**:72-90.
5. Cherubin, C. E., M. Baden, F. Kavalier, S. Lerner, and W. Cline. 1968. Infective endocarditis in narcotic addicts. *Ann. Intern. Med.* **69**:1091-1098.
6. Crosby, I. K., R. Carrell, and W. A. Reed. 1972. Operative management of valvular complications of bacterial endocarditis. *J. Thor. Cardiovasc. Surg.* **64**:235-246.
7. Darrell, J. H., L. P. Garrod, and P. M. Waterworth. 1968. Trimethoprim: laboratory and clinical studies. *J. Clin. Pathol.* **21**:202-209.
8. Ederer, G. M., and J. M. Matsen. 1972. Colonization and infection with *Pseudomonas cepacia*. *J. Infect. Dis.* **125**:613-618.
9. Finland, M., and M. W. Barnes. 1970. Changing etiology of bacterial endocarditis in the antibacterial era. *Ann.*

- Intern. Med. **72**:341-348.
10. Fowle, A. S. E., and P. A. Zorab. 1970. *Esch. coli*: endocarditis successfully treated with oral trimethoprim and sulfamethoxazole. *Brit. Heart J.* **32**:127-129.
  11. Gilardi, G. L. 1972. Infrequently encountered *Pseudomonas* species causing infection in humans. *Ann. Intern. Med.* **77**:211-215.
  12. Griffin, F. M., G. Jones, and C. G. Cobbs. 1972. Aortic insufficiency in bacterial endocarditis. *Ann. Intern. Med.* **76**:23-28.
  13. Joseph, W. L., H. S. Fletcher, J. M. Giordano, and P. C. Adkins. 1973. Pulmonary and cardiovascular implications of drug addiction. *Ann. Thor. Surg.* **15**:263-274.
  14. Louria, D. B., T. Hensle, and J. Rose. 1967. The major medical complications of heroin addiction. *Ann. Int. Med.* **67**:1-33.
  15. Menda, K. B., and S. L. Gorbach. 1973. Favorable experience with bacterial endocarditis in heroin addicts. *Ann. Intern. Med.* **78**:25-32.
  16. Schiff, J., L. S. Suter, R. D. Gourley, and W. D. Sutliff. 1961. Flavobacterium infection as a cause of bacterial endocarditis. Report of a case, bacteriologic studies, and review of the literature. *Ann. Intern. Med.* **55**:499-506.
  17. Sorrell, W. B., and L. V. White. 1953. Acute bacterial endocarditis caused by a variant of the genus *Herellea*. *Amer. J. Clin. Pathol.* **23**:134-138.
  18. Speller, D. C. E. 1972. *Pseudomonas cepacia* endocarditis treated with co-trimazole and kanamycin. *Brit. Heart J.* **35**:47-48.
  19. Wilson, L. M. 1963. Etiology of bacterial endocarditis before and since the introduction of antibiotics. *Ann. Intern. Med.* **58**:946-952.
  20. Windsor, H. M., L. M. Golding, and M. X. Shanahan. 1972. Cardiac surgery in bacterial endocarditis. *J. Thor. Cardiovasc. Surg.* **64**:282-290.