

Papillary glioneuronal tumor: case report and review of literature

B. CARANGELO¹, U. ARRIGUCCI², A. MARIOTTINI¹, L. LAVALLE¹, G. MUSCAS¹, D. BRANCO¹,
L. LIPPA¹, G. PERI¹, M. MUYA¹, G. COSTANTINO¹, G. TIEZZI¹, D. TACCHINI³, A. MATURO⁴

SUMMARY: Papillary glioneuronal tumor: case report and review of literature.

B. CARANGELO, U. ARRIGUCCI, A. MARIOTTINI, L. LAVALLE, G. MUSCAS, D. BRANCO, L. LIPPA, G. PERI, M. MUYA, G. COSTANTINO, G. TIEZZI, D. TACCHINI, A. MATURO

Papillary glioneuronal tumor (PGNT) is a recently described central nervous system neoplasm that mostly occurs in the supratentorial system,

adjacent to the lateral ventricles.

In 2007, WHO classified PGNT as grade I neuronal-glia tumor because of the characteristic papillary architecture and bipartite (astrocytic and neuronal/neurocytic) cell population. As a newly established entity of mixed glioneuronal tumor family, PGNT attracted extensive attention recently.

In our report we discuss the clinical, neuroradiological and surgical features. The final result is compared with literature data.

KEY WORDS: Papillary glioneuronal tumor - Mixed glioneuronal tumor - Brain tumor.

Introduction

Papillary glioneuronal tumor (PGNT) is a recently described central nervous system neoplasm that mostly occurs in the supratentorial system, adjacent to the lateral ventricles. Well-established examples of glioneuronal tumors include DNET (Dysembryoplastic Neuro-Epithelial Tumor), ganglioglioma and desmoplastic infantile ganglioglioma. More recently recognized entities include rosette-forming tumor of fourth ventricle, rosette glioneuronal tumor (RGNT)/ glioneuronal tumor with neuropil-like islands and PGNT (1).

In 2007, WHO classified PGNT as grade I neuronal-glia tumor because of the characteristic papillary architecture and bipartite (astrocytic and neuronal/neurocytic) cell population. As a newly established entity of mixed glioneuronal tumor family, PGNT attracted extensive attention recently.

It was described in approximately 67 cases to date (Table 1).

Both CT and MRI studies show PGNTs to be circumscribed supratentorial lesions, extending to the cortex and the white matter, or may be more deeply situated, displacing the ventricular system. Cystic alteration are frequent. Solid components are iso/hypointense in T1 and iso/hyperintense in T2, contrast enhancing in a diffuse, patchy or rimming fashion and may present as mural nodule or plaques within otherwise cystic masses. Calcifications may be seen. Bleeding of lesions are rare but recorded (3), associated with superficial siderosis of neuraxis. Surrounding edema and mass effect are seen in larger lesions. Reported tumor size ranges 1-9 cm (mean 4,5 cm).

Hystology showed pseudopapillary pattern consisting of a single layer of astrocytic cells surrounding hyalinized blood cells.

Follow-up indicated that this type of tumor had a benign behavior even if recently we found out 5 cases of aggressive PGNT (1, 2, 4, 5, 7, 8).

Case report

The patient was a 34 yr old woman with complaints of progressive headache started 2 weeks before and more recently confusion, vomiting and dizziness. She had a va-

¹ Department of Neurosurgery, "Le Scotte" University Hospital of Siena, Siena, Italy

² Department of Neuroradiology and Interventional Neurology, "Le Scotte" University Hospital of Siena, Siena, Italy

³ Department of Pathology, "Le Scotte" University Hospital of Siena, Siena, Italy

⁴ Department of Surgical Sciences, "Sapienza" University of Rome, Rome, Italy

Corresponding Author: Biagio Carangelo,
e-mail: biagiorobocarangelo@gmail.com

© Copyright 2015, CIC Edizioni Internazionali, Roma

TABLE 1 - REVIEW OF LITERATURE.

Series	Age/sex	Localization	Surgery	Follow-up	Type	Calcification	Perit edema	Mass effect	Ventricular association	MRI features
Kim et al., (1997)	25/F	temporal	GTR	5/NR	solid	NA	NA	NA	adjacent	ring-like
Komori et al., (1998)	13/M	temporal/sx	GTR	45/NR	cystic/mural nodule	yes	marked	NA	intimate	mixed
Komori et al., (1998)	30/F	parietal/sx	GTR	43/NR	cystic/solid	no	mild	NA	adjacent	mixed
Komori et al., (1998)	11/M	temporal/sx	PR	12/NR	cystic	yes	marked	NA	intimate	ring-like
Komori et al., (1998)	27/F	temporal/dx	GTR	18/NR	cystic/solid	yes	mild	NA	intimate	irregular
Komori et al., (1998)	36/M	parietal/sx	GTR	6/NR	cystic/mural nodule	no	mild	NA	intimate	mixed
Komori et al., (1998)	19/F	temporal/sx	GTR	12/NR	solid	no	mild	NA	no	mixed
Komori et al., (1998)	35/F	temporal/sx	GTR	12/NR	cystic/solid	yes	mild	NA	no	mild
Komori et al., (1998)	52/M	frontal/dx	GTR	6/NR	cystic/mural nodule	no	mild	NA	intimate	mixed
Komori et al., (1998)	26/F	frontal/sx	GTR	NA	cystic/mural nodule	no	mild	NA	intimate	mixed
Bouvier-Labit et al. (2000)	23/M	P-O/sx	GTR	84/NR	cystic/mural nodule	NA	marked	NA	adjacent	mixed
Prayson et al. (2000)	18/M	P-O/sx	GTR	3/NR	cystic	no	no	NA	intimate	ring-like
Broholm et al. (2002)	16/M	frontal/sx	GTR	6/NR	cystic/solid	NA	no	NA	no	peripheral/solid enhanced
Barnes et al. (2002)	4/M	temporal/sx	GTR	30/NR	cystic/solid	NA	mild	mild	intimate	mixed
Tsukayama et al. (2002)	75/F	frontal/sx	PR	20/NR	cystic/mural nodule	NA	mild	mild	intimate	mural nodule
Lamszus et al. (2002)	24/F	P-O/sx	GTR	4/NR	cystic/solid	NA	NA	NA	no	absence
Ebato et al. (2003)	23/F	frontal/dx	NA	33/NR	cystic/mural nodule	NA	mild	mild	adjacent	NA
Kordek et al. (2003)	14/F	parietal/sx	NA	NA	cystic/solid	no	no	no	no	solid enhanced
Borges et al. (2004)	14/F	fronto-parietal/sx	GTR	56/NR	cystic	NA	no	mild	intimate	ring-like
Tanaka et al., (2005)	18/F	occipital	GTR	NA	NA	NA	NA	NA	no	mixed
Tanaka et al., (2005)	28/F	3rd ventricle	GTR	23/NR	cystic/solid	yes	mild	NA	adjacent	NA
Tanaka et al., (2005)	25/M	temporal/dx	GTR	6/NR	cystic/solid	no	no	NA	adjacent	solid enhanced
Stosic-Opincal et al. (2005)	16/F	parietal/dx	PR	36/NR	cystic	no	no	NA	adjacent	rim, septum
Chen et al. (2006)	16/F	temporal/dx	GTR	13/NR	cystic/solid	yes	no	no	intimate	mixed
Chen et al. (2006)	35/M	temporal/dx	GTR	50/NR	cystic/mural nodule	NA	no	NA	adjacent	NA
Celli et al. (2006)	27/M	frontal/sx	GTR	30/NR	cystic/solid	NA	no	mild	adjacent	wall, solid part
Qi et al. (2006)	NA	NA	NA	NA	NA	NA	NA	NA	NA	NA
Vajtal et al. (2006)	13/M	temporal/sx	GTR	0	cystic/solid	NA	no	mild	adjacent	mixed
Ishizawa et al. (2006)	67/M	parietal/dx	PR	6/R	cystic/solid	NA	NA	NA	NA	solid enhanced
Epelbaum et al. (2006)	27/M	temporal/sx	GTR	214/NR	cystic	no	marked	mild	adjacent	ring-like
Epelbaum et al. (2006)	17/F	frontal/dx	GTR	24/NR	solid	no	no	NA	adjacent	mixed
Buccoliero et al., (2006)	15/F	basal ganglia/sx	GTR	12/NR	cystic/solid hemorrhage	no	mild	NA	intimate	solid enhanced
Dim et al. (2006)	20/F	frontal/dx	GTR	2/NR	cystic/solid	NA	moderate	mild	intimate	homogeneous
Konya et al. (2006)	49/F	frontal/dx	GTR	12/NR	cystic/hemorrhage	no	no	NA	adjacent	NA

TABLE 1 - REVIEW OF LITERATURE. (continued)

Series	Age/sex	Localization	Surgery	Follow-up	Type	Calcification	Perit edema	Mass effect	Ventricular association	MRI features
Vaquero et al., (2007)	34/M	frontal-parietal/dx	GTR	60/NR	Cystic/solid	NA	no	NA	adjacent	solid enhanced wall, mural nodule
Atri et al. (2007)	4/M	frontal dx	PR	24/NR	cystic/mural nodule	no	mild	NA	no	mixed
Radotra et al. (2007)	41/M	T-P-O/dx	GTR	12/NR	solid	no	mild	mild	intimate	ring-like
Adam et al., (2007)	74/F	frontal	PR	8/ER	NA	NA	mild	mild	no	mixed
Adam et al., (2007)	38/M	frontal/dx	GTR	NA	cystic/hemorrhage	NA	NA	mild	no	ring-like
Gelpi et al. (2007)	12/M	trigone/sx	GTR	NA	cystic/solid	NA	no	NA	intimate	ring-like
Pimentel et al. (2008)	19/F	occipital	GTR	32/NR	cystic+mural nodule	no	no	no	adjacent	mixed
Pimentel et al. (2008)	9/F	temporal	GTR	19/NR	cystic+mural nodule	no	mild	mild	adjacent	multiple rings
Williams et al. (2008)	26/F	frontal	GTR	NA	cystic+mural nodule	yes	no	no	adjacent	ring enhancing
Newton et al., (2008)	19/F	T-O sx	PR	2/ER	solid	NA	marked	marked	no	mixed
Faria et al. (2008)	NA	NA	NA	NA	NA	NA	NA	NA	NA	NA
Guo et al. (2008)	23/M	fronto-parietal/sx	GTR	14/NR	cystic/solid	no	no	no	adjacent	mixed
Izycka-Swieszewska et al. (2008)	15/M	pre-central gyrus	GTR	NA	cystic+solid	no	no	no	adjacent	mixed
Mahajan et al. (2009)	17/F	frontal/sx	GTR	NA	NA	no	mild	no	no	ring-like
Govindan et al. (2009)	47/M	fronto-parietal/sx	GTR	NA	cystic/mural nodule	no	no	no	NA	mural nodule
Govindan et al. (2009)	25/M	temporal/dx	GTR	NA	cystic/solid	NA	no	NA	intimate	mixed
Husain et al. (2009)	4/M	pineal/3°-lateral ventricle	NA	NA	NA	NA	NA	NA	NA	NA
Javahery et al., (2009)	13/F	frontal	GTR	ER	cystic	NA	NA	mild	yes	mixed
Javahery et al., (2009)	7/F	parietal	GTR	ER	cystic	NA	NA	yes	yes	mixed
Hema et al (2009)	17/F	frontal sx	GTR	NA	Solid	no	no	no	no	mixed
Xiao et al. (2010)	12/F	temporal/dx	GTR	10/NR	cystic/solid	yes	no	no	intimate	mixed
Xiao et al. (2010)	27/M	temporal/sx	GTR	8/NR	cystic	NA	no	no	no	mural nodule
Phi JK et al (2010)	7/F	3° ventricle	GTR	NA	NA	NA	NA	NA	NA	NA
Lavnic et al. (2011)	23/F	parietal dx	GTR	NA	cystic+mural nodule	no	Moderate	Mild	Intimate	mixed
Lavnic et al. (2011)	27/F	lateral ventricle sx	PR	NA	Solid	Yes	Moderate	no	Intimate	mixed
Myung et al., (2011)	75/F	P-T dx	PR	9/DAD	Cystic	no	no	Mild	Intimate	ring-like
Myung et al., (2011)	22/M	frontal sx	GTR	35/NR	Cystic	no	no	no	Intimate	ring-like
Myung et al., (2011)	24/M	frontal sx	GTR	34/NR	cystic/solid	NA	NA	NA	NA	mixed
Myung et al., (2011)	12/M	frontal dx	GTR	48/NR	cystic	no	no	Mild	Intimate	ring-like
Agarwal et al., (2012)	6/M	luxaventricular	GTR	24/ER	Cystic+solid	no	no	no	Intimate	mixed
Agarwal et al., (2012)	26/F	frontal sx	NA	NA	NA	NA	NA	NA	NA	NA
Agarwal et al., (2012)	14/M	parietal dx	GTR	30/NR	Cystic+solid	no	Minimal	no	no	mixed
Agarwal et al., (2012)	4/M	F-P dx	PR+RT	48/NR	Cystic	no	no	no	no	mixed

Legend: GTR: gross total resection; F-P: fronto-parietal; T-O: temporo-occipital; P-T: parieto-temporal; P-O: parieto-occipital; NA: not available; NR: not evidence of recurrence; ER: evidence of recurrence; DAD: death associated with disease progression.

scular operation for aortic coarctation with stenting in 2003. She denied any use of drugs, alcohol and tobacco. Her family history was significant for a pituitary adenoma in her mother. On physical examination, she was found to have deterioration of conscious level, rigor nuchalis, right upper arm paresis (4+/5), aphasia (E3, V4, M6). The patient was referred to the hospital for evaluation and imaging studies. The brain CT scan with and without contrast revealed a bulky, iso-iperdense lesion (50x39x52 mm) in her left basal/polar temporal lobe on post-contrast injection, images showed a round-ring enhancement of the cyst wall with disomogeneous components (Figure 1).

MRI - after administration of contrast enhancement, the cystic portion showed heterogeneous enhancement while the solid component a more homogeneous one. Angio-CT and angio-MRI were also mandatory because of the high suspect of a vascular abnormality that was excluded after the performance of these neuroradiological studies (Figures 2, 3).

The patient underwent a fronto-temporal craniotomy with macroscopically total removal of tumor. Intraope-

ratively it appears in most part an hemorrhagic lesion (90%) with a minimal solid component (10%). All the samples were analyzed and processed. The final histopathological exam that matched with the diagnosis of PGNT documented the presence of "piloid" areas with associated high vascular proliferation and cystic degeneration. It described papillary zones surrounding a vascular core, the vessels showed marked thickening and hyalinization of wall layers, proliferation index (MIB1) <1%; p53 and EGFR immunoreactivity was not observed (Figures 4, 5). There were no post-operative complications and the patient was discharged after 10 days with complete remission of pre-operative deficits. The post-operative neuroradiological exams showed the complete exeresis of tumor and the absence of further complications. Seizure therapy was prescribed (Levetiraceam). Therefore after 2 months, she was readmitted in our clinic, complaining of headache, pain in the nape of head and lumbar pain. She underwent imaging exams (CT and MRI) that showed new bleeding inside the operative field and an enhanced residual lump (Figure 6). Because of the worsening of neurological status and re-

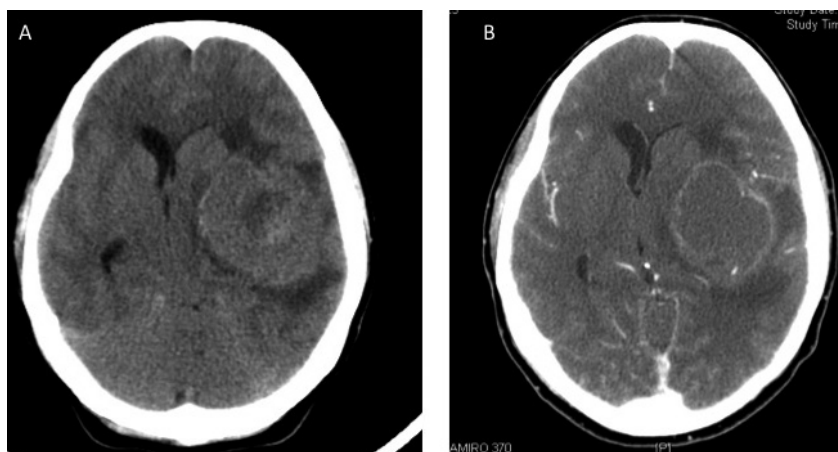


Fig. 1 - A) Pre-operative CT scan that shows the voluminous tumor in the left temporal lobe. B) After iopamiro injection is evident the ring enhancement of the cystic component.

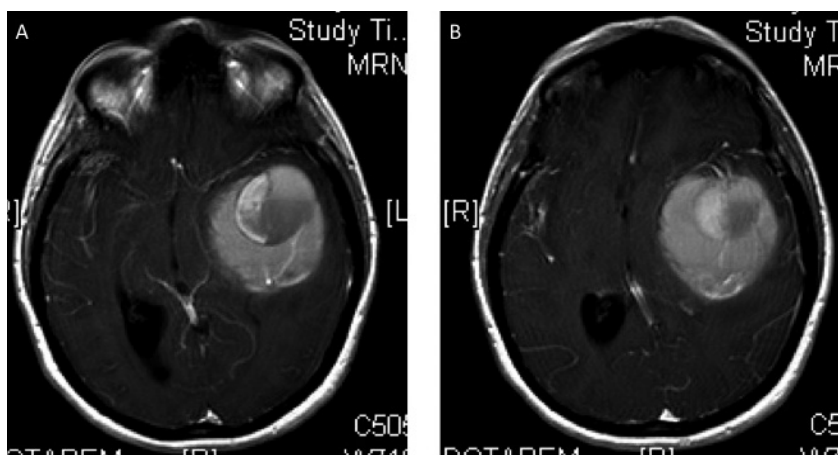


Fig. 2 - A, B) Pre-operative MRI with gadolinium that shows a disomogeneous enhancement of the tumor with solid and cystic components.

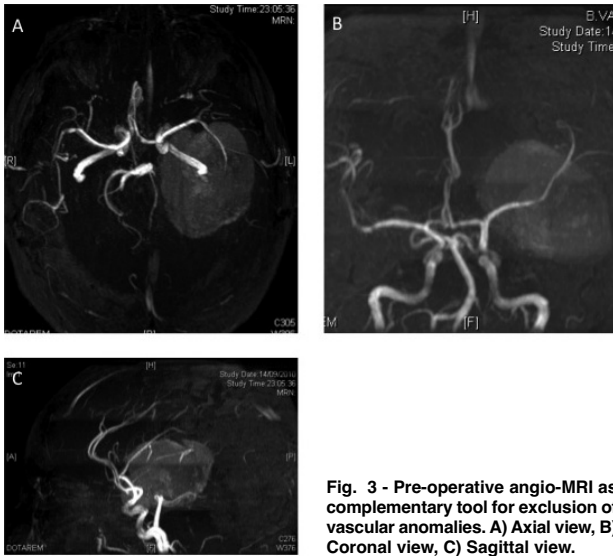


Fig. 3 - Pre-operative angio-MRI as complementary tool for exclusion of vascular anomalies. A) Axial view, B) Coronal view, C) Sagittal view.

currence of tumor, we decided to make a new operation with the evacuation of the blood clot and of lesion. The redo had no complications and reverted the clinical condition to “status quo antea”. After the second operation no radio or chemotherapy were offered to the patient and there were no signs of recurrence in 2 years follow-up, documented with serial MRIs (Figure 7). Our patient, during last clinic, complained cervical pain with arms radiation that relieved after medical therapies with

NSAIDs and muscle relaxants. After 2 years, the patient came to our emergency department because of generalized seizures. Neurological exam was intact except cervical pain. CT scan and MRI were performed, they showed a minimal presence of bleeding in the operative surgical field, that we decided to treat conservatively. MRI after 3 months showed a good recovery.

However, the last MRI performed (Figure 8) showed a rounded area of hyperintensity within the operative field. This neuroradiological condition was related to a worsening of her epileptic seizures. After performing an fMRI for a further imaging study, we decided to operate the patient making a left temporal lobectomy. The histological exam finally diagnosed a PGNT with a shift from a grade I to grade II. The operation didn't have complications and the patient did well as it was confirmed by the radiological control (Figure 9). We chose not to subject the patient to further therapies, rather to intensify strictly the clinical and neuroimaging controls. This histological finding raises questions about the benign nature of the lesion. We also noticed that the literature reports just describe the aggressiveness of this tumour from the beginning of its presentation.

Discussion

Papillary glioneuronal tumor is a distinct entity recently included in the Neuronal and Mixed glial

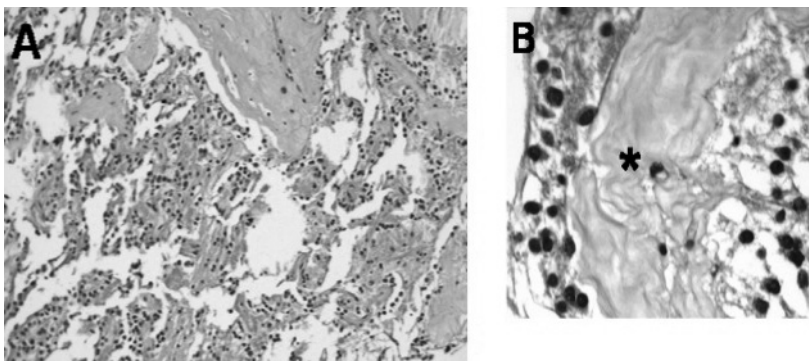


Fig. 4 - Histopathological exam. A) Pseudopapillary pattern of the neoplasm. B) Detail of a "papilla", showing a hyalinized core (asterisk), linked with oligodendroglial-like cells. A, B) Hematoxylin and eosin, original magnification: A, x 100; B, x 100.

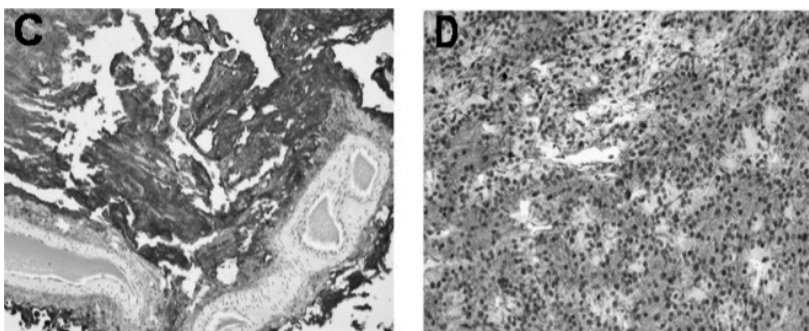


Fig. 5 - Histopathological exam. C) Tumor cells immediately surrounding vessels are GFAP-positive. D) Synaptophysin-positive neurocytes, stained brown by diaminobenzidine, are intermingled with glial negative cells. C, D) Immunohistochemistry, Avidin-Biotin method, original magnification: C, x 50; D, x 100.

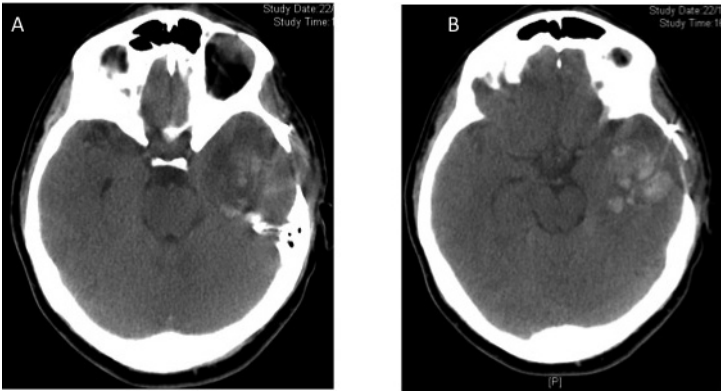


Fig. 6 - A, B) 2-month CT scan showing the new bleeding in the left temporal lobe.

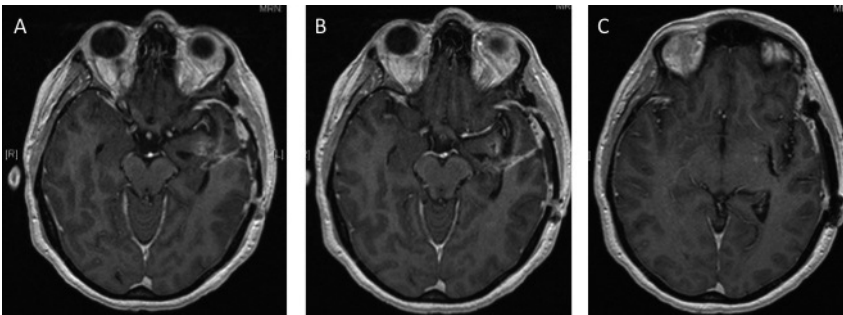


Fig. 7 - A, B, C) 1-month MRI after the second operation that shows neither residual nor recurrence of the tumor.

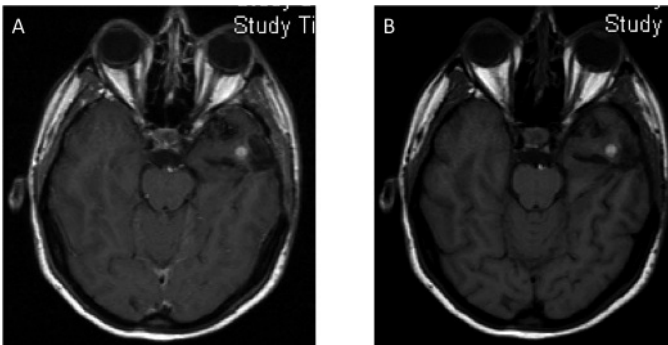


Fig. 8 - A, B) 2-year MRI. Little hyperintensity in T1 sequence, in the temporal left region.

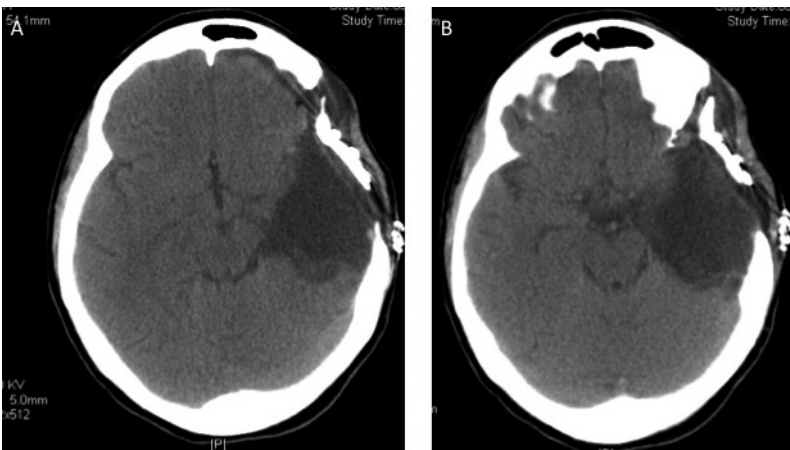


Fig. 9 - A, B) Control CT scan after the third operation.

group of CNS tumors in the 2007 WHO classification. These are slow-growing indolent tumors and involve patients over a wide range of age varying from 4 to 75 years. Komori et al., as first, reported in 1998 this entity as PGNT (papillary glioneuronal tumor). A similar histologic case was reported by Kim et al. in 1997 as pseudopapillary neurocytoma. The glial component is astrocytic, characterized by pseudopapillary formation and featuring conspicuous hyalinized mixed vasculature. The vessels are enclosed by a uniform, single, or pseudostratified layer of small cuboidal cells with round reticular nuclei without atypia and scant cytoplasm. These cells are uniformly immunoreactive for GFAP and S-100 antibodies and in some cases they show immunostaining with synaptophysin antibodies. The interpapillary spaces contain small round neuronal cells with perinuclear halos, resembling oligodendrocytes that have been shown to stain for anti-oli and synaptophysin antibodies. Other pertinent findings, seen in most cases, included the presence of Rosenthal fibers. Proliferative indices, as determined by immunostaining with Ki-67, have uniformly been shown to be low. The patients are asymptomatic or complain of mild neurologic symptoms. With the addition of our case the total number of published cases concerning PGNTs exceeds 68. Most of the currently recognized glioneuronal tumors has a benign course. There are, however,

examples of more aggressive glioneuronal tumor described in the literature. Adam C et al., described the first case of aggressive variant of papillary glioneuronal tumor, doubting about the complete benignity of this variant. Then also Newton HB and Javahery RJ described a case of aggressive PGNTs, while Myung JK had a death because of the disease progression. In our case we have not an aggressive component but a recurrence of PGNT.

The histogenesis of papillary glioneuronal tumor is uncertain and its origin from multipotent precursor cells capable of divergent glioneuronal differentiation has been suggested by its common periventricular location, probably arising from subependymal stem cells. The malignant or anaplastic component of glioneuronal tumor may be the glial portion, neuronal portion, or both (6, 9). The more superficially located ones probably originate from the secondary germinal layer. Expression of PDGF R alpha olig 2 and Nestin by the tumor cells indicates an origin from subependymal progenitor cells. Vaquero et al in a single genetic study published reveal genomic structural alteration in chromosome 7 with break points at 7p22 and amplification at 7p14-q12 (10). There are no characteristic imagings of the tumor that could be specifically indicative of an aggressive nature in our case. In effect PGNTs, like other neurological tumors do not always have a strictly benign course.

References

1. Adam C, Polivka M, Carpentier A, Carpentier A, George B, Gray F. Papillary glioneuronal tumor: not always a benign tumor? *Clin Neuropathol.* 2007;26:119-124.
2. Agarwal S, Sharma MC, Singh G, Suri V, Sarkar C, Garg A, Kumar R, Chandra PS. Papillary glioneuronal tumor- a rare entity: report of four cases and brief review of literature. *Childs Nerv Syst.* 2012;28(11):1897-904.
3. Buccoliero AM, Giordano F, Mussa F, Taddei A, Genitori L, Taddei GL. Papillary Glioneuronal tumor radiologically mimicking a cavernous emangioma with hemorrhagic onset. *Neuropathology.* 2006;26:206-211.
4. Javahery RJ, Davidson L, Fangusaro J, Finlay JL, Gonzalez-Gomez I, McComb JG. Aggressive variant of papillary glioneuronal tumor. Report of 2 cases. *J Neurosurg Pediatr.* 2009;3:46-52.
5. Kim DH, Suh YL. Pseudopapillary neurocytoma of temporal lobe with glial differentiation. *Acta Neuropathol.* 1997;94:187-191.
6. Komori T, Scheithauer BW, Anthony DC, Roseblum MK, McLendon RE, Scott RM, Okazaki H, Kobayashi M. Papillary glioneuronal tumor: a new variant of mixed neuronalglial neoplasm. *Am J Surg Pathol.* 1998;22:1171-1183.
7. Myung JK, Byeon SJ, Kim B, Suh J, Kim SK, Park CK, Chung CK, Chang KH, Park SH. Papillary glioneuronal tumors: a review of clinicopathologic and molecular genetic studies. *Am J Surg Pathol.* 2011;35:1794-1805.
8. Newton HB, Dalton J, Ray Chaudhury A, Gahbauer R, McGregor J. Aggressive papillary glioneuronal tumor: case report and literature review. *Clin Neuropathol.* 2008;27:317-324.
9. Tanaka Y, Yokoo H, Komori T, Makita Y, Ishizawa T, Hirose T, Ebato M, Shibara J, Tsukayama C, Shibuya M, Nakazato Y. A distinct pattern of Oligo2-positive cellular distribution in papillary glioneuronal tumors: a manifestation of the oligodendroglial phenotype? *Acta Neuropathol.* 2005;110:39-47.
10. Vaquero J, Coca S. Atypical papillary glioneuronal tumor. *J Neurooncol.* 2007;83:319-323.