

Giant retroperitoneal bronchogenic cyst mimicking a cystic teratoma: A case report

HAN-XING TONG^{1*}, WEN-SHUAI LIU^{1*}, YING JIANG¹, JU LIU², JIAN-JUN ZHOU³,
YONG ZHANG¹ and WEI-QI LU¹

Departments of ¹General Surgery, ²Pathology and ³Radiology, Zhongshan Hospital, Fudan University, Shanghai 200032, P.R. China

Received June 15, 2014; Accepted February 17, 2015

DOI: 10.3892/ol.2015.3076

Abstract. Retroperitoneal bronchogenic cysts (RBCs) are regarded as a rare type of congenital dysplasia disease that stems from the primitive foregut. Thus far, the exact pathogenesis of RBCs remains unknown. Due to an atypical clinical manifestation, RBCs are often incidentally detected and diagnosed by imaging modalities, such as computed tomography and magnetic resonance imaging. However, they are easily misdiagnosed due to their non-specific imaging features. Additionally, the most appropriate treatment strategy for an RBC is considered to be surgical resection. The present study reports the rare case of a 36-year-old female with a large RBC containing fatty fluid that was previously misdiagnosed as liposarcoma or cystic teratoma. Following a complex surgical resection, pathological findings confirmed a diagnosis of RBC. The follow-up examination showed that the patient was in good health at 16 months post-surgery, with no evidence of recurrence. Although rare, bronchogenic cysts must be considered in the differential diagnosis of retroperitoneal teratoma, and surgical resection should be pursued for symptom resolution and to establish a definitive histology.

Introduction

Bronchogenic cysts are an unusual type of congenital lesion that often occur in the mediastinum, are less common in the lung parenchyma, pleura and diaphragm (1), and are rare in the retroperitoneal space (2). Retroperitoneal bronchogenic cysts (RBCs) have been observed in patients of a variety of ages. Furthermore, patients with an RBC commonly lack characteristic symptoms

and do not demonstrate signs of the disease until the development of a secondary infection or perforated cysts, or until the cysts become large enough to compress the adjacent organs (3). RBCs are occasionally identified by imaging analyses. Despite their unique histological composition, RBCs are often misdiagnosed as teratomas, pseudomyxoma peritonei, lymphocoeles, hemorrhagic cysts, or neoplasms derived from the pancreas, adrenal system or urinary system (4). According to a previous study (5), the appearance of the aforementioned diseases are similar to RBCs on radiological imaging. Thus, at present, only histopathological examination is able to determine a definitive diagnosis of RBC.

Surgical resection is the only therapeutic strategy currently used for the treatment of patients with RBCs (6-9). As the cysts develop adjacent to various important organs, such as the pancreas, stomach, spleen and kidney, the surgical resection of an RBC is complicated.

The current study presents the case of a 36-year-old female with a large mass in the upper left retroperitoneal area that was considered to be a teratoma following numerous imaging studies. However, upon surgical resection, histopathological analysis determined a final diagnosis of an RBC. The patient provided written informed consent.

Case report

A 36-year-old female presented to Zhongshan Hospital (Fudan University, Shanghai, China) with lower back pain that had persisted for 10 days. The patient had a history of tubal ligation and the patient's mother had been diagnosed with colorectal cancer. No family or individual history of hypertension was reported, and the patient had no history of other hereditary or infectious diseases. Laboratory results, including blood count, urea level, liver index and renal function, were all within the normal ranges. However, ultrasonography identified the presence of a mass in the left upper retroperitoneal space.

Abdominal computed tomography (CT) revealed an irregularly-shaped mass located in the upper retroperitoneal space, measuring 15x9.4 cm (Fig. 1A). The lesion consisted of two major sections, a fat density section and a watery fluid density section, with no evident dividing line between them. In the fat density portion, CT indicated a small number of soft-tissue density nodules. In addition, calcium was present

Correspondence to: Dr Ying Jiang, Department of General Surgery, Zhongshan Hospital, Fudan University, 180 Fenglin Road, Shanghai 200032, P.R. China
E-mail: jiang.ying@zs-hospital.sh.cn

*Contributed equally

Key words: retroperitoneal bronchogenic cyst, diagnostic imaging, therapeutics

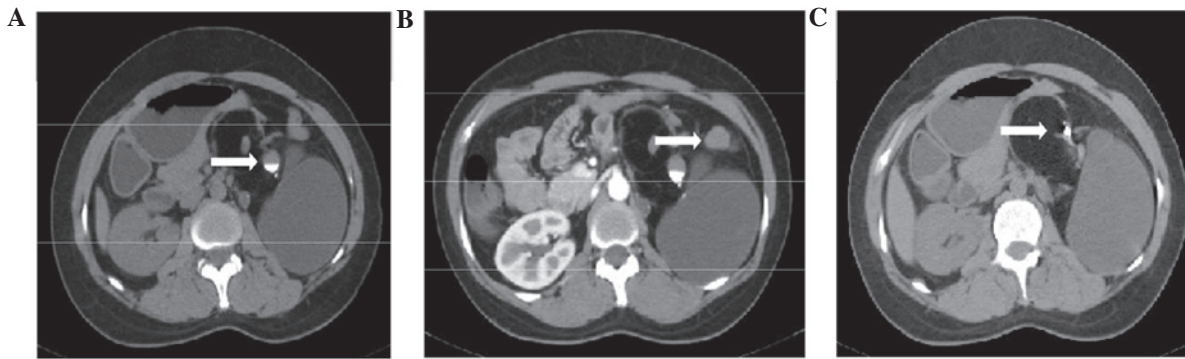


Figure 1. (A) Computed tomography (CT) scan indicating an irregularly-shaped mass in the left retroperitoneal region. Note the dependent high attenuating material (arrow) consistent with calcium. (B) Contrast-enhanced CT demonstrated no enhancement of the mass, however, the soft tissues in the lesion showed slight enhancement (arrow). (C) Calcification (arrow) in the soft tissues of the lesion.

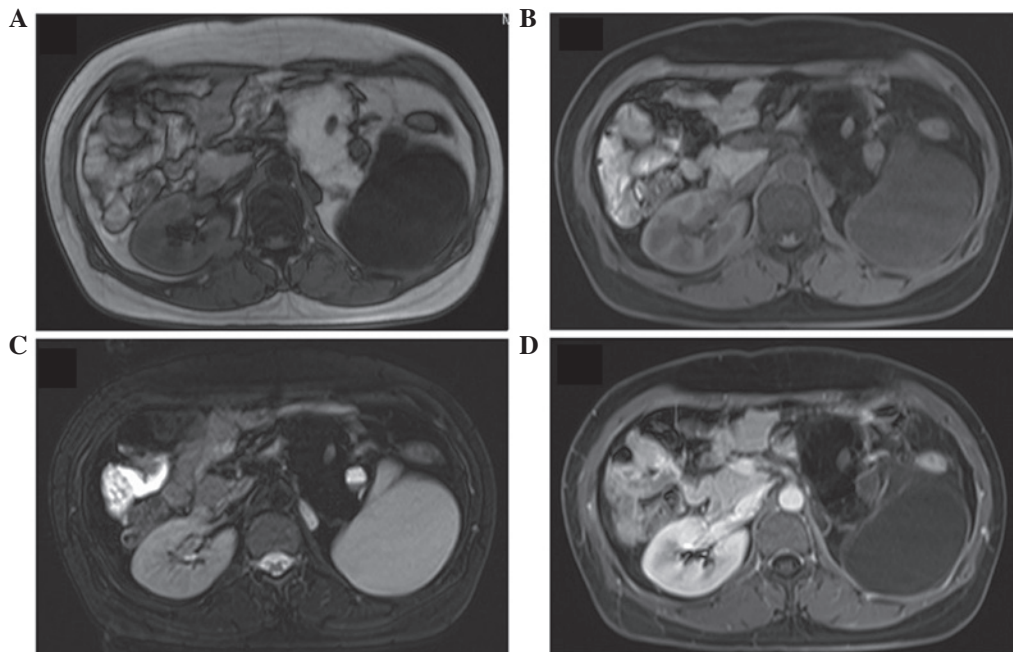


Figure 2. (A) T1-weighted magnetic resonance imaging (MRI) demonstrating an unclearly-marginated heterogeneous mass in the left abdomen. (B) T1-weighted fat suppression MRI indicating that the lesion contains fatty tissue. (C) T1-weighted MRI demonstrating the lesion contents of markedly increased signal intensity, similar to that of cerebrospinal fluid. (D) T1-weighted MRI with enhancement, revealing enhancement in the content of the soft tissues and the surroundings of the mass.

in the cyst fluid (Fig. 1A). The cyst also contained soft-tissue attenuating nodules. The lesion was located adjacent to the abdominal aorta, as well as the mesenteric and spleen vessels. The pancreas and left kidney were compressed and displaced forward, and the left adrenal gland was not clearly displayed. Subsequently, enhanced CT demonstrated no enhancement of the mass and no evident enlarged lymph nodes in the retroperitoneal space (Fig. 1B). Calcification in the soft tissues of the lesion was also observed. Furthermore, CT scanning displayed no homogenous dark areas that would indicate liquid. Based on these findings, the mass was diagnosed as a teratoma by the radiologists.

Upper abdominal magnetic resonance imaging (MRI) revealed a mass with heterogeneous signals. Upon T1-weighted imaging, MRI identified an irregular mass with two separate sections (Fig. 2A); the medial lesion presented with a high-intensity signal, while the lateral part exhibited a

homogeneous low-intensity signal. On T1-weighted imaging with fat suppression, the signal of the medial portion was decreased, however, the signal of the lateral compartment remained unchanged (Fig. 2B). Similarly, on T2-weighted imaging, the lesion exhibited an irregular heterogeneous signal and indicated the presence of a fat compartment with a number of soft-tissue nodules within the medial section (Fig. 2C). By contrast, the lateral portion of the lesion was displayed as a homogeneous high-intensity signal on T2-weighted imaging. Furthermore, on MRI with enhancement scanning, the content of the soft tissues appeared to be progressively enhanced (Fig. 2D). Thus, the MRI findings supported the diagnosis of a teratoma.

Due to the considerable size of the mass and its close proximity to important organs, an exploratory laparotomy was considered to be a reasonable treatment strategy for the patient. The lesion was located in the left retroperitoneal

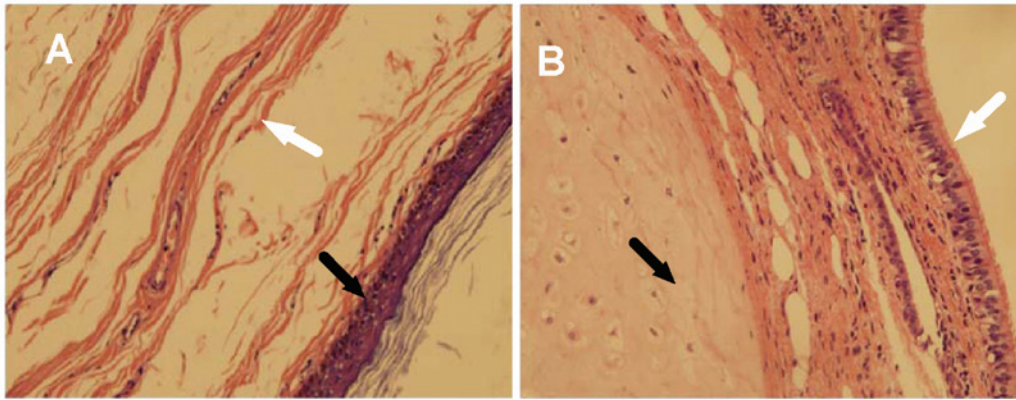


Figure 3. Microscopic view of the retroperitoneal bronchogenic cyst. (A) The mass contained smooth muscle cells (white arrow) and squamous epithelial cells (black arrow). (B) The lesion was lined by pseudostratified ciliated columnar epithelium (white arrow) and the parenchymal portion contained mature hyaline cartilage (black arrow). Hematoxylin and eosin staining; magnification, x100.

region and was fused to the diaphragmatic muscle, however, the inferior margin and the base of the lesion were dissociated. Furthermore, the mass was adjacent to the left kidney and the body of the pancreas, pushing them forward, and the boundary between the adrenal gland and the mass was well-defined. The mass was completely surgically resected in <1 h. The post-operative course was smooth and one week later the patient was discharged from hospital.

Upon gross examination, the mass was ~17x14x7.5 cm in size and taupe-colored. Upon sectioning, the mass contained gray mucous fluid and a 14x10-cm oval cyst, with yellowish-brown oil-like fluid. Histopathology revealed that the cyst was lined by squamous epithelial cells (Fig. 3A) and a pseudostratified ciliated columnar epithelium, while the mass parenchymal portion contained mature hyaline cartilage (Fig. 3B). The aforementioned histopathological characteristics were used to determine a new diagnosis of RBC.

Follow-up examination showed that the patient was in good health at 16 months after the surgery, with no evidence of recurrence.

Discussion

Bronchogenic cysts are commonly benign congenital abnormalities that arise from the primitive foregut. The cysts are lined by a pseudostratified ciliated columnar epithelium, in addition to bronchial glands, smooth muscle cells or cartilage (3,5). Bronchogenic cysts commonly occur in the mediastinal region of the thorax, and are occasionally located in subcutaneous tissue, the pericardium, the spinal canal and other areas of the body (1). However, only a small number of bronchogenic cysts have been identified in the retroperitoneal space (2).

The exact pathogenesis of RBCs remains unclear. However, in 1985, Sumiyoshi *et al* (10) hypothesized that the cysts arose as a separation and migration of the lung bud. In the early stages of embryonic development, the thorax and the abdomen are a singular unit, and the primitive gut tube is divided into the foregut, midgut and hindgut. During the fourth and fifth weeks of embryogenesis, the tracheobronchial tree develops on the ventral aspect of the future pharynx. At the end of seventh week, the pleuroperitoneal membranes completely seal off the

pericardioperitoneal canal (11). Consequently, the dysplastic lung buds are pinched off from the tracheobronchial tree by the closure of the diaphragm. Finally, the early lung buds develop into RBCs. As RBCs commonly occur in the left upper pericardioperitoneal canal, the left pericardioperitoneal canal may be larger and close later than the right one, thus, acting as one indicator of an RBC. Consistent with the clinical features identified in the present case and previous studies (4,12,13), a study conducted by Govaerts *et al* (11) analyzed the published literature to identify that 76% of RBCs are located in the left upper pericardioperitoneal space.

RBCs occur regardless of age or gender. Due to the large potential retroperitoneal space, RBCs are typically asymptomatic and are able to grow to a large size. At present, the largest reported RBC measured ~18 cm in diameter (14), similar in size to the RBC in the present case (17x14x7.5 cm). When an RBC develops to a considerable size, its extent is gradually revealed by a number of clinical manifestations caused by the compression of adjacent viscera, the development of secondary infections or malignant transformations (2,6,7). Hence, patients typically discover an RBC by chance. The predominant clinical manifestations are abdominal discomfort and lower back pain.

Due to the embryological development in the foregut, RBCs are composed of mesodermal and endodermal tissue. From a histological standpoint, RBCs are lined by a pseudostratified ciliated columnar epithelium that composes the base of the fibrovascular connective tissue wall (15). In addition, RBCs contain at least one of the following: Seromucous glands, smooth muscle cells or hyaline cartilage (16,17). However, infection or malignant transformation may alter a number of these histopathological features (18).

Considering that RBCs are located adjacent to surrounding tissues, including the kidney and pancreas, the condition is easy to misdiagnose as a liposarcoma, teratoma, pseudomyxoma peritonei, lymphocoele, hemorrhagic cyst or neoplasm derived from the pancreas prior to surgery (4). However, with the development of radiological techniques, the number of incidental discoveries of asymptomatic RBC is rapidly increasing (5).

The value of ultrasonography in the diagnosis of an RBC is limited due to the deep location of the retroperitoneal lesions and interference from gastrointestinal gas. However, CT

scanning may overcome this issue. The fluid within an RBC is typically a mixture of water and proteinaceous mucus, therefore, CT typically detects RBCs as well-defined spherical lobulated lesions. Furthermore, RBCs frequently appear as hetero- or homogenous hypoattenuating lesions without enhancement following the intravenous administration of contrast agents (11). However, in conditions of hemorrhage, thick mucinous or proteinaceous secretions of the lesions often present as high attenuation signals (18-20). Thus, the variability in cyst contents may be responsible for the attenuation differences observed on CT imaging and the signal intensity features detected on MRI (21,22). In addition, calcium has been proposed as the predominant contributor to high attenuation on CT scans (23). CT identifies a teratoma as an irregular well-defined mixed-density mass that contains fatty density and high-attenuating material consistent with calcium. However, contrast-enhanced CT demonstrates no enhancement of the lesion. In the present case, the observation of fluid, soft tissue, fatty tissue and calcification in the mass contributed to its misdiagnosis as a teratoma.

Considering that CT may be unable to definitely diagnose specific lesions as a cyst due to a lack of mural enhancement or atypical location/internal heterogeneity, McAdams *et al* (19) proposed that MRI may be useful for correctly detecting the true cystic nature of the lesion on T2-weighted images. The different content of the cyst presented as different signals on MRI; the higher the concentration of proteinaceous mucinous fluid present, the higher signal intensity on T1-weighted imaging. Govaerts *et al* (11) noted that RBCs generally appear as an intermediate to high signal intensity on T1-weighted imaging compared with a significantly high signal intensity on T2-weighted imaging. It was also concluded that T1 weighted fat-suppressed imaging could exclude the diagnosis of a teratoma. However, in the current case, the RBC contained an oily fluid that made it more difficult to determine an accurate diagnosis. In addition, when an RBC presents as a solid mass, it is more important to make a differential diagnosis from a neoplasm, particularly with malignant tumors that are derived from the primitive foregut. Furthermore, MRI can be useful for differentiating high attenuating cysts on CT from soft-tissue masses (19). It should be noted that the present case had limitations, as it was difficult to interpret the origin of the fat tissue, which commonly leads to a misdiagnosis of teratoma.

The treatment of an RBC varies depending on the case, and the surgical approach is selected based on the nature and location of the mass (24). Considering the potential complications associated with surgical removal, resection of an RBC should be performed in the early stages when the cyst is found. For asymptomatic RBCs, the majority of studies consider resection to be the most favorable technique. Furthermore, considering that the lesion is commonly located adjacent to surrounding organs, the patients and their family members should be informed of the potential possibility of resection of the adjacent organs. Laparotomy is a common and widely performed surgical procedure for the resection of RBCs (25).

In conclusion, bronchogenic cysts are congenital abnormalities of the primitive foregut that commonly occur in the lung and mediastinum, but are rarely located in the retroperitoneal region. Due to their asymptomatic nature, RBCs are typically incidentally identified upon imaging analyses. Furthermore, as RBCs can be homogeneous or heterogeneous,

they can be easily misdiagnosed as a teratoma, liposarcoma, pseudomyxoma peritonei, lymphocoele, adrenal tumor, pancreatic cyst or tumor. Imaging techniques, such as ultrasonography, CT and MRI, are generally effective methods in the detection of RBC. MRI facilitates the localization of the lesion and assists in the identification of the nature of the cyst, thus aiding in the differential diagnosis of RBC from solid lesions. In addition, serological examinations are useful for excluding a diagnosis of other lesions. However, due to the wide variety of differential diagnoses, it is impossible to establish a definite diagnosis prior to surgery; instead, histopathological analysis is required for clarification. Furthermore, surgical resection is the most effective method to relieve patient discomfort and reduce the possibility of malignant transformation.

The present case indicates that, although extremely rare, bronchogenic cysts must be considered in the differential diagnosis of retroperitoneal tumors, and surgical resection must be pursued for symptom resolution and to establish a definitive histology.

References

- O'Neal PB, Moore FD, Gawande A, *et al*: Bronchogenic cyst masquerading as an adrenal tumor: a case of mistaken identity. *Endocr Pract* 18: e102-e105, 2012.
- Liang MK, Yee HT, Song JW and Marks JL: Subdiaphragmatic bronchogenic cysts: a comprehensive review of the literature. *Am Surg* 71: 1034-1041, 2005.
- Yang DM, Jung DH, Kim H, *et al*: Retroperitoneal cystic masses: CT, clinical and pathologic findings and literature review. *Radiographics* 24: 1353-1365, 2004.
- Cai Y, Guo Z, Cai Q, *et al*: Bronchogenic cysts in retroperitoneal region. *Abdom Imaging* 38: 211-214, 2013.
- Tambo M, Fujimoto K, Miyake M, *et al*: Clinicopathological review of 46 primary retroperitoneal tumors. *Int J Urol* 14: 785-788, 2007.
- Díaz Nieto R, Naranjo Torres A, Gómez Alvarez M, *et al*: Intraabdominal bronchogenic cyst. *J Gastrointest Surg* 14: 756-758, 2010.
- El Youssef R, Fleseriu M and Sheppard BC: Adrenal and pancreatic presentation of subdiaphragmatic retroperitoneal bronchogenic cysts. *Arch Surg* 145: 302-304, 2010.
- Ishikawa T, Kawabata G, Okada H, *et al*: Retroperitoneal bronchogenic cyst managed with retroperitoneoscopic surgery. *J Urol* 169: 1078-1079, 2003.
- McCrystal DJ and Borzi PA: Retroperitoneoscopic resection of retroperitoneal bronchogenic cysts. *Pediatr Surg Int* 18: 375-377, 2002.
- Sumiyoshi K, Shimizu S, Enjoji M, Iwashita A and Kawakami K: Bronchogenic cyst in the abdomen. *Virchows Arch A Pathol Anat Histopathol* 408: 93-98, 1985.
- Govaerts K, Van Eyken P, Verswijvel G and Van der Speeten K: A bronchogenic cyst, presenting as a retroperitoneal cystic mass. *Rare Tumors* 4: e13, 2012.
- Ishizuka O, Misawa K, Nakazawa M and Nishizawa O: A retroperitoneal bronchogenic cyst: laparoscopic treatment. *Urol Int* 72: 269-270, 2004.
- Runge T, Blank A, Schäfer SC, *et al*: A retroperitoneal bronchogenic cyst mimicking a pancreatic or adrenal mass. *Case Rep Gastroenterol* 7: 428-432, 2013.
- Goh BK, Chan HS and Wong WK: A rare case of 'giant' right-sided retroperitoneal bronchogenic cyst. *Dig Dis Sci* 49: 1491-1492, 2004.
- Geng YH, Wang CX, Li JT, *et al*: Gastric foregut cystic developmental malformation: Case series and literature review. *World J Gastroenterol* 21: 432-438, 2015.
- Liang MK and Marks JL: Congenital bronchogenic cyst in the gastric mucosa. *J Clin Pathol* 58: 1344, 2005.
- Cuyppers P, De Leyn P, Cappelle L, *et al*: Bronchogenic cysts: a review of 20 cases. *Eur J Cardiothorac Surg* 10: 393-396, 1996.
- Sullivan SM, Okada S, Kudo M and Ebihara Y: A retroperitoneal bronchogenic cyst with malignant change. *Pathol Int* 49: 338-341, 1999.

19. McAdams HP, Kirejczyk WM, Rosado-de-Christenson ML and Matsumoto S: Bronchogenic cyst: imaging features with clinical and histopathologic correlation. *Radiology* 217: 441-446, 2000.
20. Wang SE, Tsai YF, Su CH, *et al*: Retroperitoneal bronchogenic cyst mimicking pancreatic cystic lesion. *J Chin Med Assoc* 69: 538-542, 2006.
21. Mendelson DS, Rose JS, Efremidis SC, *et al*: Bronchogenic cysts with high CT numbers. *AJR Am J Roentgenol* 140: 463-465, 1983.
22. Glazer HS, Siegel MJ and Sagel SS: Low-attenuation mediastinal masses on CT. *AJR Am J Roentgenol* 152: 1173-1177, 1989.
23. Yernault JC, Kuhn G, Dumortier P, *et al*: 'Solid' mediastinal bronchogenic cyst: mineralogic analysis. *AJR Am J Roentgenol* 146: 73-74, 1986.
24. Inaba K, Sakurai Y, Umeki Y, *et al*: Laparoscopic excision of subdiaphragmatic bronchogenic cyst occurring in the retroperitoneum: Report of a case. *Surg Laparosc Endosc Percutan Tech* 20: e199-e203, 2010.
25. Dong B, Zhou H, Zhang J, *et al*: Diagnosis and treatment of retroperitoneal bronchogenic cysts: A case report. *Oncol Lett* 7: 2157-2159, 2014.