



ELSEVIER

Contents lists available at ScienceDirect

International Journal for Parasitology:
Parasites and Wildlifejournal homepage: www.elsevier.com/locate/ijppaw

Invited Review

A retrospective study of *Babesia macropus* associated with morbidity and mortality in eastern grey kangaroos (*Macropus giganteus*) and agile wallabies (*Macropus agilis*)Shannon L. Donahoe^{a,b,1}, Christopher S. Peacock^{c,d,1,*}, Ace Y.L. Choo^c, Roger W. Cook^e, Peter O'Donoghue^f, Sandra Crameri^g, Larry Vogelneust^a, Anita N. Gordon^h, Jenni L. Scottⁱ, Karrie Rose^{a,j}^a Taronga Conservation Society Australia, Mosman, New South Wales 2088, Australia^b Faculty of Veterinary Science, University of Sydney, Sydney, New South Wales 2006, Australia^c School of Pathology and Laboratory Medicine, University of Western Australia, Nedlands, Western Australia 6009, Australia^d Telethon Kids Institute, Subiaco, Western Australia 6008, Australia^e Regional Veterinary Laboratory, NSW Department of Primary Industries, Wollongbar, New South Wales 2477, Australia^f School of Chemistry and Molecular Biosciences, The University of Queensland, Brisbane, Queensland 4072, Australia^g Australian Animal Health Laboratory, Commonwealth Scientific and Industrial Research Organisation, Geelong, Victoria 3219, Australia^h Biosecurity Sciences Laboratory, Department of Agriculture, Fisheries and Forestry, 39 Kessels Road, Coopers Plains, Queensland 4108, Australiaⁱ School of Veterinary and Biomedical Sciences, James Cook University, Townsville, Queensland 4811, Australia^j School of Public Health, Tropical Medicine and Rehabilitation Sciences, James Cook University, Townsville, Queensland 4811, Australia

ARTICLE INFO

Article history:

Received 7 February 2014

Revised 13 February 2015

Accepted 14 February 2015

Keywords:

Babesia
Piroplasm
Anaemia
Kangaroo
Wallaby

ABSTRACT

This is a retrospective study of 38 cases of infection by *Babesia macropus*, associated with a syndrome of anaemia and debility in hand-reared or free-ranging juvenile eastern grey kangaroos (*Macropus giganteus*) from coastal New South Wales and south-eastern Queensland between 1995 and 2013. Infection with *B. macropus* is recorded for the first time in agile wallabies (*Macropus agilis*) from far north Queensland. Animals in which *B. macropus* infection was considered to be the primary cause of morbidity had marked anaemia, lethargy and neurological signs, and often died. In these cases, parasitised erythrocytes were few or undetectable in peripheral blood samples but were sequestered in large numbers within small vessels of visceral organs, particularly in the kidney and brain, associated with distinctive clusters of extraerythrocytic organisms. Initial identification of this piroplasm in peripheral blood smears and in tissue impression smears and histological sections was confirmed using transmission electron microscopy and molecular analysis. Samples of kidney, brain or blood were tested using PCR and DNA sequencing of the 18S ribosomal RNA and heat shock protein 70 gene using primers specific for piroplasms. The piroplasm detected in these samples had 100% sequence identity in the 18S rRNA region with the recently described *Babesia macropus* in two eastern grey kangaroos from New South Wales and Queensland, and a high degree of similarity to an unnamed *Babesia* sp. recently detected in three woylies (*Bettongia penicillata ogilbyi*) in Western Australia.

© 2015 Published by Elsevier Ltd on behalf of Australian Society for Parasitology. This is an open access article under the CC BY-NC-ND license (<http://creativecommons.org/licenses/by-nc-nd/4.0/>).

Contents

1. Introduction	269
2. Materials and methods	269
2.1. Animals	269
2.2. Haematology	270
2.3. Pathology	270

* Corresponding author. School of Pathology and Laboratory Medicine, University of Western Australia, Nedlands, Western Australia, Australia, and Telethon Institute for Child Health Research, Subiaco, Western Australia, Australia. Tel.: +08 92876172; fax: +0893462891.

E-mail address: christopher.peacock@uwa.edu.au (C.S. Peacock).

¹ Joint first author.

<http://dx.doi.org/10.1016/j.ijppaw.2015.02.002>

2213-2244/© 2015 Published by Elsevier Ltd on behalf of Australian Society for Parasitology. This is an open access article under the CC BY-NC-ND license (<http://creativecommons.org/licenses/by-nc-nd/4.0/>).

2.4.	Cytology	270
2.5.	Histopathology	270
2.6.	Ancillary testing	271
2.7.	Transmission electron microscopy	271
2.8.	DNA extraction, amplification protocols, and sequencing	271
2.9.	Phylogenetic analysis	271
3.	Results	271
3.1.	Clinical findings	271
3.2.	Haematology and clinical chemistry	271
3.3.	Pathology	271
3.4.	Cytology	272
3.5.	Histopathology	272
3.6.	Electron microscopy	273
3.7.	Molecular studies	273
3.8.	Microbiology, parasitology, virology and toxicology	273
4.	Discussion	273
	Acknowledgements	276
	Conflict of interest	276
	References	276

1. Introduction

The eastern grey kangaroo (*Macropus giganteus*) is one of the most abundant large Australian macropods, with a broad distribution that extends along the eastern seaboard and west to inland plains. Despite frequent contact with domestic livestock and humans in these areas, little is known about the prevalence and impact of haemoparasite infections in eastern grey kangaroos and the role that other macropods may play in their maintenance and transmission in Australia.

Babesiosis is a tick-transmitted disease caused by intraerythrocytic protozoa of the phylum Apicomplexa and order Piroplasmorida, which are capable of infecting many mammalian and some avian species. The *Babesia* organisms replicate within the cytoplasm of erythrocytes, to form typically two or four merozoites, which may be detected in blood samples. Although many infections remain asymptomatic, some produce clinical disease resulting from a severe haemolytic anaemia. Distribution of these parasites is widespread, with members of the genus endemic in North and South America, Europe, Asia, Africa and Australia (Taylor et al., 2007). Some are emerging zoonotic species, with human disease caused by *Babesia divergens* in Europe and by *Babesia microti* in the United States (Kjemtrup and Conrad, 2000) and Australia (Senanayake et al., 2012).

Although the occurrence of babesiosis in imported animal species, such as cattle and dogs, has been well documented in Australia (Bock et al., 2004), relatively little is known about the diversity of *Babesia* spp. that are endemic to this continent. *Babesia* spp. have been described in at least eight species of Australian marsupials: *Babesia thylacis* in southern brown bandicoots (*Isodon obesulus*) and quolls (*Dasyurus* spp.) (Mackerras, 1959; O'Donoghue and Adlard, 2000; Clark et al., 2004), *Babesia tachyglossi* in echidnas (*Tachyglossus aculeatus*) (Backhouse and Bolliger, 1957), and an un-named *Babesia* sp. in eastern grey kangaroos (*Macropus giganteus*) (Fletcher et al., 2008), in woylies (*Bettongia penicillata ogilbyi*) (Paparini et al., 2012), brown antechinus (*Antechinus stuartii*) (Cheal et al., 1976), agile antechinus (*Antechinus agilis*) (O'Donoghue and Adlard, 2000) and a Proserpine rock wallaby (*Petrogale persephone*) (Clark et al., 2004). Most of these parasites were identified on evaluation of blood smears, with their clinical significance unknown. *Babesia* infections in southern brown bandicoots, Gilbert's potoroos (*Potorous gilbertii*) and woylies do not cause apparent disease (Clark et al., 2004; Lee et al., 2009; Paparini et al., 2012). Moderate anaemia and mortality have been observed in the brown antechinus (Cheal et al., 1976) and recrudescence of *Babesia* infections in the male agile antechinus is believed to contribute to post-mating mortality associated with

anaemia, haemoglobinuria, and hemosiderosis of the lung and spleen (Barker et al., 1978).

Since 1994, a syndrome of severe anaemia and debility associated with infection by an intraerythrocytic apicomplexan protozoan in eastern grey kangaroos has been described from the north coast of New South Wales and south-eastern Queensland; usually, juvenile animals reared for variable periods by wildlife carers were affected and developed clinical signs at 6 to 13 months of age, while in care or soon after release (Cook et al., 1997; Ladds, 2009). Clinical signs included anaemia, lethargy, inappetence and a tendency to bleed excessively from venipuncture and tick attachment sites; polydipsia and polyuria were reported in some animals. Small pleomorphic intraerythrocytic parasites were detected within peripheral blood smears in some animals, but because the level of parasitaemia was low and variable, diagnosis was usually confirmed by examination of histological sections and/or tissue impression smears (Cook et al., 1997; Ladds, 2009). Recently, three cases of a similar syndrome were reported in eastern grey kangaroos from south eastern Queensland and the south coast of New South Wales and a new *Babesia* sp., *Babesia macropus*, was identified (Dawood et al., 2013).

In this paper, we report the morphological and genetic characterisation of *Babesia macropus*, the putative cause of the disease syndrome in eastern grey kangaroos and review the clinical and pathological findings in 38 animals infected with this piroplasm. We also make the first report of *B. macropus* infection in the agile wallaby (*Macropus agilis*).

2. Materials and methods

2.1. Animals

Thirty-eight eastern grey kangaroos, diagnosed with intraerythrocytic apicomplexan protozoan infection from 1995 to 2013, are included in this retrospective study. They originated from an area extending from south-eastern Queensland along coastal New South Wales to Newcastle (Fig. 1). The captive animals were between the ages of 6 and 19 months and included 16 males, 13 females, and 5 of undetermined sex. The free-ranging animals were three young-at-foot and one adult. Sick or dead kangaroos or samples collected from them were examined at the Australian Registry of Wildlife Health (ARWH), Mosman, New South Wales (10 animals in 2012; 3 animals in 2013); the Biosecurity Sciences Laboratory (BSL) in Coopers Plains, Queensland (2 animals in 2009; 2 animals in 2012); or the Regional Veterinary Laboratory Wollongbar (RVLW), New South Wales (21 animals between 1995 and 2005).

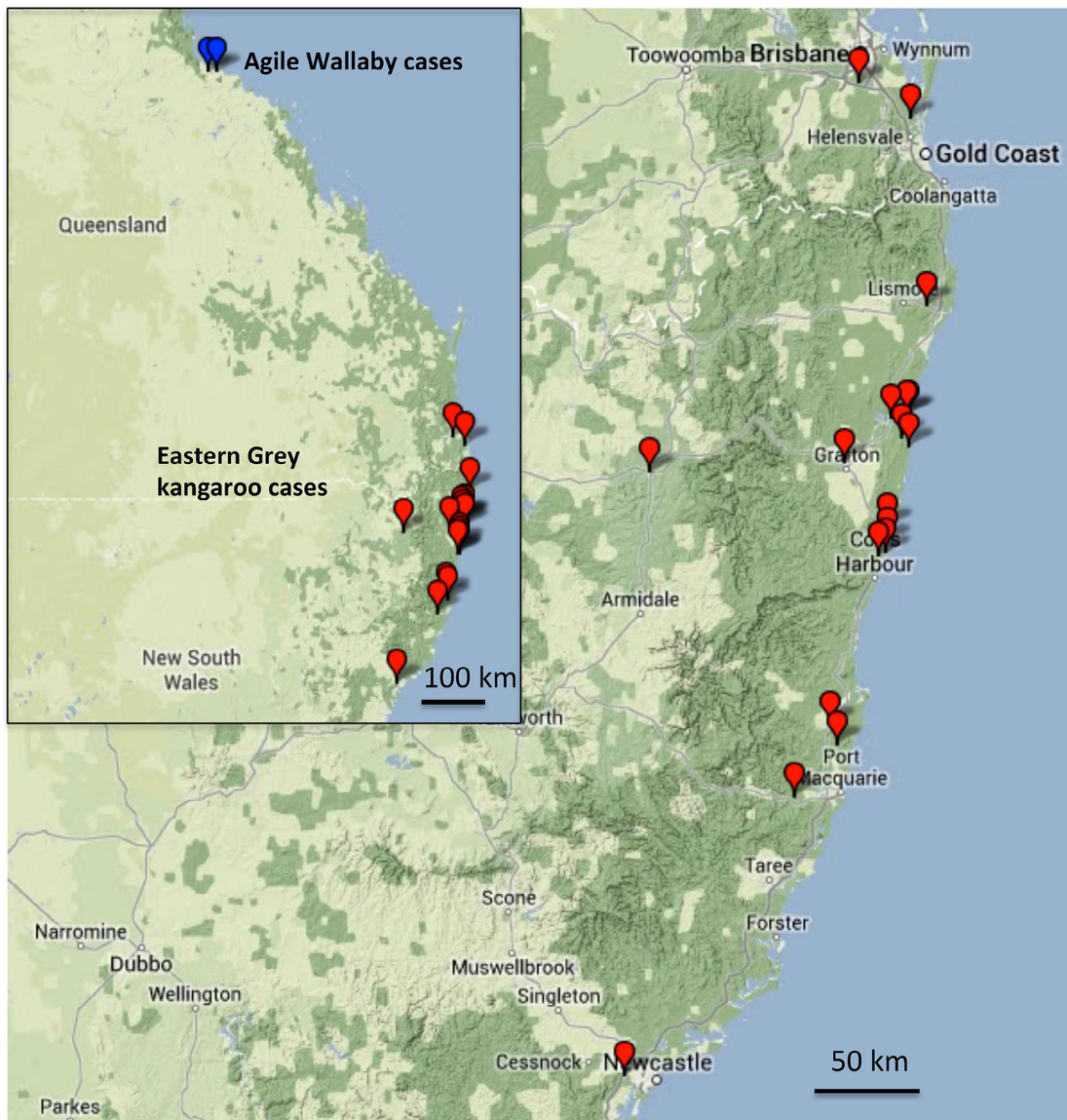


Fig. 1. Map showing the distribution of the 38 cases of *Babesia* infection in eastern grey kangaroos in coastal New South Wales and southeastern Queensland over the period 1995–2013. Insert also shows the two locations of the three cases identified in agile wallabies in northern Queensland in 2009 and 2013. The locations of cases were converted to GPS coordinates and mapped using GPS Visualizer on 21/05/2014 (www.gpsvisualizer.com).

Three agile wallabies from the Townsville region (Fig. 1) died while in care of wildlife rehabilitators (one in 2009 and two in 2013) and were examined at the School of Veterinary and Biomedical Sciences, James Cook University, Townsville, Queensland.

2.2. Haematology

Blood preserved in EDTA was examined from 32 eastern grey kangaroos and one agile wallaby. Complete blood counts were conducted when possible, and blood films from each animal were stained with Giemsa and examined under light microscopy.

2.3. Pathology

Of the 38 eastern grey kangaroos in this study, necropsies were conducted on 31 that had died or were euthanised due to declining health. At necropsy, a range of tissue samples, usually including kidney, brain, spleen, liver, heart, lung and bone marrow, was collected and fixed in 10% neutral buffered formalin for histological examination. From some of these cases, fresh tissues, usually

including kidney and brain, spleen and bone marrow, were also available for cytological evaluation, microbial culture, toxicological testing, and molecular examination.

Necropsies were conducted on the three agile wallabies, and tissue samples, usually including kidney, spleen, liver, heart, lung, stomach and brain, were fixed in 10% neutral buffered formalin for histological examination.

2.4. Cytology

Impression smears from kidney, liver, brain, spleen and bone marrow were made at necropsy of many of the eastern grey kangaroos and one agile wallaby, and were stained with Giemsa or Diff-Quik for microscopic evaluation.

2.5. Histopathology

The formalin-fixed tissues were processed routinely and embedded in paraffin wax. Sections were stained with haematoxylin and eosin and Giemsa.

2.6. Ancillary testing

To determine whether the clinical signs were attributable to babesiosis, another aetiological agent or a multifactorial process tests were conducted on tissues collected, and stored for several weeks at -80°C , from seven eastern grey kangaroos examined at the ARWH. Lung and liver samples from each animal were subjected to aerobic, anaerobic, and fungal culture, using MacConkey agar, Columbia blood agar, Anaerobe agar, and Sabouraud broth with antibiotics (Oxoid, distributed by Thermo Fisher, Adelaide, South Australia). Formalin-fixed, paraffin-embedded brain and kidney were submitted for immunohistochemistry using polyclonal antibody against *Toxoplasma gondii* and *Neospora caninum*. Brain samples were submitted for viral culture and PCR to detect Tammar orbivirus (Rose et al., 2012). Liver tissues were subjected to thin layer chromatography for the identification of anticoagulants (warfarin, coumatetralyl, difenacoum, bromadiolone, brodifacoum and flocoumafepindone and diphacinone) and were analysed for concentrations of Hg (method 04-006, US EPA 200.7 Revision 5.0 “Trace elements in water, solids and biosolids by inductively coupled plasma-atomic emission spectrometry”), Cu, Zn, As, Pb, Se, and Cd (method 04-016, US EPA method 200.8 Revision 5.4 “Trace elements in water, solids and biosolids by inductively coupled plasma-mass spectrometry”).

2.7. Transmission electron microscopy

Brain and kidney tissues of two animals (from ARWH and RVL-W) were formalin-fixed and subsequently processed with glutaraldehyde and osmium tetroxide before infiltration and embedding in resin. Ultrathin sections were stained with uranyl acetate and lead citrate and examined in a JEOL 1010 or a Philips CM120 transmission electron microscope.

2.8. DNA extraction, amplification protocols, and sequencing

Samples of fresh brain, kidney or blood from nine eastern grey kangaroos from ARWH (2012 and 2013 cases), five from the RVL-W (1996, 1997, 1998, 1998 and 2002 cases) and two from the BSL (2012 cases), and from one agile wallaby (one of the 2013 cases) were collected at necropsy, frozen at -20°C or -80°C and subsequently used for DNA extraction and sequencing undertaken from 2012 onwards. Twenty milligrams of kidney, brain or 50 μl blood was pre-lysed for 4 hours at 55°C and then extracted using the PureLink Genomic DNA kit (Life Technologies Australia, Victoria, New South Wales). Samples of formalin-fixed, paraffin-embedded kidney from the other two agile wallabies (2009 case and second 2013 case) were similarly processed. The DNA was then used to amplify regions of the 18S ribosomal RNA (18S rRNA) gene and heat shock protein 70 (hsp70) gene using primers that are specific to Piropasmida. A 934 bp fragment of the 18S rRNA gene was amplified using the primers BTF1 5'-GGCTCATTACAACAGTTATAG-3' and BTR1 5'-CCCAAAGACTTTGATTTCTCTC-3' (Jefferies et al., 2007). A second locus, a ~ 740 bp fragment of the hsp70 gene, was amplified using primers targeted to the region 255–903 hsp70F1 5'-CATGAAGCACTGGCCHTTCAA-3' and hsp70R1 5'-GCNCKGCTGATGGTGGTGTG-3' (Soares et al., 2011). In all cases, appropriate positive and water negative controls were used to validate the results. PCR products were then submitted for forward and reverse Sanger sequencing by the Australian Genome Research Institute. In each case, the reverse sequences returned were reverse complemented, matched to the forward sequences and used to construct a composite region of 850 bp for the 18S rRNA gene and of 631 bp for the hsp70 gene for phylogenetic analysis.

2.9. Phylogenetic analysis

Initial nucleotide BLAST results for both the 18S rRNA and hsp70 gene sequences against the GenBank nucleotide database showed greatest similarity to sequences from *Babesia* spp. For phylogenetic analysis, a range of sequences of *Babesia* spp. and closely related *Theileria* spp. was retrieved from GenBank along with a representative from other apicomplexan parasites for use as outliers. Fasta files containing all the sequences were imported into MEGA6 which was used for alignment, determination of the best fit model and phylogenetic tree building (Tamura et al., 2011). The sequences were aligned using CLUSTAL W (Larkin et al., 2007). The best-fit substitution models were selected based on the lowest Bayesian Information Criterion (BIC) score (Tamura-Nei). Neighbor-Joining (NJ) trees were constructed within the program. Bootstrap values were determined for 500 replicates to test tree reliability.

3. Results

3.1. Clinical findings

Clinical changes detected in the 38 eastern grey kangaroos included anaemia, lethargy and neurological signs, including depression, ataxia, bruxism and ocular deficits (persistent mydriasis, loss of pupillary light reflex and a variable menace response). Some animals were chronic poor doers, while others were in fair to good body condition with only a recent history of debilitation. Additional signs reported in some animals included bleeding from venepuncture sites, polydipsia and polyuria. Animals with a strongly regenerative anaemia were reported to have responded to empirical treatment with imidocarb.

Two of the three agile wallabies had been in care with wildlife rehabilitators for 6 months and had been clinically normal until suddenly appearing depressed and inappetent for a day and dying overnight. The third wallaby was in care for several months in 2013 before showing depression associated with a severe regenerative anaemia. This animal died three days after treatment with imidocarb.

3.2. Haematology and clinical chemistry

The haematological examination of 33 animals revealed a PCV range between 5 and 45%, whereas normal values for this species range between 39 and 51% (ISIS, 2002). Blood films from macropods with a PCV of <25% had evidence of anisocytosis and polychromasia, which was considered consistent with a regenerative anaemia. Within peripheral blood smears from 14 eastern grey kangaroos and one agile wallaby, usually less than 5% of erythrocytes contained pyriform, oval, fusiform or irregularly shaped protozoan zoites, 1 to 5 μm in width or length and morphologically consistent with *Babesia* spp. (Table 1); individual erythrocytes contained usually two to four, but occasionally up to 16 zoites (Fig. 2A). Other variable, clinical pathological findings included thrombocytopenia, neutropenia, hyperamylasaemia, decreased total serum protein, hypoalbuminaemia, hypoglobulinaemia, elevated blood urea nitrogen and elevated total serum bilirubin.

3.3. Pathology

The most common necropsy findings included variable body condition, ranging from normal to emaciated, diffuse pallor of the carcass and visceral organs, thin watery blood that was slow to clot, widespread petechiae, ecchymoses and tissue oedema, splenomegaly and occasionally generalised lymphadenomegaly.

Table 1

Summary of *Babesia* infections detected in 38 eastern grey kangaroos (*Macropus giganteus*) and three agile wallabies (*Macropus agilis*) reviewed in this study (1995–2013). The failure to detect *Babesia* organisms in peripheral blood smears of some animals with histological evidence of infection reflects the low and variable level of parasitaemia.

No. of animals	<i>Babesia</i> infection result		
	Histopathology	Haematology	PCR
Eastern grey kangaroos			
5	POS	POS	POS
9	POS	NEG	POS
2	POS	NT	POS
2	POS	POS	NT
9	POS	NEG	NT
4	POS	NT	NT
7	NT	POS	NT
38 total	31 tested	32 tested	16 tested
Agile wallabies			
1	POS	POS	POS
1	POS	NT	POS*
1	POS	NT	NEG*
3 total	3 tested	1 tested	3 tested

PCR: PCR test for *Babesia* specific 18s rRNA and hsp70 gene sequences.

POS: Positive.

NEG: Negative.

NT: Not tested.

* These two PCR tests were on formalin-fixed, paraffin-embedded samples. The sample that tested negative (2009 case) had been exposed to prolonged formalin fixation.

3.4. Cytology

In the eastern grey kangaroos, two distinctive forms of the *Babesia* organism were identifiable in tissue impression smears, particularly of kidney and brain. There were large numbers of intact erythrocytes containing usually two or four protozoan zoites within their cytoplasm and many clusters of extracellular protozoan zoites (Fig. 2B,C). These findings were in contrast to the very small numbers of parasitised erythrocytes detected in peripheral blood smears. The organisms ranged from 1 to 5 µm in diameter and were pyriform, oval or fusiform, with hypochromic cytoplasm and a single basophilic eccentric nucleus.

3.5. Histopathology

In histological sections, the lumens of small-calibre blood vessels in many organs contained large numbers of parasitised erythrocytes and also distinctive clusters, up to 25 µm in diameter, of zoites within a pink coagulum. Some of these protozoal clusters appeared to be within or adherent to degenerating erythrocytes. In the eastern grey kangaroos, these changes were most prominent within the capillaries of the renal glomerular tufts and the brain (Fig. 2D). In the agile wallabies, organisms were detected in capillaries of the renal cortex, heart, and stomach but not in the two brains examined histologically. In none of the specimens examined was there evidence of inflammation associated with this intravascular sequestration of parasitised erythrocytes or with the intravascular clusters of extraerythrocytic organisms.

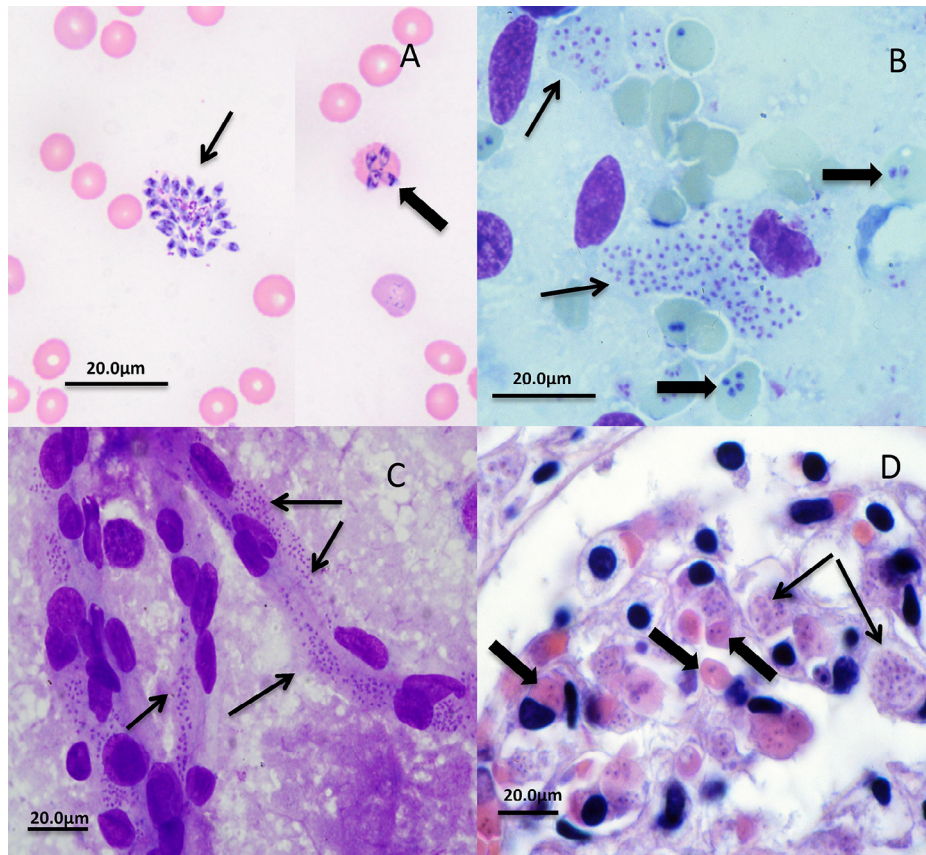


Fig. 2. Photomicrographs showing the forms of *Babesia* seen in cytological preparations and tissue sections in macropods. (A) Agile wallaby, Giemsa stained peripheral blood smear showing extraerythrocytic zoites (thin arrow) and merozoites (thick arrow) within an intact erythrocyte. (B) Eastern grey kangaroo, Diff-Quik-stained renal impression smear demonstrating 2 or 4 merozoites within intact erythrocytes (thick arrows) and clusters of extraerythrocytic zoites (thin arrows). (C) Eastern grey kangaroo, Diff-Quik-stained brain squash preparation showing large clusters of intravascular zoites (arrows). (D) Eastern grey kangaroo, H&E stained section of kidney glomerulus showing merozoites within intact erythrocytes (thick arrows) and as large extraerythrocytic clusters of zoites (thin arrows). All scale bars = 20 µm.

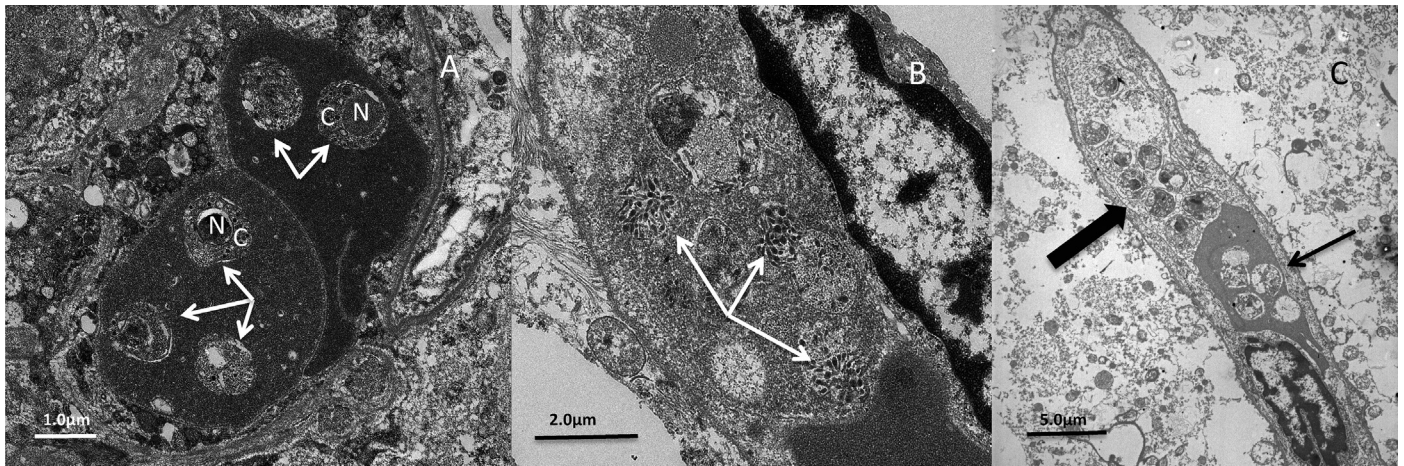


Fig. 3. Transmission electron micrographs showing the intravascular location and structure of *Babesia* organisms in the kidney and brain of eastern grey kangaroos. (A) Kidney, the cytoplasm of two adjacent erythrocytes contains *Babesia* merozoites (arrows) with a membrane-bound nucleus (N) and cytoplasm containing polymorphic vacuoles and some electron dense particles (C) (scale bar = 1.0 μm). (B) Brain, adjacent to an intact erythrocyte and the nucleus of an endothelial cell is a cluster of extraerythrocytic *Babesia* organisms containing electron dense micronemes and developing pellicles (arrows) (scale bar = 2.0 μm). (C) Brain, within the capillary lumen is a cluster of eight or nine extraerythrocytic organisms (thick arrow) and a distorted erythrocyte (thin arrow) containing four intracytoplasmic parasites (scale bar = 5.0 μm).

In cases where *Babesia*-associated anaemia was considered the primary cause of clinical disease, other non-specific histological changes included pulmonary congestion and oedema, bone marrow hyperplasia and lymphoid hyperplasia in peripheral lymph nodes.

3.6. Electron microscopy

Transmission electron microscopic examination of kidney and brain revealed intra and extraerythrocytic zoiters 714–1530 nm in size (Fig. 3A,B). They were small eukaryotic unicellular organisms with well-defined internal structures consistent with apicomplexan piroplasmids, including a membrane bound nucleus, electron dense ellipsoidal micronemes, and a cell membrane subtended by microtubules when mature (forming a pellicle) (Fig. 3B). Immature parasites appeared as undifferentiated merozoites (simple walls and few organelles) located within erythrocytes which otherwise appeared normal, with distinct membranes and filled with homogenous electron-dense haemoglobin. Mature parasites had developed more conspicuous internal structures (subpellicular microtubules and micronemes), while the parasitised erythrocytes exhibited signs of progressive degeneration, including irregular cell outlines, indistinct membranes, and depletion and electron opacity of cytoplasmic haemoglobin. Extraerythrocytic aggregations of zoiters were numerous within the lumens of capillaries and, in some images, these clumps appeared to be loosely surrounded by membranous cellular remnants, the likely fragments of ruptured erythrocytes (Fig. 3C).

3.7. Molecular studies

All 16 eastern grey kangaroos and two of the three agile wallabies with histological evidence of infection were positive on PCR for the *Babesia* specific 18S rRNA and hsp70 gene sequences; the sample from the 2009 agile wallaby case had been exposed to prolonged formalin fixation and yielded DNA of poor quality and a negative result on PCR (Table 1). The 850 bp DNA sequence products for the 18S rRNA gene from the 16 eastern grey kangaroo samples were identical in sequence. A nucleotide BLAST search performed in January 2013 with this 18S rRNA gene sequence revealed no identical sequence in the public databases to this parasite. The most closely related sequences with 97% sequence identity were from a novel *Babesia* spp. recently detected in wild woylies in Western Australia (Fig. 4). Since this comparison was

done, an identical sequence has been submitted and published for *B. macropus* from two eastern grey kangaroos from Queensland and New South Wales (Dawood et al., 2013). In contrast, analysis of the 850 bp DNA sequence product for the 18S rRNA gene from the blood sample of a 2013 agile wallaby case showed that although highly related to the eastern grey kangaroo sequence, there were significant differences, with 98% sequence identity across this region. This difference was confirmed in the second 2013 agile wallaby case using a shorter sequence from this gene taken from DNA extracted from formalin-fixed, paraffin-embedded material. The 631 bp DNA sequence products for the hsp70 gene from all but two of the 16 eastern grey kangaroo samples were identical in sequence; a sample collected in 1998 (RVL-W) and one in 2013 (ARWH) showed a <0.5% difference (3 bases and 2 bases respectively) (Fig. 5). In comparison, analysis of the 631 bp DNA sequence product for the hsp70 gene from the blood sample of the 2013 agile wallaby case showed ~5% difference from the eastern grey kangaroo sequences (Fig. 5). DNA from the formalin-fixed, paraffin-embedded material from the second wallaby case in 2013 was not of sufficient quality to sequence this locus.

3.8. Microbiology, parasitology, virology and toxicology

Amongst the 32 eastern grey kangaroos with histological evidence of *Babesia* infection, concurrent coccidiosis in three cases and amyloidosis in one case were found; babesiosis was not considered the primary cause of morbidity in these four animals. No other viral, bacterial, fungal, protozoal or helminth agent was detected that would account for the disease syndrome in the remaining macropods examined.

4. Discussion

This retrospective study included recent molecular phylogenetic analysis of fragments of 18S rRNA and hsp70 genes amplified by PCR on brain, kidney and/or blood samples from 16 eastern grey kangaroos diagnosed with histological evidence of piroplasm infection between 1995 and 2013. Phylogenetic analysis of 18S rRNA sequence products identified this organism as *Babesia macropus*, recently described in an eastern grey kangaroo from south-eastern Queensland and in another from the south coast of New South Wales

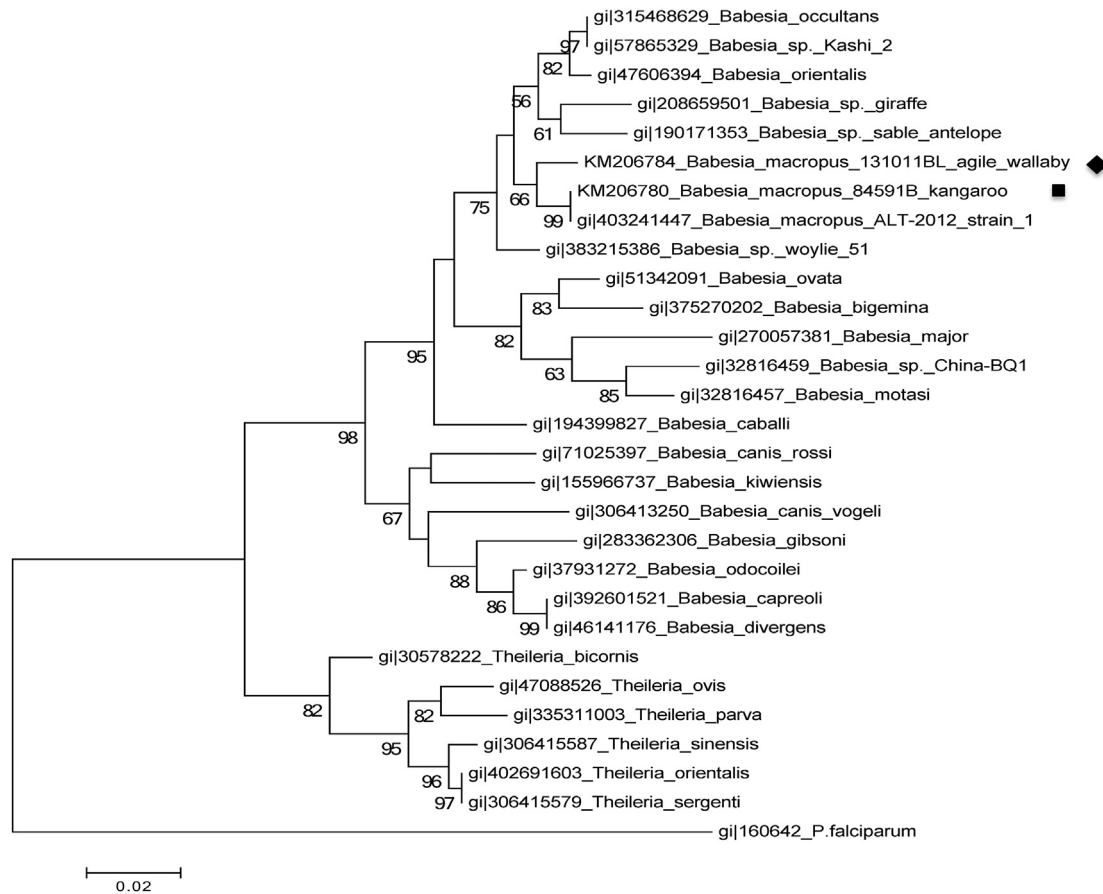


Fig. 4. Phylogenetic tree of 18S ribosomal RNA (18S rRNA) gene sequences of eastern grey kangaroo and agile wallaby *Babesia* and other piroplasmids that are in the GenBank nucleotide database. For each sequence, the GenBank GI number is followed by the species name. The representative *Babesia* isolates from eastern grey kangaroos and an agile wallaby in this study are shown with a ■ and a ◆ respectively. Evolutionary history was inferred using the Maximum Likelihood method based on the Tamura 3-parameter model. The tree with the highest log likelihood (−1820.5242) is shown. Initial tree for the heuristic search was obtained automatically as follows. When the number of common sites was <100 or less than one fourth of the total number of sites, the maximum parsimony method was used; otherwise, BIONJ method with MCL distance matrix was used. The tree is drawn to scale, with branch lengths measured in the number of substitutions per site. The scale bar represents the number of substitutions per nucleotide. All positions containing gaps and missing data were eliminated. Evolutionary analyses were conducted in MEGA6 (Tamura et al., 2011).

(Dawood et al., 2013), and which is closely related to recently-described *Babesia* isolates from woylie.

Our findings that gene fragment sequences were identical in all 16 animals for 18S rRNA and in 14 of 16 animals for hsp70 (with a <0.5% difference of only 3 bases and 2 bases respectively in 2 animals) confirm the genetic uniformity of *B. macropus* infecting eastern grey kangaroos during the period of the study.

The clinical signs, gross and light microscopic changes, and parasite morphology in this study were consistent with the syndrome of severe anaemia associated with a suspected apicomplexan haematozoan infection in juvenile, hand-reared eastern grey kangaroos, first recognised in 1994 on the north coast of New South Wales (Cook et al., 1997; Ladds, 2009). The distinctive clusters of extraerythrocytic organisms viewed histologically within capillaries of the brain, kidney and other organs of affected eastern grey kangaroos were initially interpreted as being located either within the vessel lumen or possibly within endothelial cells, the latter location not being a feature of the life cycle of *Babesia* species (Homer et al., 2000). Definitive identification of the organism as a new species of *Babesia* was delayed until the recent molecular genetic studies characterised it as *B. macropus*. Further histological, cytological and electron microscopic examinations suggested that the distinctive clusters of extraerythrocytic organisms within capillaries are most likely to be zoites of *B. macropus* released from degenerating, sequestered erythrocytes.

Clinical features of disease associated with *B. macropus* are consistent with those described for babesiosis in other species and include anaemia, thrombocytopenia, leukopenia, emaciation, lethargy, ill-thrift, splenomegaly, lymphadenomegaly, and haemorrhage and oedema in multiple tissues (Homer et al., 2000; Solano-Gallego and Baneth, 2011; Schnittger et al., 2012). Anaemia, the most consistent clinical sign in original reports of this syndrome in eastern grey kangaroos, was observed to varying degrees in the cases reviewed, and the detection of anisocytosis and polychromasia in blood smears and bone marrow hyperplasia indicated that the anaemia was regenerative. The pathogenesis of haemolytic anaemia in babesiosis has not been fully elucidated, but may involve direct erythrocyte damage by replicating parasites, immune-mediated mechanisms, or a combination thereof (Solano-Gallego and Baneth, 2011).

Definitive diagnosis of babesiosis in live macropods is currently hampered by the lack of a sensitive laboratory test. A provisional clinical diagnosis based on history, clinical signs and haemogram results can be confirmed in some cases by identification of intraerythrocytic organisms in peripheral blood smears. However, the numbers of parasitised erythrocytes detectable in blood collected from veins are low and variable; evaluation of capillary blood (in tail-tip or ear-tip blood smears), as is recommended for diagnosis of *Babesia bovis* infection in live cattle (Bock et al., 2004), may increase the chance of detecting parasitised

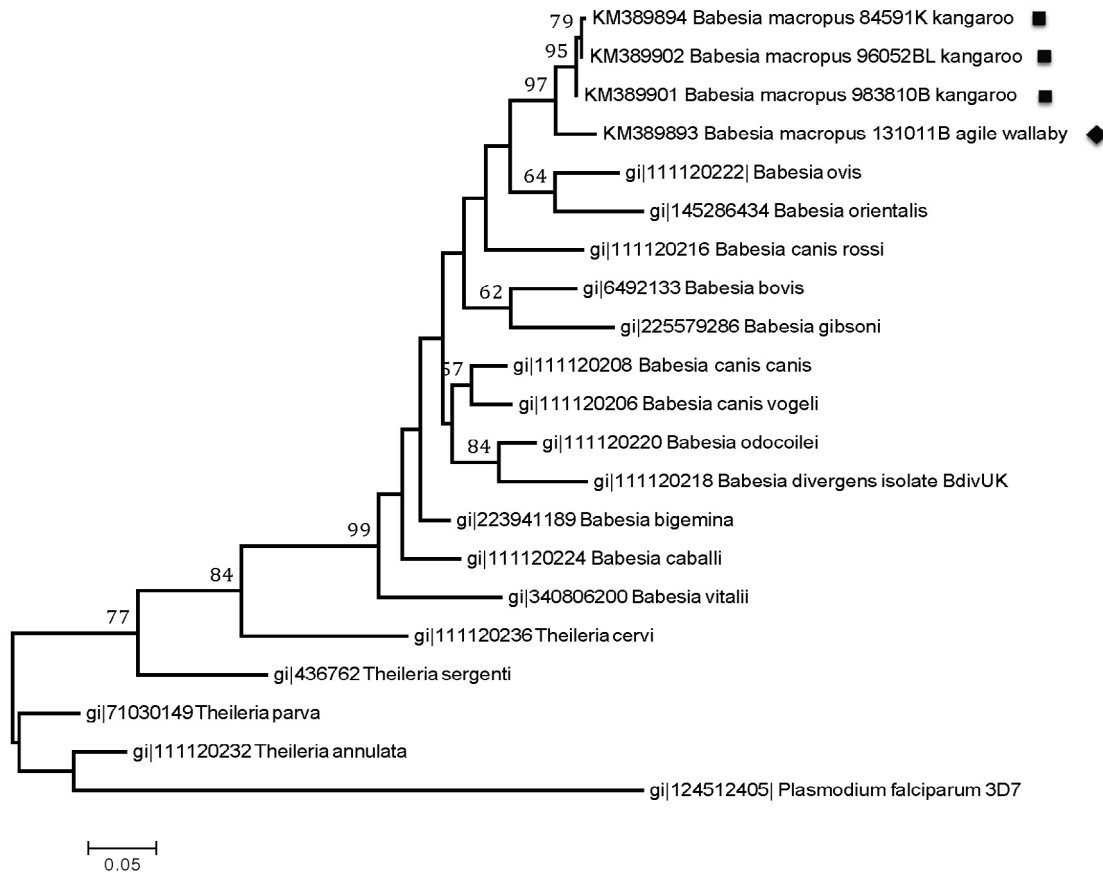


Fig. 5. Phylogenetic tree of heat shock protein 70 (hsp70) gene sequences of eastern grey kangaroo and agile wallaby *Babesia* and other piroplasm hsp70 sequences in the GenBank nucleotide database. For each sequence, the GenBank GI number is followed by the species name. The representative *Babesia* isolates from eastern grey kangaroos and an agile wallaby in this study are shown with a • and a ♦ respectively. The evolutionary history was inferred using the Maximum Likelihood method based on the Tamura-Nei model (Tamura and Nei, 1993). The tree with the highest log likelihood (−6290.3774) is shown. Initial tree for the heuristic search was obtained automatically as follows. When the number of common sites was <100 or less than one fourth of the total number of sites, the maximum parsimony method was used; otherwise, BIONJ method with MCL distance matrix was used. The tree is drawn to scale, with branch lengths measured in the number of substitutions per site. The scale bar represents the number of substitutions per nucleotide. All positions containing gaps and missing data were eliminated. There are limited data available on this locus within the public data repositories and as such there is some lack of consistency with the 18S ribosomal RNA tree.

erythrocytes circulating in peripheral blood of live macropods. Confirmation of infection is usually based on cytological or histological examination of tissues collected at necropsy. Examination of stained impression smears of brain and kidney is an efficient and rapid method of detecting this organism at the time of necropsy.

The pathogenesis of the neurological signs reported in some eastern grey kangaroos may be related to the intravascular sequestration of parasitised erythrocytes and distinctive clusters of extraerythrocytic organisms within the central nervous system. Putative pathogenic mechanisms include those reported for cerebral babesiosis and cerebral malaria, specifically hypoxic injury and/or inflammatory cytokine release caused by sludging of parasitised erythrocytes in brain capillaries (obstructive sequestration) and possible endothelial damage (Schetters and Eling, 1999). Some species of *Babesia* such as *B. bovis* in cattle (Canto et al., 2006), *Babesia lengau* in cats (Bosman et al., 2013) and *Brucella canis* in dogs (Jacobson, 2006) can cause such cerebral localisation of infection, which is associated with a poor prognosis (Canto et al., 2006; Jacobson, 2006). Certain species and strains of *Babesia* can alter the physiology of the infected erythrocyte and increase its adherence to other cells, including endothelial cells (Wright, 1972; O'Connor and Allred, 2000).

Suggested treatment in macropods with babesiosis has included provision of supportive care, including fluid therapy, nutritional and thermal support, and blood transfusions (Vogelnest

and Portas, 2008). The reported response by some infected, anaemic animals to parenteral treatment with imidocarb remains anecdotal and unevaluated (Cook et al., 1997; Vogelnest and Portas, 2008).

To date, all identified vectors of *Babesia* spp. are ticks, which transmit infection via their saliva during feeding. Studies are currently underway to determine the vector(s) for *B. macropus* in macropods; *Haemaphysalis* spp. and *Ixodes* spp. seem likely candidates.

This first report of *B. macropus* infection in another large macropod, the agile wallaby, identified a similar pathological phenotype to infection in the eastern grey kangaroo, but in a different geographic location (Townsville in Queensland). Although there were some sequence differences within the *Babesia* genetic loci encoding 18S rRNA and hsp70 in the agile wallaby compared with the eastern grey kangaroo samples, the phylogenetic analysis showed they were highly related and probably represent natural variation within the *B. macropus* species. This suggests that *B. macropus*, as seen with other recently characterised haematoprotzoans in Australian macropods, may infect a range of native fauna, although most infections may be subclinical (Dougall et al., 2009; Botero et al., 2013).

This study highlights the importance of molecular phylogenetic analysis for distinguishing *Babesia* spp. detected in Australian wildlife. Most zoonotic *Babesia* recognised overseas are maintained in wildlife reservoirs, and molecular characterisation of *Babesia* from potential wildlife reservoirs and vectors is encouraged to allow comparison with any novel *Babesia* detected in a human patient (Yabsley and Shock, 2013).

Following this characterisation of *B. macropus* infection in eastern grey kangaroos and agile wallabies, further studies are required to generate sensitive diagnostic tests for detection of infection in live animals and to improve our understanding of the epidemiology, including reservoir hosts, vector(s) and geographic distribution, of this organism, and the pathogenesis of infection in macropods.

Acknowledgements

Animals examined at the Australian Registry of Wildlife Health were done so under license from the NSW Office of Environment and Heritage and all samples were collected under the Opportunistic Sample Collection Program operated under the auspices of the Taronga Conservation Society Animal Ethics Committee.

The authors wish to thank Jane Hall for her valuable contributions to this investigation and manuscript. We would also like to extend thanks to Cheryl Sangster, Francis Hulst, Tim Portas, Taronga Wildlife Hospital veterinary nursing staff, Graeme Fraser, Mark Krockenberger, Bree Talbot, Marcus Holdsworth, Rob Mills, Jillian Lawrence, Stephen Deist, Allan Hudson, Michael Pyne, Camille Alexandra and Andrew Hill for performing physical and/or necropsy examinations, Paul Thompson, Tammy De Farria, and Dane Hayes for technical assistance, and Joanne Kelly, Arlene Hope, and Meredith Ryan for arranging transport of animals used in this investigation. Christopher Peacock is supported by an Australian Research Council Future Fellowship (FT0992120). Shannon Donahoe is supported by the International Postgraduate Research Scholarship (IPRS) and an Australian Postgraduate Award (APA) tenable at The University of Sydney.

Conflict of interest

The authors declared that there is no conflict of interest.

References

- Backhouse, T.C., Bolliger, A., 1957. A piroplasm of the echidna (*Tachygllossus aculeatus*). *Aust. J. Sci.* 19, 24–25.
- Barker, I.K., Beveridge, I., Bradley, A.J., Lee, A.K., 1978. Observations on spontaneous stress related mortality among males of the Dasyuroid marsupial *Antechinus stuartii*. *Aust. J. Zool.* 26, 435–448.
- Bock, R., Jackson, L., de Vos, A., Jorgensen, W., 2004. Babesiosis of cattle. *Parasitology* 129 (Suppl.), S247–S269.
- Bosman, A.M., Oosthuizen, M.C., Venter, E.H., Steyl, J.C., Gous, T.A., Penzhorn, B.L., 2013. *Babesia lengau* associated with cerebral and haemolytic babesiosis in two domestic cats. *Parasit. Vectors* 6, 128.
- Botero, A., Thompson, C.K., Peacock, C.S., Clode, P.L., Nicholls, P.K., Wayne, A.F., et al., 2013. Trypanosomes genetic diversity, polyparasitism and the population decline of the critically endangered Australian marsupial, the brush tailed bettong or woylie (*Bettongia penicillata*). *Int. J. Parasitol. Parasites Wildl.* 2, 77–89.
- Canto, C.G., Figueroa, J.V., Ramos, E.E., Garcia-Tapia, D., Alvarez, J.A., Allred, D.R., et al., 2006. Evaluation of cattle inoculated with *Babesia bovis* clones adhesive in vitro to bovine brain endothelial cells. *Ann. N. Y. Acad. Sci.* 1081, 397–404.
- Cheal, P., Lee, A., Barnett, J., 1976. Changes in the haematology of *Antechinus stuartii* (Marsupialia) and their association with male mortality. *Aust. J. Zool.* 24, 299–311.
- Clark, P., Adlard, R.D., Spratt, D.M., 2004. Haemoparasites of Australian mammals. In: Clark, P. (Ed.), *Haematology of Australian Mammals*. CSIRO Publishing, Collingwood, pp. 147–151.
- Cook, R.W., Fraser, G.C., Hartley, W.J., 1997. Haematozoan infection in young eastern grey kangaroos. In: *Proceedings of the Australian Society for Veterinary Pathology Annual Conference*, Brisbane, Queensland, Australian Society for Veterinary Pathology, p. 42.
- Dawood, K.E., Morgan, J.A.T., Busfield, F., Srivastava, M., Fletcher, T.I., Sambono, J., et al., 2013. Observation of a novel *Babesia* spp. in Eastern Grey Kangaroos (*Macropus giganteus*) in Australia. *Int. J. Parasitol. Parasites Wildl.* 2, 54–61. in press.
- Dougall, A., Shilton, C., Low Choy, J., Alexander, B., Walton, S., 2009. New reports of Australian cutaneous leishmaniasis in Northern Australian macropods. *Epidemiol. Infect.* 137 (10), 1516–1520.
- Fletcher, T., Rolls, P., Jarett, S., Minchin, C., Morgan, J., Jackson, L., et al., 2008. A new *Babesia* species isolated from an Eastern Grey Kangaroo (*Macropus giganteus*), in SE Queensland. *Proceedings from Australian Society for Parasitology Annual Scientific Meeting*, Glenelg, South Australia, 7–9 July 2008.
- Homer, M.J., Aguilar-Delfin, I., Telford, S.R., Krause, P.J., Persing, D.H., 2000. Babesiosis. *Clin. Microbiol. Rev.* 13, 451–469.
- ISIS, 2002. Reference Ranges for Physiological Values in Captive Wildlife. International Species Information System, Eagan, MN.
- Jacobson, L.S., 2006. The South African form of severe and complicated canine babesiosis: clinical advances 1994–2004. *Vet. Parasitol.* 138, 126–139.
- Jefferies, R., Ryan, U.M., Irwin, P.J., 2007. PCR-RFLP for the detection and differentiation of the canine piroplasm species and its use with filter paper-based technologies. *Vet. Parasitol.* 144 (1–2), 20–27.
- Kjemtrup, A.M., Conrad, P.A., 2000. Human babesiosis: an emerging tick-borne disease. *Int. J. Parasitol.* 30 (12–13), 1323–1337.
- Ladds, P., 2009. Protozoal diseases in terrestrial mammals. In: Ladds, P. (Ed.), *Pathology of Australian Native Wildlife*. CSIRO Publishing, Collingwood, pp. 219–220.
- Larkin, M.A., Blackshields, G., Brown, N.P., Chenna, R., McGettigan, P.A., McWilliam, H., et al., 2007. Clustal W and Clustal X version 2.0. *Bioinformatics* 23 (21), 2947–2948.
- Lee, J.Y., Ryan, U.M., Jeffries, R., McInnes, L.M., Forshaw, D., Firmed, J.A., et al., 2009. *Theileria gilberti* sp. (Apicomplexa: Theileriidae) in the Gilbert's Potoroo (*Potorous gilbertii*). *J. Eukaryot. Microbiol.* 56, 290–295.
- Mackerras, M.J., 1959. The haematozoa of Australian mammals. *Aust. J. Zool.* 7, 105–135.
- O'Connor, R.M., Allred, D.R., 2000. Selection of *Babesia bovis*-infected erythrocytes for the adhesion to endothelial cells co-selects for the altered variant erythrocyte surface antigen isoforms. *J. Immunol.* 164 (4), 2037–2045.
- O'Donoghue, P.J., Adlard, R.D., 2000. Catalogue of protozoan parasites recorded in Australia. *Mem. Qld. Mus.* 45, 1–163.
- Paparini, A., Ryan, U.M., Warren, K., McInnes, L.M., de Tores, P., Irwin, P.J., 2012. Identification of novel *Babesia* and *Theileria* genotypes in the endangered marsupials, the woylie (*Bettongia penicillata ogilbyi*) and boodie (*Bettongia lesueur*). *Exp. Parasitol.* 131, 25–30.
- Rose, K.A., Kirkland, P.D., Davis, R.J., Cooper, D.W., Blumstein, D., Pritchard, L.I., et al., 2012. Epizootics of sudden death in Tammar Wallabies (*Macropus eugenii*) associated with an orbivirus infection. *Aust. Vet. J.* 90 (12), 505–509.
- Schettler, T.P.M., Eling, W.M.C., 1999. Can *Babesia* infections be used as a model for cerebral malaria? *Parasitol. Today* 15, 492–497.
- Schnittger, L., Rodriguez, A.E., Florin-Christensen, M., Morrison, D.A., 2012. *Babesia*: a world emerging. *Infect. Genet. Evol.* 1298, 1788–1809.
- Senanayake, S.N., Paparini, A., Latimer, M., Andriolo, K., Dasilva, A.J., Wilson, H., et al., 2012. First report of human babesiosis in Australia. *Med. J. Aust.* 196 (5), 350–352.
- Soares, J.F., Giroto, A., Brandau, P.E., Da Silva, A.S., Franca, R.T., Lopes, S.T.A., et al., 2011. Detection and molecular characterization of a canine piroplasm from Brazil. *Vet. Parasitol.* 180, 203–208.
- Solano-Gallego, L., Baneth, G., 2011. Babesiosis in dogs and cats – expanding parasitological and clinical spectra. *Vet. Parasitol.* 181, 48–60.
- Tamura, K., Nei, M., 1993. Estimation of the number of nucleotide substitutions in the control region of mitochondrial DNA in humans and chimpanzees. *Mol. Biol. Evol.* 10 (3), 512–526.
- Tamura, K., Peterson, D., Peterson, N., Stecher, G., Nei, M., Kumar, S., 2011. MEGA5: molecular evolutionary genetics analysis using the maximum likelihood, evolutionary distance and maximum parsimony methods. *Mol. Biol. Evol.* 28 (10), 2731–2739.
- Taylor, M.A., Coop, R.L., Wall, R.L., 2007. *Veterinary Parasitology*, third ed. Blackwell Publishing, Oxford, UK.
- Vogelnest, L., Portas, T., 2008. Macropods. In: Vogelnest, L., Woods, R. (Eds.), *Medicine of Australian Mammals*. CSIRO Publishing, Collingwood, pp. 133–225.
- Wright, I.G., 1972. An electron microscopy study of intravascular agglutination in the cerebral cortex due to *Babesia argentina* infection. *Int. J. Parasitol.* 2, 209–215.
- Yabsley, M.J., Shock, B.C., 2013. Natural history of zoonotic *Babesia*: role of wildlife reservoirs. *Int. J. Parasitol. Parasites Wildl.* 2, 18–31.