

This is an Open Access article licensed under the terms of the Creative Commons Attribution-NonCommercial 3.0 Unported license (CC BY-NC) ([www.karger.com/OA-license](http://www.karger.com/OA-license)), applicable to the online version of the article only. Distribution permitted for non-commercial purposes only.

# *Helicobacter suis*-Infected Nodular Gastritis and a Review of Diagnostic Sensitivity for *Helicobacter heilmannii*-Like Organisms

Shigeki Goji<sup>a</sup> Yasuhiro Tamura<sup>a</sup> Makoto Sasaki<sup>a</sup> Masahiko Nakamura<sup>b</sup>  
Hidenori Matsui<sup>c</sup> Somay Yamagata Murayama<sup>d</sup> Masahide Ebi<sup>a</sup>  
Naotaka Ogasawara<sup>a</sup> Yasushi Funaki<sup>a</sup> Kunio Kasugai<sup>a</sup>

<sup>a</sup>Department of Gastroenterology, Aichi Medical University School of Medicine, Nagakute,

<sup>b</sup>School of Pharmacy and <sup>c</sup>Kitasato Institute for Life Sciences, Kitasato University, Tokyo,

and <sup>d</sup>Laboratory of Molecular Cell Biology, School of Pharmacy, Nihon University, Funabashi, Japan

## Key Words

*Helicobacter heilmannii*-like organisms · *Helicobacter suis* · Urea breath test · Rapid urease test · Stool antigen test

## Abstract

*Helicobacter heilmannii*-like organisms (HHLOs) are associated with mucosa-associated lymphoid tissue lymphoma and peptic ulcer. However, the sensitivity of diagnostic tests for HHLOs, such as rapid urease test (RUT), urea breath test (UBT) and blood antibody, is not high. Tightly coiled spiral microorganisms were found in the gastric mucosal biopsy specimen of a 48-year-old asymptomatic woman. Her findings were positive for RUT and UBT, but negative for blood antibody and stool antigen against *H. pylori*. A 7-day course of esomeprazole, amoxicillin and clarithromycin was administered, resulting in the successful eradication of the HHLOs. Analysis of the 16S rRNA and urease genes suggested a diagnosis of the HHLO *H. suis*. The sensitivity results of RUT, UBT, culture, blood antibody, immunohistochemistry and stool antigen were 40.0, 14.8, 0, 23.1, 40.0 and 0%, respectively. We report asymptomatic nodular gastritis due to an HHLO. Histological techniques, most likely with smears, are expected to be the most effective method for diagnosing infections by HHLOs, and genetic diagnosis by polymerase chain reaction can be very useful to identify the species of HHLOs.

© 2015 S. Karger AG, Basel

## Introduction

*Helicobacter* species are Gram-negative, spiral-shaped bacteria. *Helicobacter* species other than *H. pylori*, including *H. heilmannii* and *H. felis*, also referred to as *H. heilmannii*-like organisms (HHLOs), have been identified in gastric mucosa-associated lymphoid tissue lymphoma and peptic ulcer in humans. HHLOs are found in a small percentage of human subjects (0.1–6%) [1, 2]; however, HHLO infection is prevalent in gastric mucosa-associated lymphoid tissue lymphoma [3, 4]. HHLO infection is very common in dogs, cats, pigs and nonhuman primates [5, 6].

HHLO infection is most frequently diagnosed by histopathology to identify the organism's morphology. Culture of HHLOs by traditional *H. pylori* culture techniques is difficult, although one research group has been successful [7]. The <sup>13</sup>C urea breath test (UBT) may be used to detect gastric HHLOs in animals [5, 8]. Some human cases have yielded positive results by the rapid urease test (RUT), the UBT and anti-*H. pylori* antibody, although the sensitivity of these tests is unclear. We report a case of nodular gastritis with HHLO infection diagnosed as *H. suis* by genetic sequencing. We also review the sensitivity of HHLO diagnostic methods.

## Methods

### DNA Extraction

Gastric biopsy samples were digested in SNET buffer (1% SDS, 400 mM NaCl, 5 mM EDTA, 20 mM Tris-HCl, pH 8.0) containing proteinase K (0.2 mg/ml) overnight at 50°C. After 10-min incubation at 95°C, the sample was serially diluted tenfold. The DNA was stored at –20°C until use.

### Amplification of HHLO-Specific or *H. pylori*-Specific DNA

At least 1-, 10- or 100-fold diluted samples were used as DNA templates for polymerase chain reaction (PCR). PCR amplification involved Ampdirect® Plus (Shimadzu Corporation, Kyoto, Japan), BIOTAQ™ HS DNA Polymerase (Shimadzu Corporation), 0.5 μM each of primers HeilF and HeilR (HHLO-specific) or VAC3624F and VAC4041R (*H. pylori*-specific) [9] using a CFX96 thermal cycler (Bio-Rad Laboratories Inc., Hercules, Calif., USA).

### Amplification and Sequencing of Urease Genes

Urease genes were amplified using primer pairs U430F and U1735R or U430F and U2235R (urease two, 1,752 bp) [10]. The products were sequenced commercially (Fasmac Co. Ltd., Atsugi, Japan) with the same primers and other primers (U850F, U1050R and U1350F) [10]. The sequences were compared with those in the NCBI GenBank by using the BLAST search tool (<http://blast.ncbi.nlm.nih.gov/Blast.cgi>).

## Case Presentation

In June 2013, a 48-year-old woman was diagnosed with nodular gastritis by esophago-gastroduodenal endoscopy at Marin clinic. Histology was positive for HHLO. Nothing abnormal except for gastritis was pointed out. The patient was referred to Aichi Medical University Hospital for treatment in August. She did not have any related medical history and had never come in contact with domestic animals, including cats and dogs. Esophagogastroduodenal

endoscopy showed antral nodular gastritis without mucosal atrophy; the corpus was normal (fig. 1). The  $^{13}\text{C}$  UBT finding was positive with a  $^{13}\text{C}$  value of 3.3% (cutoff value 2.5%). The RUT (PYLORITEK®, Serim Research Corp., Elkhart, Ind., USA) finding was positive in 30 min, but the results of the stool antigen and serum anti-*H. pylori* IgG antibody tests were negative. However, HHLO of characteristic morphology was found in the antral mucosa and in a gastric pit only (fig. 2). Histopathology showed mild chronic gastritis in the stomach antrum and corpus mucosa and no atrophy or intestinal metaplasia. The patient was treated with a 7-day course of triple therapy consisting of esomeprazole, amoxicillin and clarithromycin. There were no adverse events. Two months after therapy, UBT findings were negative (0.8%).

We obtained informed consent from patients and investigated the HHLO by PCR. An HHLO-specific amplicon was obtained from the sample. The sequences of the 16S rRNA gene (1,167 bp; fig. 3a) and the urease gene (916 bp, including a 4-bp undetermined sequence; fig. 3b) were determined. The 16S rRNA gene sequence of the sample showed 99% (1,162/1,167) and 96% (1,117/1,165) sequence identity with that of *H. suis* type strain HS1<sup>T</sup> (NR\_044169) and *H. heilmannii* type strain ASB1<sup>T</sup> (HE984298), respectively. The urease gene sequence of the sample showed 96% (882/918) sequence identity with sequences from GenBank accession no. AB968248, AB968247 and AF508001 from *H. suis* SH8, SH10 and HU4, respectively. The urease gene had 95% (772/815) identity with the sequence of *H. suis* type strain HS1<sup>T</sup> (EF204592), whereas it had only 82% (659/801), 81% (727/894) and 80% (692/860) identity with corresponding sequences of *H. bizzozeronii* type strain Storkis<sup>T</sup> (AF508003), *Candidatus H. heilmannii* reference strain HU2<sup>R</sup> (AF508012) and *H. heilmannii* type strain ASB1<sup>T</sup> (HE984298), respectively. On the basis of both sequences, we conclude that the species of the strain is *H. suis*.

## Discussion

We reported an asymptomatic patient with *H. suis*-infected nodular gastritis demonstrated by biopsy specimens. Genetic diagnosis of this infection by PCR was very useful to identify the HHLO species as *H. suis*.

HHLO is a zoonotic agent transmitted from animals to humans [11], and most infected persons complain of dyspepsia, epigastric pain or acid reflux [12, 13]. However, the current patient had no contact with domestic animals, including cats and dogs. Moreover, she had no symptoms despite histologically mild chronic gastritis. Stolte and colleagues [3, 4, 14] reported that HHLO infection is more often focal, with fewer organisms, and usually restricted to the gastric antrum, with less severe gastritis than *H. pylori* infection, leading to the rarity of concurrent erosions and ulcers.

Gastric non-*H. pylori* helicobacters, which are morphologically long, spiral-shaped bacteria, were originally referred to as *Gastrospirillum hominis* and later as *H. heilmannii*. *H. heilmannii* was further subdivided in two taxa, types 1 and 2. *H. heilmannii* type 2 is a group of species that colonize the gastric mucosa: *H. felis*, *H. bizzozeronii*, *H. salomonis*, *H. cynogastricus*, *H. baculiformis* and *Candidatus H. heilmannii*. On the other hand, *H. suis* has been accepted as a new gastric *Helicobacter* taxon corresponding to type 1 *H. heilmannii* [15]. The cells of this new species are tightly coiled spirals with up to six turns, which are approximately 2.3–6.7  $\mu\text{m}$  long and 0.9–1.2  $\mu\text{m}$  wide. They have bipolar tufts of 4–10 sheathed flagella that are blunt-ended or end in spherical knobs [15].

The characteristic morphology of HHLOs can be identified in biopsy specimens stained with hematoxylin and eosin, Giemsa or Warthin-Starry silver stains. The present case was also diagnosed by morphology on the basis of gastric biopsy examination, as in many report-

ed cases. However, HHLOs are better diagnosed on smears (touch cytology) than biopsies [13, 16] because they are typically found in the mucus layer above the surface and foveolar epithelial cells and do not show the intimate adherence, pedestal formation or invasion in the intercellular spaces often seen with *H. pylori*.

Other diagnostic tests in the present case showed positive results for UBT and RUT and negative results for stool antigen and serum anti-*H. pylori* IgG antibody. The sensitivity of diagnostic tests for HHLOs is summarized in table 1. The findings were as follows: RUT 40.0%, UBT 14.8%, culture 0%, blood antibody 23.1%, immunohistochemistry 40.0% and stool antigen 0%. As expected, in vitro culture of HHLO failed in 55 patients, although culture was successful in the cat stomach [17]. The urease test seems useful for diagnosing HHLO infection, although it is difficult to distinguish HHLO from *H. pylori* infection. The rate of urease positivity appears to be lower than that for *H. pylori*. HHLOs probably have a lower amount of urease than *H. pylori*, and the test might be positive only when numerous organisms are present in the tested specimen. The UBT and RUT tests are highly sensitive and specific for HHLO in animals, and the discrepancy in these diagnostic tests in humans and animals is unclear [5, 7]. Serological and immunohistochemical tests with *H. pylori* antibody yielded lower positivity rates for HHLO than for *H. pylori* infection itself. The enzyme-linked immunosorbent assay of stool with *H. pylori* polyclonal antigens showed cross-reactivity with HHLO antigens. It is critical to develop HHLO-specific antibodies for serological, immunohistochemical and stool tests.

In the present case, PCR was used to identify the species of HHLO as *H. suis*. PCR-based studies have been used to identify HHLOs in humans [4] and animals [3, 4, 18]. Chisholm and Owen [9] performed PCR using gastric biopsies, showing an HHLO prevalence rate of 2.3% in Southeast England. However, this prevalence rate is not as high as that diagnosed by morphology. PCR sensitivity for HHLOs may be lower in clinical practice, and the typical morphological features on hematoxylin and eosin staining seem sufficient to diagnose HHLO infection with chronic gastritis.

## Conclusion

We describe asymptomatic nodular gastritis infection associated with an HHLO. Histological techniques, most likely with smears, will be the most effective method for diagnosing HHLO infection. Furthermore, genetic diagnosis by PCR was shown to be very useful to identify the species of non-*H. pylori* helicobacters.

## Acknowledgement

We would like to thank Editage (www.editage.jp) for English language editing.

## Disclosure Statement

None of the contributing authors have any conflict of interest, including specific financial interests or relationships and affiliations relevant to the subject matter or materials discussed in this paper.

Goji et al.: *Helicobacter suis*-Infected Nodular Gastritis and a Review of Diagnostic Sensitivity for *Helicobacter heilmannii*-Like Organisms

## References

- 1 Ierardi E, Monno RA, Gentile A, Francavilla R, Burattini O, Marangi S, Pollice L, Francavilla A: *Helicobacter heilmannii* gastritis: a histological and immunohistochemical trait. *J Clin Pathol* 2001;54:774–777.
- 2 Yakoub J, Abbas Z, Khan R, Naz S, Ahmad Z, Islam M, Awan S, Jafri F, Jafri W: Prevalence of non *Helicobacter pylori* species in patients presenting with dyspepsia. *BMC Gastroenterol* 2012;12:3.
- 3 Stolte M, Bayerdorffer E, Morgner A, Alpen B, Wundisch T, Thiede C, Neubauer A: Helicobacter and gastric MALT lymphoma. *Gut* 2002;50(suppl 3):III19–III24.
- 4 Morgner A, Lehn N, Andersen LP, Thiede C, Bennedsen M, Trebesius K, Neubauer B, Neubauer A, Stolte M, Bayerdorffer E: *Helicobacter heilmannii*-associated primary gastric low-grade MALT lymphoma: complete remission after curing the infection. *Gastroenterology* 2000;118:821–828.
- 5 Neiger R, Dieterich C, Burnens A, Waldvogel A, Corthesy-Theulaz I, Halter F, Lauterburg B, Schmassmann A: Detection and prevalence of Helicobacter infection in pet cats. *J Clin Microbiol* 1998;36:634–637.
- 6 Queiroz DM, Rocha GA, Mendes EN, De Moura SB, De Oliveira AM, Miranda D: Association between Helicobacter and gastric ulcer disease of the pars esophagea in swine. *Gastroenterology* 1996;111:19–27.
- 7 Trevena WB, Hooper RS, Wray C, Willshaw GA, Cheasty T, Domingue G: Vero cytotoxin-producing *Escherichia coli* O157 associated with companion animals. *Vet Rec* 1996;138:400.
- 8 Kubota S, Ohno K, Tsukamoto A, Maeda S, Murata Y, Nakashima K, Fukushima K, Uchida K, Fujino Y, Tsujimoto H: Value of the 13C-urea breath test for detection of gastric Helicobacter spp. infection in dogs undergoing endoscopic examination. *J Vet Med Sci* 2013;75:1049–1054.
- 9 Chisholm SA, Owen RJ: Development and application of a novel screening PCR assay for direct detection of ‘*Helicobacter heilmannii*’-like organisms in human gastric biopsies in Southeast England. *Diagn Microbiol Infect Dis* 2003;46:1–7.
- 10 O’Rourke JL, Solnick JV, Neilan BA, Seidel K, Hayter R, Hansen LM, Lee A: Description of ‘*Candidatus Helicobacter heilmannii*’ based on DNA sequence analysis of 16S rRNA and urease genes. *Int J Syst Evol Microbiol* 2004;54:2203–2211.
- 11 Baele M, Pasmans F, Flahou B, Chiers K, Ducatelle R, Haesebrouck F: Non-*Helicobacter pylori* helicobacters detected in the stomach of humans comprise several naturally occurring Helicobacter species in animals. *FEMS Immunol Med Microbiol* 2009;55:306–313.
- 12 Hilzenrat N, Lamoureux E, Weintrub I, Alpert E, Lichter M, Alpert L: *Helicobacter heilmannii*-like spiral bacteria in gastric mucosal biopsies. Prevalence and clinical significance. *Arch Pathol Lab Med* 1995;119:1149–1153.
- 13 Debonnie JC, Donnay M, Mairesse J: *Gastrospirillum hominis* (*Helicobacter heilmannii*): a cause of gastritis, sometimes transient, better diagnosed by touch cytology? *Am J Gastroenterol* 1995;90:411–416.
- 14 Stolte M, Kroher G, Meining A, Morgner A, Bayerdorffer E, Bethke B: A comparison of *Helicobacter pylori* and *H. heilmannii* gastritis. A matched control study involving 404 patients. *Scand J Gastroenterol* 1997;32:28–33.
- 15 Baele M, Decostere A, Vandamme P, Ceelen L, Hellemans A, Mast J, Chiers K, Ducatelle R, Haesebrouck F: Isolation and characterization of *Helicobacter suis* sp. nov. from pig stomachs. *Int J Syst Evol Microbiol* 2008;58:1350–1358.
- 16 Debonnie JC, Donnay M, Mairesse J, Lamy V, Dekoninck X, Ramdani B: Gastric ulcers and *Helicobacter heilmannii*. *Eur J Gastroenterol Hepatol* 1998;10:251–254.
- 17 Lee A, Dent J, Hazell S, McNulty C: Origin of spiral organisms in human gastric antrum. *Lancet* 1988;1:300–301.
- 18 Norris CR, Marks SL, Eaton KA, Torabian SZ, Munn RJ, Solnick JV: Healthy cats are commonly colonized with ‘*Helicobacter heilmannii*’ that is associated with minimal gastritis. *J Clin Microbiol* 1999;37:189–194.
- 19 Dye KR, Marshall BJ, Frierson HF Jr, Guerrant RL, McCallum RW: Ultrastructure of another spiral organism associated with human gastritis. *Dig Dis Sci* 1989;34:1787–1791.
- 20 Morris A, Ali MR, Thomsen L, Hollis B: Tightly spiral shaped bacteria in the human stomach: another cause of active chronic gastritis? *Gut* 1990;31:139–143.
- 21 Figura N, Guglielmetti P, Quaranta S: Spiral shaped bacteria in gastric mucosa. *J Clin Pathol* 1990;43:173.
- 22 Fischer R, Samisch W, Schwenke E: ‘*Gastrospirillum hominis*’: Another four cases. *Lancet* 1990;335:59.
- 23 Wegmann W, Aschwanden M, Schaub N, Aenishanslin W, Gyr K: Gastritis associated with *Gastrospirillum hominis* – a zoonosis? *Schweiz Med Wochenschr* 1991;121:245–254.
- 24 Borody TJ, George LL, Brandl S, Andrews P, Ostapowicz N, Hyland L, Devine M: *Helicobacter pylori*-negative duodenal ulcer. *Am J Gastroenterol* 1991;86:1154–1157.
- 25 Mazzucchelli L, Wilder-Smith CH, Ruchti C, Meyer-Wyss B, Merki HS: *Gastrospirillum hominis* in asymptomatic, healthy individuals. *Dig Dis Sci* 1993;38:2087–2089.
- 26 Lavelle JP, Landas S, Mitros FA, Conklin JL: Acute gastritis associated with spiral organisms from cats. *Dig Dis Sci* 1994;39:744–750.
- 27 Yang H, Li X, Xu Z, Zhou D: ‘*Helicobacter heilmannii*’ infection in a patient with gastric cancer. *Dig Dis Sci* 1995;40:1013–1014.



Goji et al.: *Helicobacter suis*-Infected Nodular Gastritis and a Review of Diagnostic Sensitivity for *Helicobacter heilmannii*-Like Organisms

- 28 Akin OY, Tsou VM, Werner AL: *Gastrospirillum hominis*-associated chronic active gastritis. *Pediatr Pathol Lab Med* 1995;15:429–435.
- 29 Koyanagi M, Tanaka M, Nishi T, Kawaguchi H, Kudo H: Acute gastric mucosal lesions accompanied by *Gastrospirillum hominis*, report of a case. *Stomach Intestine* 1995;30:1079–1083.
- 30 Goddard AF, Logan RP, Atherton JC, Jenkins D, Spiller RC: Healing of duodenal ulcer after eradication of *Helicobacter heilmannii*. *Lancet* 1997;349:1815–1816.
- 31 Isomoto H, Matsunaga K, Shikuwa S, Ofukuji M, Mizuta Y, Makiyama K, Kohno S: A case of *Gastrospirillum hominis*-associated corpus gastritis. *Gastroenterol Endosc* 1997;39:68–72.
- 32 Chen Y, Zhou D, Wang J: Biological diagnostic and therapeutic study on the infection of *Helicobacter heilmannii*. *Zhonghua Yi Xue Za Zhi* 1998;78:490–493.
- 33 Jhala D, Jhala N, Lechago J, Haber M: *Helicobacter heilmannii* gastritis: association with acid peptic diseases and comparison with *Helicobacter pylori* gastritis. *Mod Pathol* 1999;12:534–538.
- 34 Yamamoto T, Matsumoto J, Shiota K, Kitajima S, Goto M, Imaizumi M, Arima T: *Helicobacter heilmannii* associated erosive gastritis. *Intern Med* 1999;38:240–243.
- 35 Kamoshida T, Hotta S, Hirai S, Oka Y: A case of *Helicobacter heilmannii*-associated antral gastritis diagnosed by McMullen modified staining. *Gastroenterol Endosc* 2000;42:974–979.
- 36 Yoshimura M, Isomoto H, Shikuwa S, Osabe M, Matsunaga K, Omagari K, Mizuta Y, Murase K, Murata I, Kohno S: A case of acute gastric mucosal lesions associated with *Helicobacter heilmannii* infection. *Helicobacter* 2002;7:322–326.
- 37 Boyanova L, Koumanova R, Lazarova E, JeleV C: *Helicobacter pylori* and *Helicobacter heilmannii* in children. A Bulgarian study. *Diagn Microbiol Infect Dis* 2003;46:249–252.
- 38 Singhal AV, Sepulveda AR: *Helicobacter heilmannii* gastritis: a case study with review of literature. *Am J Surg Pathol* 2005;29:1537–1539.
- 39 Kato S, Ozawa K, Sekine H, Ohyauchi M, Shimosegawa T, Minoura T, Iinuma K: *Helicobacter heilmannii* infection in a child after successful eradication of *Helicobacter pylori*: case report and review of literature. *J Gastroenterol* 2005;40:94–97.
- 40 Oyauchi M, Ohara S, Sekine H, Shimosegawa T: Barrett's adenocarcinoma with *Helicobacter heilmannii* infection, report of a case. *Stomach Intestine* 2006;41:1089–1093.
- 41 Boyanova L, Lazarova E, JeleV C, Gergova G, Mitov I: *Helicobacter pylori* and *Helicobacter heilmannii* in untreated Bulgarian children over a period of 10 years. *J Med Microbiol* 2007;56:1081–1085.
- 42 Qualia CM, Katzman PJ, Brown MR, Kooros K: A report of two children with *Helicobacter heilmannii* gastritis and review of the literature. *Pediatr Dev Pathol* 2007;10:391–394.
- 43 Ohtaka M, Tatsumi A, Fukasawa M, Yamaguchi T, Uetake T, Ohtsuka H, Sato T, Enomoto N, Watanabe H, Mitani K: Complete remission of gastric plasmacytoma following eradication of 'Candidatus *Helicobacter heilmannii*'. *Clin J Gastroenterol* 2012;5:158–163.
- 44 Matsumoto T, Kawakubo M, Akamatsu T, Koide N, Ogiwara N, Kubota S, Sugano M, Kawakami Y, Katsuyama T, Ota H: *Helicobacter heilmannii* sensu stricto-related gastric ulcers: a case report. *World J Gastroenterol* 2014;20:3376–3382.

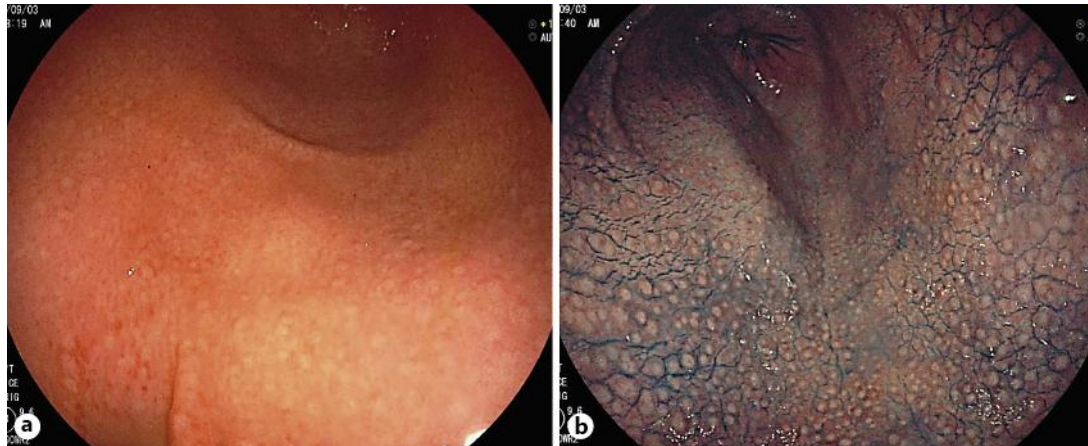Goji et al.: *Helicobacter suis*-Infected Nodular Gastritis and a Review of Diagnostic Sensitivity for *Helicobacter heilmannii*-Like Organisms

**Table 1.** Sensitivity of diagnostic tests for HHLOs

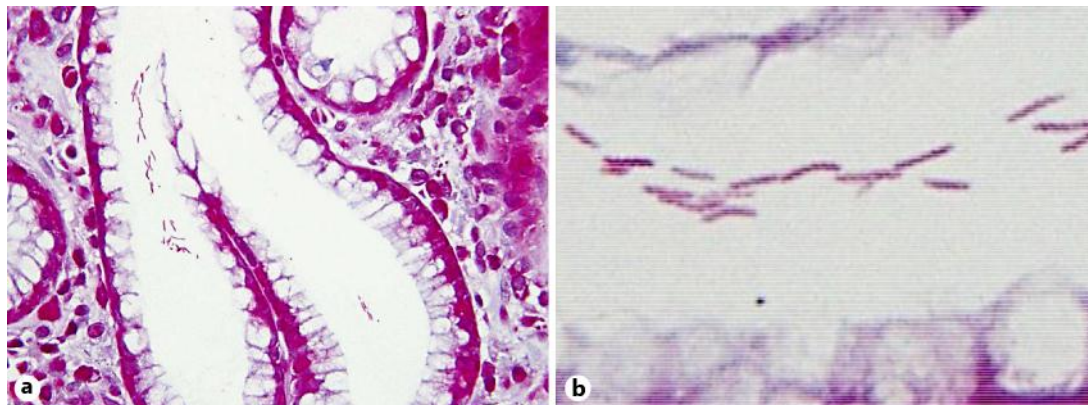
Year	First author	RUT		UBT		Culture		Blood Ab ( <i>H. pylori</i> )		IHC ( <i>H. pylori</i> )		Stool Ag ( <i>H. pylori</i> )		Refer- ence
		+	-	+	-	+	-	+	-	+	-	+	-	
1989	Dye	2	0			0	1							19
1990	Morris	2	0			0	2	0	2					20
1990	Figura	1	1			0	2	0	2					21
1990	Fischer	0	4			0	3							22
1991	Wegmann	2	3											23
1991	Borody	0	2			0	2							24
1993	Mazzucchelli	0	2	0	2	0	2							25
1994	Lavelle	1	0											26
1995	Yang	1	0											27
1995	Hilzenrat							0	3					12
1995	Akin	1	0											28
1995	Koyanagi									0	1			29
1997	Goddard	1	0			0	1							30
1997	Isomoto							0	1					31
1998	Chen	14	6	3	17	0	20							32
1998	Debongnie	1	8			0	7	1	8					16
1999	Jhala	3	2			0	4	5	0					33
1999	Yamamoto	1	0			0	1	0	1	0	1			34
2000	Kamoshida	1	0			0	1			0	1			35
2002	Yoshimura	1	0			0	1							36
2003	Boyanova	1	0			0	1							37
2005	Singhal									1	0			38
2005	Kato			0	1	0	1					0	1	39
2006	Oyauchi	1	0	0	1	0	1	0	1			0	1	40
2007	Boyanova	2	0			0	2							41
2007	Qualia	1	1											42
2012	Ohtaka			0	1			0	1					43
2014	Matsumoto			0	1	0	1			1	0			44
2015	Goji	1	0	1	0			0	1			0	1	present case
Total		40	29	4	23	0	55	6	20	2	3	0	3	
Positive rate		40.0%		14.8%		0%		23.1%		40.0%		0%		

Ab = Antibody; Ag = antigen; IHC = immunohistochemistry.

Goji et al.: *Helicobacter suis*-Infected Nodular Gastritis and a Review of Diagnostic Sensitivity for *Helicobacter heilmannii*-Like Organisms



**Fig. 1.** **a** White light endoscopy of the antrum showed small, round, yellowish-white nodules, which were the features of *H. pylori*-infected mucosa. **b** The nodular pattern can be clearly observed with indigo carmine spreading.



**Fig. 2.** **a** Giemsa staining of the antral mucosa showed mild chronic gastritis and microbial colonies in a pit ( $\times 400$ ). **b** Long, tightly spiraled microorganisms were observed ( $\times 1,000$ ).



### 16S rRNA gene sequence (1167 bp)

GGGCAGTAGCTGCTTTAGCATCCTGACTTAAGGCAAACAACCTCCCATGGTGTGACGGGCGGTGAGTACAAGA  
 CCCGGGAACGTATTCACCGCAACATAGCTGATTTGCGATTACTAGCGATTCCAGCTTCATGCAGGGCAGTTGCAGC  
 CTGCAATCCGAACCTAGGAGGTGTTTTATAGATTAGCTCTGCCTCGCGGCTTTGCATCTCTTTGTGCACCCATTGTA  
 GCACGTGTGTAGCCCTAGGCGTAAGGGCCATGATGACTTGACGTGTCCTCACCTTCCTCTGCTTACGCAGGCAG  
 TCTTCTTAGAGTGCAGCAGATAACCTGTTAGCAACTAAGAAAAAGGGTTGCGCTCGTTGCGGGACTTAACCAAC  
 ATCTCAGACACGAGCTGACGACAGCCGTGCAGCACCTGTTTTAGGGTCTAGCAAGCTAGACACTCCCTATTTT  
 TAGGGAATTCCTCAATGTAAGCCTAGGTAAGGTTCTTCGTGTAACATCGAATTAACCACATGCTCCACCGCTT  
 TGCGGGTCCCGTCTATTCTTTGAGTTTTAATCTTGCGACCGTACTCCCAGGCGGGATGCTAAGGCGTTAGCT  
 GCATTACTGGAAAGACAAAGCTTCCAACAACCTAGCATCCATCGTTTAGGGCGTGGACTACCAGGGTATCTAATCC  
 TGTTTGCTCCCCACGCTTTCGTGCAATCAGCGTCAGTGATGTTCCAGCAGGTGCGCTTCGCAATGAGTATTCCTTT  
 GATCTCTACGGATTTACCCCTACACCAAGAATCCACCTACCTCTCCCACTCCAGAAGGATAGTTTCAAATGCA  
 GTTCTATGGTTAAGCCATAGGATTTACACCTGACTTGTCTCCCGCTACGCACTTTACGCCAGTGATTCGGA  
 GTAACGCTTGACCCCTCCGTATTACCGCGGCTGCTGGCACGGAGTTAGCCGGTGCTTATTCTGTTAGATACCGTCA  
 ATCTTCTAACAAGGAGTTACGATCTAAACCTTCATCTCCACGCGGGTGTGCTGCTTCAAGGTTTCCCC  
 ATTGAGCAATATCCCTACTGCTGCTCCCGTAGGAGTCTGACCGTGTCTCAGTTCAGTGTGCTCCGCTCACCTC  
 TCAGGCCGATACCCGTCATAG

**a**

### Urease gene sequence (916 bp)

TCGGTGTGGATAGCCACTTGTACATCATACTCATCAGCAATTTAAGAGCATGGTGGATAGCTGAAGGTGTGCTGC  
 CCCAGTCTTCATGGATTTAAAGCCAATAGCCCCAGCTTCCAAGTTGGTCAACCAAGAAGGTTCAAGAAACCT  
 TACCTTTACCCATGATAGCTAAATTCATGGCGTATTCTCAGAGGCGCGGAGCATTCTTTAAATCCAGCGGCCT  
 GGAGTGATAGTTGTCGATTAGTACCATCAGCAGGGCCTGTTCCGCTCCAAGCATGGTTGTAATGCCGCTAGCAA  
 AAGCGGTGGGATTGTTGTGGAGAAATAAAGTGAATGTGGGTATCAATCCCGCCAGCTGTAACAATTAACCTT  
 CACCAGCTAGTGCTTCTGTAGCAGGACCTACACAAAGGCGGTTGCAAACGCCGCTTGAATGTCTTTATTGCCGGC  
 TTTACCAATGCCATGGATCTTGCATCTTAAATGCNAATGTCGGCTTTGTAANTCCCGGTGTAGTTTACAATTAGGG  
 CGTTAGTAATCACTAAATCTAACTCATGGCTGCTGGGGCTATTGTTTGGCCATCCCATCGCGGATAGTTTTCCCG  
 CCCCCAAATTTGATTTCTCGCCATAAGTGGTGACGTCATGCTACTTCTAAAATCAGATATGTATCGCCTAGTCGG  
 AATTTATCGCCTGTAGNNGGGCCATACATAGAAACATATTCTTCTAGAGAACACCTCATCGCTTGTCTTTCCTTA  
 ATAAATTCGTGATCGCAACCGCAATTAACAGTGCCTAAATGTTTTGGTTTTGCGGTTTGAGAGCTAAATTTAGC  
 CACCGTATCGGCGGGGNCATCTACCAAAGCATTAAGCCAGAGATGCGTCGAN TCCGCGTACATCAATCAAA

**b**

**Fig. 3.** The 16S rRNA gene (1,167 bp, **a**) and the urease gene (916 bp, **b**) were sequenced commercially (Fasmac Co. Ltd.). N = Undetermined gene.