

Correlation between Fluorescein Angiographic Findings and Visual Acuity in Behçet Retinal Vasculitis

Min Kim,¹ Hee Jung Kwon,² Eun Young Choi,¹ Sung Soo Kim,² Hyoung Jun Koh,¹ and Sung Chul Lee²

¹Department of Ophthalmology, Gangnam Severance Hospital, Yonsei University College of Medicine, Seoul;

²Institute of Vision Research, Department of Ophthalmology, Severance Eye and ENT Hospital, Yonsei University College of Medicine, Seoul, Korea.

Received: July 7, 2014

Revised: August 27, 2014

Accepted: September 26, 2014

Corresponding author: Dr. Sung Chul Lee,
Institute of Vision Research,
Department of Ophthalmology,
Severance Eye and ENT Hospital,
Yonsei University College of Medicine,
50-1 Yonsei-ro, Seodaemun-gu,
Seoul 120-752, Korea.
Tel: 82-2-2228-3570, Fax: 82-2-312-0541
E-mail: sunglee@yuhs.ac

The material was presented as a poster at
2012 ARVO meeting.

The authors have no financial conflicts of
interest.

Purpose: To identify significant fluorescein angiographic (FA) characteristics associated with visual acuity (VA) in Behçet retinal vasculitis. **Materials and Methods:** Retrospective review of 86 eyes of 48 patients (age: 35.6±10.2 years) with Behçet retinal vasculitis were performed. VA and FA findings as well as correlation between them were assessed. **Results:** The mean initial VA of eyes with posterior pole-involved vasculitis (63 eyes; 73.3%) was significantly worse than that of those with peripheral vasculitis (23 eye; 26.7%) (logarithm of the minimum angle of resolution VA: 0.554±0.572 vs. 0.078±0.148; $p<0.0001$). Subgroup analysis revealed a more severe and diffuse pattern of vascular leakage in posterior pole-involved vasculitis compared to peripheral vasculitis ($p<0.0001$). Retinal vascular leakage ($\beta=0.345$; $p<0.0001$), optic disc hyperfluorescence ($\beta=0.147$; $p=0.032$), and macular leakage ($\beta=0.107$; $p=0.047$) were significantly associated with worse initial VA. During the follow up (mean: 33.3±17.9 months), the change of leakage showed no significant correlation with change of VA in posterior pole-involved vasculitis ($\tau=0.199$, $p=0.092$). **Conclusion:** Posterior pole involvement, the degree of retinal vascular leakage, optic disc hyperfluorescence, and macular leakage are significantly associated with VA in Behçet retinal vasculitis.

Key Words: Behçet retinal vasculitis, ocular Behçet disease, fluorescein angiography, visual acuity

INTRODUCTION

Behçet disease is a chronic and recurrent multisystem inflammatory disorder of unknown etiology. Although its exact pathogenesis remains unclear, the underlying pathology is an obliterative vasculitis that affects both the arteries and veins in all organs.¹ Ocular involvement, which can include anterior uveitis, vitritis, retinal vasculitis, optic neuropathy, and scleritis, occurs in approximately 70% of Behçet's cases, and the visual prognosis for a patient with posterior segment inflammation is generally considered to be poor.² Among many ocular manifestations, retinal vasculitis has been reported to be one of the most common ocular findings and suggested to be significantly correlated with visual prognosis in many studies.³⁻⁵ As chronic and recurrent inflammation of retinal vessels is of major concern in Behçet retinal

© Copyright:

Yonsei University College of Medicine 2015

This is an Open Access article distributed under the terms of the Creative Commons Attribution Non-Commercial License (<http://creativecommons.org/licenses/by-nc/3.0>) which permits unrestricted non-commercial use, distribution, and reproduction in any medium, provided the original work is properly cited.

vasculitis due to the cumulative damage it causes to retinal structures,⁶ the identification of specific angiographic findings of such pathology and their association with visual acuity (VA) bear clinical significance.

Fluorescein angiography (FA) is essential in assessing the activity and extent of the inflammation and monitoring the response to treatment in Behçet retinal vasculitis. FA allows for the recognition of retinal vascular inflammation based on fluorescein dye leakage from compromised retinal vessels as the breakdown of the inner blood retinal barrier occurs.⁷

Previous studies have explored the clinical features of Behçet uveitis in general.^{5,8} Although a few reports have described the fluorescein and indocyanine green angiographic findings in ocular Behçet's disease,⁹⁻¹¹ the correlations between various FA findings and VA were not taken into consideration in these studies. Further, the impact of vascular leakage severity and its changes on VA have not been previously explored.

In this retrospective study, we intend to identify clinically significant FA findings that are associated with VA and assess the correlations between changes of FA findings and VA in Behçet retinal vasculitis.

MATERIALS AND METHODS

Patient selection

A retrospective review was performed of the medical records of 68 consecutive patients with active retinal vasculitis associated with Behçet disease who had been examined between January 2007 and March 2011 at the Behçet Uveitis Clinic at the Yonsei University Medical Center. The study was approved by the Institutional Review Boards at the Yonsei University Medical Center (IRB approval number: 4-2011-0829) and was performed in accordance with the tenets of the Declaration of Helsinki and all federal laws. Inclusion of patients were based on the following criteria. First, patients that satisfied the diagnostic criteria of the International Study Group for Behçet disease¹² were identified. Then, their FA were retrospectively evaluated for signs of retinal vasculitis such as vascular sheathing or leakage and staining of the retinal capillaries or large vessels in FA. Only patients who presented with their first episode of active retinal vascular inflammation were included in the study.

The exclusion criteria were as follows: concurrent active infection, a history of tuberculosis, sarcoidosis, end-stage vasculitis with no light perception, a previous history of ocu-

lar inflammation, presence of any other disease, such as diabetic retinopathy and age-related macular degeneration, that could contribute to vascular leakage, inability to visualize the fundus due to a severe media opacity such as a dense cataract or a vitreous opacity, posterior synechiae, cataract or retinal surgery during the follow-up period, and macular pathologies, such as epiretinal membrane, macular holes, and optic nerve atrophy. In total, 86 eyes of 48 patients (27 males and 21 females; 10 patients with unilateral involvement; mean age: 35.63±10.18 years) were finally enrolled in the study.

Data collection

The demographic and clinical data gathered were age at the time of diagnosis, gender, laterality, HLA-B51 status, duration of follow up, best corrected Snellen visual acuity (BCVA) at initial presentation, at 2 years within +/- six months and at the last follow up. For BCVA at 2 years, the visit closest to the 2 year time point within a 3 months window was counted as the visit to be used. All patients were examined by the same uveitis specialist (SCL). Ophthalmic examinations included a slit lamp examination, a dilated fundus examination, and measurement of the intraocular pressure. Further, the Standardization of Uveitis Nomenclature (SUN) Group grading scheme was used for the assessment of the degree of inflammation in the anterior chamber and the vitreous.¹³ Patients underwent FA and optical coherence tomography (OCT) for the evaluation of retinal vasculitis and macular edema. FA findings at initial presentation and at 2 years within +/- three months were graded according to the FA classification described below.

For a change in VA to be considered as an improvement, there had to be an improvement of at least three Snellen chart lines between the initial VA and VA at 2 year time point within a 3 months window, whereas a drop of at least three Snellen chart lines was considered a worsening of VA. A change in VA of fewer than three lines was regarded as no change.

Imaging

Fluorescein angiography

Images were obtained with a confocal scanning laser ophthalmoscope (HRA 2; Heidelberg Engineering, Heidelberg, Germany). The images were selected from multiple early-phase and late-phase FA images, and analyzed by experienced, independent retinal specialists (MK and SCL).

We devised a grading system for retinal vasculitis by slightly modifying a grading criteria previously used in several studies.¹⁴⁻¹⁶ All classifications were based on the late phase of angiograms. The macular and posterior pole regions were delineated through the use of an image overlay with measuring capability that was built into the HRA system. To define a macular region of interest, an overlaid circle with a diameter of 1.5 mm was centered on the fovea in an FA image. To define the posterior pole, an overlaid circle with a diameter of 5.5 to 6.0 mm that approximated both the superior and inferior temporal vascular arcades was used (Fig. 1).

Eyes with retinal vasculitis were classified based on the

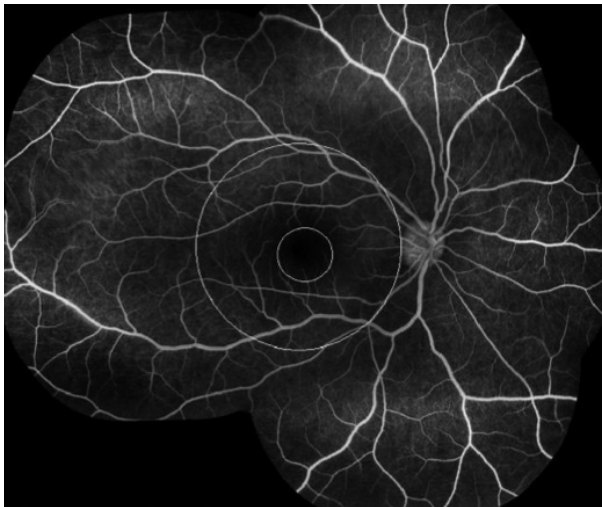


Fig. 1. An overlaid circle of diameter 5.5 mm was centered on the fovea to define the posterior pole region approximating the superior and inferior temporal vascular arcades in a patient with Behçet retinal vasculitis (the outer circle). The macular region was delineated with another overlaid circle of diameter 1.5 mm centered on the fovea (the inner circle).

anatomical location of the retinal vascular leakage. Those that exhibited leakage within the posterior pole were classified as having posterior pole-involved vasculitis, and those that only showed angiographic leakage in the periphery were defined as having peripheral vasculitis. The extent of the vascular leakage was classified as either focal-type in cases where there was a specific focus of dye leakage and/or if a well-defined focal area of leakage could be localized to within one quadrant, or diffuse-type if there was widespread leakage and/or a large area of multifocal leakage that involved more than one quadrant and did not have a specific focus of dye leakage (Fig. 2).

After classification based on the anatomical location of the leakage, those with posterior pole leakage were further evaluated to determine whether the macula was involved. Macular leakage was graded based on FA findings according to criteria previously proposed by Yannuzzi¹⁶ in which grade 0 equals no perifoveal hyperfluorescence, grade 1 indicates incomplete perifoveal hyperfluorescence, grade 2 indicates mild 360° hyperfluorescence, grade 3 indicates moderate 360° hyperfluorescence with the hyperfluorescent area being approximately 1 disc diameter across, and grade 4 indicates severe 360° hyperfluorescence with the hyperfluorescent area being approximately 1.5 disc diameters across (Fig. 3).

For the grading of the severity of the retinal vascular leakage in the late angiographic phases, a grading system similar to that used previously by others was adopted.^{14,15} Leakage was classified as mild for staining of vessels with minimal leakage, moderate for more intense leakage with a distinct vascular margin, and severe for even greater leakage with

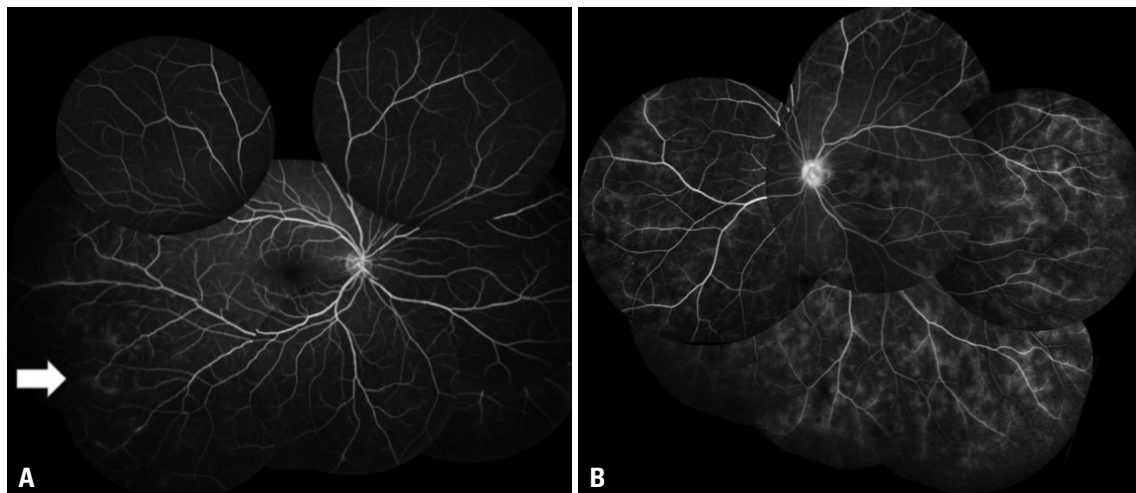


Fig. 2. Fluorescein angiogram showing focal leakage (A, arrow pointing at a focal leakage site at the infero-temporal quadrant) and diffuse vascular staining and leakage (B) in Behçet retinal vasculitis.

blurring of the large vessel margins (Fig. 4). In vasculitis involving the posterior pole, grading was performed with regard to only the retinal vessels outside the macular area to avoid the inclusion of the small vessel leakage associated with macular leakage in this grade.

Optic disc hyperfluorescence in the late angiographic phases was also graded using a system similar to that used previously by others.^{14,15} Hyperfluorescence was categorized as none (normal exiting of fluorescein and normal staining of the scleral rim), partial (partial staining of the optic disc), diffuse (diffuse leakage without blurring of the disc margin), and diffuse with blurring of the disc margin (Fig. 5).

For the evaluation of the change in vascular leakage during follow up, the magnitudes of retinal vascular leakage,

optic disc hyperfluorescence, and macular leakage were compared collectively between the initial FA and FA at 2 year time point (within +/- three months) in which the visit closest to the 2 year time point within a three month window was counted as the visit to be used. Then, they were categorized into three patterns. A change in the magnitude of the overall vascular leakage was considered an improvement or worsening of the leakage, depending on the direction of the change, whereas, the eye was considered to have had no change in vascular leakage, if there was no discernible difference in the degree of leakage. FA analysis was performed by two independent observers (MK and SCL) who were blind to the other's reading and the relevant clinical characteristics of the patients (such as VA and slit lamp

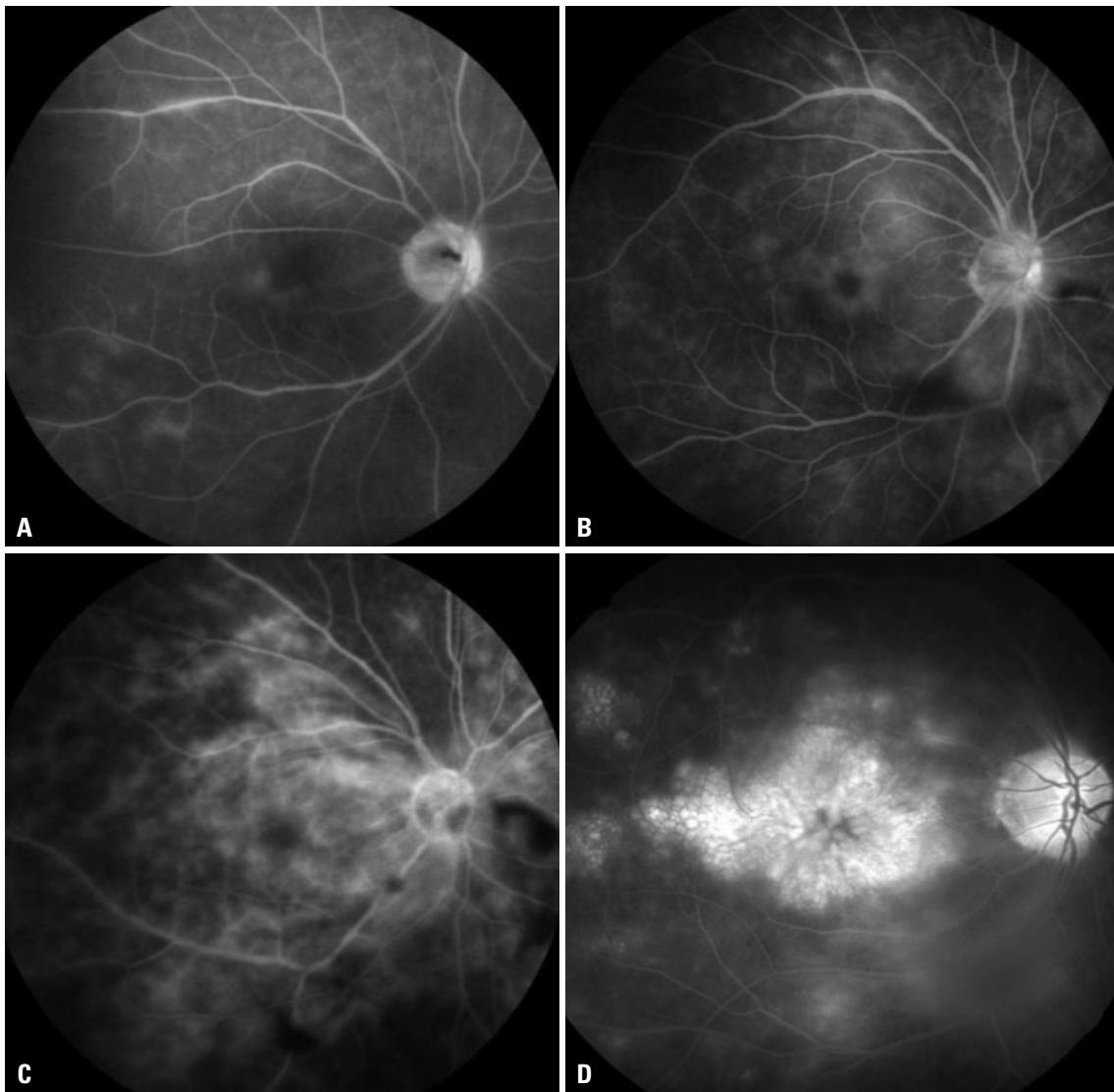


Fig. 3. Fluorescein angiograms demonstrating different grades of macular leakage in Behçet retinal vasculitis. Grade 1, incomplete perivascular hyperfluorescence (A); grade 2, mild 360° hyperfluorescence (B); grade 3, moderate 360° hyperfluorescence with the hyperfluorescent area being approximately 1 disc diameter across (C); grade 4, severe 360° hyperfluorescence with the hyperfluorescent area being approximately 1.5 disc diameters across (D).

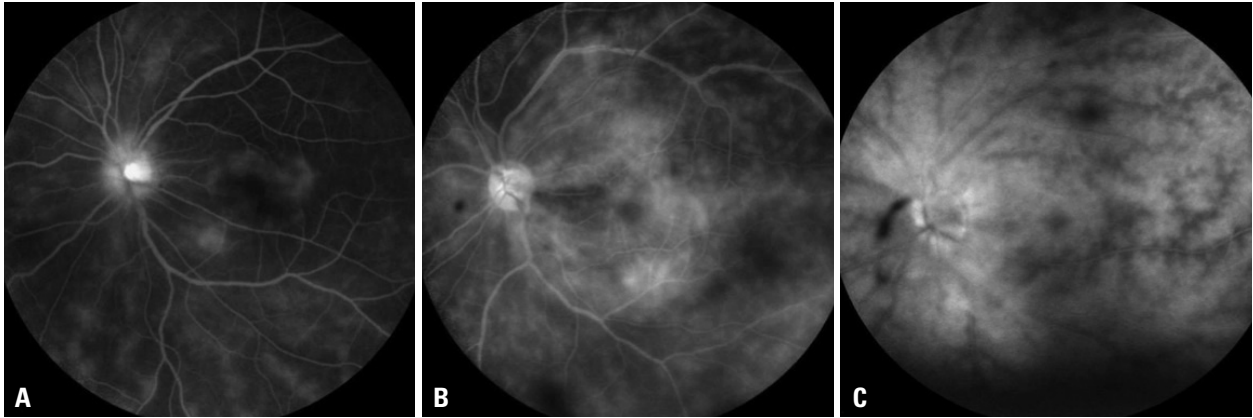


Fig. 4. Fluorescein angiograms demonstrating different degrees of retinal vascular leakage in Behçet retinal vasculitis. Mild, staining of vessels with minimal leakage (A); moderate, more intense leakage with a distinct vascular margin (B); severe, even greater leakage with blurring of the large vessel margins (C).

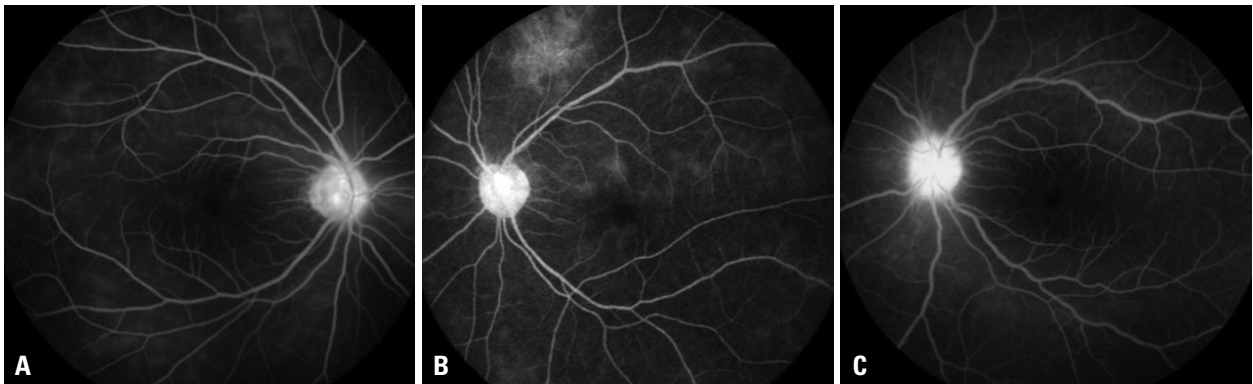

Fig. 5. Fluorescein angiograms of Behçet retinal vasculitis demonstrating varying degrees of optic disc hyperfluorescence. Partial (A); diffuse with clear disc margin (B); diffuse with blurring of the disc margin (C).

findings). Any disagreement on the FA findings was resolved by open adjudication.

Statistical analysis

The VA, demographics, and angiographic findings at initial presentation were analyzed with the Pearson chi-square test (Fisher's exact test was used when the expected cell counts were less than five) or independent Student's t-test (or Mann-Whitney U test). Mantel-Haenszel chi-square analysis was done to assess any trends in the level of retinal vascular leakage and optic disc hyperfluorescence in peripheral and posterior pole-involved vasculitis. The Cohen's kappa coefficient was calculated to evaluate intergrader and intragrader reliability by measuring chance-adjusted agreement for angiographic grading.

In vasculitis involving the posterior pole, multivariable linear regression analysis was performed with initial VA as the dependent variable and the angiographic features as independent variables after adjusting for potential confounders. A compound symmetry covariance structure was used to account for potential correlations between the two eyes of

an individual. Kendall's tau beta coefficient was calculated for the correlation analysis of the relationship between the changes of VA and leakage during follow up at 2 year time point within a 3 months window.

p-values less than 0.05 were considered statistically significant SAS software version 9.2 (SAS Institute Inc., Cary, NC, USA) was used for the statistical analyses.

RESULTS

Retinal vasculitis was classified into two types based on the anatomic location involved. As shown in Table 1, retinal vasculitis involved the posterior pole in 63 eyes (73.3%), all of which also showed vascular leakage in the periphery. Isolated peripheral involvement (i.e., no vascular leakage in the posterior pole) was found in 23 eyes (26.7%). The mean logarithm of the minimum angle of resolution (logMAR) VA for eyes with vasculitis involving the posterior pole was significantly worse than that of those with peripheral vasculitis ($p < 0.0001$). These two groups did not differ in the pres-

Table 1. Fluorescein Angiography Findings in Behçet Retinal Vasculitis

	Total	Peripheral vasculitis*	Vasculitis involving posterior pole [†]			<i>p</i> value [‡]	<i>p</i> value [§]
			Total	Macular [‡]	Extramacular [§]		
Number of eyes (%)	86	23 (26.7)	63 (73.3)	51 (59.3)	12 (19.0)	NA	NA
Age (yrs)	35.63±10.18	32.0±10.20	36.78±9.98	35.42±12.49	37.10±9.41	0.60 ^{††}	0.067 ^{††}
HLA B-51 (%)	35 (40.7)	11 (47.8)	24 (38.1)	22 (34.9)	2 (3.17)	0.11 ^{**}	0.20 ^{**}
Initial VA (logMAR)	0.427±0.537	0.078±0.148	0.554±0.572	0.560±0.566	0.529±0.619	0.87 ^{††}	<0.0001 ^{††}
Follow-up VA ^{§§} (logMAR)	0.439±0.529	0.087±0.181	0.568±0.557	0.618±0.576	0.354±0.426	0.14 ^{††}	<0.0001 ^{††}
Follow-up duration (months)	33.3±17.9	30.1±18.9	34.4±17.7	35.4±18.9	25.1±17.7	0.091 ^{††}	0.33 ^{††}
Extent of leakage (%)							<0.0001 ^{**}
Focal	17 (19.8)	17 (73.9)	0 (0.0)	0 (0.0)	0 (0.0)	0.99 ^{**}	
Diffuse	69 (80.2)	6 (26.1)	63 (91.3)	51 (80.9)	12 (19.1)		
Degree of retinal vascular leakage (%)						0.012 ^{††}	<0.0001 ^{††}
Mild	46 (53.5)	22 (95.6)	23 (36.5)	14 (27.5)	9 (75.0)		
Moderate	28 (32.6)	1 (4.4)	28 (44.4)	26 (51.0)	2 (16.7)		
Severe	12 (14.0)	0 (0.0)	12 (19.0)	11 (21.6)	1 (8.3)		
Optic disc hyperfluorescence (%)							
None	15 (17.4)	7 (30.4)	8 (12.7)	6 (11.8)	2 (16.7)	0.50 ^{††}	0.11 ^{††}
Partial	34 (39.5)	8 (34.8)	26 (41.3)	23 (45.1)	3 (25.0)		
Diffuse with clear disc margin	29 (33.7)	8 (34.8)	21 (33.3)	15 (29.4)	6 (50.0)		
Diffuse with blurring of disc margin	8 (9.3)	0 (0.0)	8 (12.7)	7 (13.7)	1 (8.3)		
Ischemic change (%)							
Peripheral Capillary nonperfusion	15 (17.4)	3 (13.0)	12 (19.0)	8 (15.7)	4 (33.3)	0.22 ^{††}	0.75 ^{††}
Vascular anastomosis	22 (25.6)	0 (0.0)	22 (34.9)	17 (33.3)	5 (41.7)	0.74 ^{**}	0.002 ^{**}
NVE	2 (2.3)	0 (0.0)	2 (3.2)	0 (0.0)	2 (16.7)	0.034 ^{**}	0.99 ^{**}
NVD	1 (1.2)	0 (0.0)	1 (1.6)	1 (2.0)	0 (0.0)	0.99 ^{**}	0.99 ^{**}
BRVO	1 (1.2)	0 (0.0)	1 (1.6)	1 (2.0)	0 (0.0)	0.99 ^{**}	0.99 ^{**}
Macular ischemia	7 (8.1)	0 (0.0)	7 (11.1)	6 (11.7)	1 (8.3)	0.99 ^{**}	0.18 ^{**}

logMAR, logarithm of the minimum angle of resolution; VA, visual acuity; NVE, neovascularization elsewhere; NVD, neovascularization at disc; BRVO, branch retinal vein occlusion.

*Peripheral vasculitis refers to eyes with vascular leakage confined to the periphery (i.e., no involvement of the posterior pole).

[†]Vasculitis involving the posterior pole refers to eyes with vascular leakage that involves the posterior pole. All of these eyes also had vascular leakage in the periphery.

[‡]Macular subtype had involvement of the posterior pole region that included the central 1.5 mm area of the macula.

[§]Extramacular subtype showed involvement of the posterior pole but no evidence of macular leakage.

^{||}Comparison between the macular and extramacular subtypes.

^{††}Comparison between peripheral vasculitis and posterior pole-involved vasculitis.

**Pearson chi-square test (Fisher's exact test).

^{†††}Independent Student's t-test or Mann-Whitney U test.

^{††††}Mantel-Haenszel chi-square test for trend analysis.

^{§§}Follow-up VA at 2 year time point within a 3 month window; *p*-value<0.05 is considered statistically significant (indicated in italic).

ence of cataracts, the magnitude of anterior uveitis, and posterior vitreous inflammation (all *p*>0.05, data not shown). Regarding the extent of vascular leakage, a diffuse-type of retinal vascular leakage was found in 69 eyes (80.2%), whereas 17 eyes were classified as focal-type (19.8%). Retinal vascular leakage was accompanied by optic disc involvement in 71 eyes (82.6%, partial: 39.5%, diffuse: 33.7%,

diffuse with blurring of disc margin: 9.3%). Subgroup analysis (based on anatomic location) revealed a significant trend towards a more severe and diffuse-type of vascular leakage in retinal vasculitis involving the posterior pole compared to peripheral vasculitis (Mantel-Haenszel chi-square test, all *p*<0.0001). In contrast, most of the eyes with peripheral vasculitis had only a mild degree of retinal vascular leakage

(95.6%), with one eye displaying moderate retinal vascular leakage (4.4%). However, there was not a significant difference in optic disc hyperfluorescence between the two groups ($p=0.108$).

Eyes with posterior pole vasculitis were further subdivided into those that involved the macular region and those without any evidence of macular leakage (extramacular subtype). Comparison of these two subtypes showed a significant trend towards more severe retinal vascular leakage in those with macular involvement ($p=0.012$), but a significant difference was not found in optic disc hyperfluorescence ($p=0.50$). There was not a significant difference between macular and extramacular types in either initial or follow-up VA at the two year time point, but the initial and follow-up VA of eyes with peripheral vasculitis were significantly better than those of eyes with the extramacular subtype of posterior pole vasculitis ($p=0.001$ and $p=0.005$, respectively) (Table 1).

Univariable linear regression analysis identified retinal vascular leakage, optic disc hyperfluorescence, and macular leakage as factors significantly associated with worse VA in the eyes with retinal vasculitis involving the posterior pole (all $p<0.05$) (Table 2). Multivariable regression analysis with stepwise variable selection showed that these variables remained significantly associated with worse logMAR VA after adjusting for potential confounding variables (adjusted $R^2=0.41$) (Table 3). However, in peripheral vasculitis, no significant association between angiographic findings and logMAR VA could be identified (all $p>0.05$, data not shown).

During the follow-up period (33.3 ± 17.9 months), the 12 eyes that had vasculitis involving the posterior pole without any evidence of angiographic macular leakage (the extramacular subtype) all remained free of any macular involvement at the final follow up, and did not show a significant change in VA (Wilcoxon signed rank test, $p>0.05$). Only one eye (4.3%) with peripheral vasculitis eventually progressed to having vasculitis involving the posterior pole. This eye developed grade 2 macular leakage over 5 years, and the VA decreased from 20/30 to 20/50.

Inter-grader reliability for grading of angiographic findings of Behçet retinal vasculitis was very favorable (k: kappa value; extent of leakage, $k=0.95$; degree of retinal vascular leakage, $k=0.96$; optic disc hyperfluorescence, $k=0.95$; Macular leakage, $k=0.91$; change in leakage, $k=0.93$). Intra-grader reliability regarding these findings also was favorable (extent of leakage, $k=1.00$; degree of retinal vascular leakage, $k=0.98$; optic disc hyperfluorescence, $k=0.98$; macular

leakage, $k=0.95$; change in leakage, $k=0.97$).

As shown in Table 4, in posterior pole-involved vasculitis, no significant correlation was found between the changes in vascular leakage and the change in VA evaluated at 2 year time point (correlation coefficient $\tau=0.199$, $p=0.092$). Furthermore, we could not establish any significant correlation between the overall change in vascular leakage and the change in VA in eyes with peripheral vasculitis at 2 year time point ($p=0.75$).

With regard to treatments, a significantly higher percentage of the eyes with posterior pole vasculitis received systemic immunosuppressants (azathioprine, cyclosporin A,

Table 2. Factors Associated with Visual Acuity in Posterior Pole-Involved Retinal Vasculitis by Univariable Analysis in Behçet Retinal Vasculitis

Variables	β coefficient	95% confidence intervals	p value [§]
Age at initial presentation	0.013	-0.001 to 0.027	0.061
Retinal vascular leakage*	0.397	0.228 to 0.566	<i><0.0001</i>
Optic disc hyperfluorescence*	0.215	0.057 to 0.373	<i>0.008</i>
Macular leakage*	0.132	0.012 to 0.243	<i>0.013</i>
Anterior chamber cell [†]	0.088	-0.061 to 0.292	0.20
Vitreous cell [‡]	0.068	-0.119 to 0.256	0.47

A univariable linear regression analysis was performed.

*The magnitude of angiographic parameters was taken into account in the analysis.

[†]Anterior chamber cell: 0, 1+, 2+, 3+, or more.

[‡]Vitreous cell: 0, 1+, 2+, 3+, or more.

[§]Statistically significant p -value (<0.05) is indicated in italic.

Table 3. Factors Associated with Visual Acuity in Posterior Pole-Involved Retinal Vasculitis by Multivariable Analysis in Behçet Retinal Vasculitis

Variables	β coefficient	95% confidence intervals	p value [§]
Age at initial presentation	0.012	0.001 to 0.024	<i>0.041</i>
Retinal vascular leakage*	0.345	0.162 to 0.528	<i><0.0001</i>
Optic disc hyperfluorescence*	0.147	0.013 to 0.280	<i>0.032</i>
Macular leakage*	0.107	0.004 to 0.217	<i>0.047</i>
Anterior chamber cell [†]	0.067	-0.034 to 0.168	0.19
Vitreous cell [‡]	-0.007	-0.128 to 0.114	0.80

Adjusted $R^2=0.408$. A multivariable regression analysis with stepwise variable selection was used.

*The magnitude of angiographic parameters was taken into account in the analysis.

[†]Anterior chamber cell: 0, 1+, 2+, 3+, or more.

[‡]Vitreous cell: 0, 1+, 2+, 3+, or more.

[§]Statistically significant p -value (<0.05) is indicated in italic.

methotrexate) and intravitreal bevacizumab injections compared to those with peripheral vasculitis, but there was no significant difference in systemic corticosteroids administered between the two groups (Table 5).

DISCUSSION

Our study demonstrated that in Behçet retinal vasculitis,

posterior pole involvement, the degree of retinal vascular leakage, optic disc hyperfluorescence, and macular leakage were significantly associated with worse VA. This suggests that the proposed angiographic classification of Behçet retinal vasculitis may be clinically valuable in terms of patients' visual prognosis.

Takeuchi, et al.⁵ suggested that a lesion located within the retinal vascular arcade in ocular Behçet disease is more likely to be associated with an irreversible visual disturbance

Table 4. Changes in Vascular Leakage and Visual Acuity during Follow Up in Behçet Retinal Vasculitis

Change in leakage*	Change in VA [†]								Overall
	Peripheral retinal vasculitis				Posterior pole-involved retinal vasculitis				
	Total	VA loss	No change in VA	VA gain	Total	VA loss	No change in VA	VA gain	
Worsened (%)	2 (8.7)	1 (4.3)	1 (4.3)	0 (0)	10 (15.9)	3 (4.8)	7 (11.1)	0 (0)	12 (13.9)
No change (%)	17 (73.9)	1 (4.3)	12 (52.2)	4 (17.4)	32 (50.8)	5 (7.9)	23 (36.5)	4 (6.3)	49 (56.9)
Improved (%)	4 (17.4)	1 (4.3)	3 (13.0)	0 (0)	21 (33.3)	3 (4.8)	13 (20.6)	5 (7.9)	25 (29.1)
Total (%)	23 (100)	3 (13.0)	16 (69.6)	4 (17.4)	63 (100)	11 (17.5)	43 (68.3)	9 (14.3)	86 (100)
Coefficient of correlation (Kendall's tau, τ)	$\tau=-0.034$ ($p=0.75$)				$\tau=0.199$ ($p=0.092$)				

VA, visual acuity.

Follow up=time interval between the baseline and the closest-to-two year follow-up visit. p -value<0.05 is considered statistically significant.

*Retinal vascular leakage, optic disc hyperfluorescence, and macular leakage were compared collectively between the initial and at 2 year time point within a 3 months window. Worsened=there was an increase in the magnitude of the overall vascular leakage, No change=there was no discernible difference in the degree of leakage, Improved=there was a decrease in the magnitude of the overall vascular leakage.

[†]For a change in VA to be considered a gain, there had to be an improvement of at least three Snellen chart lines between the initial VA and VA at 2 year time point within a 3 months window. A drop of at least three Snellen chart lines was considered a loss of VA. A change in VA of fewer than three lines was regarded as no change.

Table 5. Systemic Treatment Summary in Patients with Behçet Retinal Vasculitis

Treatment	Total	Peripheral vasculitis (n=23)	Posterior pole-involved vasculitis (n=63)	p value*
Topical steroids (%)	60 (69.8)	18 (78.3)	42 (66.7)	0.43
Systemic corticosteroids (%)	77 (87.5)	19 (82.6)	56 (88.9)	0.48
Immunosuppressive agents (%)				
Azathioprine	54 (61.4)	8 (34.8)	44 (84.6)	0.006
Cyclosporin A	41 (46.6)	3 (13.0)	37 (58.7)	<0.0001
Colchicine	37 (42.0)	14 (60.9)	22 (34.9)	0.047
Methotrexate	24 (27.3)	1 (4.3)	22 (34.9)	0.005
Posterior subtenon triamcinolone injections (%)	26 (29.5)	3 (13.0)	20 (31.7)	0.10
Intravitreal injections (%)				
Triamcinolone	14 (15.9)	2 (8.7)	11 (17.5)	0.50
Bevacizumab	12 (13.6)	0	11 (17.5)	0.032
Methotrexate	6 (6.8)	1 (4.3)	5 (7.9)	0.99
Immunomodulating agents (%)				
Infliximab	2 (2.3)	0	2 (3.2)	0.99
Interferon	8 (9.1)	0	7 (11.1)	0.18
Cyclophosphamide (%)	5 (5.7)	0	5 (7.9)	0.32
Intravenous steroid pulses (%)	2 (2.3)	0	2 (3.2)	0.99

*Chi-square test (or Fisher's exact test).

caused by inflammatory cell-mediated damage to photoreceptors and ganglion cells in the macula. Optic disc hyperfluorescence has been previously suggested to be a marker of disease activity in posterior uveitis,¹⁷ and Gedik, et al.¹⁸ demonstrated optic disc staining and leakage in 89.8% of eyes, a finding similar to our finding of 82.6% of eyes. Previously, Nussenblatt, et al.¹⁹ reported no significant relationship between VA and the amount of fluorescein staining measured in the posterior pole. However, in our study, multivariable regression analysis indicated that the magnitude of macular leakage, retinal vascular leakage, and optic disc hyperfluorescence were significantly associated with VA. A higher prevalence of vascular anastomosis at the time of the initial FA suggests that an eye with posterior pole-involved retinal vasculitis was more likely to have sustained cumulative ischemic damage due to vasoocclusive inflammation before the patient was first diagnosed with retinal vasculitis. These findings collectively suggest that at initial presentation, patients with angiographic evidence of retinal vasculitis with posterior pole involvement and greater degree of leakage may require prompt and aggressive treatment, because prolonged retinal vascular inflammation could result in a significant alteration of retinal function by promoting retinal edema, scarring, and optic nerve dysfunction.²⁰

During follow up, vascular leakage persisted or worsened despite treatment with immunosuppressive agents in 61 eyes (70.9%), whereas 25 eyes (29.1%) showed an improvement in overall vascular leakage. In a subgroup analysis, no significant correlation was observed between vascular leakage change and VA change ($\tau=0.199$, $p=0.092$) in eyes with posterior pole-involved retinal vasculitis. Retinal vascular inflammation causes the zonulae occludentes to open up and the retinal vessels to become leaky, resulting in fluorescein leakage through the open intercellular spaces of the endothelium and the staining of the vascular wall and the area surrounding the inflamed vessel.²¹ This implies that differentiation between progression to active vascular leakage and persistent vascular leakage resulting from chronic damage incurred on the endothelial blood retinal barrier might be difficult in chronic vasculitis such as Behçet retinal vasculitis. Further, mild leakage could persist after the cessation of active inflammation as a damaged blood vessel could remain leaky for a long time after the active inflammation had resolved.²⁰ This may explain the lack of significant correlation between leakage change and VA change in our study. To differentiate chronic, inactive inflammation from acute exacerbation of active inflammation, additional means to

evaluate the activity of inflammation might be necessary.

In this study, there were no cases that progressed from ex-tramacular vasculitis to vasculitis that involved the macula, whereas there was one eye in which the vasculitis progressed from involving only the periphery to involving the posterior pole 5 years after the time of the initial FA. Considering the relatively short mean follow up of 33.3 ± 17.9 months, it is unclear whether we might have observed more cases in which retinal vasculitis limited to the periphery could progress to involve the posterior pole, and whether the treatment or natural history is what prevented initially peripheral only cases from becoming posterior pole involved vasculitis since most of peripheral retinal vasculitis have also received various treatments.

There were 12 eyes with retinal vasculitis involving the posterior pole that did not have any angiographic evidence of macular leakage. Despite the absence of leakage in the macular area, the VA of these eyes was not significantly different from that of those with macular leakage, implying that vascular inflammation within the posterior pole area could have a significant impact on VA even in conditions in which there was no apparent involvement of the macular area in FA. Several possible mechanisms have been suggested for the VA decrease that occurs in retinal vasculitis, including antiretinal antibodies released from a damaged blood retinal barrier causing the apoptotic death of photoreceptors,^{22,23} macular ischemia secondary to occlusive vasculitis, persistent leakage of inflammatory mediators such as nitric oxide²⁴ and free radicals²⁵ from damaged blood vessels leading to the oxidative stress and apoptotic death of photoreceptors,^{26,27} interference of signal transduction within the inner nuclear layer, and macular thickening due to inflammation.

There are several limitations in the present study. We adopted and slightly modified previously used criteria.¹⁴⁻¹⁶ However, there is an inherent subjectivity in grading angiographic leakage. With regard to the evaluation of visual function, due to the retrospective nature of the study, we were able to evaluate only VA. Also, the use of the best or final VA outcomes does not accurately reflect the true extent and severity of this disease as the disease tends to wax and wane with frequent recurrences,²⁸ and that is why the visit closest to the 2 year time point within a 3 months window was counted as the visit to be used for correlation between the change in vascular leakage and the change in VA. Further prospective studies involving more patients with diverse ethnic backgrounds are warranted in the future.

In conclusion, this study demonstrated that posterior pole involvement, the degree of retinal vascular leakage, optic disc hyperfluorescence, and macular leakage are significantly associated with worse VA in Behçet retinal vasculitis. This suggests that the proposed angiographic classification and grading of Behçet retinal vasculitis may be clinically significant in terms of patients' visual prognosis and physician's treatment strategy.

ACKNOWLEDGEMENTS

The authors would like to thank Kim Myo Jung at the Department of Biostatistics at Yonsei University for assistance in the statistical analysis of the data.

REFERENCES

1. Deuter CM, Kötter I, Wallace GR, Murray PI, Stübiger N, Zierhut M. Behçet's disease: ocular effects and treatment. *Prog Retin Eye Res* 2008;27:111-36.
2. Kaçmaz RO, Kempen JH, Newcomb C, Gangaputra S, Daniel E, Levy-Clarke GA, et al. Ocular inflammation in Behçet disease: incidence of ocular complications and of loss of visual acuity. *Am J Ophthalmol* 2008;146:828-36.
3. Sakamoto M, Akazawa K, Nishioka Y, Sanui H, Inomata H, Nose Y. Prognostic factors of vision in patients with Behçet disease. *Ophthalmology* 1995;102:317-21.
4. Cho YJ, Kim WK, Lee JH, Byeon SH, Koh HJ, Kwon OW, et al. Visual prognosis and risk factors for Korean patients with Behçet uveitis. *Ophthalmologica* 2008;222:344-50.
5. Takeuchi M, Hokama H, Tsukahara R, Kezuka T, Goto H, Sakai J, et al. Risk and prognostic factors of poor visual outcome in Behçet's disease with ocular involvement. *Graefes Arch Clin Exp Ophthalmol* 2005;243:1147-52.
6. Zouboulis CC. Adamantides-Behçet's disease. New York: Kluwer Academic/Plenum Publishers; 2003.
7. De Laey JJ. Fluorescein angiography in posterior uveitis. *Int Ophthalmol Clin* 1995;35:33-58.
8. Demiroğlu H, Barişta I, Dündar S. Risk factor assessment and prognosis of eye involvement in Behçet's disease in Turkey. *Ophthalmology* 1997;104:701-5.
9. Atmaca LS, Sonmez PA. Fluorescein and indocyanine green angiography findings in Behçet's disease. *Br J Ophthalmol* 2003;87:1466-8.
10. Bozzoni-Pantaleoni F, Gharbiya M, Pirraglia MP, Accorinti M, Pivetti-Pezzi P. Indocyanine green angiographic findings in Behçet disease. *Retina* 2001;21:230-6.
11. Yu HG, Kim MJ, Oh FS. Fluorescein angiography and visual acuity in active uveitis with Behçet disease. *Ocul Immunol Inflamm* 2009;17:41-6.
12. Criteria for diagnosis of Behçet's disease. International Study Group for Behçet's Disease. *Lancet* 1990;335:1078-80.
13. Jabs DA, Nussenblatt RB, Rosenbaum JT; Standardization of Uveitis Nomenclature (SUN) Working Group. Standardization of uveitis nomenclature for reporting clinical data. Results of the First International Workshop. *Am J Ophthalmol* 2005;140:509-16.
14. Suhler EB, Smith JR, Wertheim MS, Lauer AK, Kurz DE, Pickard TD, et al. A prospective trial of infliximab therapy for refractory uveitis: preliminary safety and efficacy outcomes. *Arch Ophthalmol* 2005;123:903-12.
15. Tugal-Tutkun I, Herbort CP, Khairallah M; Angiography Scoring for Uveitis Working Group (ASUWOG). Scoring of dual fluorescein and ICG inflammatory angiographic signs for the grading of posterior segment inflammation (dual fluorescein and ICG angiographic scoring system for uveitis). *Int Ophthalmol* 2010;30:539-52.
16. Yannuzzi LA. A perspective on the treatment of aphakic cystoid macular edema. *Surv Ophthalmol* 1984;28 Suppl:540-53.
17. Ciardella AP, Prall FR, Borodoker N, Cunningham ET Jr. Imaging techniques for posterior uveitis. *Curr Opin Ophthalmol* 2004;15:519-30.
18. Gedik S, Akova Y, Yilmaz G, Bozbeyoğlu S. Indocyanine green and fundus fluorescein angiographic findings in patients with active ocular Behçet's disease. *Ocul Immunol Inflamm* 2005;13:51-8.
19. Nussenblatt RB, Kaufman SC, Palestine AG, Davis MD, Ferris FL 3rd. Macular thickening and visual acuity. Measurement in patients with cystoid macular edema. *Ophthalmology* 1987;94:1134-9.
20. Nussenblatt RB, Whitcup SM. Uveitis: fundamentals and clinical practice. 4th ed. Philadelphia: Mosby; 2010.
21. Spitznas M. Understanding fluorescein angiography. Berlin: Springer; 2006.
22. Adamus G. Autoantibody-induced apoptosis as a possible mechanism of autoimmune retinopathy. *Autoimmun Rev* 2003;2:63-8.
23. Chan CC, Palestine AG, Nussenblatt RB, Roberge FG, Benezra D. Anti-retinal auto-antibodies in Vogt-Koyanagi-Harada syndrome, Behçet's disease, and sympathetic ophthalmia. *Ophthalmology* 1985;92:1025-8.
24. Yilmaz G, Sizmaz S, Yilmaz ED, Duman S, Aydin P. Aqueous humor nitric oxide levels in patients with Behçet disease. *Retina* 2002;22:330-5.
25. Rao NA, Wu GS. Free radical mediated photoreceptor damage in uveitis. *Prog Retin Eye Res* 2000;19:41-68.
26. Liversidge J, Dick A, Gordon S. Nitric oxide mediates apoptosis through formation of peroxynitrite and Fas/Fas-ligand interactions in experimental autoimmune uveitis. *Am J Pathol* 2002;160:905-16.
27. Rajendram R, Saraswathy S, Rao NA. Photoreceptor mitochondrial oxidative stress in early experimental autoimmune uveoretinitis. *Br J Ophthalmol* 2007;91:531-7.
28. DiLoreto DA Jr, Bressler NM, Bressler SB, Schachat AP. Use of best and final visual acuity outcomes in ophthalmological research. *Arch Ophthalmol* 2003;121:1586-90.