

Abdominal Tuberculosis: A Diagnostic Dilemma

SEEMA AWASTHI¹, MANOJ SAXENA², FAIYAZ AHMAD³, ASHUTOSH KUMAR⁴, SHYAMOLI DUTTA⁵

ABSTRACT

Background: Abdominal tuberculosis (TB) is the sixth most common form of extra-pulmonary site of infection after lymphatic, genitourinary, bone and joint, miliary and meningeal TB with a rising incidence in recent years. TB can affect any part of the gastro-intestinal (GI) tract including anus, peritoneum and hepato-biliary system. The clinical manifestations of abdominal tuberculosis are non-specific and mimic various GI disorders and cause delay in diagnosis and management.

Aim: To evaluate the various clinical, radiological and microbiological findings of abdominal tuberculosis and to define the role of histopathological examination in establishing the diagnosis in resource poor settings and to analyze the compliance and response to anti-tubercular treatment.

Materials and Methods: A five year retrospective study (January 2010 to December 2014) was done in a tertiary teaching hospital in Northern India and all the cases diagnosed as abdominal tuberculosis during the study period, were included. The relevant clinical informations, laboratory results, microbiological and radiological investigations were recorded. Histopathological examination of all the resected

/ excised specimens was done and Ziehl-Neelsen (ZN) staining to detect the tubercular bacilli and Periodic acid-Schiff (PAS) stain to rule out fungal infection was done in all the cases.

Results: Out of 48 cases with abdominal tuberculosis, the average age of presentation was 27.4 years with a slight male predominance (Male:Female=1.4:1). Abdominal pain (100%) was the most common presenting symptom followed by anorexia (98%), fever (88%) and intestinal obstruction (88%). The ileum was the most common site of involvement. All the 45 resected / excised tissue specimens (34 cases of intestinal resection and 11 cases of intestinal, omental and lymph nodes biopsies) showed epithelioid granulomas along with necrosis (in 38 cases) and Langhans giant cells (in 42 cases). Acid Fast Bacilli (AFB) positivity was seen in 5 tissue specimens only. All patients were put on anti-tubercular treatment and majority showed good response to therapy.

Conclusion: Abdominal tuberculosis should be considered as a differential diagnosis in patients with vague GI symptoms. Study of histopathological findings can aid in the diagnosis in the settings where advanced molecular methods of diagnosis are not available, leading to early diagnosis and management.

Keywords: Gastrointestinal, Histopathology, Intestinal obstruction, Langhans

INTRODUCTION

Tuberculosis is a chronic granulomatous disease caused by an aerobic bacteria *Mycobacterium tuberculosis*. It remains the world-wide problem despite the discovery of the causative organism for more than a century ago. Pulmonary tuberculosis is the most common form and it primarily involves the lung but any part of the body can be involved by the disease [1, 2]. Abdominal tuberculosis (TB) although less common in western countries, constitutes a major public health problem in developing countries and associated with significant morbidity and mortality [3,4]. It is the 6th most frequent site for the extra pulmonary involvement and it can involve any part of the gastrointestinal tract, peritoneum and hepatobiliary system.

The *mycobacterium* reaches the gastrointestinal tract via hematogenous spread, ingestion of infected sputum or direct spread from infected contiguous lymph nodes and fallopian tubes [5-9].

The clinical manifestations of abdominal tuberculosis are protean and can mimic many other disease process, causing delay in diagnosis [10].

The most common site of predilection is the ileocaecal region, attributed to the minimal digestive activity, relatively increased physiological stasis, higher rate of fluid and electrolyte absorption and more lymphoid tissue at this site [5,8,11].

Peritoneal involvement may occur due to spread of the bacilli from mesenteric lymph node, contiguous spread from intestinal lesion or from tubercular salpingitis in women. However, one third of the cases show abdominal lymph node and peritoneal tuberculosis without any evidence of gastrointestinal involvement [12].

Grossly the abdominal tuberculosis presents in 3 morphological forms- ulcerative, hypertrophic and combination of both ulcero-hypertrophic [6,11,13,14]. Most common complication of intestinal tuberculosis is intestinal obstruction attributed to strictures or by adhesions and in India approximately 3-20% of all cases of bowel obstruction are due to the tuberculosis [8,15,16]. One of the serious complication of abdominal tuberculosis is perforation, causing high morbidity and mortality [6,8,17] and it accounts for 5-9% of small intestinal perforations in India. It is the 2nd most common cause of intestinal perforation in India after typhoid fever [2]. Perforations due to tuberculosis are usually single and occurs proximal to the stricture site [6].

Scant literature is available on the extra-pulmonary tuberculosis in reference to its incidence and bacteria positivity [18].

We emphasize here to suspect the abdominal tuberculosis clinically and also on the role and importance of the histopathological examination in resource poor settings where study of tissue biopsy can aid in diagnosis and ultimately in proper and early management of affected cases.

MATERIALS AND METHODS

A retrospective study was conducted in a tertiary teaching hospital in North India. All the cases diagnosed as abdominal tuberculosis, including gastrointestinal tract, peritoneum, mesenteric lymph nodes or other intra-abdominal solid organs were retrieved. The detailed patient information in form of demographic data, clinical details, laboratory results and treatment outcome were recorded. Ziehl-Neelsen (ZN) staining was done to identify the tubercular bacilli and Periodic acid-Schiff (PAS) stain was used to rule out the fungal etiology of granuloma formation.

The diagnosis of abdominal tuberculosis was made in all the cases fulfilling following criterias:

- 1) Acid fast stain positivity for *M. tuberculosis* in ascitic/biopsy specimens.
- 2) Identification of caseating granulomas on histological examination of excised/ resected specimens from abdomen.
- 3) Response to anti-tubercular treatment

HIV (Human Immunodeficiency Virus) screening was done in all the cases and cases with positive HIV status were excluded from the study.

Total 48 cases were diagnosed as abdominal tuberculosis between January 2010 and December 2014 and the follow-up record was analyzed along with response to anti-tubercular agents.

RESULTS

During the study period total 48 patients were diagnosed as a case of abdominal tuberculosis with a slight male predominance of 28 males and 20 females (Male:Female=1.4:1). The demographic characteristics of all these patients are summarized in [Table/Fig-1].

These patients presented a wide age group of distribution of 11 to 58 years with maximum number of cases (n=27, 56 %) presenting between 21-40 years. Only 9 cases (19%) had the past history of pulmonary tuberculosis while family history of tuberculosis was present in only 5 cases.

The clinical manifestations of the patients are summarized in [Table/Fig- 2] which shows abdominal pain as the most common presentation followed by anorexia, fever, intestinal obstruction, perforation peritonitis, ascitis and nausea/vomiting.

The laboratory findings revealed elevated ESR in 34 patients and anaemia in 22 patients as most common laboratory abnormalities. Mantoux skin test was performed in 31 cases and was found positive in 9 cases only.

S. no.	Age group (years)	No. of cases (Male + Female)	%
1.	0-20	9 (4 Male + 5 Female)	19
2.	21-40	27 (16 Male + 11Female)	56
3.	41-60	12 (8 Male + 4 Female)	25
Total		48 (28 Male + 20 Female)	100

[Table/Fig-1]: Distribution of cases according to age

Clinical presentation	Number of cases	%
Abdominal pain	48	100
Anorexia	47	98
Fever	42	88
Intestinal obstruction	42	88
Perforation	31	65
Ascitis	19	40
Nausea/ vomiting	12	25

[Table/Fig-2]: Clinical presentations of patients

In 19 cases ascitic fluid was available for further analysis with Acid Fast Stain (AFS) and *mycobacterium* culture. Ascitic fluid was exudates in nature in all the cases and showed AFB positivity in only 8 patients. On culture, tubercular colony growth was seen in only 2 cases with Lowenstein Jensen media.

All patients received plain film chest radiographs (CXR) and 10 cases had abnormal radiological findings including cavitary lesions, pleural effusion and lymphadenopathies.

Pathological examination was performed on 45 patients and Intestinal resection was the most common surgical procedure performed in the cases of abdominal tuberculosis followed by lymph node and intestinal biopsy (intestinal resection in 34 cases and 11 cases of intestinal, omental and lymph nodes biopsies). Tubercular enteritis was seen in 39 cases with most common involvement of the ileocaecal region. Perforations were present in 31 cases out of total 39 cases of intestinal enteritis (in 28 cases of 34 intestinal segment resection) and was most commonly present in ileum. Microscopically all 45 cases revealed characteristic pathological findings consistent with tuberculosis including granulomatous inflammation (n =45), Langhans giant cells (n =38), caseous necrosis (n= 22) and AFB positivity (n=5) [Table /Fig-3-5]. None of the case showed PAS stain positivity.

The anti tubercular treatment was started in all the 48 cases. All the cases responded well to therapy except one case that developed osteomyelitis of ankle during the course of treatment.

DISCUSSION

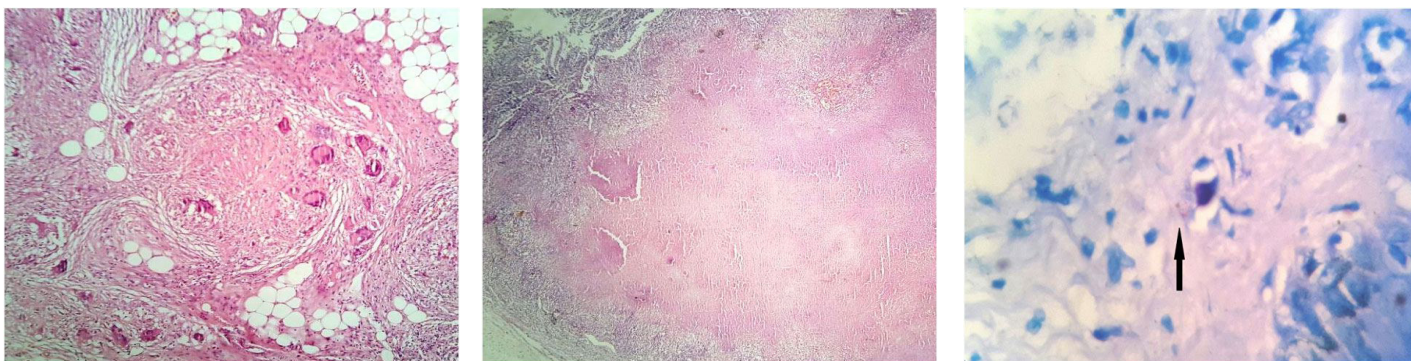
Though pulmonary tuberculosis is the most common form of tuberculosis, extra-pulmonary TB is also a significant cause of morbidity and mortality and affect lymph nodes, intestine, bone, joints, meninges, genitourinary tract, etc [1]. Abdominal tuberculosis is the sixth most common form of extra-pulmonary site of infection after lymphatic, genitourinary, bone and joints, miliary and meningeal TB [11]. The incidence of abdominal tuberculosis is rising all over the world however very scant literature and knowledge has been updated.

Abdominal TB can affect any age group. In a study conducted by Sharma MP et al., [19] most affected patients were between 21-45 years of age. Our study also showed maximum number of cases (n=27) in this age group (56%). This finding of involvement of slight younger population was also seen in many other studies [20,21]. Our study showed a slight male predominance than females with abdominal tuberculosis and a similar results were seen in a study conducted by Rajput MJ et al., [21]. Although Indian studies have suggested a slight female predominance [6].

The clinical manifestations of abdominal tuberculosis are quite protean. Similar to the previous reports abdominal pain (100%) was the most common clinical presentation in this study also, followed by anorexia (98%) [19]. In a study by Sharma MP et al., [19] fever was recorded in half of the patients while in present study higher no of cases 88% presented with fever.

Routine laboratory tests have limited value in the diagnosis of Abdominal TB [22]. In present study 10 cases were found to have abnormal findings on chest X-ray (CXR). Arif Au et al., [20] and Rajput MJ et al., [21] observed preexisting pulmonary tuberculosis in 20% and 33.95% of their patients respectively.

In this study we found ileocaecal region as the most frequent involved site in cases of abdominal tuberculosis and the most common manifestation was presence of strictures. These findings were in accordance with the previously published literature [20].



[Table/Fig-3]: Photomicrograph showing Epithelioid granulomas with numerous giant cells (x100, H&E) **[Table/Fig-4]:** Photomicrograph showing central caseous necrosis in a granuloma (x100, H&E) **[Table/Fig-5]:** High power photomicrograph showing numerous Acid fast bacilli (x1000, ZN stain)

Very low incidence of perforation (0-11% in adults, 3-4% in children, 2.5-6% at autopsy and 20% of all non-appendiceal perforations) has been reported in literature [8,17] because of reactive fibrosis of the peritoneum and formation of adhesions with adjacent tissues. In contrast however in the present study, perforation was more common than that reported previously (65% of all cases and 82% of resected intestinal segment specimens). In the present study we aimed to investigate the relative reliability of different tools for the diagnosis of abdominal tuberculosis which present with nonspecific and vague symptoms. We conclude that clinical and laboratory results are usually nonspecific and lead to diagnosis of a chronic disease only.

To differentiate the ileocaecal TB from Crohn's disease is indeed difficult and classically the diagnosis of abdominal tuberculosis requires microbiological and culture confirmation of *Mycobacterium tuberculosis*, many studies established the diagnosis on histopathological examination only [13,18]. Sharma et al., [19] found very low yield of organisms on smear and culture (acid fast bacilli is positive in less than 3 per cent of cases and positive culture in less than 20 per cent of cases). In our study also the diagnosis could be reached histopathologically in majority of the cases (93%). Polymerase chain reaction (PCR) although has emerged as a promising tools for diagnosing extra-pulmonary TB, is not cost-effective in resource poor setting .

CONCLUSION

Since the clinical presentations of abdominal tuberculosis are very non-specific and vague and the diagnostic criteria's are limited, hence diagnosis has to be supported by additional tests and by retrospective analysis with reference to clinical patterns, underlying diseases and X-ray findings. We also emphasize the importance of histopathological examination in establishing the diagnosis in poor resource settings.

REFERENCES

- [1] Park K, editor. Park's textbook of Preventive & Social Medicine. 19th ed. India: M/S Banarasidas Bhanot; 2007. pp.768.
- [2] Kapoor VK. Abdominal tuberculosis: The Indian contribution. *Indian J Gastroenterol.* 1998;17:141-47.
- [3] Global tuberculosis control 2012. [Internet]: World Health Organization. (Online) http://www.who.int/tb/publications/global_report/en/index.html Cited 2011 April 11.
- [4] Wadhwa N, Agarwal S, Mishra K. Reappraisal of abdominal tuberculosis. *J Indian Med Assoc.* 2004;102:31-32.
- [5] Marshall JB. Tuberculosis of the gastrointestinal tract and peritoneum. *Am J Gastroenterol.* 1993;88:989-99.
- [6] Kapoor VK. Abdominal tuberculosis. *Postgrad Med J.* 1998;74:459-67.
- [7] Das P, Shukla HS. Clinical diagnosis of abdominal tuberculosis. *Br J Surg.* 1976;63:941-46.
- [8] Bhansali SK. Abdominal tuberculosis: Experiences with 300 cases. *Am J Gastroenterol.* 1977;67:324-37.
- [9] Prakash A. Ulcero-constrictive tuberculosis of the bowel. *Int Surg.* 1978;63: 23-29.
- [10] Peda Veerajra E. Abdominal tuberculosis. In: Satya Sri S, editor. Textbook of Pulmonary and Extrapulmonary Tuberculosis. 3rd ed. New Delhi: Interprint; 1998. pp.250-52.
- [11] Paustian FF, Marshall JB. Intestinal tuberculosis. In: Berk JE, editor. Bockus Gastroenterology. 4th ed. Philadelphia: WB Saunders: 1985. p. 2018-36.
- [12] Hoon JR, Dockerty MB, Pemberton J. Ileocaecal tuberculosis including a comparison of this disease with non-specific regional enterocolitis and noncaseous tuberculated enterocolitis. *Int Abstr Surg.* 1950;91: 417-40.
- [13] Tandon HD, Prakash A. Pathology of intestinal tuberculosis and its distinction from Crohn's disease. *Gut.* 1972;13:260-69.
- [14] Prakash A, Tandon HD, Nirmala L, Wadhwa SN, Prakash O, Kapur M. Chronic ulcerative lesions of the bowel. *Indian J Surg.* 1970;32:1-14.
- [15] Bhansali SK, Sethna JR. Intestinal obstruction: a clinical analysis of 348 cases. *Indian J Surg.* 1970; 32:57-70.
- [16] Tandon RK, Sarin SK, Bose SL, Berry M, Tandon BN. A clinico-radiological reappraisal of intestinal tuberculosis – changing profile? *Gastroenterol Jpn.* 1986; 21:17-22.
- [17] Talwar S, Talwar R, Prasad P. Tuberculous perforations of the small intestine. *Int J Clin Pract.* 1999;53:514-18.
- [18] Yoon HJ, Song YG, Park IW, Choi JP, Chang KH, Kim JM. Clinical Manifestations and Diagnosis of Extrapulmonary Tuberculosis. *Yonsei Med J.* 2004;45:453–61.
- [19] Sharma MP, Bhatia V. Abdominal tuberculosis. *Indian J Med Res.* 2004;120:305-15.
- [20] Arif AU, Shah LA, Ullah A, Sadiq Mu D. The frequency and management of intestinal tuberculosis; a hospital based study. *J Postgrad Med Instit.* 2008;22(2):152-56.
- [21] Rajput MJ, Memon AS, Rani S, Memon AH. Clinicopathological profile and surgical management outcomes in patients suffering from intestinal tuberculosis. *JLUMHS.* 2005;4:113-18.
- [22] Underwood MJ, Thompson MM, Sayers RD, Hall AW. Presentation of abdominal tuberculosis to general surgeons. *Br J Surg.* 1992;79:1077-79.

PARTICULARS OF CONTRIBUTORS:

1. Associate Professor, Department of Pathology, Teerthanker Mahaveer Medical College & Research Centre, Moradabad, India.
2. Assistant Professor, Department of Pathology, Teerthanker Mahaveer Medical College & Research Centre, Moradabad, India.
3. Assistant Professor, Department of Pathology, Teerthanker Mahaveer Medical College & Research Centre, Moradabad, India.
4. Assistant Professor, Department of Pathology, Teerthanker Mahaveer Medical College & Research Centre, Moradabad, India.
5. Professor, Department of Pathology, Teerthanker Mahaveer Medical College & Research Centre, Moradabad, India.

NAME, ADDRESS, E-MAIL ID OF THE CORRESPONDING AUTHOR:

Dr. Seema Awasthi,
Associate Professor, Department of Pathology, Faculty Block-B, 201, TMU Campus, Moradabad, India.
E-mail : dr.seemaabhishek@yahoo.com

FINANCIAL OR OTHER COMPETING INTERESTS: None.

Date of Submission: Feb 05, 2015
Date of Peer Review: Feb 23, 2015
Date of Acceptance: Mar 30, 2015
Date of Publishing: May 01, 2015