

Functional magnetic resonance studies of the reorganization of the human hand sensorimotor area after unilateral brain injury in the perinatal period

(motor cortex/plasticity/blood oxygenation/nuclear magnetic resonance *in vivo*)

YUE CAO*[†], ERIC M. VIKINGSTAD*, PETER R. HUTTENLOCHER^{‡§}, VERNON L. TOWLE[§],
AND DAVID N. LEVIN*

Departments of *Radiology, [‡]Pediatrics, and [§]Neurology, The University of Chicago Hospitals, Chicago, IL 60637

Communicated by Paul C. Lauterbur, June 6, 1994 (received for review December 21, 1993)

ABSTRACT Functional magnetic resonance imaging was used to map the hand sensorimotor area of hemiparetic adolescents and young adults who had suffered unilateral brain damage in the perinatal period. Unlike normal subjects, who exhibit cortical activation primarily contralateral to voluntary finger movements, the hemiparetic patients' intact hemispheres were equally activated by contralateral and ipsilateral finger movements. Our findings are consistent with previous clinical observations and animal experiments which suggest that the immature brain is able to reorganize in response to focal injury.

Many observations suggest that the immature human brain is characterized by "plasticity": i.e., it is capable of major functional reorganization in response to external and internal stimuli. For example, children will recover language skills after sustaining a large insult or even hemispherectomy on the speech-dominant side if the damage occurs before age 7 or 8 (1). Similarly, if a child with strabismus is forced to use the squinting eye by patching of the good eye before about age 7, permanent visual loss in the squinting eye (amblyopia) can be prevented (2, 3). The sensorimotor system also demonstrates plasticity. Children with large unilateral brain lesions can learn to reach out and grasp an object and can walk, although with a limp (4). Movements of the paretic hand in these children are often accompanied by "mirror" movements on the opposite side (5, 6). Such parallel movements are much more prominent when brain injury occurs before 1 year of age (6). These observations suggest that motor function might be represented in the hemisphere ipsilateral to the weak hand if injury is incurred early in life.

Similar effects have been found in animal models: e.g., the reaction of the rodent motor system to postnatal hemispherectomy. In this model, it has been shown that the remaining hemisphere develops a new, uncrossed corticospinal tract to the ipsilateral spinal cord in addition to the usual crossed one (7). Huttenlocher *et al.* (8, 9) have succeeded in making separate cortical maps of the neurons forming the aberrant (uncrossed) and normal (crossed) tracts. The neurons which are "recruited" to form the uncrossed tract are found in the same areas as the usual "crossed" neurons, as well as in the adjacent cortex. Thus, these cortical mapping experiments suggest that a limited population of multipotential neurons might be involved in brain plasticity. The mechanisms of neural reorganization in the human brain are not well understood (10) but may involve the unmasking of existing pathways (11, 12), competition for synaptic space (13), or axonal migration and sprouting along chemical gradients (14).

Although ample clinical observations (1-7) and animal experiments (8, 9, 15) suggest that the human brain demonstrates plasticity, there are few studies that provide brain mapping evidence for cortical reorganization after motor-cortex lesions. A single case report utilizing magnetoencephalography suggested reorganization in the somatosensory cortex, with increased ipsilateral representation after neonatal middle cerebral artery distribution infarction (16). Weiller, Chollet, and coworkers (17, 18) have reported functional reorganization of the brain after striatocapsular infarction in adults that includes the activation of ipsilateral cortical regions. We are not aware of similar data concerning the reorganization of motor and somatic sensory representations after congenital lesions, where plasticity is likely to be greater than in the adult brain. In this article, we report brain mapping experiments on a group of hemiparetic patients who had suffered unilateral brain damage in the perinatal period (19).

In the last 2 years, functional magnetic resonance imaging (fMRI) techniques (20-24) have been developed to detect functional changes in the brain. The most widely used of these fMRI techniques is based on detecting local changes in blood deoxyhemoglobin concentration in active regions of the brain (25, 26). We used this fMRI technique to create functional maps of the hand sensorimotor areas of adolescents and young adults who have been hemiparetic since birth. The active brain regions were displayed and characterized by use of integrated three-dimensional models of the brain structure and function of each subject. We compared the fMRI-derived cortical maps of the *intact* hemispheres of hemiparetic patients with similar maps (27) of the dominant (left) hemispheres of right-handed controls. We also produced fMRI-derived cortical maps of the motor areas of the *damaged* hemispheres of hemiparetic subjects. We found that the sensorimotor area in the intact hemispheres of the hemiparetic patients was substantially activated by ipsilateral (paretic) finger movement, suggesting reorganization of sensorimotor cortex in the human brain after neonatal brain injury.

METHODS

Subjects. We studied six patients with unilateral brain damage in the perinatal period (mean age, 15 years; range, 7-22 years; four males and two females). Five of these patients had damage to the left sensorimotor cortex, while one had injury to his right sensorimotor cortex (Table 1). Three patients had porencephaly; they most likely experienced destructive lesions secondary to intrauterine or perinatal stroke. The other three had diffuse cortical atrophy with

The publication costs of this article were defrayed in part by page charge payment. This article must therefore be hereby marked "advertisement" in accordance with 18 U.S.C. §1734 solely to indicate this fact.

Abbreviation: fMRI, functional magnetic resonance imaging.
[†]To whom reprint requests should be addressed.

Table 1. Summary of anatomical features, impairment, and fMRI results of the six patients

Patient	Age, years	Injured hemisphere	Lesion size,* mm			Time for 20 thumb-to-four-digit oppositions, sec		Activated volume [‡]		
			S-I	L-R	A-P	P (MM) [†]	N (MM) [†]	I	C	I/C [§]
1	22	Left	(Diffuse atrophy)			92 (yes)	40 (yes)	0.07	0.07	0.95
2	15	Right	41	43	50	† (no)	18 (no)	0.44	0.18	2.49
3	16	Left	51	42	45	120 (yes)	41 (yes)	0.15	0.64	0.23
4	17	Left	(Diffuse atrophy)			— (no)	— (yes)	0.12	0.11	1.03
5	15	Left	59	33	76	46 (no)	37 (yes)	0.74	1.25	0.59
6	7	Left	(Diffuse atrophy)			† (yes)	41 (yes)	1.33	3.74	0.36
(Mean ± SEM)	15							0.47 ± 0.20	1.00 ± 0.58	0.94 ± 0.34

*Longest dimensions of the lesion in superior-inferior (S-I), left-right (L-R), and anterior-posterior (A-P) directions are given.

[†]P and N indicate paretic and normal hands, respectively; MM, mirror movement.

[‡]Absolute volume in the Rolandic region of the intact hemisphere activated by ipsilateral (paretic) (I) and contralateral (normal) (C) hand movements expressed in an arbitrary unit.

[§]Volume ratio (I/C) of fMRI signals in the Rolandic zone of the intact hemisphere of hemiparetic patients during ipsilateral (I) and contralateral (C) hand movements.

^{††}Patients 2 and 6 were unable to move the last two digits of their paretic hands. During the fMRI scan, they were instructed to sequentially touch their thumb to the second and third digits only.

a general decrease in size, sparse subcortical white matter, and enlargement of the lateral ventricle in the left hemisphere (patients 1, 4, and 6). Patients 4 and 6 had genetically based maldevelopment of the left hemisphere, the two being first cousins. Only patient 1 had epilepsy, controlled by anticonvulsant medication. All patients had significant impairment of voluntary movements on the paretic side but were able to carry out individual finger movements. The impairment in finger movement was most severe for patients 2 and 6, who could only oppose the thumb and the second and third digits; was intermediate for patients 1, 3, and 4; and was mild for patient 5, who had good voluntary finger control in all five digits. The degree of impairment was measured by the time required to carry out 20 sequential thumb-to-four-digits oppositions. In the group of patients who were able to carry out this task, this time varied from 46 to 120 sec on the paretic side versus 18 to 41 sec on the normal side (see Table 1). The control group consisted of eight normal right-handed adults (age range, 22–45; seven men and one woman) from our previous study (27).

Motor Task. During the fMRI scans, the subjects were instructed to perform a repetitive finger opposition task in which the thumb sequentially touched each of the four digits. Patients 2 and 6 were unable to move the last two digits of their paretic hand and were instructed to sequentially touch their thumb to the second and third fingers only. All subjects were instructed to perform the task as rapidly as possible. The instructions for the subjects to start and stop the task were given through the scanner-room intercom. Task performance was verified through a camera in the scanner room.

MRI. All MRI experiments were performed on a 1.5-T clinical scanner with a quadrature head coil (Signa, GE Medical Systems, Milwaukee, WI). First, the hand sensorimotor region was located on multislice coronal T_1 -weighted images of brain anatomy. To increase signal-to-noise during the fMRI scan, a gradient echo pulse sequence (GRASS) was modified to produce images with low spatial resolution (64×128 matrix over a 24 cm field-of-view) and narrow receiver bandwidth (± 8 kHz) (27). During the fMRI study, this modified GRASS was used to acquire four axial sections with 7- to 8-mm thickness during 14 sec ($T_R/T_E = 50/39$ msec; flip angle, 35° ; and one excitation), followed by an 8-sec delay. The fMRI scan protocol consisted of a baseline scan period followed by scans during four to eight alternating periods of task performance and rest. Each period lasted about 1–2 min; the whole fMRI protocol lasted about 7 min. In the baseline period, subjects were in a resting condition and images

acquired were not affected by residual signal from previous tasks. This protocol was repeated twice for each hand. Finally, a T_1 -weighted volumetric gradient echo pulse sequence (SPGR) was used to produce 60 contiguous 3-mm sagittal images of cranial anatomy, which were used to create a three-dimensional model of the brain anatomy of each subject. During the scan the subjects wore ear plugs and were instructed to keep their eyes closed. To reduce head motion, each subject's head was packed firmly in the head coil with Styrofoam pads, and the forehead was held down by surgical tape. Before the scan, the patients were instructed to practice the task until they could confidently perform it. The whole protocol lasted about 1 hr.

Data Analysis. Identification of significant signals during brain activation. Student's t test was applied to identify pixels containing significantly different baseline and activated signal intensities (27). Those pixels with high t values ($t > 4.58$) were further tested by temporal cross-correlation with a sine wave having the periodicity of the motor-task protocol (28). Pixels having cross-correlation coefficients greater than 0.725 were considered to represent significant functional activity. The total volume of activated brain tissue was then computed by summing the volumes of these significant pixels.

Image display. The volumetric images were reformatted to produce T_1 -weighted axial images of anatomy at the same planes scanned with fMRI. Significant fMRI signals were then overlaid on these images to produce integrated cross-sectional images of brain structure (gray scale) and function (color coded). The volumetric images were also used to create a three-dimensional model of the subject's gyral anatomy (29). Then, the significant functional signals were projected onto these three-dimensional models to produce integrated three-dimensional images of each subject's brain structure and function.

Spatial distribution of functional signals. To study the brain organization of hemiparetic patients, we sought to characterize the spatial distribution of the functional signals in the intact hemispheres of these patients. The three-dimensional model of each subject's brain was used to identify anatomic landmarks, such as the central sulcus and pre- and postcentral gyri. Coordinates of these landmarks were transferred to the integrated cross-sectional images of each subject. These landmarks were used to divide each undamaged hemisphere into Rolandic and non-Rolandic zones: the Rolandic zone was defined as the region between the anterior margin of the precentral gyrus and the posterior

margin of the postcentral gyrus; the remainder of the hemisphere was termed the non-Rolandic zone. In each intact hemisphere, every voxel with significant functional signal was identified as being in either the Rolandic or non-Rolandic zone. In the Rolandic zone of the hemiparetic patients we computed the ratio (I/C) of the volume of significant functional signal from ipsilateral (paretic) hand movement to that from contralateral (normal) hand movement. The corresponding I/C volume ratio in the left hemisphere of the right-handed normal subjects was also computed. The I/C volume ratio of the hemiparetic patients was then compared to that of the control group. We also computed the ratio (NR/R) of the volume of signal in the non-Rolandic zone of the undamaged hemisphere to that in the Rolandic zone during paretic hand movement. This was compared to the NR/R ratio in the left hemispheres of normal subjects during left (ipsilateral) hand movement.

Statistical analysis. A nonparametric χ^2 test was applied to examine the primary contrast between the average I/C ratios in the patient group and in the control group. A similar analysis was applied to the average NR/R ratios in the hemiparetic and control group.

RESULTS

Significant increases in fMRI signal in both hemispheres were observed during both normal and paretic hand movements for the six patients. For example, Fig. 1 shows two integrated cross-sectional images of brain structure and function from a patient with left-hemisphere injury during task performance with the normal (left) and paretic (right) hands (patient 5 in Table 1). The functional activation was also observed in the other three slices during both hand movements. Fig. 2 shows two representative time courses of the fMRI signals obtained from the patient in Fig. 1. The fMRI signals, which passed the double criteria of $t > 4.58$ and cross-correlation coefficient > 0.725 , demonstrate the dynamic response of the sensorimotor cortex to the finger movement (Fig. 2). Fig. 3 shows three-dimensional images of brain structure and function of the same patient, including the functional signals from all four

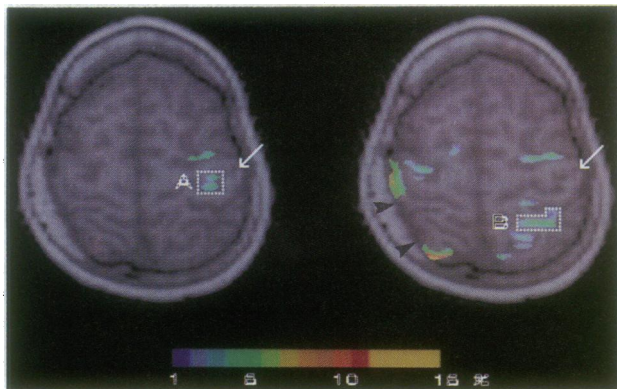


FIG. 1. Integrated cross-sectional images of brain structure (gray scale) and function (color) of patient 5 with left hemisphere damage during movements of the fingers of the normal (left) hand (Left) and the paretic (right) hand (Right). These two images are at the same anatomic location, which is one of the four planes acquired during the fMRI scan. fMRI signals were detected in the intact (right) hemisphere during movements of both the normal and paretic hands. The functional signals were distributed around the lesion in the damaged hemisphere (Right). Filled arrowheads denote the edge of the lesion. White arrows indicate the central sulcus in the intact hemisphere. Dotted lines indicate regions of interest A and B whose time courses are plotted in Fig. 2. The color bar represents the percentage change (scale from 1% to 15%) in the fMRI signal between task performance and baseline scans.

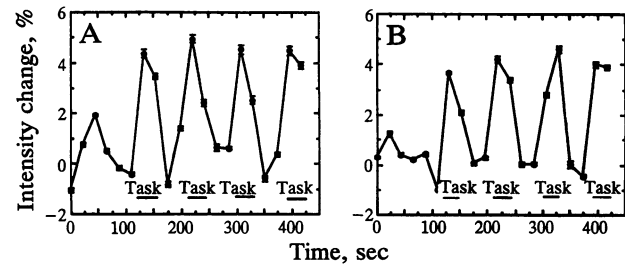


FIG. 2. Time courses of the functional signals of patient 5 (expressed as percentage of baseline signal intensity) observed during the motor-task protocol, which consisted of alternating task and rest periods. A and B show the fMRI signals from regions of interest A and B found in Fig. 1 Left and Right, respectively. Error bars indicate the SEM.

slices. During left (normal) hand task performance, fMRI signals were observed only in the right (intact) hemisphere; i.e., the normal hand was linked primarily to the contralateral hemisphere. However, during movement of the right (paretic) hand, fMRI signals were observed in both hemispheres; i.e., the paretic hand was linked to both the contralateral and ipsilateral hemispheres. During paretic hand movement, the fMRI signal distribution in the damaged (contralateral) hemisphere was distributed around the site of the lesion, whereas the intact (ipsilateral) hemisphere showed a large volume of signals in the non-Rolandic zone, mainly posterior to the central sulcus. The distribution and location of the fMRI signals were evaluated from maps of this type. Fig. 4 shows integrated three-dimensional images of brain anatomy and function of another patient with damage to the right hemisphere (patient 2 in Table 1). In this patient, with a large cortical lesion, there was a near absence of fMRI signals in the damaged hemisphere and a large volume of ipsilateral signals in the intact hemisphere during movement of the paretic hand. As with patient 5 (Figs. 1 and 3), the functional signals during paretic hand movement were more widely distributed than in the normal subjects (Fig. 5), with reorganization largely in areas posterior to the Rolandic zone. Fig. 5 shows a representative example of integrated three-dimensional images of function and anatomy of a right-handed normal subject.

Table 1 lists the averaged I/C ratios over two trials in the intact hemispheres of the hemiparetic patients; this ratio is a measure of the relative amount of contralateral and ipsilateral activation in the dominant hemispheres. As noted in Table 1,

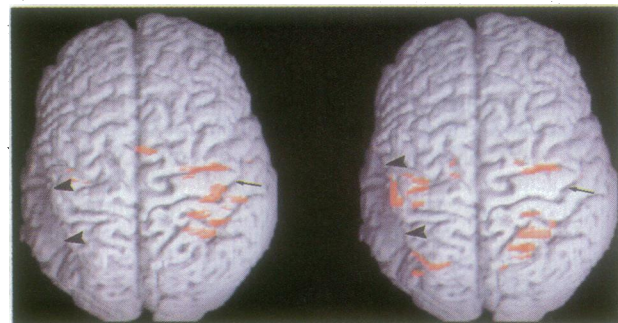


FIG. 3. Superior-view three-dimensional maps of brain surface anatomy (gray scale) with projected sensorimotor functional signals (color) of patient 5 during movements of the fingers of the normal (left) hand (Left) and the paretic (right) hand (Right). The volumes of fMRI signals observed in the intact hemisphere during both normal and paretic hand movements were larger than those in the left hemisphere of the control subjects (see Fig. 5). The fMRI signals in the intact hemisphere during paretic hand movement were posterior to the Rolandic zone. Arrows indicate the right central sulcus. Arrowheads indicate the lesion in the left hemisphere.

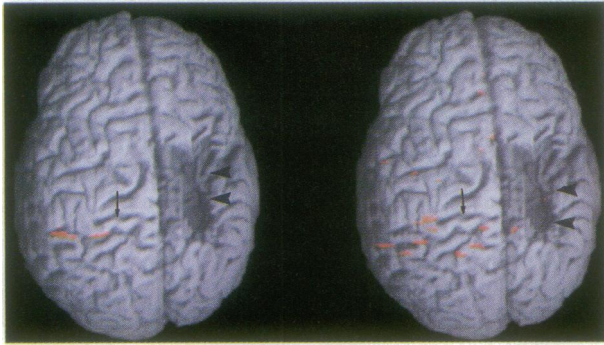


FIG. 4. Integrated three-dimensional brain models of patient 2, with right hemisphere injury, displaying gyral anatomy and sensorimotor functional signals during movement of the fingers of the normal (right) hand (*Left*) and the paretic (left) hand (*Right*). A large volume of ipsilateral functional signals was mapped in the intact hemisphere during paretic hand movement (*Right*). In this patient, with a large cortical lesion, there were only minimal fMRI signals in the damaged hemisphere during movement of the paretic hand. Arrows indicate the left central sulcus. Arrowheads indicate the lesion in the right hemisphere.

voluntary movement of the paretic hand was accompanied by minor involuntary movement of the intact hand in five patients. These involuntary mirror movements were also observed in the paretic hand of three patients when they were instructed to move their normal hand. The average value of the I/C ratio in the hemiparetic group was 0.94 ± 0.34 ($n = 6$), 7 times larger than the average I/C ratio of the left hemisphere of the control subjects (mean value, 0.14 ± 0.05 ; $n = 8$). This difference was statistically significant at the $P < 0.02$ level. In addition, we found no significant absolute difference in contralateral signal volumes in the Rolandic region between the intact hemispheres of the patients and the left hemispheres of the normal subjects during contralateral hand movement. Furthermore, no significant difference between the left and the right hemispheres of the control subjects was found; specifically, the average volume I/C ratio of the right hemisphere was 0.13 ± 0.06 ($n = 8$).

The NR/R ratio was evaluated in order to measure the spatial distribution of the fMRI signals within each hemisphere. A large value of the NR/R ratio indicates a wide signal distribution. During paretic hand movement, the intact (ipsilateral) hemispheres of the hemiparetic patients had an average NR/R ratio equal to 0.49 ± 0.20 ($n = 6$). This was twice the average NR/R ratio (0.23 ± 0.12) of the left hemisphere of normal subjects during left (ipsilateral) hand movements. This difference was not statistically significant

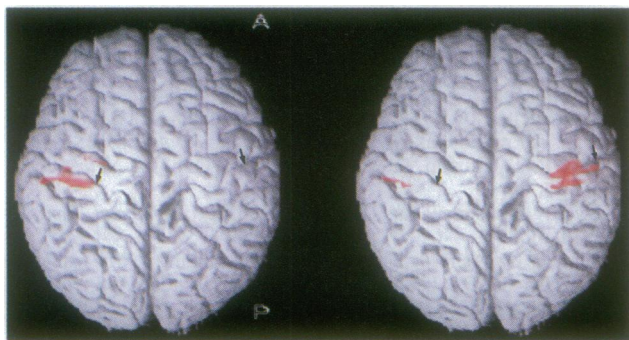


FIG. 5. Three-dimensional brain maps of a right-handed normal subject displaying gyral anatomy with projected sensorimotor functional signals during movement of the right hand (*Left*) and the left hand (*Right*). A small volume of ipsilateral fMRI signal was observed during left hand movement. Arrows indicate the central sulci. A, anterior; P, posterior.

($P > 0.1$). However, two of the hemiparetic patients (patients 5 and 6) had a particularly wide distribution of fMRI signals, with NR/R ratios 6.0 and 3.5 times the average observed for the normal subjects. Their absolute volumes of activation within the Rolandic region of the intact hemisphere during paretic hand movement were also larger than those of the other four patients (Table 1). In addition, there was no significant difference between the average NR/R ratios in the intact hemisphere of the group of patients during normal hand movement and in the dominant left hemisphere of the control group during right hand movement ($P > 0.1$).

DISCUSSION

We have employed fMRI to map reorganization of brain sensorimotor function in a group of patients with neonatal unilateral brain damage. The results indicate that their intact hemispheres have approximately equal volumes activated during contralateral and ipsilateral finger movements. In contrast, the left hemispheres of right-handed normal subjects had little ipsilateral sensorimotor activation (17, 18, 27). Our study of patients with neonatal hemiparesis suggests that their intact hemispheres are much more strongly linked to the ipsilateral hand than is the case in the normal group. Although most of this ipsilateral activation involved the Rolandic zone of the intact hemisphere, regions distant from the central sulcus, especially the parietal cortex, were activated by finger movement in some hemiparetic patients. These findings are similar to the results of positron emission tomography studies of the motor system after striatocapsular infarction in adults, where increased ipsilateral motor activation and the recruitment of the inferior parietal cortex and the anterior aspects of the insula were observed (17, 18). Our findings also resemble the pattern of reorganization of the rat motor cortex after neonatal hemispherectomy (8).

Although early investigations found only contralateral motor and somatic sensory representation (30–33), there are recent reports of ipsilateral activation of the motor and sensory cortex of normal subjects (10, 34, 35). We found slight ipsilateral sensorimotor activation in the normal right-handed subjects which was more pronounced during movement of the nondominant hand (27). These results are supported by anatomic evidence of the existence of 10–15% uncrossed corticospinal tract fibers in the human (36). Kim *et al.* (37) recently reported a much greater degree of ipsilateral motor activation within the precentral gyrus in normal subjects. In contrast to the right motor cortex, which was activated only by contralateral finger movements in both right- and left-handed subjects, they reported that the left motor cortex was substantially activated by ipsilateral finger movement, especially in right-handed subjects ($I/C = 0.77$). In our study, brain injury in the hemiparetic patients occurred in the perinatal period. It is therefore unknown what their handedness would have been had they not incurred brain injury so that their intact hemispheres became dominant by default. This raises the question as to which hemisphere of normal subjects should be used as a control to characterize sensorimotor function reorganization of the intact hemisphere in the patients. As described in *Results*, we compared the average I/C ratio for the intact hemisphere of patients with ratios for both the left and right hemispheres of normal subjects.

We observed functional signals in the damaged hemisphere of all six patients during paretic hand movements (Figs. 3 and 4). However, we did not attempt to characterize the details of location and distribution of these functional signals, since they are likely to be strongly affected by lesion size and location. Furthermore, the central sulcus and other important anatomic landmarks in the damaged hemisphere were often difficult to identify for patients in this group. These factors

make it difficult to determine which signals are due to reorganization of the damaged hemisphere and which signals are "normal." However, these maps still provide functional information about the damaged hemisphere and may help surgeons minimize morbidity during surgical procedures on that side of the brain (e.g., during epilepsy surgery).

For unknown reasons, most neonatal brain damage occurs in the left hemisphere (5, 38). We studied only one patient with injury to the right hemisphere. The data collected from this patient showed several characteristics distinct from the remaining patients (Fig. 4). For instance, this patient had no mirror movements in either the normal or the paretic hand. Furthermore, the I/C ratio for this patient was much greater than the ratios detected in patients with left hemisphere injury (Table 1). This patient was one of two subjects who had the most severely impaired finger movements; he could carry out the sequential thumb opposition only to digits 2 and 3. This raises the question of whether an increased effort during task performance may be related to activation of a large cortical volume. In our study, no significant correlation between the degree of impairment and I/C was observed. This could be due to the small number of patients studied and to the complex nature of motor impairment and reorganization. A study of a larger number of cases with impairments of varying severity will be needed to answer this question.

In this study, we used a ratio to characterize the reorganization of the intact hemisphere (I/C volume), using the signal generated in this hemisphere during normal hand movement as a reference. Using a ratio reduced the effect of absolute differences in the activated volumes across the patients (Table 1). Use of a ratio may also have reduced the effect of variations in the activated volume caused by the differences in age between the patient and control groups. In this study, we did not observe a consistent pattern of activation in the region of the supplementary motor cortex of the patients. This may be due to the increased noise in the region of the inter-hemispheric fissure causing reduced pixel *t* values (39). Due to the placement of our slices, we did not record functional signals from the thalamus or cerebellum in this study.

Our results suggest other interesting topics for future investigation. Certainly, it will be desirable to study a larger number of hemiparetic patients, including those with right hemisphere damage. The control subjects should be chosen from a neurological normal population with matching age, IQ, and handedness. Finally, in addition to mapping finger sensorimotor function, it would be interesting to map the reorganization of finger sensory function in the same group of patients.

We thank Dr. Susan C. Levine for many useful discussions. This work was supported in part by grants from the National Institutes of Health (RO1 CA51245), the National Science Foundation (NSF STC DIR-8920133), and the Cancer Research Foundation. E.M.V. was supported by a National Medical Scientist Research Service Award (T 5 32 GM07281-19).

1. Woods, B. T. & Teuber, H. L. (1978) *Ann. Neurol.* **3**, 273–280.
2. Jacobsen, S. G., Mohindra, I. & Held, R. (1981) in *Documents in Ophthalmology Proceedings Series*, ed. Maffei, L. (Junk, Dordrecht, The Netherlands), Vol. 30, pp. 210–216.
3. Assaf, A. A. (1982) *Br. J. Ophthalmol.* **66**, 64–70.
4. Wilson, P. J. E. (1970) *Brain* **93**, 147–180.
5. Levine, S. C., Huttenlocher, P. R., Banich, M. T. & Duda, E. (1987) *Dev. Med. Child. Neurol.* **29**, 27–35.
6. Woods, B. T. & Teuber, H. L. (1978) *Neurology* **28**, 1152–1158.
7. Hicks, S. P. & D'Amato, J. C. (1970) *Exp. Neurol.* **29**, 416–438.
8. Huttenlocher, P. R. & Raichelson, R. (1989) *Dev. Brain Res.* **47**, 59–69.
9. Huttenlocher, P. R. & Bonnier, C. (1991) *Dev. Brain Res.* **60**, 253–260.
10. Ramachandran, V. S. (1993) *Proc. Natl. Acad. Sci. USA* **90**, 10413–10420.
11. Evarts, E. (1988) in *Recovery of Function: Theoretical Considerations for Brain Injury Rehabilitation*, ed. Bach-y-Rita, P. (Huber, Bern, Switzerland), pp. 173–186.
12. Merzenich, M. M., Kass, J. H., Wall, J. T., Sur, M., Nelson, R. J. & Felleman, D. J. (1983) *J. Neurosci.* **10**, 639–665.
13. Hubel, D. H. & Wiesel, T. N. (1965) *J. Neurophysiol.* **26**, 994–1059.
14. Letourneau, P. C. (1983) *Trends Neurosci.* **6**, 451–455.
15. Pons, T. P., Garraghty, P. E., Ommaya, A. K., Kaas, J. H., Taub, E. & Mishkin, M. (1991) *Science* **252**, 1857–1860.
16. Lewine, J. D., Astur, R. S., Davis, L. E., Knight, J. E., Macclin, E. L. & Orrison, W. W. (1994) *Radiology* **190**, 93–96.
17. Chollet, F., DiPiero, V., Wise, R. J. S., Brooks, D. J., Dolan, R. J. & Frackowiak, R. S. J. (1991) *Ann. Neurol.* **29**, 63–71.
18. Weiller, C., Chollet, F., Friston, K. J., Wise, R. J. S. & Frackowiak, R. S. J. (1992) *Ann. Neurol.* **31**, 463–472.
19. Cao, Y., Vikingstad, E. M., Huttenlocher, P. R. & Levin, D. N. (1994) *J. Magn. Reson. Imaging* **4**, 59 (abstr.).
20. Belliveau, J. W., Kennedy, D. N., McKinstry, R. C., Buchbinder, B. R., Weisskoff, R. M., Cohen, M. S., Vevea, J. M., Brady, T. J. & Rosen, B. R. (1991) *Science* **254**, 716–719.
21. Ogawa, S., Tank, D. W., Menon, R., Ellermann, J. M., Kim, S. G., Merkle, H. & Ugurbil, K. (1992) *Proc. Natl. Acad. Sci. USA* **89**, 5951–5955.
22. Kwong, K. K., Belliveau, J. W., Chesler, D. A., Goldberg, I. E., Weisskoff, R. M., Poncelet, B. P., Kennedy, D. N., Hoppel, B. E., Cohen, M. S., Turner, R., Cheng, H.-M., Brady, T. J. & Rosen, B. R. (1992) *Proc. Natl. Acad. Sci. USA* **89**, 5675–5679.
23. Bandettini, P. A., Wong, E. C., Hinks, P. S., Tikofsky, R. S. & Hyde, J. S. (1992) *Magn. Reson. Med.* **25**, 390–397.
24. Frahm, J., Bruhn, H., Merboldt, K. D. & Hancicke, W. (1992) *J. Magn. Reson. Imaging* **2**, 501–505.
25. Ogawa, S., Lee, T., Nayak, A. S. & Glynn, P. (1990) *Magn. Reson. Med.* **14**, 68–78.
26. Turner, R., LeBihan, D. L., Moonen, C. T. W., Despres, D. & Frank, J. (1991) *Magn. Reson. Med.* **22**, 159–166.
27. Cao, Y., Towle, V. L., Levin, D. N. & Balter, J. M. (1993) *J. Magn. Reson. Imaging* **3**, 869–875.
28. Bandettini, P. A., Jesmanowicz, A., Wong, E. C. & Hyde, J. S. (1993) *Magn. Reson. Med.* **30**, 161–165.
29. Levin, D. N., Hu, X., Tan, K. K., Galhotra, S., Pelizzari, C. A., Chen, G. T. Y., Beck, R. N., Chen, C. T., Cooper, M. D., Mullan, J. F., Hekmatpanah, J. & Spire, J. P. (1989) *Radiology* **172**, 783–789.
30. Penfield, W. & Boldrey, E. (1936) *Brain* **60**, 389–443.
31. Woolsey, C. N., Erickson, T. C. & Gilson, W. E. (1979) *J. Neurosurg.* **51**, 476–506.
32. Roland, P. E., Larsen, B., Lassen, N. A. & Skinhoj, E. (1980) *J. Neurophysiol.* **43**, 118–136.
33. Roland, P. E., Meyer, E., Shibasaki, T., Yamamoto, Y. L. & Thompson, C. J. (1982) *J. Neurophysiol.* **48**, 467.
34. Colebatch, J. G., Deiber, M.-P., Passingham, R. E., Friston, K. J. & Frackowiak, R. S. J. (1991) *J. Neurophysiol.* **65**, 1392.
35. Fox, P. T., Burton, H. & Raichle, M. E. (1987) *J. Neurophysiol.* **67**, 34–43.
36. Nyberg-Hansen, R. & Rinvik, E. (1963) *Acta Neurol. Scand.* **39**, 1–30.
37. Kim, S. G., Ashe, J., Hendrich, K., Ellermann, J. M., Merkle, H., Ogawa, S., Ugurbil, K. & Georgopoulos, A. P. (1993) *Science* **261**, 615–617.
38. Perlstein, M. A. & Hood, P. N. (1954) *Pediatrics* **14**, 436–441.
39. Grafton, S. T., Woods, R. P., Mazziotta, J. C. & Phelps, M. E. (1991) *J. Neurophysiol.* **66**, 735–743.