

Clinical Research

Effect of *Neem* oil and *Haridra* on non-healing woundsAnjali Singh, Anil Kumar Singh, G. Narayan¹, Teja B. Singh², Vijay Kumar Shukla³Department of Dravyaguna, ¹Department of Human and Molecular Genetics, ²Department of Community Medicine, ³Department of General Surgery, Institute of Medical Sciences, Banaras Hindu University, Varanasi, Uttar Pradesh, India

Access this article online

Website: www.ayujournal.org

DOI: 10.4103/0974-8520.158998

Quick Response Code:



Abstract

Background: In Ayurveda, *Vrana* (wound) has stated as tissue destruction and discoloration of viable tissue due to various etiology. In *Sushruta Samhita*, Sushruta described *Vrana* as a main subject. Most commonly *Vrana* can be classified into *Shuddha* and *Dushta Vrana* (chronic wound/nonhealing ulcers). Among the various drugs mentioned for *Dushta Vrana*, two of them, *Neem* (*Azadirachta indica* A. Juss) oil and *Haridra* (*Curcuma longa* Linn.) powder are selected for their wide spectrum action on wound. **Aim:** To compare the effect of *Neem* oil and *Haridra* in the treatment of chronic non-healing wounds. **Materials and Methods:** Total 60 patients of wounds with more than 6 weeks duration were enrolled and alternatively allocated to Group I (topical application of *Neem* oil), Group II (*Haridra* powder capsules, 1 g 3 times orally) and Group III (both drugs). Duration of treatment was considered until complete healing of the wound, whereas 4th and 8th week were considered for assessment of 50% healing. Wound size was measured and recorded at weekly intervals. Wound biopsy was repeated after 4 weeks for assessment of angiogenesis and deoxyribonucleic acid (DNA) analysis. **Results:** After 8 weeks of treatment, 50% wound healing was observed in 43.80% patients of Group I, 18.20% patients of Group II, and 70.00% patients of Group III. Microscopic angiogenesis grading system scores and DNA concentration showed highly significant effect of combined use of both drugs when compared before and after results of treatment ($P < 0.001$). **Conclusion:** Topical use of *Neem* oil and oral use of *Haridra* powder capsule used in combination were found effective for chronic non-healing wounds.

Key words: Chronic wound, *Haridra*, microscopic angiogenesis grading system score, *Neem* oil, wound healing

Introduction

Vrana (wound) and its management has been dealt since the period of the *Veda* to current era.^[1] It has been a major problem since the early stage of medical science. Chronic nonhealing wounds present serious problems for patients, family, and clinicians. Most are associated with a small number of underlying disorders such as diabetes, leprosy, and peripheral vascular diseases.^[2] The development of pharmacological agents (antibiotics, vasodilators, antioxidant, and Vitamins) has enhanced the healing of acute as well as chronic wounds. In spite of all these recent advances lacunae still persists. Wound infection has been one of the major impediments in the process of wound healing and after invention of antibiotics; it was thought that this

problem would be conquered. Since then, several antibiotics in the form of systemic and local use have been tried, but problems of chronic wound healing remain as such. Research on wound healing drugs is a potential area in biomedical sciences. Ayurveda, the Indian traditional system of medicine, mentions the values of many medicinal plants for wound healing. Scientists who are trying to explore newer drugs from natural resources are looking towards Ayurveda because phyto-medicines are not only affordable, but are comparatively safe also. Several drugs from plant, mineral, and animal origin are described in Ayurveda for their wound healing properties under the term *Vranaropaka* (wound healing agent). Wound healing activities of some plants have been screened scientifically in different pharmacological models and patients, but the potential of most of them still remains unexplored. Some Ayurvedic plants, namely *Vata* (*Ficus bengalensis* Linn.), *Durva* (*Cynodon dactylon* Pers.), *Lodhra* (*Symplocos racemosa* Roxb.), *Manjishtha* (*Rubia cordifolia* Linn.), *Chandan* (*Pterocarpus santalinus* Linn. f.), *Gular* (*Ficus racemosa* Roxb.), *Yashtimadhu* (*Glycyrrhiza glabra* Linn.), *Daruharidra* (*Berberis aristata* DC.),

Address for correspondence: Dr. Anjali Singh,
218/B, Brij Enclave Colony, Sundarpur, Varanasi - 221 005,
Uttar Pradesh, India.
E-mail: dranjalirathor23@gmail.com

Haridra (*Curcuma longa* Linn.), *Mandukaparni* (*Centella asiatica* (Linn.) Urban), *Snuhi* (*Euphorbia nerifolia* Linn.), and *Chrita Kumarai* (*Aloe vera* Tourn. ex Linn.) were found to be effective in experimental models.^[3] Among them two drugs *Azadirachta indica* A. Juss and *C. longa* were selected here for clinical assessment in chronic non-healing wounds. Most of the chronic non-healing wounds are associated with co-morbid conditions such as diabetes, leprosy and peripheral vascular disease.^[2] Various topical agents such as growth factors and angiogenic factors are gaining importance in wound care^[4,5] and are used for the treatment of underlying co-morbidities.

Materials and Methods

Sixty patients attending the Wound Clinic at University Hospital, Varanasi were enrolled for this study. This study was approved by Institutional Ethics Committee (Letter No. Dean/2006-07/881, Dated: December 12, 2006).

Inclusion criteria

- Patients aged between 19 and 78 years of either sex
- Patients with non-healing chronic wounds of more than 6 weeks duration were included.

Exclusion criteria

- Patients having malignant wounds, osteomyelitis, and unwillingness to attend the clinic regularly for treatment and assessment were excluded.

Laboratory investigations

Blood investigations were done for hemoglobin%, total leukocyte count differential leukocyte count, erythrocyte sedimentation rate, total serum protein, serum albumin, blood sugar, and blood urea.

Grouping and treatment protocols

Among 60 patients only 47 patients were completed the treatment and they were alternately allocated into three groups:

Group I: Wounds were treated with topical use *Neem* oil only ($n = 16$)

Group II: *Haridra* capsule 1 g 3 times a day orally ($n = 11$)

Group III: Both the drugs were administered, that is, *Neem* oil for topical application and *Haridra* capsule 1 g 3 times a day orally ($n = 20$).

For the present work, the oil is prepared by pressing (cold pressed method) of *Neem* seed kernel.

Dressings were changed daily in patients of all three groups. Duration of treatment considered till complete healing of wound and 4th and 8th week is only for assessment of 50% healing because study sample was small.

Assessment criteria

Wound area

Size of the wound was recorded by tracing the perimeter of the wound on transparent plastic sheets at every 2 weeks. Wound size (percentage area of wound healed/total area of wound $\times 100$) was assessed.

Microscopic angiogenesis grading system score

Biopsies were performed before initiating the treatment and after 4 weeks of treatment to assess angiogenesis. These were analyzed using the microscopic angiogenesis parameters of endothelial cell regeneration: Vasoproliferation, endothelial cell hyperplasia and endothelial cytology. A numerical grade was given to each variable and a simple equation was used to calculate the overall index of endothelial regeneration – the microscopic angiogenesis grading system (MAGS) score.^[6,7]

Formula used to calculate the MAGS score:

$$\text{MAGS} = \text{KaN} + \text{KbE} + \text{KcX}$$

(N = Number of capillaries per high power field, Ka = 1, E = Number of endothelial cells lining the cross-section of a capillary, Kb = 3, X = Endothelial cell cytology on a scale of 0–5, Kc = 6, Ka, Kb, and Kc are constants with fixed values of 1, 3, and 6, respectively).

Endothelial cell cytology scale:

0 = Normal cell: Thin, flat, well-differentiated nucleus;

1 = Plump, clear nucleus;

2 = Plump, clear nucleus plus prominent nucleolus;

3 = Large hyperchromatic nucleus;

4 = Irregular endothelial cell that cannot be classified as containing mitotic or hyperchromatic nuclei;

5 = Mitotic figure.

Deoxyribonucleic acid analysis

DNA content estimation was done in the sample of wound tissue by phenol-chloroform method [Chart 1]. Tissue was kept in ribonucleic acid later solution at -70°C temperature for DNA assessment.^[8] DNA assessment was done twice that is before treatment and after 4 weeks of scheduled treatment.

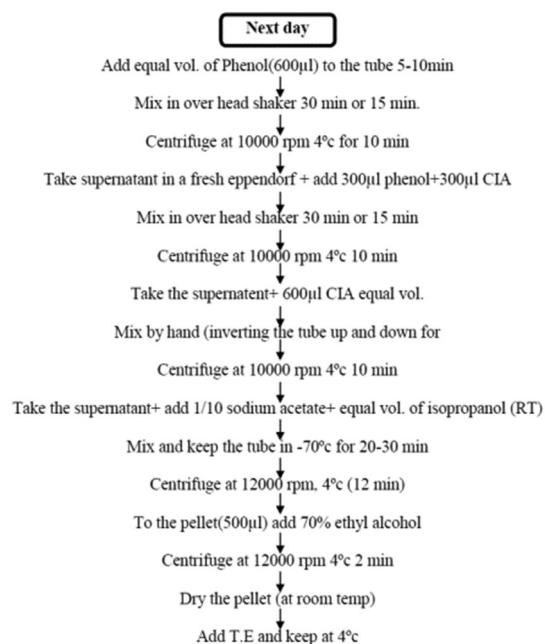
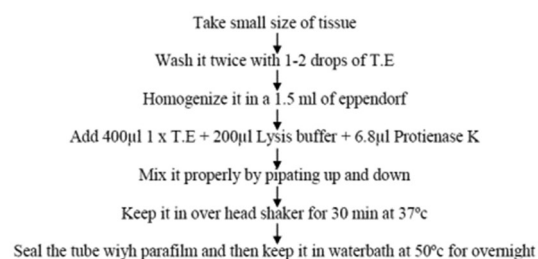
Statistical analysis

Statistical analysis was done using the ANOVA test to compare MAGS score in all groups. The distribution of DNA variable did not follow the normal distribution; therefore, nonparametric Kruskal–Wallis test was used to find out the significant difference at mean level in various study groups.

Observations

All three groups were considered in terms of patients characteristics (means characters related to wound like site of the wound, type of wound, duration of wound, etc.). Wound duration ranged from 1.5 to 3 months in 12 patients, 3 to 6 months in 9 patients, 6 to 12 months in 10 patients, 12 to 36 months in 10 patients, 36 months and above in 6 patients. Mean duration in Group I was 61.56 ± 189.05 (range 6–77) weeks, 14.82 ± 19.18 (range 6–72) weeks Group II, 29.85 ± 79.32 (range 6–36) weeks in Group III.

The ulcer was on lower limb in 93.61% of patients. When the data for the lower limb was analyzed for the exact location of the wound, it was found that the plantar aspects of feet were the most common sites. The plantar aspect of the foot accounted for 29.9% of ulcers among 47 cases. Diabetes (42.55%) was the most common underlying cause of the nonhealing ulcers, followed by leprotic (24.4%), venous ulcer (21.28%), and pressure ulcer (12.77%) [Table 1]. The patients had previously



[Note: T.E- Tris EDTA solution, CIA – Chloroform (24) + Isoamyl Alcohol (1), RT- Room Temperature]

Chart 1: Phenol chloroform method for deoxyribonucleic acid estimation in tissue

used other topical preparations, including antibiotic ointments and antiseptic creams for varying lengths of time. Those with leprosy had received antileprotic treatment, which resulted in minimal improvement in healing.

Results

More than 50% healing at 12 weeks was observed in 75% of cases in Group I, 54% in Group II and 90% in Group III with $P = 0.082$, which shows statistical insignificance of healing in Group III. Beneficial effects of therapy were obvious from 4th week onwards. Among these patients pus and discharge decreased and granulation tissue began to appear by 2nd week, only one patient of Group III showed hypergranulation tissue formation [Table 2].

Those wounds that achieved 50% healing at the end of 8 weeks were, 43% in Group I, 18% in Group II, and 70% in Group III.

Increased angiogenesis was evident after four weeks in all groups when histopathological assessment was undertaken to identify MAGS scores [Figures 1 and 2]. Statistically significant difference was observed in MAGS scores among all groups and $P = 0.02$ after treatment [Table 3].

Table 1: Etiology of non-healing wounds

Etiology	Number of patients		
	Group I (n=16)	Group II (n=11)	Group III (n=20)
Diabetes	5	3	12
Leprosy	7	2	2
Venous ulcer	0	6	4
Decubitus	4	0	2

Table 2: Evidence of >50% wound healing during treatment in three groups

Duration	Number (%)			P
	Group I (n=16)	Group II (n=11)	Group III (n=20)	
4 weeks	3 (18)	0 (0)	5 (25)	0.20
8 weeks	7 (43)	2 (18)	14 (70)	0.02
12 weeks	12 (75)	6 (54)	18 (90)	0.082

Deoxyribonucleic acid concentration (ng/µl) in wound tissue at the interval of four weeks showed statistically significant difference in all three groups [Figures 3 and 4]. The significant difference among the mean DNA was observed after treatment ($P = 0.023$). Thereafter, Mann-Whitney U-test was used to find the pair wise difference in mean [Table 4]. Figure 5 shows effect of therapy before and after treatment in some of the patients.

Results of ≥50% healing among different types of wounds

There is very small number of patients in each cell; therefore, no statistical tests have been used except in diabetic wound at eight weeks. There is a significant difference ($P < 0.05$) in the proportions of more than 50% healing. In diabetic wound up to eight weeks 40% healing seen in Group I, 0% in Group II and 75% in Group III, in leprotic wound up to eight weeks percentage healing was 57%, 0% and 50% in Group I, II, and III, respectively. In Venous ulcer 50% healing at eight week shows 0%, 33% and 75% in Group I, II, and III [Table 5].

Histopathological examination and DNA assessment of 47 cases showed that combined use of both drugs showed a significant effect in Group III.

Discussion

In spite of brilliant progress in surgery, wound management still remains a subject of speculation and the early manifestation of unsatisfactory healing pose serious complication leading to prolonged healing and even death in surgical practice.^[9]

It was already said that non-healing and chronic wounds are mostly concerned with a diabetic condition.^[10] In the case of diabetic ulcer the effect of *Neem* oil (*A. indica*) and *Haridra* (*C. longa*), there is a synergetic effect of both drugs, while when they are used alone is not very significant. However, it is observed that use of *Neem* oil alone is comparatively better than the single use of *Haridra* capsule.

This study showed that combined use of *Neem* oil and *Haridra* can be a better option for chronic non healing wounds. MAGS

Table 3. Mean MAGS scores achieved following treatment within three groups

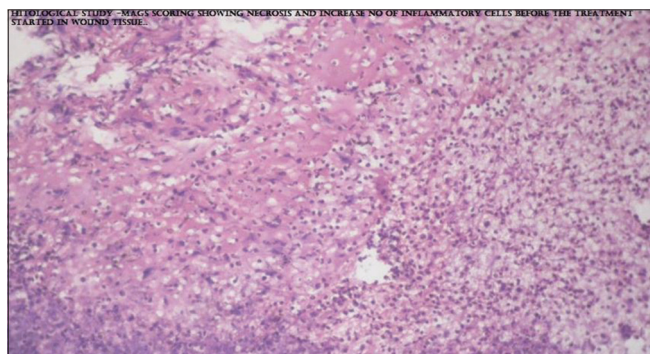
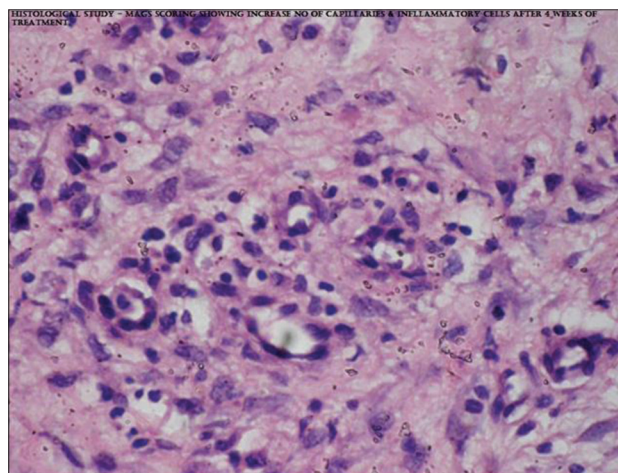
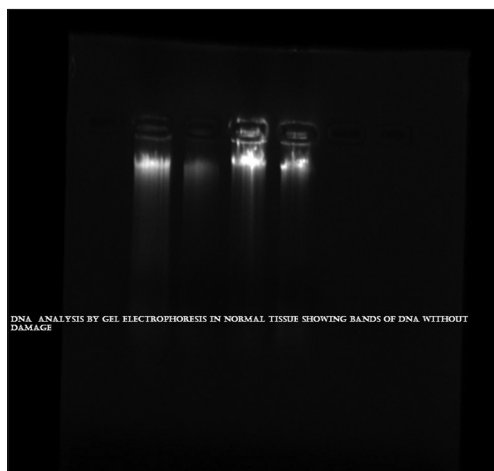
Duration value	Mean MAGS score			P
	Group I	Group II	Group III	
Baseline±SD (range)	30.12±12.87 (23-36)	24.64±7.14 (19-29)	31.6±11.6 (26-32)	0.26
4 weeks±SD (range)	39.56±13.91 (32-46)	29.91±8.21 (24-35)	43.75±12.8 (37-49)	0.02

MAGS: Microscopic angiogenesis grading system

Table 4: DNA concentration achieved within three groups

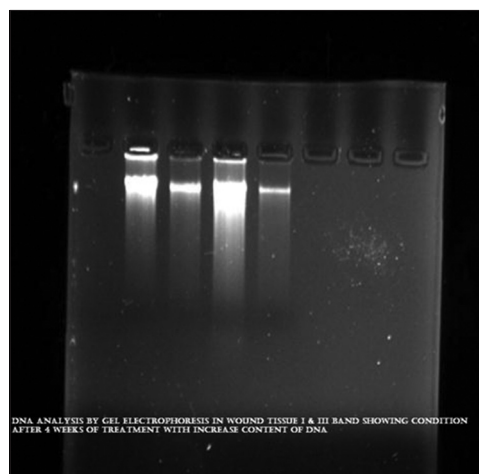
Duration	Mean DNA concentration			P
	Group I	Group II	Group III	
Baseline±SD (range)	82.2±49.67	68.11±55.06	81.85±52.08	0.58
4 weeks±SD (range)	161.93±70.15	106.55±76.92	205.28±115.78	0.023

SD: Standard deviation, DNA: Deoxyribonucleic acid

**Figure 1: Microscopic angiogenesis grading system score in wound tissue before treatment****Figure 2: Microscopic angiogenesis grading system score in wound tissue after 4 week of treatment****Figure 3: Deoxyribonucleic acid concentration in wound tissue before treatment**

scores revealed that it promoted vascular proliferation and DNA concentration in the regenerated tissues. Nimbidin, the principal component of *Neem* oil, is highly bitter and contains sulfur^[11] and sulfur has antifungal, antibacterial and keratolytic properties.^[12]

Rhizome of *Haridra* is brownish, yellow in color and powder of *Haridra* is used systemically for wound healing. It possess antibacterial, antifungal and anti-inflammatory activities.^[13] It is useful in inflammations, ulcers, wounds,

**Figure 4: Deoxyribonucleic acid concentration in wound tissue after 4 week of treatment**

leprosy, skin diseases and allergic conditions.^[14] Rhizomes of it contain curumin (diferuloylmethane), turmeric oil or turmerol and 1,7-bis, 6-hepta-diene-3, 5-dione, proteins, fat, Vitamin A, B, and C. Curcumin has potent anti-inflammatory and analgesic activities.^[15] The anti-inflammatory property and the presence of

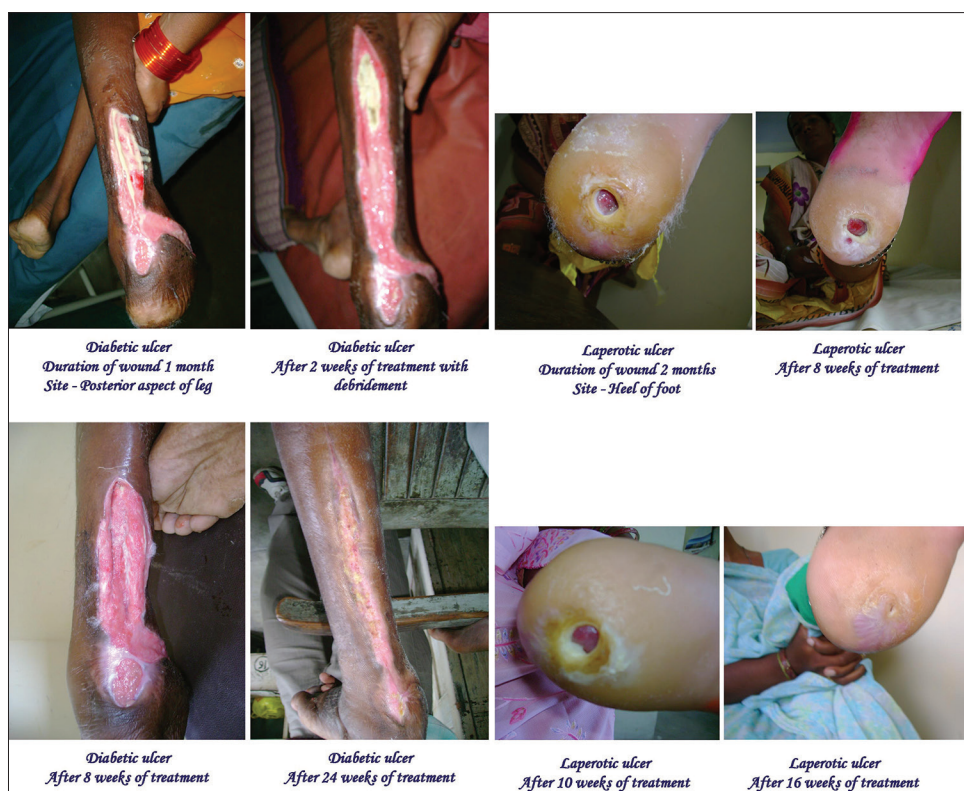

Figure 5: Wound healing at different stages

Table 5 : Results of more than 50% healing in wounds among different types of wounds in the study

Type of wounds (%)	Assessment of 50% healing at					
	8 weeks			12 weeks		
	I	II	III	I	II	III
Diabetic	40	0	75	100	100	100
Leprotic	57	0	50	100	100	100
Venous	0	33	75	0	100	100
Pressure	50	0	50	100	0	100

Due to very small sample size in each cell, therefore, no statistical tests have been used except in diabetic wound at 8 weeks; there is significant difference ($P < 0.05$) in the proportions of 50% healing

Vitamin A and proteins in turmeric result in the early synthesis of collagen fibers by mimicking fibroblastic activity.^[16]

Antimicrobial effects of *Neem* extract have been demonstrated against *Streptococcus mutans* and *Streptococcus faecalis*.^[17] Similarly, curcumin is an important constituent of turmeric powder, has shown faster wound closure of punch wounds by re-epithelialization of the epidermis and increased migration of various cells including myofibroblasts, fibroblasts, and macrophages in the wound bed. Multiple areas within the dermis showed extensive neo-vascularization as well.^[18]

Conclusion

In this study, the topical use of *Neem* (*A. indica*) oil and systemic use of *Haridra* (*C. longa*) in both groups were found effective in healing the chronic wound. Both drugs have proven value in the management of non-healing wounds. They

have also angiogenic property and potency to increase DNA content as well. The combination of *Neem* and *Haridra* is best to treat diabetic chronic wounds in a better way, both drugs showed a remarkable effect in leprotic, venous, and decubitus ulcer as well. In view of no any adverse effects and affordable economically by all, it can be recommend in combination for the treatment of chronic non healing wound.

References

1. Global Lower Extremity Amputation Study Group. Epidemiology of lower extremity amputation in centres in Europe, North America and East Asia. The Global Lower Extremity Amputation Study Group. *Br J Surg* 2000;87:328-37.
2. Shukla VK, Rasheed MA, Kumar M, Gupta SK, Pandey SS. A trial to determine the role of placental extract in the treatment of chronic non-healing wounds. *J Wound Care* 2004;13:177-9.
3. Biswas TK, Mukherjee B. Plant medicines of Indian origin for wound healing activity: A review. *Int J Low Extrem Wounds* 2003;2:25-39.
4. Shun A, Ramsey-Stewart G. Human amnion in the treatment of chronic ulceration of the legs. *Med J Aust* 1983;2:279-83.
5. Cheon SS, Nadesan P, Poon R, Alman BA. Growth factors regulate beta-catenin-mediated TCF-dependent transcriptional activation in fibroblasts during the proliferative phase of wound healing. *Exp Cell Res* 2004 15;293:267-74.
6. Kumar M, Tandon V, Singh PB, Mitra S, Vyas N. Angiogenesis and histologic scoring in prostatic carcinoma: A valuable cost effective prognostic indicator. *Uro Oncol* 2004;4:139.
7. Brem S, Cotran R, Folkman J. Tumor angiogenesis: A quantitative method for histologic grading. *J Natl Cancer Inst* 1972;48:347-56.
8. Sambrook J, Russell DW. *Molecular Cloning: A Laboratory Manual*. 3rd ed. New York: Cold Spring Harbor Laboratory Press; 2001. p. 604-8.
9. Boateng JS, Matthews KH, Stevens HN, Eccleston GM. Wound healing dressings and drug delivery systems: A review. *J Pharm Sci* 2008;97:2892-923.

10. Chronic wound. Wikimedia Foundation, Inc Available from: http://www.en.wikipedia.org/wiki/Chronic_wound. [Last modified on 2014 May 02; Last accessed on 2014 Jun 17].
11. Sharma PC, Yelne MB, Dennis TJ. Database on Medicinal Plants Used in Ayurveda and Siddha. Vol. I. New Delhi: CCRAS (Dept. of AYUSH, Min. of Health and F.W., Govt of India); 2007. p. 289.
12. Sauder DN, Miller R, Gratton D, Danby W, Griffiths C, Phillips SB. The treatment of rosacea: The safety and efficacy of sodium sulfacetamide 10% and sulfur 5% lotion (Novacet) is demonstrated in a double-blind study. *Dermatolog Treat* 1997;8:79-85.
13. Chopra RN, Chopra IC, Nayar SL. Glossary of Indian Medicinal Plants. New Delhi: Publications and Information Directorate, CSIR; 1956 p. 241.
14. Sharma PC, Yelne MB, Dennis TJ. Database on Medicinal Plants Used in Ayurveda and Siddha. Vol. I. New Delhi: CCRAS (Dept. of Ayush, Min. of Health and F.W., Govt of India); 2007. P 152.
15. Kohli KR, Ali J, Ansari MJ, Raheman Z. Curcumin: A natural anti-inflammatory agent. *Indian J Pharmacol* 2005;37:141.
16. Kumar A, Sharma VK, Singh HP, Prakash P, Singh SP. Efficacy of some indigenous drugs in tissue repair in buffaloes. *Indian Vet J* 1993;70 42-4.
17. Nayaka A, Nayak RN, Saumya BG, Bhat K, Kudalkar M. Evaluation of antibacterial and anticandidial efficacy of aqueous and alcoholic extract of Neem an *in-vitro* study. *Int J Res Ayurveda Pharm* 2011;2:230.
18. Sidhu GS, Singh AK, Thaloor D, Banaudha KK, Patnaik GK, Srimal RC, et al. Enhancement of wound healing by curcumin in animals. *Wound Repair Regen* 1998;6:167-77.

How to cite this article: Singh A, Singh AK, Narayan G, Singh TB, Shukla VK. Effect of *Neem* oil and *Haridra* on non-healing wounds. *Ayu* 2014;35:398-403.

Source of Support: Nil, **Conflict of Interest:** None declared.

हिन्दी सारांश

दुष्टव्रण पर निम्ब तैल और हरिद्रा के प्रभाव का अध्ययन

अंजलि सिंह, अनिलकुमार सिंह, जी. नारायण, तेजा बी. सिंह, विजयकुमार शुक्ला

मनुष्य प्राचीन काल से ही व्रण से ग्रस्त रहा है। पहले समय से प्रायः व्रणी पुरुष वृक्ष के पत्तों का प्रयोग व्रण रोपण में करते थे। आयुर्वेद में व्रण रोपण के लिए निम्ब और हरिद्रा का उल्लेख है, अतः यह दोनों द्रव्य व्रण रोपण का अच्छा विकल्प बन सकते हैं, इसलिए इन दोनों द्रव्यों का चयन दुष्टव्रण रोपण के लिए किया गया है। दुष्टव्रण के कुल ६० रोगियों में से ४७ रोगियों को तीन वर्गों में बाँटा गया है, जिसमें से १६ रोगी वर्ग एक में, ११ रोगी वर्ग दो में, २० रोगी वर्ग तीन में रखे गए। वर्ग एक में निम्ब तैल का बाह्य प्रयोग, वर्ग दो में हरिद्रा का अभ्यंतर प्रयोग तथा वर्ग तीन में निम्ब तैल (बाह्य) तथा हरिद्रा (अभ्यंतर) दोनों का प्रयोग किया गया है। तीनों वर्गों में सांख्यिकीय दृष्टि से वर्ग तीन में महत्वपूर्ण अन्तर पाया गया। इस अध्ययन से यह निष्कर्ष निकलता है की निम्ब तैल और हरिद्रा को प्रभावशाली रूप से दुष्टव्रण रोपण में प्रयोग किया जा सकता है।