

Sacral Herpes Zoster Associated with Voiding Dysfunction in a Young Patient with Scrub Typhus

Jian Hur

Department of Internal Medicine, Yeungnam University Medical Center, Daegu, Korea

When a patient presents with acute voiding dysfunction without a typical skin rash, it may be difficult to make a diagnosis of herpes zoster. Here, we present a case of scrub typhus in a 25-year-old man with the complication of urinary dysfunction. The patient complained of loss of urinary voiding sensation and constipation. After eight days, he had typical herpes zoster eruptions on the sacral dermatomes and hypalgesia of the S1-S5 dermatomes. No cases of dual infection with varicella zoster virus and *Orientia tsutsugamushi* were found in the literature. In the described case, scrub typhus probably induced sufficient stress to reactivate the varicella zoster virus. Early recognition of this problem is imperative for prompt and appropriate management, as misdiagnosis can lead to long-term urinary dysfunction. It is important that a diagnosis of herpes zoster be considered, especially in patients with sudden onset urinary retention.

Key Words: Herpes zoster; Scrub typhus; Urinary retention

Introduction

Herpes zoster typically affects the thoracic and lumbar vertebra (T3-L3) [1, 2], and sacral herpes zoster is found in only 4% of cases [3]. It usually occurs on one side of the sacrum, and in less than 1% of cases, it occurs on both sides. It is rare that voiding dysfunction is the first symptom of herpes zoster. This dysfunction is experienced by only 4% of herpes zoster patients, but it can happen if the virus affects the sacral nerve [4]. Voiding dysfunctions caused by herpes zoster have also been reported in Korea [5, 6]. However, the cases identified so far are limited to elderly people or patients with a deteriorated

immune system, and no such occurrence has been found among young adults. Against this background, we present the case of a 25-year-old man with a normal immune system who was hospitalized for scrub typhus and experienced herpes zoster on both sides of the sacral nerve. A literature review is also included.

Case Report

A 25-year-old man was hospitalized after seven continuous days of fever, chills, and a general feeling of weakness. The pa-

Received: April 27, 2015 **Revised:** May 30, 2015 **Accepted:** May 31, 2015

Corresponding Author : Jian Hur, MD

Department of Internal Medicine, Yeungnam University Medical Center,
170 Hyeonchung-ro, Nam-gu, Daegu 705-802, Korea
Tel: +82-53-620-3830, Fax: +82-53-654-8386
E-mail: sarang7529@hanmail.net

This is an Open Access article distributed under the terms of the Creative Commons Attribution Non-Commercial License (<http://creativecommons.org/licenses/by-nc/3.0>) which permits unrestricted non-commercial use, distribution, and reproduction in any medium, provided the original work is properly cited.

Copyrights © 2015 by The Korean Society of Infectious Diseases | Korean Society for Chemotherapy

www.icjournal.org

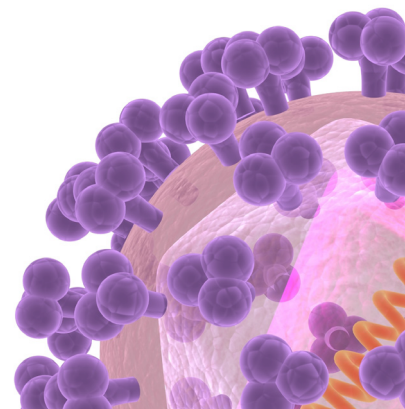

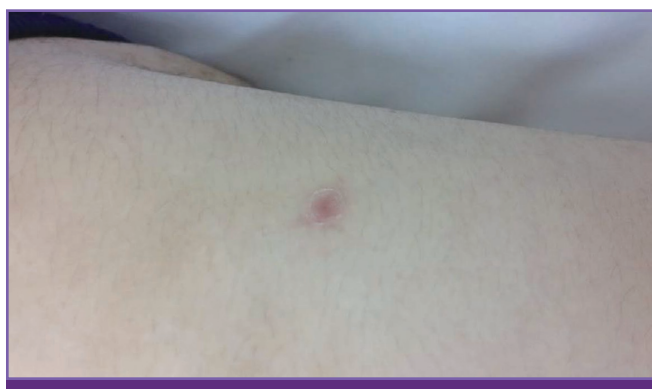


Figure 1. Eschar in right flank.

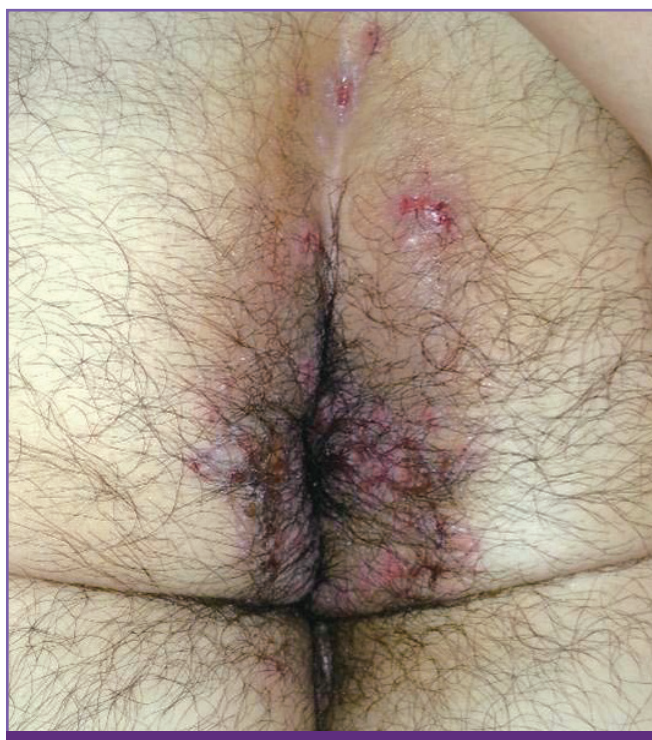

Figure 2. Patient with Herpes zoster affecting the both S1-S5 dermatomes.

tient's condition was acute, but he retained clear consciousness. His blood pressure was 140/70 mmHg, his pulse rate was 90 beats a minute, his respiratory rate was 20 breaths per minute, and his body temperature was 39.2°C. The patient reported feeling fatigued, pain upon urination, and pain in the anal area during urination and bowel movements. A skin rash was observed on the right side of the body, which was probably a eschar (Fig. 1). The patient was a college student with no previous illness, and nothing of note was found in terms of family history, personal history, or travel history. The patient had climbed a mountain on September 20th, about two weeks before his hospitalization. The fever and chills started one week

before hospitalization, and a dark red eschar of dead skin was found on the right side of the abdomen. Because the diagnosis was scrub typhus, the patient was treated with doxycycline (100 mg orally 2 times a day for seven days). The fever began to subside three days after hospitalization. On the second day, the patient reported bloody stools and severe pain around the anus. The patient was examined by a surgeon to see if there was an anal laceration. Ultrasound was performed, but no irregularity was found. A hip bath was advised, and anti-inflammatory medicine was administered. On the sixth day of hospitalization, the pain during urination lessened, but the patient still complained about voiding dysfunction. There was no decrease in the volume or frequency of daily urination. The patient felt the need to urinate as usual but had difficulty doing so. He had to suck in his stomach to urinate, and the amount of urine produced was less than usual. Constipation started on the sixth day, and the anal sphincter was weaker than usual. On the eighth day, a skin rash, several blisters the size of rice grains, and calluses were observed on both sides of the anus (Fig. 2). A Tzanck test revealed multinuclear cells. Hypalgesia of the S1–S5 dermatomes was also observed. However, a spinal MRI did not show anything unusual. The diagnosis was scrub typhus, and acyclovir and dexamethasone were administered accordingly. Three days after the administration, the constipation improved, and from the fourth day the urinary dysfunction improved to the point of waiting a few seconds before urination and not needing to suck in the stomach anymore. The results of a blood test were as follows: white blood cell count, 4,930/mm³; hemoglobin, 14.1 g/dL; platelet count, 179,000/mm³; aspartate aminotransferase, 56 IU/L; alanine aminotransferase, 43 IU/L; blood urea nitrogen, 17.35 mg/dL; creatinine, 0.97 mg/dL; albumin, 4.43 g/dL; C-reactive protein, 7.9 mg/dL; and erythrocyte sedimentation rate, 26 mm/hour. The immunofluorescence assay titer (Green cross labs, Yongin, Korea) against *Orientia tsutsugamushi* increased 4-fold or more. The fact that the blisters appeared bilaterally on each buttock simultaneously without any previous history, the size of the blister, intensity of pain, and the depth of the ulcer all indicated the diagnosis more likely as herpes zoster than herpes simplex.

Acyclovir (10 mg/kg every 8 hours) was administered for seven days, and dexamethasone (10 mg/day) was administered for six days and changed to prednisolone (100 mg orally). We tapered off prednisolone over three weeks. After that, treatment ended as the patient's symptoms subsided.

Discussion

Herpes zoster rarely causes voiding dysfunction. Varicella zoster virus (VZV) usually affects thoracolumbar nerves and dermatomes. Infection of the sacral nerve is found in only 4–8% of patients [3, 4, 6]. Although urinary dysfunction due to herpes zoster is rare, it can happen if the virus affects related nerves, particularly S2 and S3 of the sacral nerve; this affects the motor and sensory nerves of the bladder [7].

Chen, et al. reported that herpes zoster causes urinary dysfunction in only 4% of patients, but the ratio was 29% for patients who had the virus in the lumbosacral dermatome [4]. Regarding age and gender, herpes zoster accompanied by urinary dysfunction was mostly observed in middle-aged men, and the rate increased with age. The outbreak rate was high in patients with a deteriorated immune system [8]. Richmond reported that 78% of herpes zoster patients who experienced urinary retention had the virus in the sacral nerve, 11% had the virus in the thoracolumbar nerve, and 11% had the virus in the upper sternal nerve. In cases where the virus affected the sacral nerve, many patients also experienced constipation or bowel incontinence [8].

There are three types of urinary dysfunction caused by herpes zoster: cystitis, neuritis, and myelitis. The reported cases to date mostly involved cystitis or neuritis [4]. In cystitis, VZV directly attacks the bladder wall to cause urinary dysfunction, and inflammation of the mucous membrane or blisters are observed upon cystoscopy. In neuritis, VZV lurks in a posterior ganglion and then affects the motor nerve of the sacral nerve. This disrupts the reflex of the detrusor muscle and weakens the bladder. In myelitis, the upper sacral nerve of the spinal cord is damaged, which causes a rigid bladder [4].

Voiding dysfunction caused by herpes zoster responds well to treatment and usually improves along with the disappearance of skin rashes [4]. However, in some cases, acute urinary retention requires intermittent catheterization or an in-dwelling catheter. Sometimes, it takes months to restore bladder function [6, 9, 10]. Chen, et al. reported cases of catheter insertion or urethral catheterization for patients with urinary dysfunction caused by herpes zoster. The recovery took as little as two days to as long as eight weeks, but the average was 16 days [4]. Yamanashi, et al. reported an average recovery period of 5.4 weeks for seven patients [10], and Park, et al. reported an average recovery period of 12 days for 20 patients [6].

Cases of urinary dysfunction caused by herpes zoster reported so far have included symptoms such as acute urinary retention, pain upon urination, urinary incontinence, cystitis,

and neurogenic bladders. All the patients had either an impaired immune system or were elderly people aged 60 or older. There has been no reported case where a young adult with a normal immune system and without a previous illness had a dual infection of VZV and *O. tsutsugamushi*. There was a case of a 75-year-old female patient who had a hip replacement surgery, followed by a knee replacement surgery. She was affected by VZV in the sacral nerve, showing that in elderly people, multiple joint replacement surgeries can reactivate VZV [11].

Cases of the simultaneous outbreak of *O. tsutsugamushi* and *Rickettsia typhi*, *Leptospira*, or malaria have been reported in the past, but no case involving dual infection with herpes zoster has been recorded [12, 13]. One report discussed *O. tsutsugamushi*, a microorganism that causes monocyte-derived cells to trigger replication and activation of the cell, which in turn activates CD4 positive T lymphocyte [14]. However, there has been no report on *O. tsutsugamushi* infection and changing immunity. Both VZV and *O. tsutsugamushi* cause infection within cells, but their interaction mechanisms have yet to be determined.

This case study examined a patient who had voiding dysfunction and pain upon urination as the first symptoms of herpes zoster without dermatome lesions. His symptoms improved with the administration of acyclovir and steroids without catheter insertion, intermittent catheterization, or administration of an α -blocker or anticholinergic drugs. In conclusion, when patients under treatment for acute infection report sudden urinary retention, the possibility of voiding dysfunction caused by herpes zoster needs to be considered. Skin rashes on the bottom or lower limbs and changes in sensory nerves need to be checked. Early administration of acyclovir or steroids might help to reduce the duration of urinary dysfunction.

ORCID

Jian Hur

<http://orcid.org/0000-0003-3219-8368>

References

1. Whitley RJ. Varicella-zoster virus. In: Mandell GL, Bennett GE, Dolin R, editors. Mandell, Douglas, and Bennett's principles and practice of infectious diseases. 7th ed. Philadelphia: Churchill Livingstone, Elsevier; 2010;1963-9.
2. Whitley RJ. Varicella-Zoster virus infection. In: Longo DL, Fauci AS, Kasper DL, et al. eds. Harrison's principles of internal medicine. 18th ed. New York: McGraw-Hill; 2012;1462-6.

3. Ragozzino MW, Melton LJ 3rd, Kurland LT, Chu CP, Perry HO. Population-based study of herpes zoster and its sequelae. *Medicine (Baltimore)* 1982;61:310-6.
4. Chen PH, Hsueh HF, Hong CZ. Herpes zoster-associated voiding dysfunction: a retrospective study and literature review. *Arch Phys Med Rehabil* 2002;83:1624-8.
5. Lee DH, Kim HW, Suh HJ, Cho DH. Voiding dysfunction associated with Herpes Zoster. *Korean J Urol* 1999;40:226-8.
6. Park BS, Kim JI, Lee SJ. Comparison of recovery periods according to treatment modalities in Zoster-associated voiding dysfunction. *J Korean Continence Soc* 2007;11:36-40.
7. Broseta E, Osca JM, Morera J, Martinez-Agullo E, Jimenez-Cruz JF. Urological manifestations of herpes zoster. *Eur Urol* 1993;24:244-7.
8. Richmond W. The genito-urinary manifestations of herpes zoster. Three case reports and a review of the literature. *Br J Urol* 1974;46:193-200.
9. Imafuku S, Takahara M, Uenotsuchi T, Iwato K, Furue M. Herpes zoster-associated voiding dysfunction in hematopoietic malignancy patients. *Int J Dermatol* 2008;47:36-9.
10. Yamanishi T, Yasuda K, Sakakibara R, Hattori T, Uchiyama T, Minamide M, Ito H. Urinary retention due to herpes virus infections. *Neurourol Urodyn* 1998;17:613-9.
11. Park KS, Yoon TR, Kim SK, Park HW, Song EK. Acute post-operative herpes zoster with a sciatic nerve distribution after total joint arthroplasty of the ipsilateral hip and contralateral knee. *J Arthroplasty* 2010;25:497:e11-5.
12. Mahajan SK, Kaushik M, Raina R, Thakur P. Scrub typhus and malaria co-infection causing severe sepsis. *Trop Doct* 2014;44:43-5.
13. Phommasone K, Paris DH, Anantatat T, Castonguay-Vanier J, Keomany S, Souvannasing P, Blacksell SD, Mayxay M, Newton PN. Concurrent infection with murine typhus and scrub typhus in southern Laos-the mixed and the unmixed. *PLoS Negl Trop Dis* 2013;7:e2163.
14. Chu H, Park SM, Cheon IS, Park MY, Shim BS, Gil BC, Jeung WH, Hwang KJ, Song KD, Hong KJ, Song M, Jeong HJ, Han SH, Yun CH. *Orientia tsutsugamushi* infection induces CD4+ T cell activation via human dendritic cell activity. *J Microbiol Biotechnol* 2013;23:1159-66.