

Acute disseminated encephalomyelitis after *Plasmodium vivax* infection: case report and review of literature

Jasmeet Sidhu, Anu Maheshwari,
Raju Gupta, Veena Devgan

Department of Pediatrics, North Delhi
Municipal Corporation Medical College,
Hindu Rao Hospital, New Delhi, India

Abstract

Acute demyelinating encephalomyelitis (ADEM) usually occurs after viral infections or vaccination. Its occurrence after *Plasmodium vivax* infection is extremely uncommon. We report the case of an 8-year-old girl who had choreo-athetoid movements and ataxia after recovery from *P.vivax* infection. Diagnosis of ADEM was made on the basis of magnetic resonance imaging findings. The child responded to corticosteroids with complete neurological recovery.

Introduction

Acute disseminated encephalomyelitis (ADEM) is a monophasic, immune mediated, inflammatory and demyelinating disease of the central nervous system (CNS) with diffuse neurological signs and multifocal white matter lesions on neuroimaging.^{1,2} It usually occurs within 2 days to 4 weeks following a viral infection or vaccination.^{3,4} In some patients, no antecedent trigger can be identified. An autoimmune reaction of T-cells against myelin basic protein, triggered by viral infection or vaccination, has been suggested as a possible pathogenesis.⁵ Post-malarial ADEM has been previously reported as a complication of *Plasmodium falciparum*. To the best of our knowledge, only a single case of ADEM following treatment of *Plasmodium vivax* malaria has been reported in pediatric literature.⁶

Case Report

An 8-year old female child presented with complaints of fever and vomiting for 2 days and an episode of generalized tonic clonic seizure on the day of admission. Her mother and sibling were also admitted to our hospital with diagnosis of severe malaria. Vitals revealed

tachycardia and hypotension. On general physical examination, the child had mild pallor with no sign of icterus, cyanosis, edema or lymphadenopathy. Respiratory, cardiovascular and abdominal examinations were normal. Neurological examination showed that the child was drowsy with hypertonia, hyper-reflexia and positive Babinski response. There were no meningeal or cerebellar signs.

Investigations showed hemoglobin 9.8 g/dL, white blood cell count $9.8 \times 10^3/\mu\text{L}$ and platelets $0.37 \times 10^9/\mu\text{L}$. Peripheral smear examination showed multiple trophozoites of *P.vivax* along with thrombocytopenia. Differential leucocyte count was 60% neutrophils, 30% lymphocytes, 3% eosinophils and 7% monocytes. Rapid malaria antigen tests (RMAT) was also positive for *P.vivax*. Serum biochemistry including blood sugar, renal and liver function tests were normal. Cerebrospinal fluid (CSF) examination was normal.

Child was managed in intensive care unit with supportive care for hypotension with crystalloids and ionotropes. In view of peripheral smear and RMAT suggestive of *P.vivax*, the child was started on intravenous artesunate (as per the guidelines of National Vector Borne Disease Control Programme, India, for severe malaria).⁷

The child responded well and was shifted to pediatric ward after one week of admission. Patient did not have any neurological deficit and repeat peripheral smears showed parasitological clearance. On day 15 of illness, the child presented with abnormal movements in form of ataxia and choreo-athetoid movements of limbs. There were no meningeal signs or cranial nerve palsies. Deep tendon reflexes were exaggerated and Babinski sign was present. Repeat peripheral blood smear examination did not show any malarial parasite. Magnetic resonance imaging (MRI) of brain with contrast showed high intensity signals in subcortical, cortical, left parietal, periventricular regions and pons (Figure 1). In view of temporal relationship and latency of symptoms and MRI findings, diagnosis of post malaria ADEM (secondary to *P.vivax*) was made. Patient was started on prednisolone at 2 mg/kg/day for 7 days and tapered over one week. Choreo-athetoid movements decreased and ataxia improved. After 2 weeks of discharge, patient had no neurological sequelae.

Discussion

Severe malaria is known to be classically caused by *P.falciparum* species, but in recent years, *P.vivax* is being increasingly recognized as a cause of severe malaria in children.⁸ ADEM has been reported in literature as a complication of falciparum malaria (Table

Correspondence: Anu Maheshwari, Department of Pediatrics, North Delhi Municipal Corporation Medical College, New Delhi, India.
Tel.: +91.987.3294979.
E-mail: dranugulati@gmail.com

Key words: Acute demyelinating encephalomyelitis; malaria; post-malaria neurological syndrome; *Plasmodium vivax*.

Contributions: the authors contributed equally.

Conflict of interest: the authors declare no potential conflict of interest.

Received for publication: 9 February 2015.

Revision received: 5 March 2015.

Accepted for publication: 6 March 2015.

This work is licensed under a Creative Commons Attribution NonCommercial 3.0 License (CC BY-NC 3.0).

©Copyright J. Sidhu et al., 2015

Licensee PAGEPress, Italy

Pediatric Reports 2015; 7:5859

doi:10.4081/pr.2015.5859

1).^{4,6,9-12} Only a single case of *P.vivax* malaria followed by ADEM has been reported in pediatric age group.⁶ This case reiterates the importance of neurological complications occurring even after recovery from *P.vivax* in concordance with the changing epidemiology of malaria.

Post-malaria neurological syndrome (PMNS) was first described by Nguyen *et al.* as symptomatic malaria infection (initial blood smear positive for asexual forms of parasite), whose parasites have cleared from the peripheral blood and, in cerebral cases, had recovered consciousness fully, who developed neurological or psychiatric symptoms within two months of acute illness.¹³ Schnorf, *et al.* classified PMNS into 3 subtypes according to severity: i) mild and localized encephalopathy, characterized by isolated cerebellar ataxia or postural tremor; ii) diffuse, but relatively mild encephalopathic form, characterized by acute confusion or epileptic seizures; and iii) severe, corticosteroid-responsive encephalopathy, characterized by motor aphasia, generalized myoclonus, postural tremor, and cerebellar ataxia, resembling ADEM.¹⁴ PMNS and ADEM have striking similarities *e.g.* period of latency, multifocal neurological deficits, response to steroids and good prognosis.

Increase in levels of cytokines in cerebrospinal fluid, tumor necrosis factor- and interleukins 2 and 6 have been noted in severe malaria and PMNS.¹⁵ The latency to neurological involvement after eradication of parasite and response to corticosteroids in our patient support an immunological mechanism.

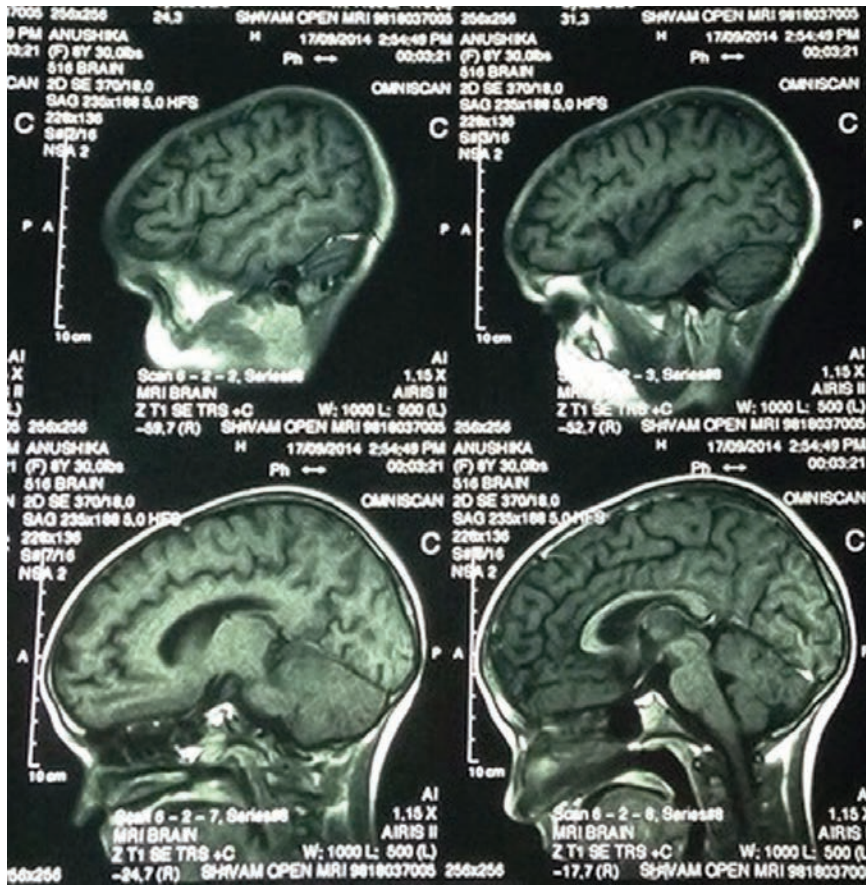


Figure 1. Magnetic resonance imaging of the brain showing high-intensity signals in subcortical, cortical, left parietal, periventricular regions and pons.

Conclusions

Recurrent or new appearance of neurological complications in a known patient of severe malaria should arouse suspicion of ADEM. Cranial MRI should be ordered for confirmation of the diagnosis. Definitive treatment should be instituted as the disease has a good outcome with negligible sequelae.

References

1. Murthy SNK, Faden HS, Cohen ME, Bakshi R. Acute disseminated encephalomyelitis in children. *Pediatrics* 2002;110:e21.
2. Alper G. Acute disseminated encephalomyelitis. *J Child Neurol* 2012;27:1408-25.
3. Van der Wal G, Verhagen WIM, Dofferhoff ASM. Neurological complications following *Plasmodium falciparum* infection. *Neth J Med* 2005;63:180-3.
4. Mohsen AH, McKendrick MW, Schmid ML, et al. Postmalaria neurological syndrome: a case of acute disseminated encephalomyelitis? *J Neurol Neurosurg Psychiatry* 2000;68:388-9.
5. Garg RK. Acute disseminated encephalomyelitis. *Postgrad Med J* 2003;79:11-7.

Table 1. List of cases of acute demyelinating encephalomyelitis reported after recovery from malaria.

First author	Species	Age of patient	Time of neurological complication after recovery from malaria	MRI finding (T2-DWI)	Treatment	Outcome
Mohsen ⁴	<i>P. falciparum</i>	30y	8 weeks	Hyperintensities in subcortical white matter of right frontal and temporal lobes and left cerebellar hemisphere	No steroids	Complete neurological recovery
Sharma ⁹	<i>P. falciparum</i>	20y	2 weeks	Hyperintensities of subcortical white matter, corpus callosum and midbrain	IV methylprednisolone for 3 days	Complete neurological recovery
Rachita ¹⁰	<i>P. falciparum</i>	4y	1 week	Hyperintensities in cerebral hemisphere, subcortical white matter and midbrain	IV methylprednisolone for 3days, then oral steroids	Complete neurological recovery
Agrawal ¹¹	<i>P. falciparum</i>	12y	16 days	Hyperintensities in periventricular white matter, centrum semiovale and genu of corpus callosum	IV methylprednisolone for 5 days, then oral steroids	Complete neurological recovery
Koibuchi ¹²	<i>P. vivax</i>	24y	2 weeks	Hyperintensities in left cerebral cortex and subcortex		Complete neurological recovery
Goyal ⁶	<i>P. vivax</i>	18mo	1 week	Diffuse white matter hyperintensities of subcortical deep and periventricular white matter and both external capsules	IV methylprednisolone for 3 days, then oral steroids for 2 weeks	Complete neurological recovery

y, years; mo, months; MRI, magnetic resonance imaging.

6. Goyal JP, Shah VB, Parmar S. Acute disseminated encephalomyelitis after treatment of Plasmodium vivax malaria. *J Vector Borne Dis* 2012;49:119-21.
7. National Vector Borne Diseases Control programme. Diagnosis and treatment of malaria in India. 2013. Available from: <http://nvbdc.gov.in/Doc/Diagnosis-Treatment-Malaria-2013.pdf>
8. Singh H, Parakh A, Basu S, Rath B. Plasmodium vivax malaria: Is it actually benign? *J Infect Public Health* 2011;4:91-5.
9. Sharma N, Varma S, Bhalla A. Acute disseminated encephalomyelitis after treatment of severe falciparum malaria. *Indian J Med Sci* 2008;62:69-70.
10. Rachita S, Satyasundar M, Mrutunjaya D, Birakishore R. Acute disseminated encephalomyelitis (ADEM)—a rare complication of falciparum malaria. *Indian J Pediatr* 2013;80:499-501.
11. Agrawal A, Goyal S. Acute demyelinating encephalomyelitis in a child following malaria. *Indian Pediatr* 2012;49:922-3.
12. Koibuchi T, Nakamura T, Miura T, et al. Acute disseminated encephalomyelitis following Plasmodium vivax malaria. *J Infect Chemother Off J Jpn Soc Chemother* 2003;9:254-6.
13. Nguyen TH, Day NP, Ly VC, et al. Post-malaria neurological syndrome. *Lancet* 1996;348:917-21.
14. Schnorf H, Diserens K, Schnyder H, et al. Corticosteroid-responsive postmalaria encephalopathy characterized by motor aphasia, myoclonus, and postural tremor. *Arch Neurol* 1998;55:417-20.
15. De Silva HJ, Hoang P, Dalton H, et al. Immune activation during cerebellar dysfunction following Plasmodium falciparum malaria. *Trans R Soc Trop Med Hyg* 1992;86:129-31.