

Multiple Dural Arteriovenous Fistulas Causing Rapid Progressive Dementia Successfully Treated by Endovascular Surgery: Case Report

Kazuhiro ABE,¹ Osamu OKUDA,¹ Hidenori OHISHI,²
Makoto SONOBE,³ and Hajime ARAI²

¹*Department of Neurosurgery, Juntendo Tokyo Koto Geriatric Medical Center, Tokyo;*

²*Department of Neurosurgery, Juntendo University, School of Medicine, Tokyo;*

³*Department of Neurosurgery, Mito Medical Center, National Hospital Organization, Higashi-Ibaraki, Ibaraki*

Abstract

A 67-year-old female presented with multiple dural arteriovenous fistulas (AVFs) manifesting as dementia rapidly progressing over 2 months. The initial diagnosis was Creutzfeldt-Jakob disease based on the acute clinical course. However, angiography eventually revealed multiple dural AVFs involving the bilateral convexities to the superior sagittal sinus and the right transverse-sigmoid sinus. Endovascular treatment combining arterial and venous embolization in multiple stages proved to be effective, as the hemodynamic pathology improved, and the patient recovered from dementia. The cause of the dementia was thought to be venous hypertension in the deep white matter induced by the dural AVFs. Dural AVFs should be included in the differential diagnosis of rapidly progressive dementia.

Key words: progressive dementia, dural arteriovenous fistula, venous hypertension, endovascular surgery, treatable dementia

Introduction

Rapidly progressive dementia, developing over months, weeks, or even days, has a poorer prognosis compared to the more common slowly progressive dementia, that worsens progressively over several years.¹⁾ Rapidly progressive dementia is frequently associated with Creutzfeldt-Jakob disease (CJD), but other causes include chronic subdural hematoma and normal pressure hydrocephalus which are treatable in some cases, so early diagnosis is important. Dural arteriovenous fistulas (AVFs) manifest with a wide range of clinical presentations from tinnitus to intracranial hemorrhage, and often lead to progressive cognitive impairment. Several patients with dural AVF have presented with slowly progressive dementia,^{2–6)} but none with rapidly progressive dementia. We encountered a patient with multiple dural AVFs manifesting as rapidly progressive dementia, who was successfully treated by early endovascular surgery.

Case Report

A 67-year-old female developed rapidly progressive dementia over 2 months after a fall at home, preceded by episodes of headache and nausea without any specific trigger. Initially, CJD was suspected based on the rapidly progressive dementia and hyperintense changes in the bilateral cerebral white matter on magnetic resonance (MR) imaging, but further MR imaging revealed flow voids dorsal to the midbrain, suggesting cerebrovascular malformation, so she was finally referred to our hospital for endovascular treatment 2½ months after the onset.

Physical examination found marked emaciation and significant distention of the bilateral superficial temporal arteries (STAs) on the forehead. Bruit was noted behind the right auricle. The patient remained somnolent with Glasgow Coma Scale score 12 (E4V3M5). She was completely bedridden, opened her eyes occasionally, produced no meaningful sounds, and did not respond to any instructions. Mini-mental state examination (MMSE) was not feasible. Neurological examination detected leg-dominant quadriplegia and tendency to right hemineglect.

MR imaging showed many flow voids in the ambient cistern, and hyperintense changes (leukoaraiosis) on the T₂-weighted and fluid-attenuated inversion recovery images (Fig. 1). Cerebral angiography demonstrated markedly dilated frontal and parietal branches of the bilateral STAs, arteriovenous shunts around the superior sagittal sinus (SSS), another arteriovenous shunt from the right occipital artery to the right transverse-sigmoid sinus (TVS), and marked pseudophlebitic patterns⁷⁾ (Fig. 2). Single photon emission computed tomography (SPECT) showed markedly decreased cerebral blood flow (CBF) over almost the whole brain (Fig. 3, *left*). The diagnosis was high-risk AVFs⁸⁾ with typical clinical and radiological features, classified as Cognard type⁹⁾ IIA+B. Urgent treatment was required⁸⁾ to prevent hemorrhage and/or further neurological deficit.

Multi-stage intervention was planned to embolize the multiple shunts and cortical refluxes. Four endovascular procedures were performed at about 1-week intervals over 5 weeks. The bilateral STAs and right occipital artery were embolized through transarterial approaches with N-butyl-2-cyanoacrylate (Fig. 4, *upper left*), and the right TVS, the origin of the venous reflux from the frontal cortical veins, and the apex of the SSS were embolized through transvenous approaches with coils. Intravenous pressure of the right TVS, which had been markedly high at 31/27 (mean 21) mmHg before treatment, dropped to a normal level of 7/2 (mean 5) mmHg after these interventions.

Postoperative cerebral angiography showed anterograde blood flow and disappearance of all dural AVFs (Fig. 4, *lower left, lower center, lower right*). MR imaging revealed marked improvement in the hyperintense changes of the deep white matter on T₂-weighted images and disappearance of the pial veins. SPECT showed markedly increased

CBF in the bilateral cerebral hemispheres, including the basal ganglia (Fig. 3, *right*).

The patient's symptoms sequentially improved after every intervention. The MMSE score was 16/30 after the third intervention, and improved further to 22/30 at 2 weeks after the fourth intervention. The patient was able to walk and lead an independent life 7 months after completing the treatment, when the MMSE showed a normal score of 30/30, and dementia had completely disappeared. She has remained in stable condition without recurrence for more than 7 years.

Discussion

Several cases of dural AVF have been reported with progressive dementia, but the timing of treatment, severity of dementia, and recovery rates were not discussed in detail.²⁻⁶⁾ These cases were characterized by venous congestive encephalopathy caused by venous hypertension.¹⁰⁾ Venous hypertension occurs more often in the deep venous system than in the superficial venous system,¹¹⁾ so the deep white matter is the most vulnerable to venous congestion. Furthermore, leukoaraiosis may lead to deterioration in higher brain function in the deep white matter and basal ganglia, resulting in subcortical dementia.^{2,6,11)} Selective embolization of the dural AVF resulted in cognitive improvements in 5 of 40 patients with encephalopathy or dementia.²⁾ In the present case, multiple endovascular embolizations of the various AVFs resulted in sequential improvements in symptoms with complete recovery from dementia within 7 months. In particular, MR imaging showed that hyperintense change became less severe, and SPECT demonstrated improved CBF in the deep white matter, cortex, and basal ganglia, and sinus pressure markedly decreased to normal values.

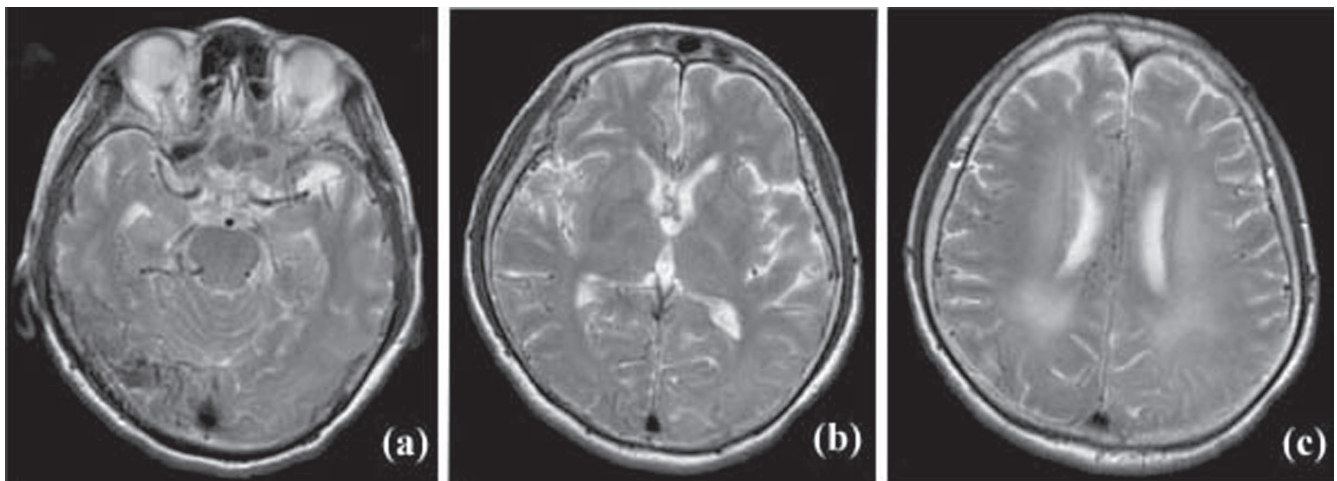


Fig. 1 Magnetic resonance images on admission. Axial T₂-weighted images demonstrating numerous dilated pial veins draining into the right transverse sinus (a), and hyperintense change, indicating leukoaraiosis, in the deep white matter (c). No hyperintense change is seen in the basal ganglia, especially the thalamus (b).

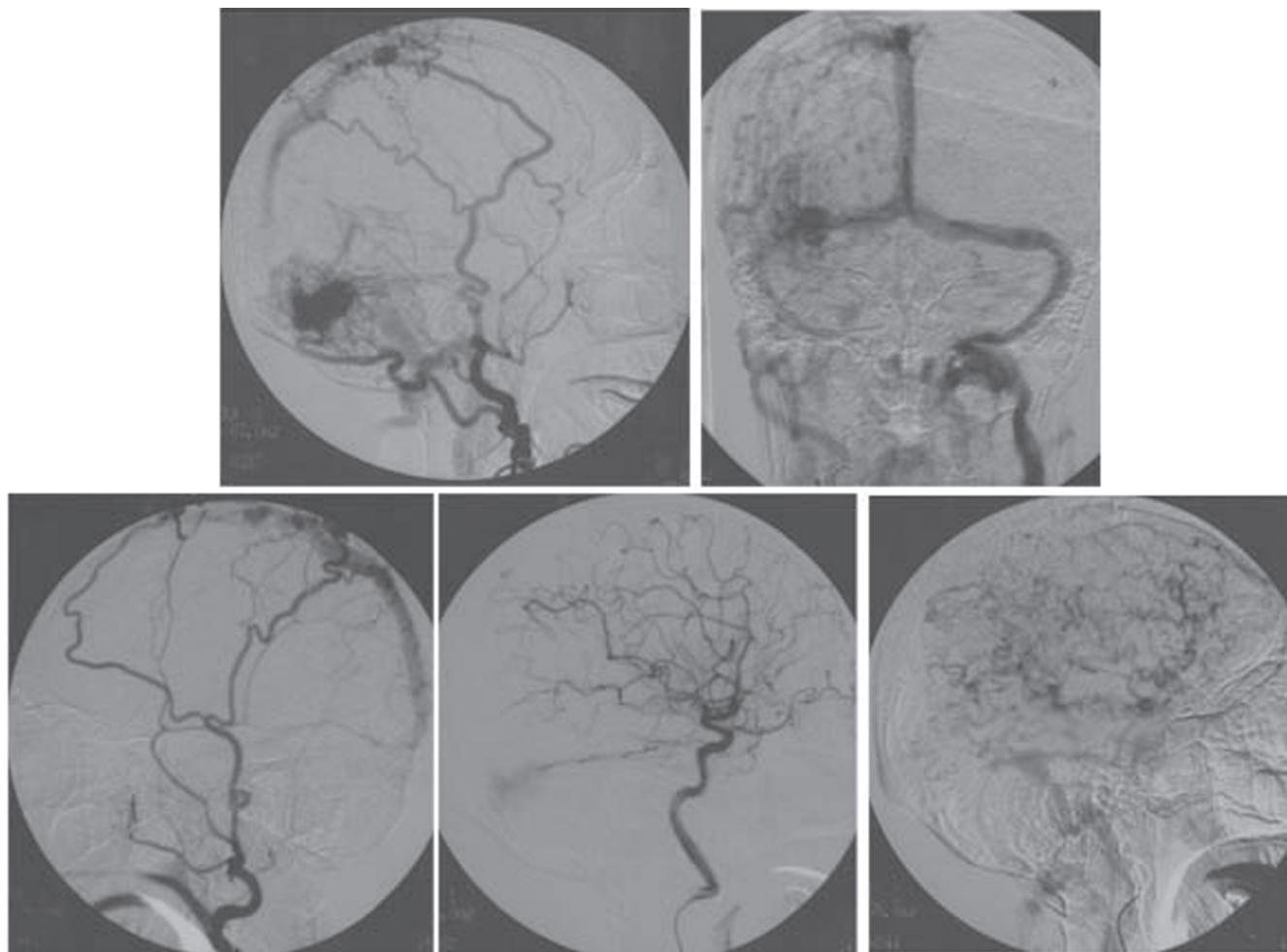


Fig. 2 Angiograms before surgery. Right external carotid angiograms demonstrating a large dural arteriovenous fistula (AVF) involving the right transverse-sigmoid sinus fed by the right occipital artery, and another dural AVF located in the middle third of the superior sagittal sinus fed by the bilateral middle meningeal and bilateral superficial temporal arteries (*upper left, upper right*). Left external carotid angiogram demonstrating retrograde venous outflow, draining into the dural AVF of the superior sagittal sinus and cortical veins of the right frontal cortex (*lower left*). Right internal carotid angiogram demonstrating the dural AVF involving the right transverse-sigmoid sinus fed by the right tentorial artery (*lower center*). Right internal carotid angiogram (early venous phase) demonstrating markedly severe pseudophlebitic pattern (*lower right*).

Hyperintense change on T₂-weighted MR images may correspond to the hypoperfusion areas observed on SPECT,¹²⁾ and extensive leukoaraiosis on MR imaging disappears after treatment,^{2,6,11)} concurrent with improvement of cognitive impairment. Such findings suggest that venous hypertension is involved in the occurrence of subcortical dementia. Previous cases had a single dural AVF manifesting as slowly progressive dementia over several months to years.²⁻⁶⁾ The present case showed much more rapid progression over only 2 months, which may have resulted from the multiplicity of lesions, including three dural AVFs, and thus required prompt and specific treatments. The rapid improvement in the venous hypertension achieved by the consecutive intravascular procedures over 5 weeks after diagnosis

is considered to be the main cause of the successful treatment.

The differential diagnosis of rapid progressive dementia includes a wide variety of etiologies from prion, neurodegenerative, autoimmune, infectious, malignant, toxic/metabolic, and vascular diseases, to surgical diseases such as chronic subdural hematoma and brain tumor. CJD is only one of many disorders to consider,¹⁾ but is specifically characterized by rapidly progressive dementia.¹³⁾ The present patient had focal symptoms such as right hemineglect, which led to an incorrect diagnosis at the previous hospital. Additionally, the marked emaciation and significant distention of the bilateral STAs on the forehead resulted in an unusual physical appearance. Distention of the bilateral STAs on the forehead is not a

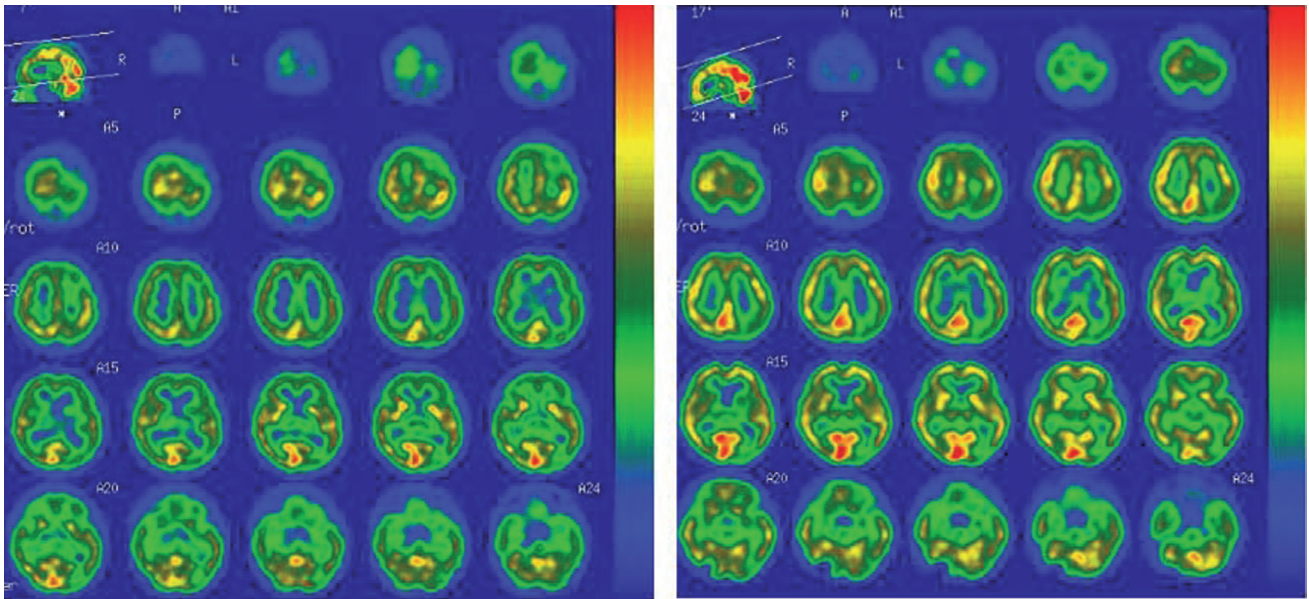


Fig. 3 Iodine-123 N-isopropyl-p-iodoamphetamine (^{123}I -IMP) single photon emission computed tomography (SPECT) scan on admission demonstrating hypoperfusion over almost the whole brain including the bilateral basal ganglia (*left*). ^{123}I -IMP SPECT scan after surgery demonstrating normal cerebral blood flow (CBF) except for the CBF defect at the venous infarction site (*right*).

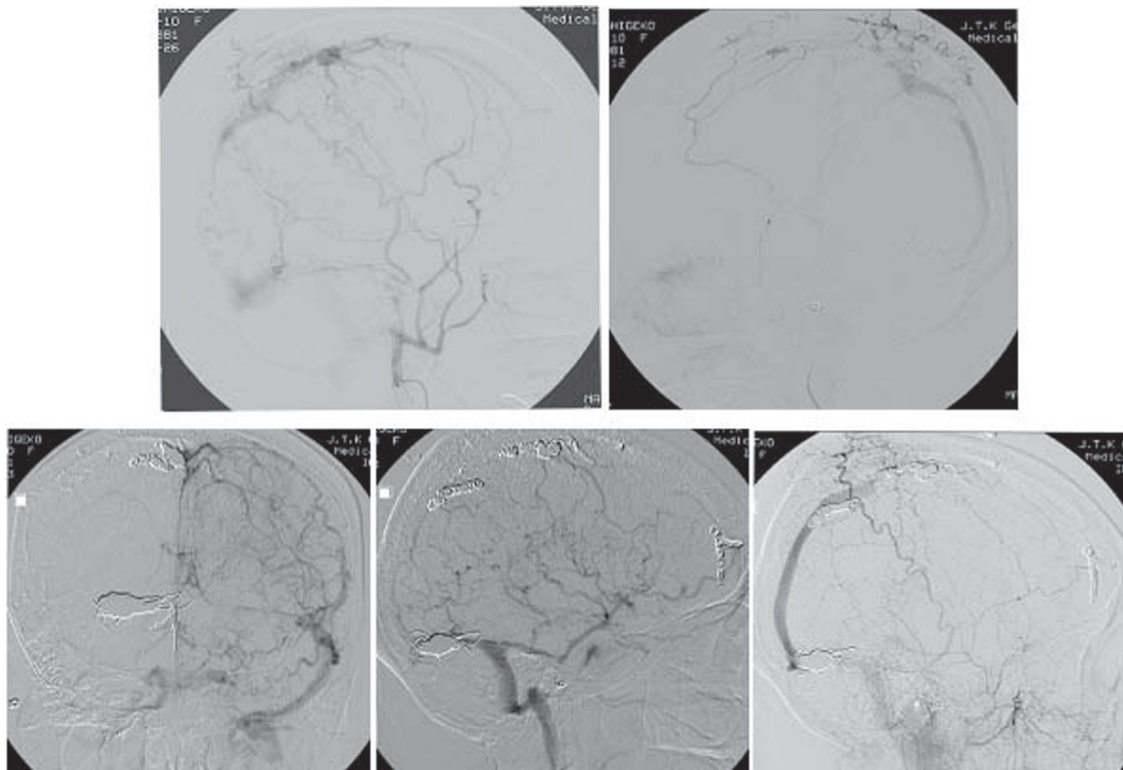


Fig. 4 Left external carotid angiogram after the second operation demonstrating the right occipital artery occluded by N-butyl-2-cyanoacrylate and Eudragit (*upper left*). Right external carotid angiogram after the third operation demonstrating that the dural arteriovenous fistula (AVF) of the superior sagittal sinus still remained (*upper right*). Left internal carotid and right external carotid angiograms after all operations demonstrating that the dural AVF of the transverse-sigmoid sinus, occluded by platinum coils, had completely disappeared, and the dural AVF of the superior sagittal sinus still remained, but the blood flowed anterogradely (*lower left, lower right*). Right internal carotid angiogram after all operations demonstrating that the pseudophlebatic pattern had completely disappeared (*lower center*).

specific sign of dural AVFs, but may occur occasionally, so should be recognized as a possible sign.

Dural AVF should be included in the differential diagnosis of rapidly progressive dementia. Dural AVF is currently considered to be a treatable disorder, thus rapid and accurate diagnosis is important. Selective cerebral angiography can establish the definitive diagnosis and provide the rationale for dural AVF therapy.⁹⁾

Conflicts of Interest Disclosure

The authors have no personal, financial, or institutional interest in any of the drugs, materials, or devices in the article. All authors who are members of The Japan Neurosurgical Society (JNS) have registered online Self-reported COI Disclosure Statement Forms through the website for JNS members.

References

- 1) Geschwind MD, Shu H, Haman A, Sejvar JJ, Miller BL: Rapidly progressive dementia. *Ann Neurol* 64: 97–108, 2008
- 2) Hurst RW, Bagley LJ, Galetta S, Glosser G, Lieberman AP, Trojanowski J, Sinson G, Stecker M, Zager E, Raps EC, Flamm ES: Dementia resulting from dural arteriovenous fistulas: the pathologic findings of venous hypertensive encephalopathy. *AJNR Am J Neuroradiol* 19: 1267–1273, 1998
- 3) Nakahara Y, Ogata A, Takase Y, Maeda K, Okamoto H, Matsushima T, Sakata S: Treatment of dural arteriovenous fistula presenting as typical symptoms of hydrocephalus caused by venous congestion: case report. *Neurol Med Chir (Tokyo)* 51: 229–232, 2011
- 4) van Dijk JM, terBrugge KG, Willinsky RA, Wallace MC: Clinical course of cranial dural arteriovenous fistulas with long-term persistent cortical venous reflux. *Stroke* 33: 1233–1236, 2002
- 5) Waragai M, Takeuchi H, Fukushima T, Haisa T, Yonemitsu T: MRI and SPECT studies of dural arteriovenous fistulas presenting as pure progressive dementia with leukoencephalopathy: a cause of treatable dementia. *Eur J Neurol* 13: 754–759, 2006
- 6) Yamakami I, Kobayashi E, Yamaura A: Diffuse white matter changes caused by dural arteriovenous fistula. *J Clin Neurosci* 8: 471–475, 2001
- 7) Willinsky R, Terbrugge K, Montanera W, Mikulis D, Wallace MC: Venous congestion: an MR finding in dural arteriovenous malformations with cortical venous drainage. *AJNR Am J Neuroradiol* 15: 1501–1507, 1994
- 8) Tsai LK, Jeng JS, Liu HM, Wang HJ, Yip PK: Intracranial dural arteriovenous fistulas with or without cerebral sinus thrombosis: analysis of 69 patients. *J Neurol Neurosurg Psychiatr* 75: 1639–1641, 2004
- 9) Cognard C, Gobin YP, Pierot L, Bailly AL, Houdart E, Casasco A, Chiras J, Merland JJ: Cerebral dural arteriovenous fistulas: clinical and angiographic correlation with a revised classification of venous drainage. *Radiology* 194: 671–680, 1995
- 10) Deveikis JP: Venous hypertensive encephalopathy. *AJNR Am J Neuroradiol* 19: 1274–1275, 1998
- 11) Zeidman SM, Monsein LH, Arosarena O, Aletich V, Biafore JA, Dawson RC, Debrun GM, Hurko O: Reversibility of white matter changes and dementia after treatment of dural fistulas. *AJNR Am J Neuroradiol* 16: 1080–1083, 1995
- 12) Kai Y, Hamada J, Morioka M, Todaka T, Mizuno T, Ushio Y: Pre- and post-treatment MR imaging and single photon emission CT in patients with dural arteriovenous fistulas and retrograde leptomeningeal venous drainage. *AJNR Am J Neuroradiol* 24: 619–625, 2003
- 13) Brandel JP, Delasnerie-Lauprêtre N, Laplanche JL, Hauw JJ, Alperovitch A: Diagnosis of Creutzfeldt-Jakob disease: effect of clinical criteria on incidence estimates. *Neurology* 54: 1095–1099, 2000

Address reprint requests to: Osamu Okuda, MD, Department of Neurosurgery, Juntendo Tokyo Koto Geriatric Medical Center, 3-3-20, Shinsuna, Koto-ku, Tokyo 136-0075, Japan. e-mail: ookuda@juntendo.gmc.ac.jp